

CASE REPORT

Spinal Tap Needle Technique for Creating Apical Plug with Mineral Trioxide Aggregate in Immature Permanent Teeth

Preetika Yadav¹, Mandeep S Viridi²

ABSTRACT

Aim: This report evaluates the apical plug formation in two cases with necrotic immature maxillary central incisors in 11 and 12 years old female patients by the use of spinal tap needle to create apical plug-in single increment without any residual mineral trioxide aggregate (MTA) attachment to the wall of the root canal.

Materials and methods: The shape of the immature root canal resembles a truncated cone. To achieve a truncated cone with MTA on the apical 4 mm in order to plug the open apex, the volume of material that will be required can be calculated by taking spinal tap needle (BD Spinal, Spain) equal to the last file used, in a way that the MTA extruded is equal to the amount required to shape the apical plug in a single increment.

Result: A uniform void-free apical plug was made in single increments by using this technique.

Conclusion: This spinal tap needle is very economical, available in various sizes corresponding to endodontic K files, so spinal tap needle method is a viable method to create uniform void-free accurate apical plug in one increment without the wastage of material and time preventing the material to extrude beyond.

Keywords: Calcium hydroxide, Mineral trioxide aggregate, Pediatric dentistry.

International Journal of Clinical Pediatric Dentistry (2022): 10.5005/jp-journals-10005-2388

INTRODUCTION

In pediatric dentistry many a times we encounter tooth with incomplete root development as a consequence of pulp necrosis through trauma or caries, the absence of natural constriction at the end of the canal makes obturating material control difficult.¹ One of the aims of root canal treatment is to completely fill the canal system in order to prevent reinfection. Because of the lack of an apical constriction, an alternative to standard root canal remedy, apexification, or root-stop-closure has been advocated.¹

The conventional technique is initiation of apexification with the aid of induction of calcific barrier in a root with an open apex or continued apical development of tooth with incomplete roots and a necrotic pulp.² First material of choice for apexification is calcium hydroxide,³ with repeatedly changing of the calcium hydroxide over a period of 5–20 months to induce the formation of a calcific barrier.⁴ The unpredictable and often lengthy duration of this treatment modality presents challenges, along with the vulnerability of the temporary coronal filling with reinfection.⁵ Moreover, this treatment needs great amount of patient's compliance. For these reasons, single visit apexification has been suggested.⁶ MTA has been proposed as an appropriate material for formation of apical plug⁷ because MTA combines biocompatibility,⁸ and a bacteriostatic action with favorable sealing ability while used to restore root/pulp chamber perforations⁹ or as root-end filling material.¹⁰ MTA offers a barrier at the end of the root canal (apical plug) in teeth with necrotic pulps and open apices that lets in vertical condensation of heat gutta-percha inside the rest of the canal.⁸

Some authors¹¹ suggest that the success of the apical plug formation method could be influenced by the intracanal delivery approach. Aminoshariae et al.¹¹ obtained satisfactory adaptation of MTA by usage of hand instrumentation methods rather than by means of ultrasonic condensation, which turned out to be superior.¹²

¹Department of Pedodontics, PDM Dental College and Research Institute, Rohtak, Haryana, India

²Department of Pediatric Dentistry, PDM Dental College and Research Institute, Rohtak, Haryana, India

Corresponding Author: Preetika Yadav, Department of Pedodontics, PDM Dental College and Research Institute, Rohtak, Haryana, India, Phone: +91 8930691841, e-mail: preetika122@gmail.com

How to cite this article: Yadav P, Viridi MS. Spinal Tap Needle Technique for Creating Apical Plug with Mineral Trioxide Aggregate in Immature Permanent Teeth. *Int J Clin Pediatr Dent* 2022;15(3):380–384.

Source of support: Nil

Conflict of interest: None

Here we are presenting an exactly controlled technique of the use of spinal tap needle to create a uniform void free apical plug which has an advantage of being very economical, easily available in different gauge size corresponding to the ISO no. of the endodontic files. Conventional placement of apical barrier resorbable matrix like CollaPlug, CollaCote, CollaTape, and CaSO₄ is done over which apical plug is created with MTA. Resorbing of this matrix relies on the healing capability and immune system of the body. Placement of the matrix activates immune reaction to resorb this artificial matrix and this matrix remains partially unresorbed in some cases.

MATERIALS AND METHODS

Spinal tap needle has two parts; a hollow needle and a stylet which is inserted inside the hollow needle both are cut to appropriate size keeping the length of stylet more than the needle that will aid to push the MTA material out of spinal tap needle (Fig. 1).

The shape of the immature root canal resembles a truncated cone. To achieve a truncated cone with MTA on the apical 4 mm in order to plug the open apex, the volume of material that will be

required can be calculated by taking spinal tap needle (BD Spinal, Spain) equal to last file used, in a way that the MTA extruded is equal to the amount required to shape the apical plug in a single increment. To create an apical plug of 4 mm the last endodontic file K file (MANI, Japan) which is loosely fitted on the apical third is taken and equal spinal needle is selected based upon the outer diameter of the spinal tap needle (Table 1).

Formula used to calculate the required height up to which MTA is to be filled in spinal tap needle equivalent to volume of material to form apical plug is calculated using the following method.

Volume of each increment by the spinal tap being a hollow cylinder.

$$\text{Formula} = 3.14 (OR^2 - IR^2) H$$

OR = outer radius, IR = inner radius, H = height

Endo file is tapering in shape and the diameter at the tip is different at different graduations as we move up toward the base of the file. So, the shape of the endodontic file resembles the truncated cone (Fig. 2).

$$\text{Formula} = 1/3 \times 3.14 h (r^2 + Rr + R^2)$$

R = radius at tip of file, r = radius at height of 4 mm

From the calculation it is deduced that if an apical plug of 4 mm is required, MTA must be filled up to 6 mm in spinal tap needle of equal length of last file. The spinal tap needle with MTA will be positioned 4 mm short of apex and material is pushed completely. This will make the desired MTA plug of 4 mm in a single increment (Table 2).

CASE DESCRIPTION

Case 1

A 12-year-old female referred with complain of a dull ache and slight swelling on the upper lip area. The medical history of the patient was noncontributory during extraoral evaluation;

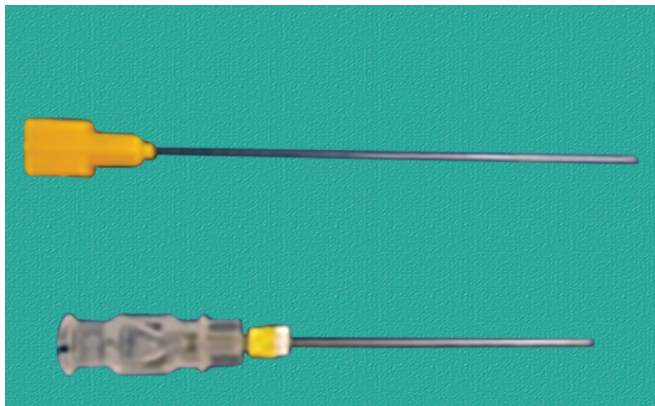


Fig. 1: Parts of spinal tap needle

Table 1: Equivalent spinal tap needle corresponding to last used K file

Endodontic file no.	Equivalent spinal needle gauge
45	26
50	25
60	23
70	22
80	21
90	20

there was a localized swelling in the periapical area of the left central incisor. The central incisor was sensitive to percussion and showed grayish discoloration. The patient reported history of trauma to her upper teeth 2 years earlier. The response of electric pulp tester was negative. Periapical radiographs showed moderate radiolucent lesion. The teeth had immature roots with open apex. The final diagnosis was pulp necrosis with acute apical abscess. After explaining the condition of the teeth and possible treatment modalities, an informed consent was taken from patient's parent (Figs 3A to F).

The tooth was anesthetized using local anesthetic solution (2% lidocaine, 1:80,000) and access opening done under rubber dam. Working length was kept 2 mm short of apex. The canal was gently cleaned and debrided using 60 no. K file and irrigation was done using 20 mL 3% sodium hypochlorite followed by irrigation with normal saline, dried with paper points, and calcium hydroxide dressing was given. Access cavity was sealed with Cavit G. Patient was dismissed and a course of antibiotics was advised for 5 days. At the second visit tooth was asymptomatic. Apical plug was formed with MTA using spinal tap needle was kept 4 mm short of the working length and the MTA was pushed out. At the second visit spinal tap needle equivalent to last file used in first visit is selected, stopper is adjusted on the spinal tap needle 4 mm short of the determined working length, then stylet is placed inside the spinal needle 6 mm short and the MTA was filled into the spinal needle from direction opposite to needle hub and then spinal tap needle was introduced into the canal up to marked stopper length and stylet was pushed to its maximum limit to extrude the MTA out of the spinal tap needle this leads to formation of 4 mm of MTA apical plug that is confirmed with a periapical radiograph. At third visit the remaining length of the canal was obturated up to 2 mm below cement enamel junction (CEJ) using Calamus 3-D obturating

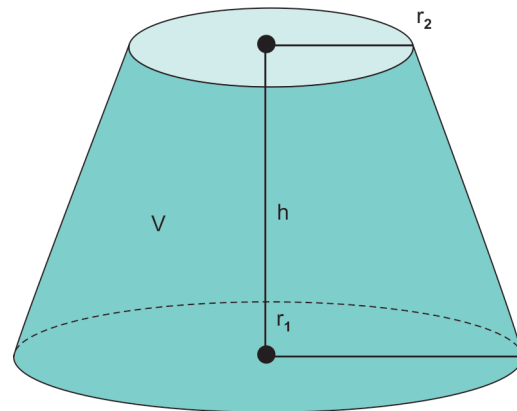


Fig. 2: Circular truncated cone shape resembling cross-section of endodontic file

Table 2: Calculation to determine the height of MTA to be taken in selected spinal tap needle

Endo file	Equivalent spinal needle gauge	Radius of endo file at tip	Radius of endo file at height 4 mm	Volume of MTA required when canal prepared with endo file	Height up to which spinal needle should be filled
60	23	0.30	0.33	1.276	6 mm
70	22	0.35	0.38	1.674	6 mm

technique and endofloss was used as sealer. Later the coronal post endodontic restoration was done and porcelain crown was placed.

Case 2

An 11-year-old female reported with a chief complaint of broken front tooth since 1.5 years with pain in left central incisor since 2 months. The medical history was noncontributory, on extraoral examination no swelling was visible. On intraoral examination the 21 was sensitive to percussion and showed slight grayish hue of discoloration. The response of tooth to electric pulp tester was negative. Periapical radiograph revealed immature open apex and radiolucency surrounding it. The final diagnoses was pulp necrosis.

After explaining the condition of tooth and possible treatment modalities, an informed consent was obtained from patient’s parents and treatment was started.

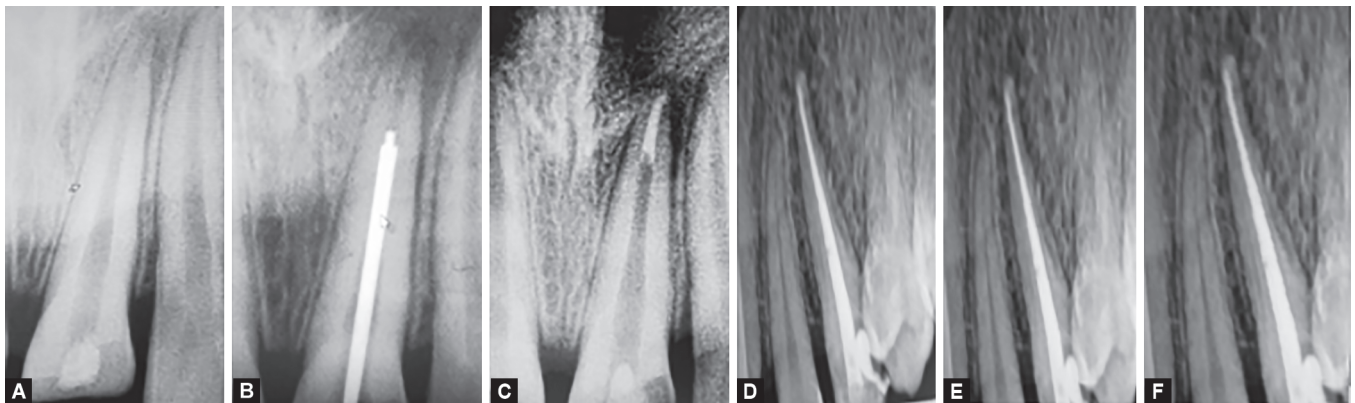
Similarly as in case 1 tooth was anesthetized, isolated with rubber dam, access opening done, and working length was determined. Canal was cleaned and debrided up to 70 no. K file, copious amount of irrigation was done with 3% sodium hypochlorite and calcium hydroxide dressing was given and canal sealed with Cavit G. On second visit tooth was examined for tenderness on percussion and paper points no. 70 were introduced into the canal and upon confirmation of the dry canal same steps as in case 1 were followed to create apical plug of 4 mm using 22 gauge spinal tap needle and apical plug was confirmed with periapical radiograph. Followed by backfill obturation using Calamus 3-D technique later followed by porcelain crown placement (Figs 4A to G).

DISCUSSION

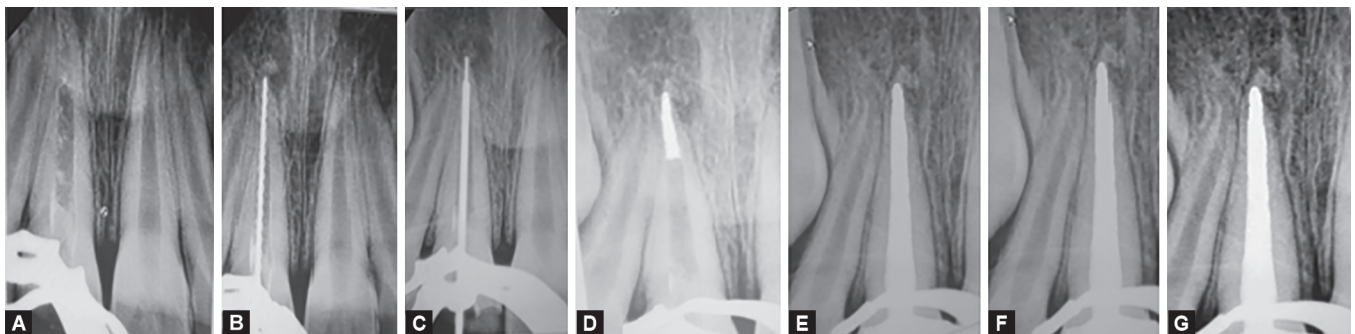
In pediatric dentistry very frequently we are presented with an immature tooth as a consequence of pulp necrosis through trauma or caries. Absence of natural constriction at the end of root canal makes control of filling material difficult. The main objective of any endodontic treatment is to achieve a hermetic seal to avoid reinfection of the tooth, but achieving hermetic seal in tooth with immature root by conventional root canal therapy is not possible. So for dealing with such cases other treatment modalities have been advocated. One of these is root-end closure.¹ The achieved crown to root ratio is also one of the main factor to be considered while selecting the most appropriate treatment plan.

The conventional ways of root canal closure is by initiating apexification to induce a calcific barrier in roots with open apex. This treatment is inherently lengthy and its outcome depends on the patient’s compliance as the patient has to undergo multiple visits for evaluation of the outcome of the procedure and frequent follow-ups till complete root canal closure has been achieved by conventional apexification.

Calcium hydroxide is the commonly used material for apexification. It has a high success rate when used for apexification treatment. However, there are some disadvantages of this material. One of them is that the treatment requires a very long time which is from 3 to 21 months. The required time is dependent on the diameter of the open apex, during this period of time, root canal may get infected by the leakage of the temporary coronal filling. The success



Figs 3A to F: Complete apical plug procedure stepwise radiographs done using spinal tap needle in case 1 and follow-ups at 6 and 12 months. (A) tooth with open apex; (B) spinal tap no. of equivalent no is selected; (C) apical plug created with selected spinal needle; (D) one month follow-up; (E) 6 months follow-up; (F) 12 months follow-up



Figs 4A to G: Complete apical closure procedure stepwise radiographs done with spinal tap needle in case 2 along with follow-ups at 6 and 12 months. (A) tooth with open apex; (B) K file selected; (C) spinal tap needle selected; (D) apical plug created with spinal needle; (E) one month follow-up; (F) 6 months follow-up; (G) 12 months follow-up

rate decreases by 10% in teeth with poor coronal filling.⁷ Therefore, performing a definitive treatment is always better as it avoids the possible reinfection of the root canal. Also there is possibility of fracture of the weakened tooth. As it is known that leaving calcium hydroxide in the root for more than 30 days, the fracture resistance reduces.⁹ The patient's motivation is also one of the critical factors. Multiple appointments and esthetic problems may be reason of patient complaint in the calcium hydroxide apexification treatment.

In recent times, creating MTA apical plug in one visit is suggested for the treatment of the nonvital immature permanent teeth as an alternative to long-term apexification treatment.¹³ Lee et al. first described this material to dental literature in 1993. MTA is a material which has less leakage, better antibacterial properties, high marginal adaptation, short setting time (~4 hours), a pH of 12.5, and is more biocompatible. A biocompatible material MTA stimulates the release of cytokine and interleukins. So it is capable of promoting the hard tissue formation. The clinician may restore the tooth after setting of MTA, the fracture resistance of the teeth with thin dentinal walls increases. MTA can be used in teeth with pulp necrosis and inflamed periapical lesions because it sets in moist environments.¹⁴

In apical plug technique using MTA, root canals must be disinfected firstly with calcium hydroxide dressing before placing MTA for 2 weeks. Because performing chemomechanical preparation alone is not effective for the elimination of microorganisms completely, hence, we used calcium hydroxide dressing for 2 weeks in these cases.

The requirement of forming a successful apical plug is two-fold, first, the plug should be formed for approximately 4 mm of length at apex, second, there should be no extrusion of the material from the apex. The use of spinal tap needle has been introduced which has two parts, a hollow needle and a stylet which is inserted inside the hollow needle both are cut to appropriate size keeping the length of stylet more than the needle, that will aid to push the MTA material out of spinal tap needle to calculate the amount of MTA to be loaded. The shape of the immature root canal is compared to a truncated cone.

To achieve a truncated cone with MTA at the apical 4 mm which will plug the open apex, the volume of material that will be required is calculated by taking spinal tap needle equivalent to last file used, in a manner that MTA extruded is equal to the amount required to form the apical plug in one increment. To create an apical plug of 4 mm the last file which is loosely fitted at the apical third is taken and equivalent spinal needle is selected on the basis of the outer diameter of the spinal tap needle. From the calculations it is deduced that in order to make apical plug of 4 mm, MTA will have to be filled up to 6 mm in spinal tap needle of equivalent size of last file. The spinal tap needle with MTA will be placed 4 mm short of apex and material is pushed completely. This will form the desired MTA plug of 4 mm in a single increment.

Using spinal tap needle is an accurate, economical, and convenient method for placement of MTA. When MTA is placed using spinal tap needle following the calculation based on formula described earlier it is possible to place the exact amount of material to form the plug without voids and chances of extruding out material is also negligible.

In these clinical cases, after calcium hydroxide medication, on second visit we used filled spinal tap needle with MTA to 6 mm height and by pushing the stylet fully at selected working length we achieved apical plug of 4 mm in one increment.

The importance of limiting the MTA within the canal cannot be overemphasized, as described by Erdem and Sepet wherein if MTA was extruded beyond the canal the periapex showed incomplete healing.¹⁵ According to their study, reasons of the failure are unusual shape and width of the canal, disinfecting difficulties of the canal and dentinal tubules along with porous structure of the calcified apical barrier. Conventionally to avoid extrusion an apical barrier is placed using resorbable matrix like CollaPlug, CollaCote, CollaTape, and CaSO₄ over which apical plug is created with MTA. Resorbing of this matrix is dependent on the healing capability and immune system. Placement of the matrix activates immune reaction to resorb this artificial matrix and sometimes this matrix remains partially unresorbed.

In these two cases, 3, 6, 9, and 12 months radiographic and clinical follow-ups revealed the complete healing of the apical lesions and the regeneration of periradicular tissues. The clinical examination of these cases confirmed the suitability of this method.

CONCLUSION

This spinal tap needle is very economical, available in various sizes corresponding to file size, a fresh needle is used in every case as it is very cost effective, there is no use of matrix at apex and no attachment of the MTA to the walls of the root canal as the material is only pushed out after inserting the needle to the desired working length. So spinal tap needle method is a viable method to create uniform void free accurate apical plug in one increment without the wastage of material and time preventing the material to extrude beyond.

Bullet Points

- Trauma of permanent anterior teeth has very high incidence and pediatric dentist encounters such teeth with open apex every frequently.
- MTA apical plug is made by using various methods, one of the innovative method has been developed by use which is very economical and easy to use.
- Spinal needle is available in sizes equivalent to the endodontic K files effective in making void free accurate apical plug in one increment.

AUTHOR CONTRIBUTIONS

Preetika Yadav and Mandeep S Viridi conceived the idea.

Preetika Yadav did the cases and formulated the tables.

Mandeep S Viridi analyzed the final table.

Preetika Yadav did the final writing.

REFERENCES

1. Seltzer S. Endodontology: Biologic Considerations in Endodontic Procedures, 2nd ed. Philadelphia: Lea & Febiger; 1988.
2. American Association of Endodontists. Glossary of Endodontic Terms, 7th ed. Chicago: American Association of Endodontists; 2003.
3. Rafter M. Apexification: a review. Dent Traumatol 2005;21(1):1–8. DOI: 10.1111/j.1600-9657.2004.00284.x
4. Sheehy EC, Roberts GJ. Use of calcium hydroxide for apical barrier formation and healing in nonvital immature permanent teeth: a review. Br Dent J 1997;183(7):241–246. DOI: 10.1038/sj.bdj.4809477
5. Magura ME, Kafrawy AH, Brown Jr CE, et al. Human saliva coronal microleakage in obturated root canals: an in vitro study. J Endod 1991;17(7):324–331. DOI: 10.1016/S0099-2399(06)81700-0

6. Deepti A, Shifar S, Muthu MS, et al. Apical closure of immature molar roots: a rare case report. *Int J Clin Pediatr Dent* 2008;1(1):54–57. DOI: 10.5005/jp-journals-10005-1010
7. Torabinejad M, Chiavian N. Clinical application of mineral trioxide aggregate. *J Endod* 1993;25(3):197–205. DOI: 10.1016/S0099-2399(99)80142-3
8. Koh ET, McDonald F, Pitt Ford TR, et al. Cellular response to mineral trioxide aggregate. *J Endod* 1998;24(8):543–547. DOI: 10.1016/S0099-2399(98)80074-5
9. Torabinejad M, Hong CU, Pitt Ford TR, et al. Antibacterial effects of some root end filling materials. *J Endod* 1995;21(8):403–406. DOI: 10.1016/s0099-2399(06)80824-1
10. Al-Kahtani A, Shostad S, Schifferle R, et al. In-vitro evaluation of microleakage of an orthograde apical plug of mineral trioxide aggregate in permanent teeth with simulated immature apices. *J Endod* 2005;31(2):117–119. DOI: 10.1097/01.don.0000136204.14140.81
11. Aminoshariae A, Hartwell GR, Moon PC. Placement of mineral trioxide aggregate using two different techniques. *J Endod* 2003;29(10):679–682. DOI: 10.1097/00004770-200310000-00017
12. Lawley GR, Schindler WG, Walker WA, et al. Evaluation of ultrasonically placed MTA and fracture resistance with intracanal composite resin in a model of apexification. *J Endod* 2004;30(3):167–172. DOI: 10.1097/00004770-200403000-00010
13. Porkaew P, Rettief H, Barfield RD, et al. Effects of calcium hydroxide paste as an intracanal medicament on apical seal. *J Endod* 1998;24(8):176–179. DOI: 10.1016/S0099-2399(06)81908-4
14. Lee SJ, Torabinejad M, Smith PW, et al. Comparative investigation of marginal adaptation of mineral trioxide aggregate and other commonly used root-end filling materials. *J Endod* 1995;21(6):295–299. DOI: 10.1016/S0099-2399(06)81004-6
15. Erdem A, Sepet E. Mineral trioxide aggregate for obturation of maxillary central incisors with necrotic pulp and open apices. *Dent Traumatol* 2008;25(5):e38–e41. DOI: 10.1111/j.1600-9657.2008.00636.x