

## Research Article

# A New Orthodontic Appliance with a Mini Screw for Upper Molar Distalization

Nurhat Ozkalayci<sup>1</sup> and Mehmet Yetmez<sup>2</sup>

<sup>1</sup>Department of Orthodontics, Faculty of Dentistry, Bulent Ecevit University, 67100 Zonguldak, Turkey

<sup>2</sup>Department of Mechanical Engineering, Faculty of Engineering, Bulent Ecevit University, 67100 Zonguldak, Turkey

Correspondence should be addressed to Nurhat Ozkalayci; [dt.nurhat@yahoo.com](mailto:dt.nurhat@yahoo.com)

Received 29 April 2016; Accepted 30 June 2016

Academic Editor: Alberto Borboni

Copyright © 2016 N. Ozkalayci and M. Yetmez. This is an open access article distributed under the Creative Commons Attribution License, which permits unrestricted use, distribution, and reproduction in any medium, provided the original work is properly cited.

The aim of this study is to present a new upper molar distalization appliance called Cise distalizer designed as intraoral device supported with orthodontic mini screw for upper permanent molar distalization. The new appliance consists of eight main components. In order to understand the optimum force level, the appliance under static loading is tested by using strain gage measurement techniques. Results show that one of the open coils produces approximately 300 gr distalization force. Cise distalizer can provide totally 600 gr distalization force. This range of force level is enough for distalization of upper first and second molar teeth.

## 1. Introduction

Orthodontic problems can be classified as skeletal problems and dental problems. Skeletal problems can be originated from skeletal deviations and treated with orthopedic corrections, fixed mechanics, or surgery. Dental problems are classified as dental class I malocclusion, dental class II malocclusion, and dental class III malocclusion. Dental class II malocclusion is generally caused by the early loss of the upper deciduous second molar. After early tooth loss, upper first permanent molars erupt more mesially than their normal locations or drift mesially [1–3]. On one hand, upper first premolars' extraction followed by fixed orthodontic treatment is mostly chosen treatment way of this type of dental malocclusion. On the other hand, upper molar distalization can be used as alternative treatment way [4–6]. This type of molar tooth movement can be achieved by extraoral or intraoral orthodontic appliances [7, 8]. The main disadvantages of extraoral appliances are aesthetic appearance and need of patient cooperation [9, 10]. In order to eliminate such need, intraoral appliances are designed for usage [1–3]. The class II elastics or intermaxillary anchorage is one of the ways that correct the class II dental relationships but the lower incisor protrusion and the bite deepening are the most probably seen

side effects of this elastic usage. Removable appliances can be also used for the upper molar distalization but it is difficult to provide enough anchorage with removable appliances due to their retention limits, whereas the upper incisor protrusion is the possible disadvantage of these mechanics. Another disadvantage of these devices is the fact that their success is directly dependent on the patient's compliance like headgears. Only fixed mechanics with coils do not achieve proper molar distalization. Another common way for upper molar distalization is the extraction of the second molar or distalizing the upper molar before the second molar eruption [11]. However, loss of the upper second molar is a cold idea for patients and clinician in general clinical practice. In addition to that, the anchorage need is one of the main problems for intraoral appliances [12]. Intraoral appliances can be supported by teeth or/and soft tissue [13]. However, side effects like soft tissue irritation and unwanted tooth movement can be seen due to teeth and soft tissue anchorage [14]. Recently, to avoid these side effects, the most popular way of the intraoral anchorage is the use of orthodontic mini screw [15]. New appliances which supported orthodontic mini screw, teeth, or soft tissue are designed and presented on last decade for upper molar distalization [16]. Most of these appliances can be placed on palatal soft tissue and

orthodontic mini screws are placed in palatine bone. These two-side effective appliances can be mainly considered for only first molar distalization [17].

In this study, a new appliance called Cise distalizer supported with only orthodontic mini screw for upper molar distalization is designed, produced, and tested. Cise distalizer is placed into the buccal maxillary area and can be used on one-side or two-side upper first and second molar distalization.

## 2. Materials and Methods

The appliance called Cise distalizer consists of eight main components (see Figure 1), namely, (i) a mini screw (Dentaurum, Germany), (ii) a rectangular bendable L-wire (Dentaurum, Germany), (iii) a crimple bendable wire (Dentaurum, Germany), (iv) NiTi open coil spring (Modern Orthodontics, India), (v) two screwed stoppers (Dentaurum, Germany), (vi) two T-tubes (Dentaurum, Germany), (vii) a molar tube (Dentaurum, Germany), and (viii) lingual retainer composite with its bonding agent (3M Unitek, USA).

Three design steps of the appliance are as follows:

- (a) The main structure is completed by integrating the screwed stopper to the rectangular long L-wire and the crimple bendable wire. In this step, crimple wire is crimped to the small arm of L-wire with crimple hook plier.
- (b) The open coil springs are fixed to one end of each wire. That is, the two stoppers are placed to the L-wire and the crimple wire, respectively. Similarly, the two open coils are located to the L-wire and the crimple wire, respectively.
- (c) The structure ends up adding T-tubes and a molar tube to the wires. Briefly, it means that after molar tube is bonded on the upper first molar, two T-tubes are inserted on L-wire. Then, the L-wire is transformed into U-wire. Finally, the appliance is bonded to the head of mini screw. The appliance without activation is given in Figure 2.

Shortly, the appliance has four active and two passive parts. Active parts are two open coils and two screw activated stoppers. Passive parts are two rectangular wire ends, one of which attaches to orthodontic mini screw and the other one is placed into molar tube. Orthodontic mini screw can be inserted either between upper canine and first premolar region (right side) or between upper first premolar and second premolar region (left side). These two different mini screw cases are presented in Figure 3. It is noted that the region can be chosen according to characteristics of patient's dental arches.

For strain gage measurement, two unidirectional GFLA-3-350-50 strain gages (gage factor:  $2.12 \pm 0.01$ ; gage resistance:  $350 \pm 1 \Omega$ ) are used with an adhesive, namely, P-2 (TML, Tokyo Sokki Kenkyujo Co., Ltd., Japan). Figure 3 shows location of the mounted strain gages on the critical points of the model. The critical point is the location of distal surface of upper first permanent molar teeth. When the appliance is

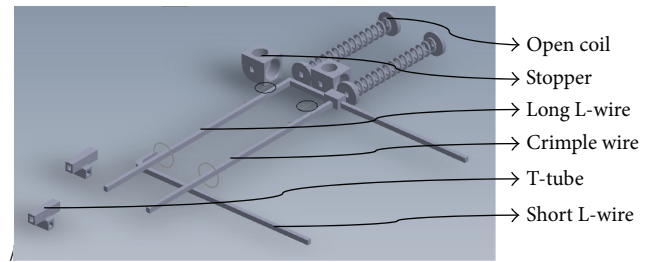


FIGURE 1: Components of Cise distalizer.

activated with the sliding of two stoppers, strain gage measurement is obtained. The two-channel strain measurements are completed using a microprocessor-based data acquisition system, namely, SoMat™ eDAQlite, and SoMat TCE software (HBM, Inc., USA).

## 3. Results and Discussions

Results of the strain measurement are given in Figure 4. The results obviously show that one of the open coils produces approximately 300 gr distalization force. Cise distalizer can provide totally 600 gr distalization force. This range of force level is acceptable for distalization of upper first and second molar teeth to eliminate unwanted tooth movement. In other words, it is possible to provide optimum force level while using Cise distalizer.

One can also say that (1) loading of appliance provides acceptable deflection distal surface of upper first molar and (2) strain field at mini screw with upper first premolar and second premolar region (left side) is higher than that at mini screw with upper canine and first premolar region. In other words, the design at left side reflects more deflection than that of the other side.

Corresponding to the advantages of the Cise distalizer for clinical applications, one may discuss three main points. First, dental malocclusion caused by dental crowding shows different molar relationships. If the mandibular arch crowding is mild and the molar relationship is class II and the sagittal, transversal, and vertical skeletal relationships between the maxillary and mandibular bones are normal, most possible cause of the severe upper arch crowding is the mesial movements of upper molars [18]. According to the acceptable force versus movement control, Cise distalizer can provide molar distalization without poor aesthetics because anchorage control can be completed by orthodontic mini screws which are more esthetic than extraoral appliances and activation of appliance is done by clinician and there is no need for patient's cooperation. Only monthly activation of Cise distalizer is suitable for providing force of optimum molar distalization. Force level of Cise distalizer can be controlled easily with the activation degree of stoppers. This force control is very important for elimination of unwanted tooth movement of high force level. It is possible to provide optimum force level while using Cise distalizer.

Second, most of the distalization appliances are placed on the palatine region with orthodontic mini screws [11, 19–21]. This type of appliances possesses hygiene problem due to

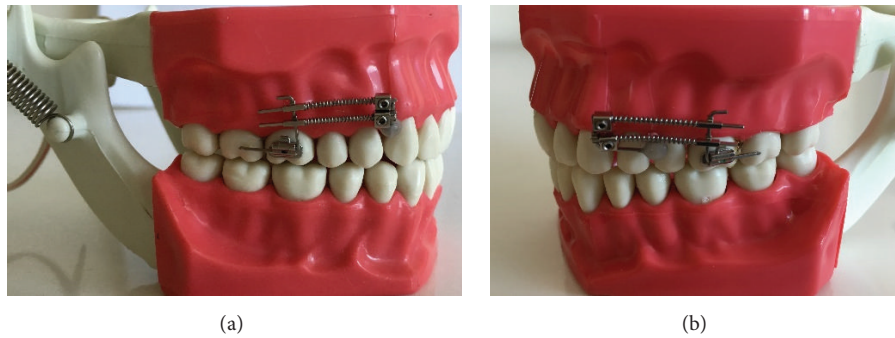

FIGURE 2: Cise distalizer on model without activation.

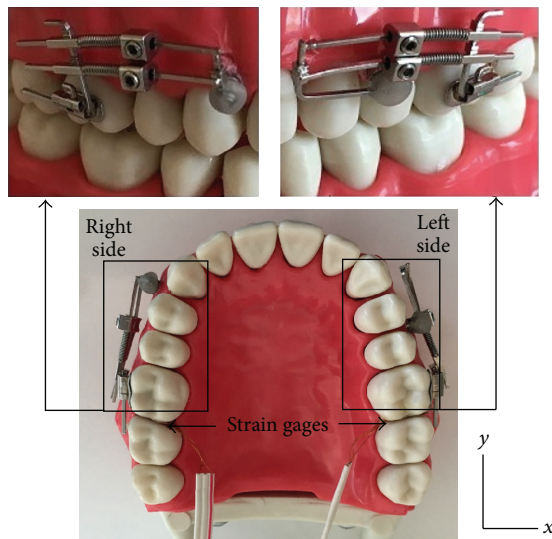


FIGURE 3: Cise distalizer and mounted strain gages on the model.

the fact that it is difficult to provide adequate plaque control under appliances. Also, there are high risks of aspiration, swallowing of piece of the appliance, and damage of the orthodontic mini screw due to trauma. In order to decrease the risk(s), Cise distalizer with its orthodontic mini screw is placed on the buccal region of maxilla [22].

Third, many distalization appliances are designed for two-side molar movement or at least need both right and left first molar attachment with welding molar bands [23, 24]. Cise distalizer can be placed on one side and molar attachment can be made with molar tube and can be produced by clinician at clinic and there is no need for study model, a technician, and a laboratory work. So Cise distalizer is more economic and useful appliance than others. Consequently, Cise distalizer is more hygienic and ergonomic than other appliances and can be easily used on one side. Anchorage of Cise distalizer is provided by an orthodontic mini screw infinite anchorage unit. This type of anchorage eliminates side effects like soft tissue irritation and unwanted tooth movement such as anterior teeth protrusion or mesial movement of premolar [3, 25]. In addition to that, mini screw can be placed in different

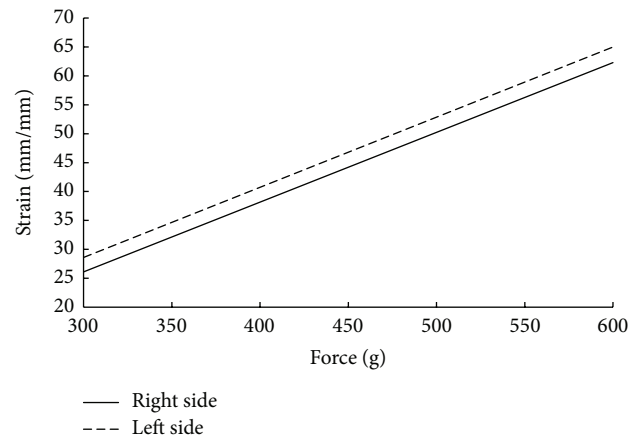


FIGURE 4: Comparison of Cise distalizer at right side and at left side under various loading.

proper area like being placed distal to canine or distal to first premolar.

#### 4. Conclusion

Cise distalizer is an economic and ergonomic distalization appliance. The new appliance introduced here can be used in clinical applications and orthodontic treatments to provide adequate and enough distalization force for upper first and second molar. In the near future, clinical results are to be carefully evaluated to improve the appliance.

#### Competing Interests

The authors declare that they have no competing interests.

#### References

- [1] A. Prakash, R. Patil, O. P. Mehta, G. Singh, and P. K. Jayaprakash, "Post distalization—anchoring molars," *Indian Journal of Dental Sciences*, vol. 5, pp. 120–121, 2013.
- [2] G. Yordanova, "Pendulum appliance—clinics and results," *International Journal of Science and Research*, vol. 3, pp. 1647–1649, 2014.
- [3] C. L. Sandifer, J. D. English, C. D. Colville, R. L. Gallerano, and S. Akyalcin, "Treatment effects of the Carrière distalizer

- using lingual arch and full fixed appliances,” *Journal of the World Federation of Orthodontists*, vol. 3, no. 2, pp. e49–e54, 2014.
- [4] T. T. Üçem, S. Yüksel, C. Okay, and A. Gülşen, “Effects of a three-dimensional bimetric maxillary distalizing arch,” *The European Journal of Orthodontics*, vol. 22, no. 3, pp. 293–298, 2000.
  - [5] D. R. Burkhardt, J. A. McNamara Jr., and T. Baccetti, “Maxillary molar distalization or mandibular enhancement: a cephalometric comparison of comprehensive orthodontic treatment including the pendulum and the Herbst appliances,” *American Journal of Orthodontics and Dentofacial Orthopedics*, vol. 123, no. 2, pp. 108–116, 2003.
  - [6] G. Oberti, C. Villegas, M. Ealo, J. C. Palacio, and T. Baccetti, “Maxillary molar distalization with the dual-force distalizer supported by mini-implants: a clinical study,” *American Journal of Orthodontics and Dentofacial Orthopedics*, vol. 135, no. 3, pp. 282.e1–282.e5, 2009.
  - [7] H. Wang, J. Feng, P. Lu, and G. Shen, “Correction of a skeletal Class II malocclusion with severe crowding by a specially designed rapid maxillary expander,” *American Journal of Orthodontics and Dentofacial Orthopedics*, vol. 147, no. 2, pp. 242–251, 2015.
  - [8] A. D. L. S. D. Lira, A. Izquierdo, S. Prado, M. Nojima, and L. Maia, “Anteroposterior dentoalveolar effects with cervical headgear and pendulum appliance: a systematic review,” *Brazilian Journal of Oral Sciences*, vol. 11, no. 4, pp. 433–439, 2012.
  - [9] E. Bolla, F. Muratore, A. Carano, and S. J. Bowman, “Evaluation of maxillary molar distalization with the distal jet: a comparison with other contemporary methods,” *The Angle Orthodontist*, vol. 72, no. 5, pp. 481–494, 2002.
  - [10] G. S. M. Kinzinger and P. R. Diedrich, “Biomechanics of a distal jet appliance: theoretical considerations and in vitro analysis of force systems,” *The Angle Orthodontist*, vol. 78, no. 4, pp. 676–681, 2008.
  - [11] G. S. Antonarakis and S. Kiliaridis, “Maxillary molar distalization with noncompliance intramaxillary appliances in class II malocclusion: a systematic review,” *Angle Orthodontist*, vol. 78, no. 6, pp. 1133–1140, 2008.
  - [12] K.-R. Chung, S.-H. Kim, M. P. Chaffee, and G. Nelson, “Molar distalization with a partially integrated mini-implant to correct unilateral Class II malocclusion,” *American Journal of Orthodontics and Dentofacial Orthopedics*, vol. 138, no. 6, pp. 810–819, 2010.
  - [13] A. Caprioglio, M. Cozzani, and M. Fontana, “Comparative evaluation of molar distalization therapy with erupted second molar: segmented versus Quad Pendulum appliance,” *Progress in Orthodontics*, vol. 15, no. 1, article 49, 2014.
  - [14] A. Sodagar, M. A. Akhoundi, A. Rafighii, and S. Arab, “Fabrication and evaluation of a noncompliant molar distalizing appliance: bonded molar distalizer,” *Journal of Dentistry*, vol. 8, no. 3, pp. 107–116, 2011.
  - [15] J. Hourfar, B. Ludwig, and G. Kanavakis, “An active, skeletally anchored transpalatal appliance for derotation, distalization and vertical control of maxillary first molars,” *Journal of Orthodontics*, vol. 41, supplement 1, pp. S24–S32, 2014.
  - [16] A. S. Burhan, “Combined treatment with headgear and the frog appliance for maxillary molar distalization: a randomized controlled trial,” *Korean Journal of Orthodontics*, vol. 43, no. 2, pp. 101–109, 2013.
  - [17] P. Chandra, S. Agarwal, and D. Singh, “Intra oral molar distalization—a review,” *Journal of Dentofacial Sciences*, vol. 1, no. 1, pp. 15–18, 2012.
  - [18] W. Al-Faleh, “Intraoral maxillary molar distalization: a review,” *Pakistan Oral and Dental Journal*, vol. 29, pp. 301–310, 2009.
  - [19] A. Goyal, H. Jyothikiran, V. Patel, and B. Shivalinga, “Mini-implant supported molar distalization,” *Journal of Dental Implants*, vol. 2, no. 2, pp. 136–140, 2012.
  - [20] A. Caprioglio, M. Fontana, E. Longoni, and M. Cozzani, “Long-term evaluation of the molar movements following Pendulum and fixed appliances,” *The Angle Orthodontist*, vol. 83, no. 3, pp. 447–454, 2013.
  - [21] B. Wilmes, V. Katyal, and D. Drescher, “Mini-implant-borne Pendulum B appliance for maxillary molar distalisation: design and clinical procedure,” *Australian Orthodontic Journal*, vol. 30, no. 2, pp. 230–239, 2014.
  - [22] T. E. Bechtold, J.-W. Kim, T.-H. Choi, Y.-C. Park, and K.-J. Lee, “Distalization pattern of the maxillary arch depending on the number of orthodontic miniscrews,” *The Angle Orthodontist*, vol. 83, no. 2, pp. 266–273, 2013.
  - [23] A. G. Acar, S. Gürsoy, and M. Dinçer, “Molar distalization with a pendulum appliance K-loop combination,” *The European Journal of Orthodontics*, vol. 32, no. 4, pp. 459–465, 2010.
  - [24] A. Mavropoulos, K. Sayinsu, F. Allaf, S. Kiliaridis, M. A. Papadopoulos, and A. O. Keles, “Noncompliance unilateral maxillary molar distalization: a three-dimensional tooth movement analysis,” *The Angle Orthodontist*, vol. 76, no. 3, pp. 382–387, 2006.
  - [25] M. Matei, K. Earar, I. Grigorescu, and I. Zetu, “Simplified systems of distalization—the frog appliance,” *Annals of the University Dunarea de Jos of Galati*, vol. 17, no. 1, pp. 77–80, 2014.