



## Case report

# Minor stroke with bilateral acute infarctions and combined vascular anomalies: A complex case report



Fabrizio Giammello<sup>a,\*</sup>, Cristina Dell'Aera<sup>a</sup>, Francesco Grillo<sup>a</sup>, Masina Cotroneo<sup>a</sup>, Carmela Casella<sup>a</sup>, Paolino La Spina<sup>a</sup>, Carmelo T. Currò<sup>a</sup>, Mariano Velo<sup>b</sup>, Francesca Granata<sup>b</sup>, Antonio Toscano<sup>a</sup>, Rosa F. Musolino<sup>a</sup>, Maria C. Fazio<sup>a</sup>

<sup>a</sup> Department of Clinical and Experimental Medicine, University of Messina, Messina, Italy

<sup>b</sup> Neuroradiology Unit, Department of Biomedical, Dental Science and Morphological and Functional Images, University of Messina, Messina, Italy

## ARTICLE INFO

## Keywords:

Neurology  
Immune disorder  
Medical imaging  
Radiology  
Diagnostics  
ESUS  
Combination of vascular anomalies  
Minor stroke with bilateral acute infarctions  
COCA  
aRSA  
Left OA

## ABSTRACT

We report the case of a patient with bilateral acute ischemic lesions (AIS) in middle cerebral artery (MCA) territory associated with an extremely rare combination of anomalies of the aortic arch and the left internal carotid artery (ICA). The diagnosis deposited for bilateral minor embolic stroke of undetermined source (ESUS), inpatient with patent foramen ovale (PFO) and positive antiphospholipid (aPL) test. To our knowledge, this is the first description of a patient with this rare combination of vascular anomalies.

## 1. Introduction

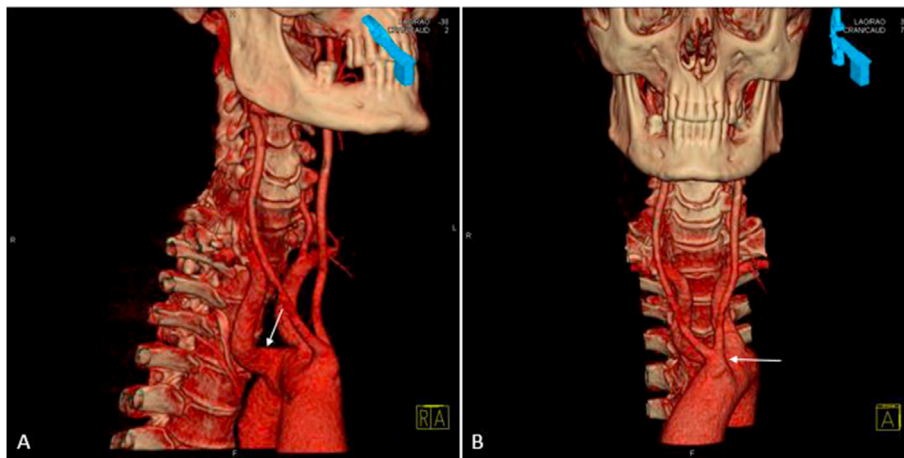
Aortic arch anomalies (AAA) are common congenital aberrations, which usually do not manifest any evident clinical symptoms. Common origin of the carotid arteries (COCA) is a normal aortic arch variant found in about 11% of whites. An aberrant right subclavian artery (aRSA) as the most distal branch of the aortic arch is unusual, representing around 1% of all arch vessel anomalies. AAA have an embryological origin for their development. An aRSA allegedly arise from the stoppage of the embryonic right arch proximal to the seventh cervical intersegmental artery. The high prevalence of these abnormalities makes them significant every time endovascular or open repair of the arch vessels should be performed [1]. The embryology of abnormal origin of the occipital artery (OA) is unclear. Lasjaunias et al. theorized that the horizontal and distal ascending portion of the OA is a residue of the proatlantal intersegmental artery. Thus, the OA arising from the internal carotid artery (ICA) could be a persistent proatlantal intersegmental artery [2].

## 2. Case report

We report the case of S.C., a 50-year-old man with transient ischemic attack symptoms (right facial and arm weakness, associated with right-sided paresthesias), lasted for about 30 min and then completely resolved. He was admitted to Stroke Unit of University Hospital "G. Martino" in August 2019. He had a history of beta thalassemia trait, smoking and gastroesophageal reflux disease (GERD). Clinical picture and neurological examination at admissions were unremarkable. The hospital stay was uneventful. Laboratory routine tests were normal, with the exception of microcytic hypochromic anemia and mildly low fibrinogen levels (178 mg/dl, normal range 200–400); acute phase reactants, homocysteinemia, essay for autoantibodies and thyroid function tests were normal, with the exception of antiphospholipid antibodies (IgM 47.30 U/ml, normal range <25.0), serum TSH (6.880 µIU/ml, n.r. 0.270–4.200), folic acid (1.27 ng/ml, n.r. 3.21–20.00), lactic acid (26 mg/dl, n.r. 3.0–12.0) and alterations in hemoglobin pattern (Hb A 93.1% n.r. 96.2–98.5; Hb A2 5.5 % n.r. 1.50–3.60). Screening for inherited

\* Corresponding author.

E-mail address: [fabrizio.giammello@gmail.com](mailto:fabrizio.giammello@gmail.com) (F. Giammello).



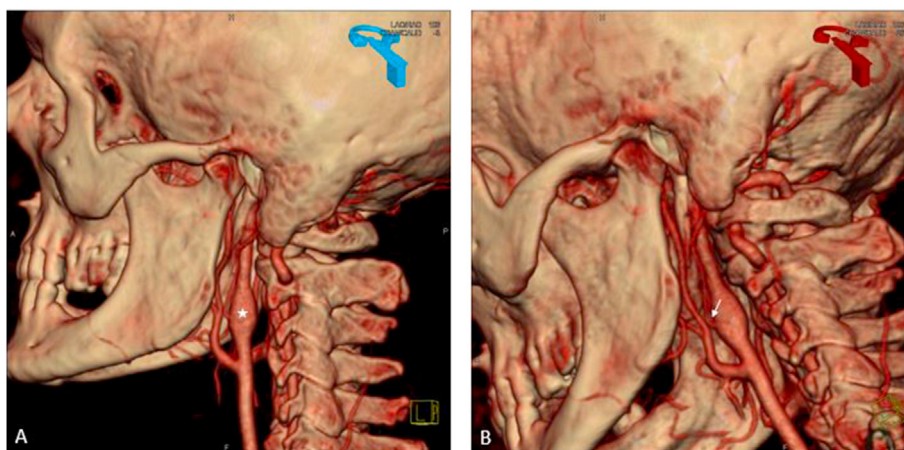
**Figure 1.** Aortic arch anomalies. Computed Tomography Angiography with three-dimensional reconstruction (3D-CTA) demonstrates (A) the right subclavian artery (white arrow) originating directly from the middle part of the aortic arch and (B) the left and right common carotid arteries sharing a common origin (white arrow).

thrombophilia did not show meaningful alterations. At 6 weeks fibrinogen levels, serum TSH, folic and lactic acid were within normal range; the results of autoimmune diagnostic tests were inconclusive even after a repeat testing. The computed tomography angiography (CTA) and magnetic resonance imaging (MRI) findings showed bilateral acute ischemic lesions (AIS) in middle cerebral artery (MCA) territories, associated with an extremely rare combination of anomalies of aortic arch and left internal carotid artery (ICA): first, the right subclavian artery originates directly from the middle part of the aortic arch (Figure 1A); second, the left and right common carotid arteries share a common origin (Figure 1B); third, fusiform dilatation of left ICA (Figure 2A); fourth, left occipital artery (OA) arises from the very same dilatation of left ICA (Figure 2B). In addition, brain MRI showed an incidental finding (hyperintense lesion on long TR sequences in the left precentral gyrus, with mild swelling of the frontal lobe). A complementary MRI with gadolinium and magnetic resonance spectroscopy (MRS) showed no contrast-enhancement and normal ratio between total choline and N-acetyl aspartate (tCho/NAA ratio), supporting the diagnosis of low-grade glioma. Transthoracic Ecocardiography (TTE) detected right-to-left shunt both at rest and during the Valsalva maneuver, showing a patent foramen ovale (PFO) tunnel-like 15 mm in length and 4 mm of maximum amplitude, annuloaortic ectasia (49 mm) and ascending aortic ectasia (40 mm). Ultrasonography (US) of the legs and abdominal veins showed absence of covert deep venous thrombi. Thus, the patient was dismissed with diagnosis of bilateral minor embolic stroke of undetermined source

(ESUS). During hospitalization we started acetylsalicylic acid at a dose of 300 mg daily. Informed consent was obtained from the patient.

### 3. Discussion

The diagnostic findings revealed the presence of PFO, positive anti-phospholipid (aPL) test and anomalies of aortic arch and left ICA. TEE identifies potentially salient abnormalities in approximately 50–75% of young patients with otherwise cryptogenic stroke. The presence of PFO is found in up to half of young adults with cryptogenic stroke but is also found in one quarter of healthy persons. Among patients with cryptogenic stroke who had a PFO, this abnormality is probably causally related to the stroke in approximately half [3]. The repeated tests for aPL antibodies did not allow to define diagnosis of Antiphospholipid Syndrome (APS), following the 2006 International consensus criteria Sydney, with positivity for aPL (IgM 159.00 U/ml, normal range <25.0) and normal levels of lupus anticoagulant (LAC), anti-cardiolipin (aCL) as well as anti-b2glycoprotein I (b2GPI) antibodies. It is proposed to distinguish high-risk triple positive APS patients from others or to categorize APS into definite (triple positive), probable (dual positive) and possible or non-APS (single positive) [4]. APS does not seem to be a constant propensity to thrombosis but, rather, a continuum of severity that may depend not only on antibody isotype and titer but also on antibody avidity and other factors such as activated protein C resistance, smoking, oral contraceptive use, serum homocysteine level, trauma or



**Figure 2.** Left internal carotid artery (LICA) anomalies. 3D-CTA demonstrates (A) fusiform dilatation of LICA (white star) and (B) left occipital artery (OA) arising from the very same dilatation of LICA (white arrow).

immobilization. The reported frequency of positive aPL results in cancer patients varies widely, from 1.4% to 74%. Furthermore, in patients with cancer, tumor cells or the immune system may contribute to produce aPL. By performing MRS, the tCho/NAA ratio is often used as a biomarker for tumor load and malignancy in gliomas. TCho/NAA ratio is significantly higher for high-grade glioma, while low-grade glioma demonstrates variable amounts of Cho elevation and NAA decrement [5]. Many patients with glioma may have an altered phospholipid metabolite profile that would affect neoplasm pathobiology. Increased risk of developing blood clots may depend on clinically significant aPL profiles. In COCA, the brachiocephalic trunk and the left carotid artery arise from a single source of the aorta. More recent studies showed an amplified occurrence of COCA with certain congenital anomalies including DiGeorge syndrome, esophageal atresia-tracheoesophageal fistula and abnormal origin of the left coronary artery from the pulmonary artery, although previously it was reported that this defect did not associate with abnormalities or adverse consequences to the patient. Typically, an aRSA has no clinical or pathological implication unless it develops symptoms, among which the most common is the so called dysphagia lusoria, due to compression of the esophagus between the trachea and the artery [1]. Variation of the branches of the external carotid artery (ECA) is well known, but it is extremely rare for the OA to arise from the ICA. Furthermore, the right OA more commonly arises from the ICA than the left OA according to previous studies [2]. Even though thalassemia minor was associated with hypercoagulable status through laboratory test, as reported by Labib et al [6], different studies showed a reduced risk of cerebral and cardiovascular events in these patients. This protective effect was explained by low pressure value, low blood viscosity and low cholesterol levels [7]. In literature, we did not find data about venous thrombosis and thalassemia minor, suggesting it as a cause of paradoxical embolism. To our knowledge, no association has been reported between thalassemia minor and large vessel anomalies. Hence, we considered these findings unrelated.

#### 4. Conclusions

With regard to the etiology of our patient symptoms, the presence of bilateral AIS in MCA territory in a patient with COCA is highly suggestive for the possible causal role of PFO, in absence of major cardiac embolic source as risk factor. Not every positive aPL test is clinically significant. Thus, detection of aPL on two occasions at least 12 weeks apart, may help in conditions in which the aPL are transient. We do not feel that the anatomic variant itself caused his symptomatology, although there are reports recording that tortuosity of the cerebral arteries can lead to cerebral hyperperfusion and/or embolic events [8]. The remarkable point is the presence of these anomalies being together. To our awareness, this is the first report of a patient in which a rare combination of anomalies of the aortic arch is associated with extremely rare presentation of left OA arising from homolateral ICA.

#### Declarations

##### Author contribution statement

All authors listed have significantly contributed to the investigation, development and writing of this article.

##### Funding statement

This research did not receive any specific grant from funding agencies in the public, commercial, or not-for-profit sectors.

##### Competing interest statement

The authors declare no conflict of interest.

##### Additional information

No additional information is available for this paper.

#### Acknowledgements

We thank the patient and her family for their kind cooperation.

#### References

- [1] S. Chahwan, M.T. Miller, K.A. Kim, M. Mantell, L. Kirksey, Aberrant right subclavian artery associated with a common origin of carotid arteries, *Ann. Vasc. Surg.* 20 (6) (2006 Nov) 809–812. Epub 2006 May 31.
- [2] T. Iwai, T. Izumi, T. Inoue, J. Maegawa, N. Fuwa, K. Mitsudo, I. Tohnai, Occipital artery arising from the anterior aspect of the internal carotid artery identified by three-dimensional computed tomography angiography, *Iran. J. Radiol.* 9 (2) (2012) 103–105.
- [3] D.M. Kent, R. Ruthazer, C. Weimar, et al., An index to identify stroke-related vs incidental patent foramen ovale in cryptogenic stroke, *Neurology* 81 (2013) 619–625.
- [4] M.G. Tektonidou, L. Andreoli, M. Limper, Z. Amoura, R. Cervera, N. Costedoat-Chalumeau, M.J. Cuadrado, T. Dörner, R. Ferrer-Oliveras, L. Hambly, M.A. Khamashta, J. King, F. Marchionni, P.L. Meroni, M. Mosca, V. Pengo, L. Raio, G. Ruiz-Irastorza, Y. Shoenfeld, L. Stojanovich, E. Svenungsson, D. Wahl, A. Tincani, M.M. Ward, EULAR recommendations for the management of antiphospholipid syndrome in adults, *Ann. Rheum. Dis.* 78 (2019) 1296–1304.
- [5] E. Kousi, I. Tsougos, E. Tsolaki, K.N. Fountas, K. Theodorou, I. Fezoulidis, E. Kapsalaki, C. Kappas, Spectroscopic evaluation of glioma grading at 3T: the combined role of short and long TE, *Sci. World J.* 2012 (2012) 546171.
- [6] H.A. Labib, R.L. Etewa, H. Atia, The hypercoagulable status in common Mediterranean  $\beta$ -thalassaemia mutations trait, *Int. J. Lit. Humanit.* 37 (2015) 326–333.
- [7] M. Karimi, A.B. Haghighi, M. Yazdani, et al., Is  $\beta$ -thalassaemia trait a protective factor Against ischemic cerebrovascular accidents? *J. Stroke Cerebrovasc. Dis.* 17 (2008) 79–81.
- [8] P.H. Lin, A.B. Lumsden, Carotid kinks and coils, in: C.B. Ernst, J.C. Stanley (Eds.), *Current Therapy in Vascular Surgery*, Mosby, St. Louis, 2001, pp. 114–117.