

## ORIGINAL ARTICLE

# Clinical characteristics of prenatally diagnosed persistent left superior vena cava in low-risk pregnancies

Eun-Young Choi<sup>1\*</sup>, Soo-Kyung Hong<sup>2</sup> and Na-Yeong Jeong<sup>2</sup>

<sup>1</sup>Department of Pediatrics, Gangnam Medical Center, CHA University, Seoul, Korea

<sup>2</sup>Division of Fetal Ultrasound, Gangnam Medical Center, CHA University, Seoul, Korea

\*Correspondence to: Eun-Young Choi. E-mail: symptom@medicus.co.kr, ped002@cha.ac.kr

## ABSTRACT

**Objective** To determine the incidence and clinical characteristics of persistent left superior vena cava (PLSVC) among low-risk pregnancies. We have also compared electrocardiography (ECG) parameters of infants with PLSVC with those of normal controls.

**Method** At our institute, fetal echocardiogram is routinely performed in the midtrimester. We retrospectively reviewed the records of prenatally diagnosed PLSVC cases from 2010 to 2014. The ECG findings in infants with isolated PLSVC were compared with those of age-matched controls.

**Results** Sixty-five cases of fetal PLSVC were detected during the study period. It represents 0.36% (65/18 188) of all fetal echocardiographic examinations during the study period. Twenty cases (30.8%) had other cardiac anomalies, seven cases (10.8%) were associated with extracardiac anomalies, and four cases (6.2%) had both cardiac and extracardiac anomalies, whereas in 34 cases (52.3%), the anomaly was isolated. There were no significant differences in ECG parameters between neonates with PLSVC and normal controls.

**Conclusion** Detection of PLSVC should prompt careful search for associated anomalies. Isolated PLSVC is a benign vascular anomaly and the outcomes are excellent. © 2016 The Authors. *Prenatal Diagnosis* published by John Wiley & Sons, Ltd.

Funding sources: None

Conflicts of interest: None declared

## INTRODUCTION

Persistent left superior vena cava (PLSVC) is the most common congenital venous anomaly, and it is observed in 0.5 to 2% of the general population<sup>1</sup> and 0.7 to 0.9% of the fetal population.<sup>2–4</sup> In the early embryonic period, the right and left anterior cardinal veins constitute the main venous drainage of the cephalic portion, but the development of the left innominate vein and the regression of the proximal part of the left cardinal vein cause a usual pattern of right superior vena cava drainage, whereas the left cardinal vein becomes the ligament of Marshall. A few series of prenatally diagnosed PLSVC have been published in the literature,<sup>2–6</sup> mostly from high-risk populations referred for fetal echocardiography. Therefore, little is known about the significance of isolated PLSVC and its prevalence in a low-risk population. Patients with PLSVC are usually asymptomatic, so the anomaly is often found unexpectedly during central venous catheterization or pacemaker implantation. Therefore, its incidence is unclear. PLSVC can be reliably diagnosed at prenatal screening echocardiography; therefore, we have evaluated the true incidence of PLSVC in a large cohort. Moreover, because

PLSVC can be associated with cardiac arrhythmias,<sup>7–9</sup> we have also compared the electrocardiogram (ECG) findings of infants with PLSVC with those of normal controls.

## METHODS

Between January 2010 and December 2014, 17 401 fetal echocardiographic examinations were performed at our institution. At our institute, fetal echocardiogram is routinely performed in the midtrimester in most of all pregnancies. Of the echocardiogram we have performed, we estimate that 1.3% women were referred, following the suspicion of anomalies at an outside institution. An average of 3483 pregnant women delivered each year at our institution during the study period; the hospital has neonatal intensive care unit capability, but does not provide neonatal surgery, so most of the cases with cardiac anomalies or extracardiac anomalies were referred to a tertiary care center.

All cases of PLSVC were retrospectively retrieved from our fetal echocardiographic database. We reviewed their medical records, ultrasound video recordings, and still frames of fetal

echocardiography and obstetrical ultrasound to determine associated conditions and outcome. To confirm the prenatal findings, neonatal echocardiography was obtained only in 27 cases (41.5%).

During the study period, fetal echocardiography was carried out by a segmental approach using standardized anatomical planes incorporating pulsed-wave Doppler imaging.<sup>10–12</sup> All fetal echocardiographic examinations were performed using Prosound  $\alpha$ -10 (Hitachi Aloca Medical, Ltd., Tokyo, Japan) or Prosound F75 (Hitachi Aloca Medical, Ltd., Tokyo, Japan). Gestational ages at fetal echocardiography, maternal age, associated cardiac and extracardiac anomalies, chromosomal anomaly, and specific perinatal problems were recorded.

Infants with isolated PLSVC and ECGs performed within 1 week of delivery were categorized as the PLSVC group ( $n=24$ ). The same numbers of ECG recordings were obtained from our ECG database for age-matched subjects (normal controls). We examined the medical records and echocardiography images of both groups. Cases with heart anomalies, except for small atrial septal defect ( $<3$  mm) or small patent ductus arteriosus ( $<2$  mm), were excluded from the PLSVC or control group.

Statistical analysis was performed using independent sample tests. All values are given as mean  $\pm$  standard deviation, and  $p < 0.05$  was considered significant.

CHA Gangnam Medical Center Institutional Review Board approved this study and waived the requirement for informed consent (GCI-15-33).

## RESULTS

Sixty-five cases of fetal PLSVC were detected during the study period out of a total of 18 188 fetuses evaluated (including 1171 twin pregnancies and eight triplet pregnancies), representing 0.36% (65/18 188) of all fetal echocardiographic examinations performed in the study period. All 65 cases had a normal right superior vena cava and had an abnormal three-vessel view. However, only a few cases had a markedly enlarged coronary sinus (Figure 1). The neonatal confirmation of the prenatal sonographic findings was obtained in 27 cases (seven cases in PLSVC with cardiac or extracardiac anomalies and 22 cases in isolated PLSVC).

A total of 31 fetuses (47.7%) had associated anomalies: Twenty fetuses (30.8%, 20/65) had associated congenital heart defects (CHDs), seven fetuses (10.8%, 7/65) had extracardiac anomalies, and four fetuses (6.2%, 4/65) had both CHD and extracardiac anomalies. The data of the fetuses with associated anomalies and outcome are shown in Table 1. A wide spectrum of CHD was observed. The most frequently associated cardiac anomaly was ventricular septal defect ( $n=9$ ), whereas ten cases had conotruncal anomalies. Interestingly, in our series, there was no case of heterotaxy syndrome combined with

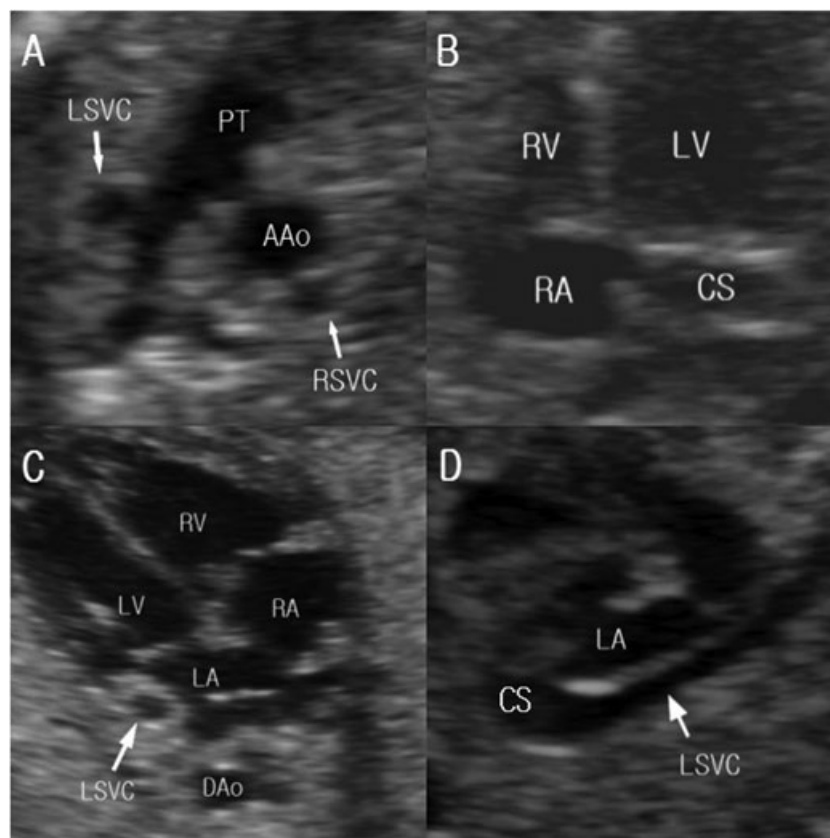


Figure 1 Abnormal three-vessel view showing the persistent left superior vena cava (LSVC) to the left of the pulmonary trunk. (A) A markedly enlarged coronary sinus in the caudal four-chamber view was observed in only 14 cases. (B) Prominent LSV near the left atrium also observed in 47 cases. (C) Oblique parasagittal view showing the drainage of the LSV into the coronary sinus. (D) AAO, ascending aorta; RSVC, right superior vena cava; LV, left ventricle; RV, right ventricle; RA, right atrium

Table 1 Characteristics of cases with persistent left superior vena cava and associated abnormalities

Case	MA (years)	GAD (weeks)	CHD	Extracardiac abnormality	RSVC (mm)	LSVC (mm)	R/L	Chromosomal abnormality	Outcome
1	35	21	AVSD	Polydactyly of both hands	2.4	2.2	1.09	N/A	Refer to tertiary center
2	36	23	Small VSD		3.1	2.2	1.41	46OO 22psk+	Refer to tertiary center
3	36	20	DORV with TGA, dextrocardia		2.4	3.0	0.80	46OO	Termination of pregnancy
4	36	19		Syndactyly of both hands	2.7	2.2	1.23	N/A	Refer to tertiary center
5	32	22	AVSD		2.0	3.2	0.63	N/A	Refer to tertiary center
6	37	22	Moderate sized ASD <sup>a</sup>		3.0	2.1	1.43	N/A	Well
7	38	22	Interruption of aorta, VSD		2.0	2.5	0.80	N/A	Refer to tertiary center
8	27	16	CoA, aortic valvular stenosis		1.7	1.3	1.31	N/A	Transfer after birth
9	28	21	DORV with TGA		2.3	2.6	0.88	46OO	Refer to tertiary center
10	32	22	TOF, r/o pulmonary atresia		2.0	1.8	1.11	N/A	Refer to tertiary center
11	37	21	DORV, CoA, aortic valvular stenosis		1.9	2.2	0.86	46OO	Refer to tertiary center
12	27	19	TOF		2.0	1.4	1.43	N/A	Refer to tertiary center
13	30	21		Duplication of right kidney	2.7	2.5	1.08	N/A	Refer to tertiary center
14	34	22		Single UA	2.1	1.8	1.17	46OO	Refer to tertiary center
15	33	21	TGA		2.3	2.3	1.00	46OO	Refer to tertiary center
16	35	23		Single UA	4.4	3.8	1.32	N/A	Well
17	37	24		Single UA	2.6	2.5	1.04	N/A	Well
18	32	23		Persistent right umbilical vein	2.6	2.0	1.30	N/A	Well
19	36	22		Polydactyly of left foot	2.5	2.4	1.04	N/A	Refer to tertiary center
20	30	22	VSD		2.2	2.2	1.00	46OO	Refer to tertiary center
21	30	23	DORV, PS		1.7	1.4	1.21	46OO	Operation after birth
22	30	21	Tricuspid atresia, VSD, r/o truncus arteriosus		3.2	2.8	1.14	46OO	Refer to tertiary center
23	33	24	VSD	Syndactyly, polydactyly	3.4	3.4	1.00	46OO	Refer to tertiary center
24	25	26	HLHS, muscular VSD		3.1	3.0	1.03	46OO	Refer to tertiary center
25	32	20	Unbalanced AVSD	Single UA, hydrops fetalis	1.9	2.2	0.86	45X	Termination of pregnancy
26	35	20	Large PDA <sup>a</sup>		2.1	1.9	1.11	N/A	Operation after birth
27	32	22	VSD, right aortic arch		2.2	2.3	0.96	46OO	Operation after birth
28	34	21	TOF		3.0	3.3	0.91	46OO	Refer to tertiary center

(Continues)

Table 2 (Continued)

Case	MA (years)	GAD (weeks)	CHD	Extracardiac abnormality	RSVC (mm)	LSVC (mm)	R/L	Chromosomal abnormality	Outcome
29	34	20	TGA with VSD, severe PS		2.5	2.5	1.00	46OO	Refer to tertiary center
30	31	21	Retroaortic innominate vein		2.4	2.3	1.04	46OO	Refer to tertiary center
31	36	21	VSD	Cleft lip and palate, r/o Dandy-Walker syndrome	2.7	2.6	1.04	46OO	Refer to tertiary center

MA, maternal age; GAD, gestational age at diagnosis; CHD, congenital heart defects; RSVC, right superior vena cava; LSVC, left superior vena cava; R/L, right to left SVC ratio; AVSD, atrioventricular septal defect; VSD, ventricular septal defect; DORV, double outlet right ventricle; TGA, transposition of great arteries, CoA, coarctation of aorta; TOF, tetralogy of Fallot; UA, umbilical artery; PS, pulmonary stenosis; HLHS, hypoplastic left heart syndrome.

<sup>a</sup>Postnatal diagnosis.

PLSVC. The most frequent extracardiac anomaly was single umbilical artery ( $n=4$ ), followed by polydactyly ( $n=3$ ). We performed fetal karyotyping in about 54.8% cases (17/31) with associated CHD or extracardiac anomalies; a significant chromosomal abnormality was detected in only one case (45, XO).

In 34 cases, the PLSVC was isolated, that is, not associated with other cardiac or extracardiac anomalies. Fetal karyotyping was performed in 23.5% (8/34) of them; only one case of chromosomal abnormality was detected (47, XY, +21). Among the 34 cases with isolated PLSVC, seven were delivered at another hospital: all were discharged without perinatal problems and did well. Among the 27 newborns delivered at our institution, an ECG was obtained in 24 neonates at an average age of  $3.0 \pm 1.4$  days (range 1–7). We extracted the ECG data for the same number age-matched controls from our database. The demographic data and ECG parameters of both groups are shown in Table 2. No significant differences in gestational age at birth, birth weight, P-wave axis, QRS wave axis, T-wave axis, and heart rate were observed between the two groups. There was no arrhythmia observed in either group.

## DISCUSSION

We have found that the incidence of PLSVC in a low-risk prenatal population is 0.36% and is similar to that reported by Liu *et al.* (0.5%).<sup>4</sup> Our data come from a single secondary center during the most recent 5 years. At our institute, routine antenatal fetal cardiac screening is performed in the midtrimester of pregnancy. Therefore, our data more closely reflect those of a general population than previous reports

from tertiary referral centers.<sup>2–4</sup> In recent years, the addition of the tree-vessel view at the upper mediastinum during fetal cardiac examinations has facilitated the diagnosis of PLSVC as it appears as four vessels instead of the normal three, with a supernumerary vessel to the left of the pulmonary trunk and ductus arteriosus (Figure 1).

Patients with PLSVC rarely have associated chromosomal anomalies. In our series, only two cases (3.1%, 2/65) had aneuploidies. An association between PLSVC and chromosomal defects has been previously reported in as high as 9% of cases, most commonly trisomy 18 and trisomy 21.<sup>3</sup> Some authors have advocated that fetal karyotype should be routinely performed if PLSVC is detected prenatally.<sup>4,13–15</sup> However, in our series, chromosomal abnormality was found only in two cases, one of which had associated structural anomalies. Larger studies are needed in low-risk populations like ours to establish whether isolated PLSVC should be an indication for fetal karyotyping.

Most of the fetuses in our series (36.9%), as well as those in other series, have associated cardiac defects other than chromosomal anomalies.<sup>2–4,6</sup> In addition, extracardiac defects were observed in 16.9% of our cases. These findings highlight the importance to evaluate the heart and other organs meticulously if PLSVC is detected during routine screening. PLSVC has been frequently reported in association with heterotaxy, occurring in 50 to 70% of cases.<sup>2,3</sup> We did not detect heterotaxy in any of our cases, despite the fact that Asians show a higher prevalence of heterotaxy syndrome compared with Western populations.<sup>16</sup> The reason for this unexpected finding is not clear, but it may reflect the low-risk population

Table 2 Demographic and ECG data of the PLSVC and the control groups

	PLSVC group ( $n=24$ )	Control group ( $n=24$ )	<i>p</i> -value
GA at birth (weeks)	$38.5 \pm 1.5$	$38.2 \pm 1.9$	0.07
Birth weight (g)	$2815.8 \pm 513.90$	$2960.4 \pm 586$	0.32
P wave axis	$35.1 \pm 35.5$	$41.5 \pm 37.3$	0.61
PR interval	$105.0 \pm 17.3$	$110.0 \pm 17.1$	0.68
QRS axis	$148.0 \pm 55.6$	$145.6 \pm 40.9$	0.29
T wave axis	$51.3 \pm 60.8$	$37.1 \pm 62.0$	0.78
Heart rate (bpm)	$129.1 \pm 18.0$	$139.0 \pm 16.3$	0.37

ECG, electrocardiography; bpm, beats per minute; PLSVC, persistent left superior vena cava; GA, gestational age

included in the present study. Heterotaxy is easily detected at prenatal ultrasonography, and it routinely constitutes an indication for referral for fetal echocardiography.

All neonates with isolated PLSVC did well after birth; the outcomes of those with PLSVC associated with cardiac or extracardiac anomalies are unclear because most of them were referred to a tertiary center.

Persistent left superior vena cava can be associated with anatomical and architectural abnormalities of the pacemaker and conduction tissues.<sup>8,9</sup> During the fetal development of the human heart, the left superior vena cava is normally incorporated into the coronary sinus, and its only visible remnant that persists is the oblique vein of Marshall. Both the atrioventricular (AV) node and sinus node can show persistent fetal dispersion in the central fibrous body in patients with PLSVC. The PLSVC, through its multiple anatomical and electrical communications with the atria, may generate repetitive rapid discharges with shorter activation cycle length that cause the initiation and maintenance of atrial fibrillation and sudden death.<sup>17</sup> Several recent studies have demonstrated that the ligament of Marshall, which contains the vein of Marshall, plays an important role in arrhythmogenesis through its muscle sleeves, which continue into the coronary sinus, forming an inferior interatrial pathway.<sup>1,17</sup> If the left superior vena cava persists later in life, the coronary sinus ostium becomes larger than normal,<sup>8</sup> displacing the AV node anteriorly. Clinically, sudden death in patients with PLSVC is known to occur, and the immaturity or structural displacement of their AV nodes may play a role in fatal electrical instability.<sup>9</sup> Therefore, we compared the basic ECG parameters of the PLSVC group and the control group: None of our cases showed a significant arrhythmia on the ECGs. However, the assessment within 1 week of age may be too early to observe electrophysiological change. Previously reported arrhythmia cases in patients with

PLSVC were not in infants, but in an older population.<sup>1,17</sup> Therefore, the changes over time in the electrophysiological characteristic of patients with PLSVC should be studied in the future.

This study had some limitations such as its retrospective nature. Moreover, in our series, the postnatal confirmation of PLSVC with echocardiography was obtained in only 41.5% of cases.

## CONCLUSION

The PLSVC detected in fetal life should be followed by the meticulous inspection of the fetal anatomy, as it is frequently associated with CHD and extracardiac malformations that influence the outcome. However, isolated PLSVC is a benign vascular anomaly and may not affect on survival; however, there are some concerns about arrhythmia associated with PLSVC. Therefore, we need to perform a long-term follow-up for patients with PLSVC.

## ACKNOWLEDGEMENT

We would like to thank Editage ([www.editage.co.kr](http://www.editage.co.kr)) for English language editing.

### WHAT'S ALREADY KNOWN ABOUT THIS TOPIC?

- Persistent left superior vena cava (PLSVC) can be accurately diagnosed prenatally and can be associated with cardiac and extracardiac anomalies
- The significance of PLSVC when isolated is unclear.

### WHAT DOES THIS STUDY ADD?

- We establish the incidence and clinical characteristics of PLSVC in low-risk pregnancies.
- Electrocardiographic parameters in neonates with PLSVC are similar to those of unaffected controls.

## REFERENCES

1. Sheikh AS, Mazhar S. Persistent left superior vena cava with absent right superior vena cava: review of the literature and clinical implications. *Echocardiography* 2014;31:674–9.
2. Galindo A, Gutierrez-Larraya F, Escibano D, *et al.* Clinical significance of persistent left superior vena cava diagnosed in fetal life. *Ultrasound Obstet Gynecol* 2007;30:152–61.
3. Berg C, Knuppel M, Geipel A, *et al.* Prenatal diagnosis of persistent left superior vena cava and its associated congenital anomalies. *Ultrasound Obstet Gynecol* 2006;27:274–80.
4. Du L, Xie HN, Zhu YX, *et al.* Fetal persistent left superior vena cava in cases with and without chromosomal anomalies. *Prenat Diagn* 2014; 34: 797–802.
5. Perles Z, Nir A, Gavri S, *et al.* Prevalence of persistent superior vena cava and association with congenital heart anomalies. *Am J Cardiol* 2013;112:1214–8.
6. Esmer AC, Yuksel A, Cali H, *et al.* Prenatal diagnosis of persistent left superior vena cava and its clinical significance. *Balkan Med J* 2014;31:50–4.
7. Ratliff HL, Yousufuddin M, Lieving WR, *et al.* Persistent left superior vena cava: case reports and clinical implications. *Int J Cardiol* 2006; 113: 242–6.
8. James TN. Congenital disorders of cardiac rhythm and conduction. *J Cardiovasc Electrophysiol* 1993;4:702–18.
9. Bunger PC, Neufeld DA, Moore JC, *et al.* Persistent left superior vena cava and associated structural and functional considerations. *Angiology* 1981;32:601–8.
10. Yoo SJ, Lee YH, Kim ES, *et al.* Three-vessel view of the fetal upper mediastinum: an easy means of detecting abnormalities of the ventricular outflow tracts and great arteries during obstetric screening. *Ultrasound Obstet Gynecol* 1997;9:173–82.
11. Yagel S, Cohen SM, Achiron R. Examination of the fetal heart by five short-axis views: a proposed screening method for comprehensive cardiac evaluation. *Ultrasound Obstet Gynecol* 2001;17:367–9.
12. Lee MY, Won HS. Technique of fetal echocardiography. *Obstet Gynecol Sci* 2013;56:217–26.
13. Kalache KD, Romero R, Conoscenti G, *et al.* Prenatal diagnosis of dilated coronary sinus with persistent left superior vena cava in a fetus with trisomy 18. *Prenat Diagn* 2003;23:108–10.
14. Machevin-Surugue E, David N, Verspyck E, *et al.* Dilated coronary sinus in prenatal echocardiography; identification, associations and outcome. *Prenat Diagn* 2002;22:898–902.
15. Kula S, Cevik A, Sanli C, *et al.* Persistent left superior vena cava: experience of a tertiary health-care center. *Pediatr Int* 2011; 53:066–9.
16. Kim SJ. Heterotaxy syndrome. *Korean Circ J* 2011;41:227–32.
17. James TN, Marshall TK, Edwards JE. De subitaneis mortibus. XX. Cardiac electrical instability in the presence of a left superior vena cava. *Circulation* 1976;54:689–97.