

Case report

Open Access

Quadricuspid aortic valve not discovered by transthoracic echocardiography

Magnus Dencker*¹ and Martin Stagmo²

Address: ¹Dept of Clinical Sciences, Unit of Clinical Physiology and Nuclear Medicine, University Hospital MAS, Lund University, Malmö, Sweden and ²Dept of Cardiology, University Hospital MAS, Lund University, Malmö, Sweden

Email: Magnus Dencker* - magnus.dencker@skane.se; Martin Stagmo - martin.stagmo@skane.se

* Corresponding author

Published: 07 November 2006

Received: 17 October 2006

Cardiovascular Ultrasound 2006, **4**:41 doi:10.1186/1476-7120-4-41

Accepted: 07 November 2006

This article is available from: <http://www.cardiovascularultrasound.com/content/4/1/41>

© 2006 Dencker and Stagmo; licensee BioMed Central Ltd.

This is an Open Access article distributed under the terms of the Creative Commons Attribution License (<http://creativecommons.org/licenses/by/2.0>), which permits unrestricted use, distribution, and reproduction in any medium, provided the original work is properly cited.

Abstract

Background: Quadricuspid aortic valve is a rare congenital heart defect. Several different anatomical variations of a quadricuspid aortic valve has been described and aortic regurgitation is the predominant valvular dysfunction associated with quadricuspid aortic valve.

Case presentation: A 68-year-old woman presented with almost a years history of increasing dyspnoea on exertion. The patient have had two previous transthoracic echocardiographic exams in the last six years and they had only documented moderate aortic regurgitation. Transoesophageal echocardiography displayed a rare case of quadricuspid aortic valve with three cusps of equal size and one larger cusp. The malformation was associated with severe aortic regurgitation.

Conclusion: Liberal use of transoesophageal echocardiography is often warranted if optimal display of valvular morphology is desired.

Background

Quadricuspid aortic valve is a rare congenital heart defect. It has in the past been an incidental finding at open heart surgery or at autopsy. There has in recent years been a few case report, with the increasing use of echocardiography [1-8].

Case presentation

A 68-year-old woman presented with almost a years history of increasing dyspnoea on exertion. On physical examination, her blood pressure was 200/90 mm Hg and a diastolic murmur of grade 5/6 was heard at the left sternal border. ECG displayed, sinusrhythm with high QRS-voltage and ST-T configuration consistent with left ventricular hypertrophy. Chest X ray was normal. The patient have had two previous transthoracic echocardiographic

exams in the last six years and they had only documented moderate aortic regurgitation. Transoesophageal echocardiography displayed a quadricuspid aortic valve. Three cusps were of equal size and one cusp was larger (Figure 1 in diastole and Figure 2 in systole). Planimetric evaluation of the 4 separate cusps performed on an end diastolic still frame resulted in following cusp areas (cm²): 1.4, 1.4, 1.5, and 2.2. The three equal cusps had minimal differences in cusp area whereas the larger cusp had a approximately 50% larger cusp area. In this patient the quadricuspid aortic valve malformation was associated with severe aortic regurgitation (Figure 3).

Discussion

Knowledge of the existence of quadricuspid aortic valve is not new, the first reported case dates back to 1862 [8]. The

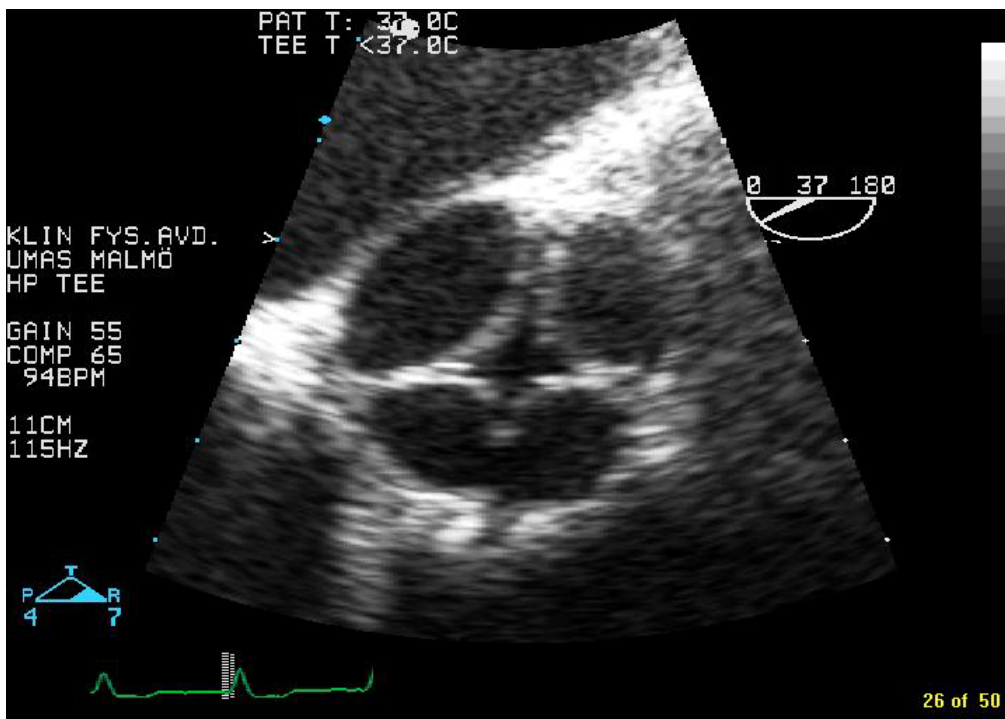


Figure 1
Transoesophageal images, in diastole, of a quadricuspid aortic valve with three cusps of equal size and one larger cusp.

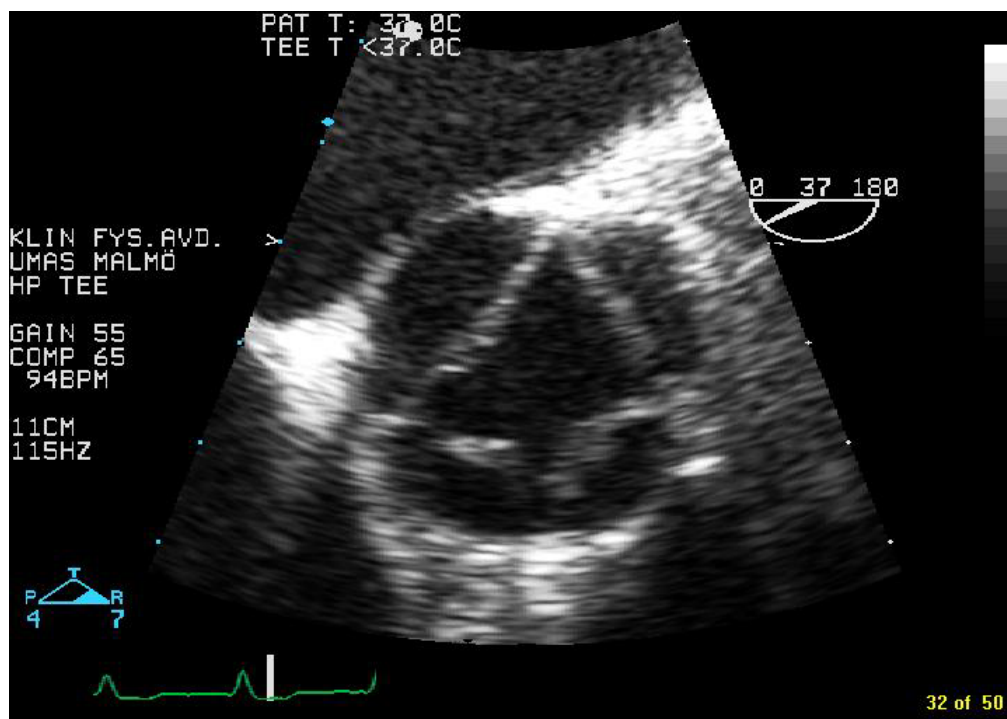


Figure 2
Transoesophageal images of a quadricuspid aortic valve in systole.

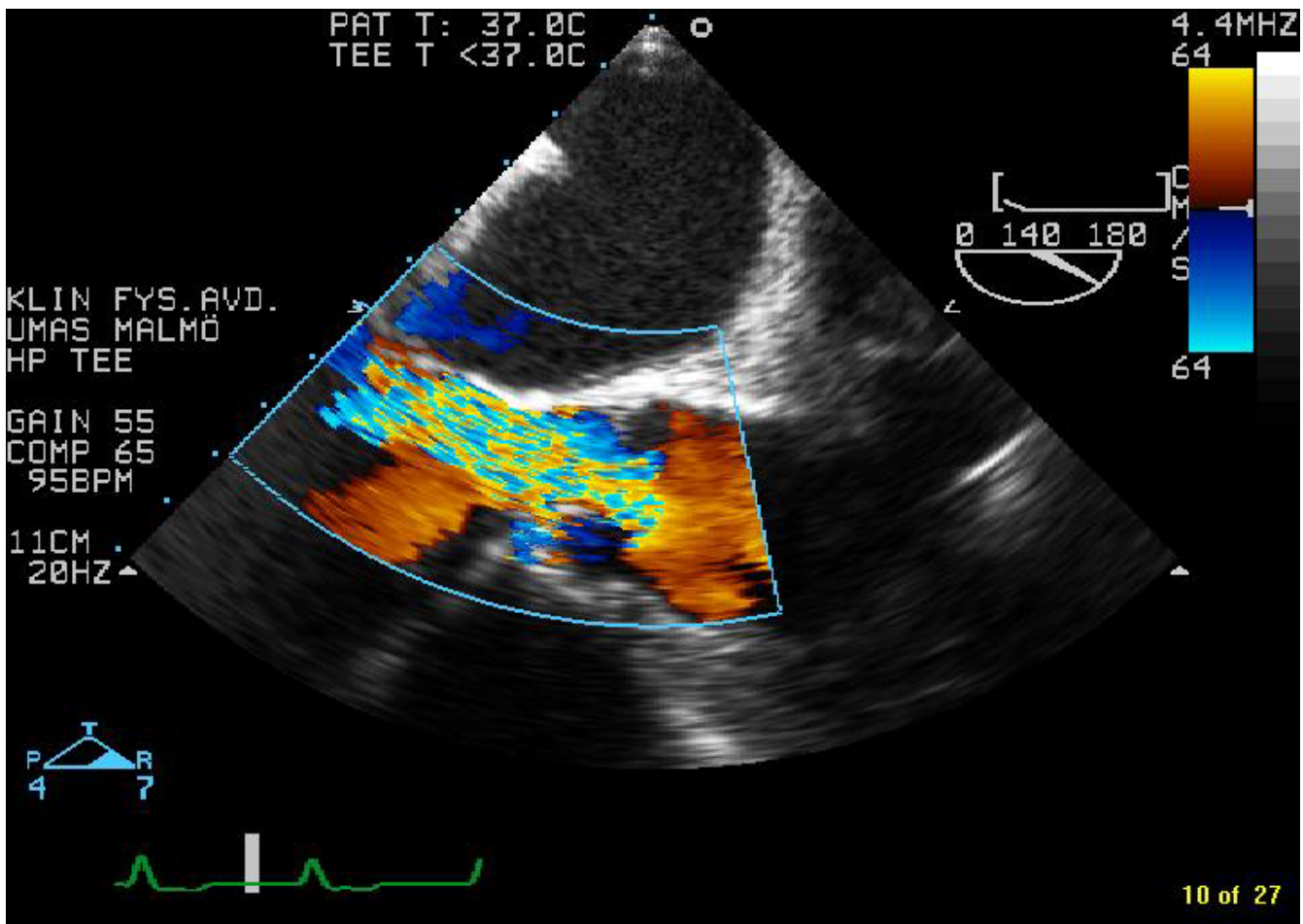


Figure 3

Transoesophageal Colour-Doppler image of severe aortic regurgitation associated with the quadricuspid aortic valve in this case.

incidence from autopsy studies matches that detected by echocardiography, around 0.01%, with a slight male predominance [9]. Hurwitz and Roberts introduced a classification nomenclature for quadricuspid aortic valve that included 7 different types named A to G [10]. The type described in this case report, with three equal cusps and one larger, is type E and extremely rare. Tutarel published the most comprehensive review of the literature concerning quadricuspid aortic valve, in 2004 [9]. This review included 186 cases of quadricuspid aortic valve and only 4 was designated type E [9]. Aortic regurgitation is the predominant valvular dysfunction and is seen in up to 75% of documented cases, on the other hand, quadricuspid aortic valve is rarely associated with aortic stenosis [9]. The most prevalent other cardiac malformation associated with quadricuspid aortic valve was anomalies of the coronary arteries, which have been reported in 10% of the cases [9]. Other malformation associated with quadricuspid aortic valve include stenosis of pulmonic valve, non-

obstructive cardiomyopathy, subaortic stenosis, and ventricular septal defect [8,9]. Also, cases of bacterial endocarditis affecting a quadricuspid aortic valve have been reported [2,3].

The prevalence of quadricuspid aortic valve is too low to study the diagnostic accuracy of transthoracic versus transoesophageal echocardiography in the detection of this malformation. A recent study by Alegret and co-workers concerning bicuspid aortic valve morphology gives an hint to what might be the case [11]. Alegret et al investigated 59 selected patients and 15 out of 32 bicuspid aortic valves were missed on transthoracic, but detected on transoesophageal echocardiography [11].

Conclusion

Noteworthy is that two consecutive transthoracic echocardiographic exams had failed to document the quadricuspid aortic valve and this is one more example that liberal use

of transoesophageal echocardiography is often warranted if optimal display of valvular morphology is desired. Also, the increasing use of transoesophageal echocardiography will probably lead to an increase in the detection of quadricuspid aortic valve. It is therefore of importance to know this anomaly and its associated defects.

Competing interests

The author(s) declare that they have no competing interests.

Authors' contributions

MD did the echocardiography of this case.

MD, MS jointly performed review of the literature and wrote the paper.

References

1. Cooke JC, Dupuche DR, Gay TJ: **Quadricuspid Aortic Valve.** *Echocardiography* 2000, **17**:699.
2. Takeda N, Ohtaki E, Kashegawa H, Tobaru T, Sumiyoshi T: **Infective endocarditis associated with quadricuspid aortic valve.** *Jpn Heart J* 2003, **44**:441-5.
3. Watanabe Y, Taketani Y, Takei Y, Tanaka K, Watanabe Y: **Complete heart block resulting from quadricuspid aortic valve penicillin-resistant pneumococcal endocarditis: a case report.** *Circ J* 2003, **67**:275-6.
4. Hwang DM, Feindel CM, Butany JW: **Quadricuspid semilunar valves: Report of 2 cases.** *Can J Cardiol* 2003, **19**:938-42.
5. Niinuma H, Yoshioka K, Ogino Y, Kawazoe K: **Three-dimensional demonstration of tetracuspid aortic valve by 16-row multi-detector-row computed tomography: comparison with transesophageal echocardiography.** *Eur J Cardiothorac Surg* 2005, **28**:326.
6. Recupero A, Pugliatti P, Rizzo F, Arrigo F, Coglitore S: **Quadricuspid aortic valve: a rare cause of aortic insufficiency diagnosed by doppler echocardiography. Report of two cases and review of the literature.** *Ital Heart J* 2005, **6**:927-30.
7. Schulze MR, Strasser RH: **Uni-, Bi-, Tri-, and Quadricuspid Aortic Valves.** *N Engl J Med* 2006, **355**(12):1262.
8. Timperley J, Milner R, Marshall JA, Gilbert TJ: **Quadricuspid aortic valves. A review.** *Clin Cardiol* 2002, **25**:548-52.
9. Tutarel O: **The quadricuspid aortic valve: A comprehensive review.** *J Heart Valve Dis* 2004, **13**:534-37.
10. Hurwitz LE, Roberts WC: **Quadricuspid semilunar valve.** *Am J Cardiol* 1973, **31**:623-6.
11. Alegret JM, Palazon O, Duran I, Vernis JM: **Aortic valve morphology definition with transthoracic combined with transesophageal echocardiography in a population with high prevalence of bicuspid aortic valve.** *Int J Cardiovasc Imaging* 2005, **21**:213-7.

Publish with **BioMed Central** and every scientist can read your work free of charge

"BioMed Central will be the most significant development for disseminating the results of biomedical research in our lifetime."

Sir Paul Nurse, Cancer Research UK

Your research papers will be:

- available free of charge to the entire biomedical community
- peer reviewed and published immediately upon acceptance
- cited in PubMed and archived on PubMed Central
- yours — you keep the copyright

Submit your manuscript here:
http://www.biomedcentral.com/info/publishing_adv.asp

