

Voiding Urosonography with Second-Generation Ultrasound Contrast Agent for Diagnosis of Vesicoureteric Reflux: First Local Pilot Study

Dafina Kuzmanovska^{1*}, Aleksandar Risteski², Margarita Kambovska², Tase Trpcevski², Emilija Sahpazova¹, Mile Petrovski³

¹University Children's Hospital, Medical Faculty, Ss Cyril and Methodius University of Skopje, Vodnjanska 17, Skopje, Republic of Macedonia; ²Private Hospital Plodnost, ASNOM 9, Bitola, Republic of Macedonia; ³University Pediatric Surgery Clinic, Medical Faculty, Ss Cyril and Methodius University of Skopje, Vodnjanska 17, Skopje, Republic of Macedonia

Abstract

Citation: Kuzmanovska D, Risteski A, Kambovska M, Trpcevski T, Sahpazova E, Petrovski M. Voiding Urosonography with Second-Generation Ultrasound Contrast Agent for Diagnosis of Vesicoureteric Reflux: First Local Pilot Study. Open Access Maced J Med Sci. 2017 Apr 15; 5(2):215-221. <https://doi.org/10.3889/oamjms.2017.055>

Keywords: Vesicoureteric reflux (VUR); paediatric urinary tract infection; Fluoroscopic voiding ureterocystography; radionuclide cystography; Contrast-enhanced voiding urosonography (ceVUS).

***Correspondence:** Dafina Kuzmanovska. University Children's Hospital, Medical Faculty, Ss Cyril and Methodius University of Skopje, Vodnjanska 17, Skopje, Republic of Macedonia. E-mail: kuzmanovska.dafina@gmail.com

Received: 20-Feb-2017; **Revised:** 23-Mar-2017; **Accepted:** 24-Mar-2017; **Online first:** 11-Apr-2017

Copyright: © 2017 Dafina Kuzmanovska, Aleksandar Risteski, Margarita Kambovska, Tase Trpcevski, Emilija Sahpazova, Mile Petrovski. This is an open-access article distributed under the terms of the Creative Commons Attribution-NonCommercial 4.0 International License (CC BY-NC 4.0).

Funding: This research did not receive any financial support.

Competing Interests: The authors have declared that no competing interests exist.

BACKGROUND: Vesicoureteric reflux (VUR) is an important association of paediatric urinary tract infection (UTI) found in 30-50% of all children presenting with first UTI. Contrast-enhanced voiding urosonography (ceVUS) has become an important radiation-free method for VUR detection in children. Its sensitivity in detecting VUR has greatly improved due to the development of the contrast-specific ultrasound techniques and the introduction of the second-generation ultrasound contrast agent, superseding the diagnostic accuracy of standard radiological procedures.

AIM: This article aimed to summarise the current literature and discuss the first local pilot study performed in our institution on detection of vesicoureteric reflux by contrast-enhanced voiding urosonography with second-generation agent (SonoVue, Bracco, Italy).

MATERIAL AND METHODS: Retrospective review of the first 31 ceVUS (24 girls, 7 boys) was presented. Age range was 2 months to 18 years (mean = 6.4 ± 4.9).

RESULTS: All examinations were well tolerated without any adverse incident. VUR was shown in 20 (64.5%) children in 32/62 (51.6) nephroureteral units (NUUs). In 18 NUUs, VUR was grade II/V, in 11 Grade III/V and in 3 grade IV/V, respectively. Urethra was shown in 19/31 children and in all boys, without pathological finding. In two girls spinning top urethra has been detected. Subsequent urodynamic studies revealed functional bladder problem in both.

CONCLUSIONS: Contrast-enhanced voiding urosonography using intravesical second generation ultrasound contrast agent could be recommend as a valid alternative diagnostic modality for detecting vesicoureteral reflux and evaluation of the distal urinary tract in children, based on its radiation-free, highly efficacious, reliable, and safe characteristics.

Introduction

Vesicoureteric reflux refers to the abnormal retrograde flow of urine from the urinary bladder back into the ureter or, even, to the kidney. Its prevalence in general population is around 1% may be higher. It is identified in 30-50% of all children presenting with a first UTI and in 27.4% of siblings of patients with documented VUR [1-5]. It is not only a developmental anomaly related to the inadequate length of the intravesical submucosal ureter but also a dysfunctional problem in which many patients have associated bladder emptying and bowel dysfunction

[6]. For decades, it has been thought to be associated with reflux nephropathy (RN) and renal scarring [7]. It is now evident that there is a sex difference in the development of RN. In most males with RN, the kidneys are congenitally abnormal suggesting and embryological abnormality. In females, it is an acquired condition, the most severe damage being sustained by recurrent urinary tract infections. It is recommended to exclude vesicoureteric reflux in high-risk patients, including those with hydronephrosis, renal scarring, or other findings that suggest high-grade vesicoureteric reflux or obstructive uropathy on renal ultrasound, and in those suffering from atypical UTI or complex clinical circumstances [8].

Three types of voiding cystography are currently used to identify VUR, namely, X-ray voiding cystourethrography (VCUG), radionuclide voiding cystography (RNC), and contrast-enhanced voiding ultrasonography (ceVUS). The voiding cystography differentiate according to the type of contrast agent installed in the bladder and the equipment required for depicting the contrast agent. All of these techniques require catheterization of the urinary bladder. Also, VCUG and RNC involve exposure to ionising radiation. Contrast-enhanced voiding ultrasonography, previously known as reflux sonography, cystosonography, and echo-enhanced cystography [9-11] does not involve ionising radiation. It involves the intravesical application of ultrasound contrast and normal saline continuous sonographic examination of the bladder, kidneys and retrovesical region during and after bladder filling and finally during voiding. Hereby the observer assesses whether microbubbles ascend to the ureters and the kidneys in a case of vesicoureteral reflux.

ceVUS has been accepted as a routine radiation-free method for diagnosis of VUR in many European centres and from the recently in our institution. We here describe our initial experience with ceVUS using the second generation US contrast agent SonoVue. We are focusing on optimisation of examination technique, observation of reflux and discussion of potential pitfalls.

Materials and Methods

This is a retrospective review of first 31 ceVUS studies, 24 girls and 7 boys. The age range was 2 months to 18 years (mean: 6.4 ± 4.9).

Technique

All US examinations were performed using a Voluson E6 high-definition scanner (GE Healthcare) equipped with HI mode and "contrast-tuned imaging", contrast-specific harmonic software dedicated to second generation contrast agents and based on maintenance of microbubbles at low acoustic pressure with subtractive imaging techniques. This software also enables colour coding of the conventional B-mode signal to improve resolution. Contrast imaging at all ages was performed with a phased-array convex 2.5–5-MHz probe prepared for this purpose. The mechanical index (MI) setting ranged between 0.08 and 0.16 in the low-MI contrast specific mode to minimise the breakage of microbubbles and to prolong the observation time.

A preliminary US study of kidneys, ureter and bladder was performed to evaluate the renal size,

parenchymal echo structure and presence of pelvicalyceal or ureteric dilatation.

A 6F or 8F infant feeding tube was inserted into the urinary bladder under aseptic conditions. The bladder was emptied and then filled slowly with saline solution from a 500 ml plastic bottle kept at body temperature [12, 13] and placed about 80 cm above the examination table. 1 ml of the second-generation US contrast agent SonoVue was injected into the bottle and gently shakes to homogenize the contents ensuring the correct mixture of contrast agent and saline solution and thus avoiding the accumulation of contrast material in the anterior aspect of the bladder which could cause an acoustic shadow that would impede the correct study of the bladder due to the difficulty of dissolving the contrast agent with its greater molecular weight. Within seconds of the start of bladder filling with the suprapubic approach, contrast material has been observed being progressively and homogeneously incorporated, bringing about generalised distention or filling the bladder. The bladder is well defined by the hypoechoic band that corresponds to the bladder wall, and the normal detrusor muscle is seen in the posterior inferior aspect.

When we observe correct filling, it coincides with clinical symptoms such as crying and flexion of the toes. At this point, we consider that we have reached the maximum capacity of the bladder, and we acquire images in the transverse and sagittal planes of the bladder and calculate its volume.

Immediately after the end of the first voiding, which was carried out with the catheter left in the bladder, the second cycle of VUS was performed with the same procedural steps except that no additional contrast agent was injected [14].

Simultaneously during filling phase and voiding through the catheter, we studied the kidneys by alternating between longitudinal and cross-sectional slices with the patient in the supine position. In the renal study, we are especially careful to detect VUR, defined as the presence of microbubbles of contrast material in the pyelocalyceal system and ureters. To grade VUR, we used the five-level grading system adapted to VUS [Darge Treger 25]: Grade I Microbubbles only in the ureter; Grade II Microbubbles in the renal pelvis; no significant renal pelvic dilatation; Grade III Microbubbles in the renal pelvis + significant renal pelvic dilatation + moderate calyceal dilatation; Grade IV Microbubbles in the renal pelvis + significant renal pelvic dilatation + significant calyceal dilatation; Grade V Microbubbles in the renal pelvis + significant renal pelvic dilatation and calyceal dilatation + loss of renal pelvis contour + dilated tortuous ureters.

To evaluate the urethra, we use a transperineal approach, placing the probe in the sagittal plane in all boys, regardless of age, and we also use a suprapubic approach in infants and a case

of urgent voiding. A trans pelvic approach was used for the study of the urethra in girls (placing the convex transducer sagittally against the suprapubic area of the abdominal wall); however, in older girls, a longitudinal interlabial approach was also used.

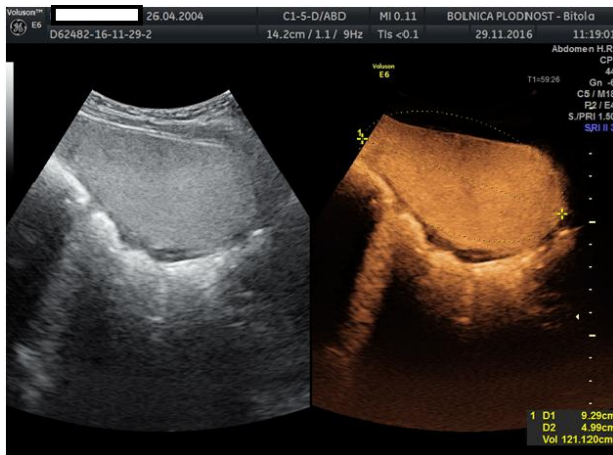


Figure 1: Contrast-enhanced voiding ultrasonography. Bladder filled with ultrasound contrast agent (B-mod "grayscale", left and B-mod + contrast specific software (right)

The urethra is considered normal when we see adequate distention and normal calibre along its entire length, with a continuous progression of contrast material toward the exterior during voiding. As reference values for distention during voiding, we use 6.4 ± 0.78 mm for the posterior urethra and 5.8 ± 0.91 mm for the anterior urethra. The difference in the calibre of the posterior and anterior urethra is between 0-2 mm. For the female urethra, we used 9.5 ± 1.1 mm as the reference value [15]. Continuous images of voiding were obtained in real time. Lastly, we evaluated residual urine and the urethra after voiding.

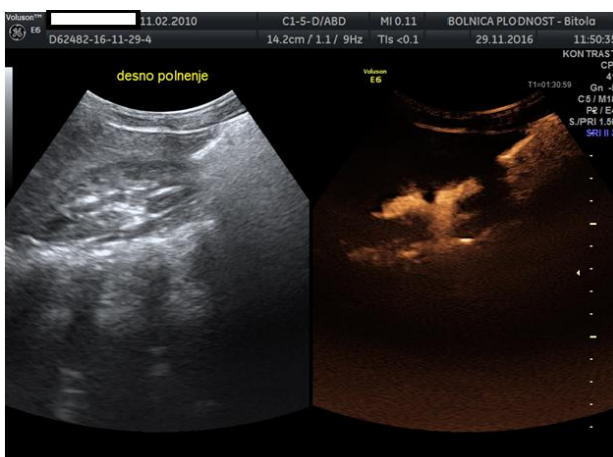


Figure 2: Ultrasound contrast agent in the collecting system of the right kidney using contrast specific software, B-mod "grayscale" (left) B-mod + contrast specific software (right)

The entire study (from the time the patient is admitted to the examination room until the end of the test) does not differ from that necessary for VCUG (25-30 min).

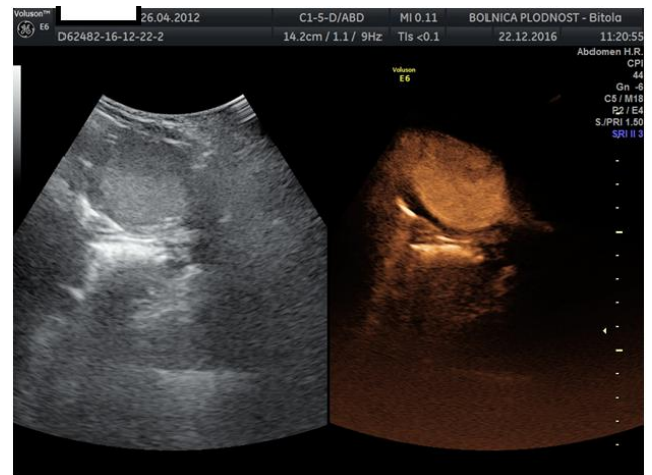


Figure 3: Spinning Top Urethra, using contrast specific software, B-mod "grayscale" (left), B-mod + contrast specific software (right)

The ceVUS study is digitally recorded and stored on a hard drive. It is obtained in all cases and available for review (Fig. 1-4). All children were placed on antibiotic prophylaxis for 3 days including the day of the examination (cefixime 8 mg/kg body weight, once a day in infants <3 months of age, and trimethoprim-sulfamethoxazole 6 mg/kg per day divided into two equal doses in children >3 months of age). Any adverse events related to a contrast agent, including acute or late allergic reactions, observed during the 6-h stay in the clinic or the next 24 h follow-up by phone reported by the patients were recorded.

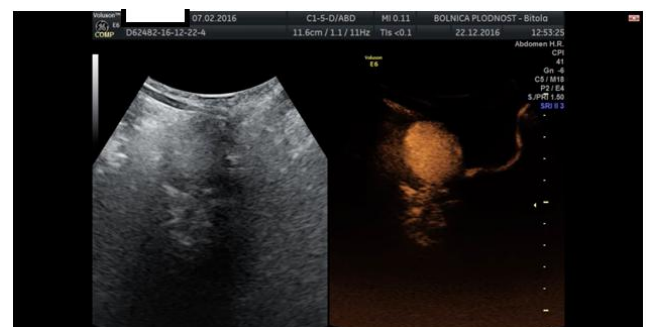


Figure 4: Normal transpubic view of the male urethra, using contrast specific software, B-mod "grayscale" (left), B-mod + contrast specific software (right)

Results

A total of 31 children with 62 nephroureteral units (NUUs) were evaluated. Indications for ceVUS were acute pyelonephritis and recurrent urinary tract infection (16 children), hydronephrosis /small kidney (5 children) and control investigation for VUR during conservative management or after endoscopic correction (10 children). All examinations were well tolerated without any adverse incident.

VUR was shown in 20 (64.5%) children in 32/62 (51.6) NUUs. It was unilateral in 8 and bilateral in 12 children. In 18 NUUs VUR was grade II/V in 11 Grade III/V and 3 grade IV/V respectively.

The urethra was shown in 19/31 children and all boys, without a pathological finding. In two girls spinning top urethra has been detected. Subsequent urodynamic studies revealed functional bladder problem in both.

Discussion

Conventional reflux imaging modalities for diagnosing VUR include voiding cystourethrography and radionuclide cystography.

Voiding cystourethrography has been the gold standard of imaging for diagnosing and grading vesicoureteric reflux. The procedure involves bladder catheterization and intravesical administration of radiographic contrast via the urinary catheter, followed by a fluoroscopic examination of the lower abdomen and pelvis. The presence of opacification of the upper urinary tract with radiographic contrast during bladder filling and voiding phases is diagnostic of vesicoureteric reflux. A standardised international system is used for grading the reflux [16]. Voiding cystourethrography involves fluoroscopy and, thus, exposure to ionising radiation. The standard mean effective dose of VUCG is approximately 0.4 to 0.9 mSv [17]. To reduce radiation exposure in both patients and operators, intermittent fluoroscopic screening and last image hold on pulsed digital fluoroscopy are employed. Nevertheless, children are more susceptible than adults to the long-term hazards of radiation, because growing tissues in children are more sensitive to radiation effects than the fully mature tissues of adults. Furthermore, children have longer life expectancy during which potential oncogenic effects of radiation may be manifested [17]. Recent literature shows a dramatic increase in medical radiation burden to children arising from radiological examinations with the expansion of medical imaging. It is postulated that medical radiation can contribute to radiation-induced cancers [17]. Hence, radiation exposure is a major drawback of VCUG. Of note, as vesicoureteric reflux is an intermittent phenomenon it can sometimes be missed by intermittent fluoroscopic screening techniques. The dilution of a small amount of radiographic contrast in the already-dilated collecting contrast and obscuration by overlying bowel shadow, also contribute to the lower sensitivity of VUCG.

Direct RNC also involves bladder catheterization and intravesical administration of radiopharmaceuticals. It carries the advantages of

continuous examination of kidneys and bladder during the filling phase, and lower gonadal radiation dose. The estimated dose to the ovary is 0.005 to 0.01 mSv, and even smaller dose to the testis [18]. In general, it has a comparable diagnostic performance with VCUG, with no significant difference in the detection rate [18, 19]. However, owing to its lower spatial resolution and impaired anatomical delineation, RNC is used for follow-up of patients with known vesicoureteric reflux [20]. It is not recommended as the first diagnostic test for vesicoureteric reflux, particularly in boys due to its limited efficacy in examining the urethral abnormality in detail. Besides, RNC also involves ionising radiation to both children and parents.

The diagnostic performance of ceVUS was only improved since the introduction of stabilised ultrasound contrast agent on the intravesical application [21] as well as the advances in the ultrasound techniques, namely, harmonic imaging [22]. Levovist (Levovist Schering, Berlin, Germany) was the first generation stabilised ultrasound contrast composed of palmitic-acid stabilised microbubbles employed in ceVUS. Until its withdrawal in 2011, it was commonly used for VUS. Since that time the second generation contrast SonoVue (Bracco Imaging, Milan, Italy) has remained as the only available ultrasound contrast agent (USCA) in the EU. SonoVue has several intrinsic advantages over Levovist [23]. SonoVue is a stabilised aqueous suspension of sulphur hexafluoride microbubbles with a phospholipid shell, which resonates by asymmetric contraction and expansion, and strongly increase the ultrasound backscatter allowing visualisation. It is not readily soluble in water, and, hence, remains stable for up to 6 hours. In an in-vitro comparative study with Levovist [5% volume] the contrast duration with SonoVue was seven times longer at a dose that was 80% lower [31]. Moreover, the contrast duration of a freshly prepared suspension of SonoVue was stable over 6 h, whereas Levovist showed a significant reduction after 30 min. In addition to the improved intrinsic property of ultrasound contrast, tissue harmonic imaging technique is now employed in ultrasound imaging. Tissue harmonic imaging is based on the phenomenon of non-linear distortion of an acoustic signal as the ultrasound wave resonates and travels through the body tissues. It improves contrast and spatial resolution and reduces artefacts compared with conventional grayscale ultrasound [24]. Together with subtraction technique, contrast-specific harmonic imaging mode further increases the conspicuity of the microbubble. It is important to set a mechanical index (MI) below 0.10 in order not to break the micro bubbles of the second-generation USCA, since with an increase of MI the rate of micro bubbles destruction increases.

The presence of microbubbles in the ureter or pelvicalyceal system, appearing as strong hyperechoic signals in contrast-harmonic mode, was

considered diagnostic of VUR. If it is present VUR is graduated in 5 grades according to Drage and Troeger comparable with radiographic classification [25].

Diagnostic performance of ceVUS in comparison with VCUG has been elaborated extensively. Darge has confirmed the diagnostic performance of ceVUS by the first-generation stabilised ultrasound contrast Levovist [26]. Using VCUG as the reference method, the sensitivity of ceVUS ranged from 57% to 100%, and specificity from 85% to 100%. The diagnostic accuracy, measuring the concordance of both positive and negative cases, ranged from 78% to 96%. Currently, the second-generation contrast SonoVue-enhanced VUS has superior sensitivity ranging from 80% to 100%, and a specificity of 77% to 97% [13, 27, 28, 29, 30]. Diagnostic accuracy is similar to that of Levovist, at about 80% to 98%. Moreover, SonoVue-enhanced VUS has consistently higher reflux detection rate than VCUG. Data show that VCUG misses 6% to 62% of all reflux units. In the study by Ključevšek et al. [27], 26 (62%) out of 42 reflux units were additionally identified by ceVUS alone, but none by VCUG alone. On the other hand, ceVUS misses only 0% to 12% of all reflux units.

Therefore, ceVUS is not only highly concordant with VCUG on reflux detection, but also more sensitive than VCUG. With the use of VCUG, a significant number of patients with reflux who may need to be on prophylactic antibiotics can be missed. Furthermore, the reflux missed by VCUG was predominantly of higher grade and thus clinically more important than that missed by VUS. The fact that VCUG might underestimate or miss reflux may be partly explained by the intermittent nature of VUR, the potential for marked dilution of contrast agent in a dilated system, and the short fluoroscopic time during VCUG [26]. Conversely, prolonged observation is an advantage of VUS that allows a higher number of patients with VUR and possibly higher grades of VUR to be diagnosed compared to VCUG. On the other hand, the lower detection rate of low-grade reflux on ceVUS is attributed to the difficulty in visualising retrovesical regions and nondilated ureter related to the acoustic shadow cast by the intravesical contrast.

In our patients, we did not perform comparative studies between ceVUS vs. VCUG.

We considered that there is enough evidence in the literature for diagnostic performance of ceVUS to escape unnecessary radiation.

A further advantage of second-generation contrast agents in the evaluation of VUR is the use of substantially lower volumes compared to first-generation contrast agents, leading to a significant reduction in the cost of the procedure [28, 30, and 31]. We used 1 ml of a second generation contrast agent that was adequate for making a confident diagnosis of

VUR. Due to the increased sensitivity of harmonic imaging [HI], even sporadic microbubbles can be reliably visualised. Because microbubbles after reconstitution are stable for approximately 6 h, a 5-ml vial could potentially be used for the examination of reflux in 5 children.

With the application of urethral imaging in ceVUS, examination of the urethra is technically feasible. Up to introduction of ceVUS, VCUG has been used as the only method for evaluation of the urethral pathology. By RNC it is not possible to visualise urethra. Consequently, for years in the evaluation of children with UTI, we have used VCUG as a first diagnostic test in boys and RCN in female children where there is no significant pathology of the urethra. Duran et al. [34] revealed that diagnosis of urethral pathologies, such as a posterior urethral valve, diverticulum of prostatic utricle, and anterior urethral stricture could be achieved by ceVUS, using interscrotal and transperineal approaches in boys. In our patients, we used transperineal and suprapubic trans pelvic approach during urgent voiding. The urethra was visualised in most but not in all patients, presumably because of their refusing to void. In children where the urethra has been shown by ceVUS, we did not diagnose any urethral pathology; however, from a clinical point of view, it is important that we have ruled it out by using radiation-free method instead of invasive VCUG. In two girls spinning top urethra has been shown (Fig. 3), that can be a normal variant, but it is important to rule out functional voiding disorder. Indeed, in both patients, subsequent urodynamic study confirmed functional bladder disturbance.

Echo-enhanced VUS is now described in standard paediatric radiology and urology textbooks and incorporated into guidelines. The ceVUS had been incorporated in the joint guideline for urological examination by the European Society of Urogenital Radiology [ESUR] and European Society of Pediatric Radiology (ESPR) in 2007[35]. The indications of ceVUS include follow-up examination of known vesicoureteric reflux, investigation of UTI in girls, as well as screening for familial history of vesicoureteric reflux and fetal hydronephrosis. The application of ceVUS has extended to the investigation of UTI in boys and urethral imaging in genitogram in the ESUR and ESPR guideline 2012 [36]. It is starting to be used as the primary imaging modality for all cases of VUR detection, regardless of age [27, 32]. VCUG is reserved for a limited number of patients requiring detailed anatomical assessment [32].

In conclusion, in the era of heightened radiation awareness and protection, radiation doses to infants and children should be kept as low as reasonably achievable. Our data indicate that contrast-enhanced voiding ultrasonography using intravesical second-generation ultrasound contrast agent could be introduced as a valid alternative diagnostic modality for detecting vesicoureteral reflux

and evaluation of the distal urinary tract in children, based on its radiation-free, highly efficacious, reliable, and safe characteristics.

References

- Diamond DA, Mattoo TK. Endoscopic treatment of primary vesicoureteral reflux. *N Engl J Med*. 2012;366(13):1218-26. <https://doi.org/10.1056/NEJMct1108922> PMID:22455416
- Sargent MA. What is the normal prevalence of vesicoureteral reflux? *Pediatr Radiol*. 2000;30(9):587-93. <https://doi.org/10.1007/s002470000263> PMID:11009294
- Venhola M, Hannula A, Huttunen NP, Renko M, Pokka T, Uhari M. Occurrence of vesicoureteral reflux in children. *Acta Paediatr*. 2010;99(12):1875-8. <https://doi.org/10.1111/j.1651-2227.2010.01909.x> PMID:20545929
- Greenfield SP, Wan J. Vesicoureteral reflux: practical aspects of evaluation and management. *Pediatr Nephrol*. 1996;10(6):789-94. <https://doi.org/10.1007/s004670050218>
- Skoog SJ, Peters CA, Arant BS Jr, Copp HL, Elder JS, Hudson RG, Khoury AE, Lorenzo AJ, Pohl HG, Shapiro E, Snodgrass WT, Diaz M. Pediatric Vesicoureteral Reflux Guidelines Panel Summary Report: Clinical Practice Guidelines for Screening Siblings of Children With Vesicoureteral Reflux and Neonates/Infants With Prenatal Hydronephrosis. *J Urol*. 2010;184(3):1145-51. <https://doi.org/10.1016/j.juro.2010.05.066> PMID:20650494
- Koff SA, Wagner TT, Jayanthi VR. The relationship among dysfunctional elimination syndromes, primary vesicoureteral reflux and urinary tract infections in children. *J Urol*. 1998; 160:1019-22. [https://doi.org/10.1016/S0022-5347\(01\)62686-7](https://doi.org/10.1016/S0022-5347(01)62686-7)
- Bailey RR. The relationship of vesico-ureteric reflux to urinary tract infection and chronic pyelonephritis—reflux nephropathy. *Clin Nephrol*. 1973; 1:132-41. PMID:4783715
- Subcommittee on Urinary Tract Infection, Steering Committee on Quality Improvement and Management, Roberts KB. Urinary tract infection: clinical practice guideline for the diagnosis and management of the initial UTI in febrile infants and children 2 to 24 months. *Pediatrics*. 2011; 128:595-610. <https://doi.org/10.1542/peds.2011-1330> PMID:21873693
- Radmayr C, Klauser A, Pallwein L, Zurnedden D, Bartsch G, Frauscher F. Contrast enhanced reflux sonography in children: a comparison to standard radiological imaging. *J Urol*. 2002; 167:1428-30. [https://doi.org/10.1016/S0022-5347\(05\)65335-9](https://doi.org/10.1016/S0022-5347(05)65335-9)
- Escape I, Martinez J, Bastart F, Solduga C, Sala P. Usefulness of echocystography in the study of vesicoureteral reflux. *J Ultrasound Med*. 2001; 20:145-9. <https://doi.org/10.7863/jum.2001.20.2.145> PMID:11211135
- Bosio M. Cystosonography with echocontrast: a new imaging modality to detect vesicoureteric reflux in children. *Pediatr Radiol*. 1998; 28:250-5. <https://doi.org/10.1007/s002470050343> PMID:9545481
- Darge K, Bruchelt W, Roessling G et al. Interaction of normal saline solution with ultrasound contrast medium: significant implication for sonographic diagnosis of vesicoureteral reflux. *Eur Radiol*. 2003;13:213-218. PMID:12541132
- Papadopoulou F, Anthopoulou A, Siomou E, Efremidis S, Tsamboulas C, Darge K. Harmonic voiding urosonography with a second-generation contrast agent for the diagnosis of vesicoureteral reflux. *Pediatr Radiol*. 2009; 39:239-44. <https://doi.org/10.1007/s00247-008-1080-x> PMID:19096835
- Papadopoulou F, Tsampoulas C, Siomou E et al. Cyclic contrast-enhanced harmonic voiding urosonography for the evaluation of reflux. Can we keep the cost of the examination low? *Eur Radiol*. 2006; 16:2521-2526. <https://doi.org/10.1007/s00330-006-0253-y> PMID:16639494
- Berrocal T, Gayá F, Arjonilla A. Vesicoureteral reflux: can the urethra be adequately assessed by using contrast-enhanced voiding US of the bladder? *Radiology*. 2005;234(1):235-41. <https://doi.org/10.1148/radiol.2341031503> PMID:15618383
- Lebowitz RL, Olbing H, Parkkulainen KV, Smellie JM, Tamminen- Moebius TE. International system of radiographic grading of vesicoureteric reflux. *Pediatr Radiol*. 1985; 15:105-9. <https://doi.org/10.1007/BF02388714> PMID:3975102
- Perisinakis K, Raissaki M, Damilakis J, Stratakis J, Neratzoulakis J, Gourtsoyiannis N. Fluoroscopy-controlled voiding cystourethrography in infants and children: are the radiation risks trivial? *Eur Radiol*. 2006; 16:846-51. <https://doi.org/10.1007/s00330-005-0072-6> PMID:16328446
- Unver T, Alpay H, Biyikli NK, Ones T. Comparison of direct radionuclide cystography and voiding cystourethrography in detecting vesicoureteral reflux. *Pediatr Int*. 2006; 48:287-291. <https://doi.org/10.1111/j.1442-200X.2006.02206.x> PMID:16732797
- Kuzmanovska D, Tasik V, Sahpazova E. Detection of vesicoureteral reflux with radionuclide cystography. *Srpski arhiv za celokupno lekarstvo*. 1996; 124(Suppl 1):78-81. PMID:9102939
- Fettich J, Colarinha P, Fischer S, et al. Guidelines for direct radionuclide cystography in children. *Eur J Nucl Med Mollmaging*. 2003; 30:39-44. <https://doi.org/10.1007/s00259-003-1137-x> PMID:12692686
- Bosio M. Cystosonography with echocontrast: a new imaging modality to detect vesicoureteric reflux in children. *Pediatr Radiol*. 1998; 28:250-5. <https://doi.org/10.1007/s002470050343> PMID:9545481
- Tranquart F, Grenier N, Eder V, Pourcelot L. Clinical use of ultrasound tissue harmonic imaging. *Ultrasound Med Biol*. 1999; 25:889-94. [https://doi.org/10.1016/S0301-5629\(99\)00060-5](https://doi.org/10.1016/S0301-5629(99)00060-5)
- Schneider M. SonoVue, a new ultrasound contrast agent. *Eur Radiol*. 1999; 9(Suppl 3):347S-348S. <https://doi.org/10.1007/PL00014071>
- Shapiro RS, Wagreich J, Parsons RB, Stancato-Pasik A, Yeh HC, Lao R. Tissue harmonic imaging sonography: evaluation of image quality compared with conventional sonography. *Am J Roentgenol*. 1998; 171:1203-6. <https://doi.org/10.2214/ajr.171.5.9798848> PMID:9798848
- Darge K, Troeger J. Vesicoureteral reflux grading in contrast enhanced voiding urosonography. *Eur J Radiol*. 2002; 43:122-128. [https://doi.org/10.1016/S0720-048X\(02\)00114-6](https://doi.org/10.1016/S0720-048X(02)00114-6)
- Darge K. Voiding urosonography with US contrast agents for the diagnosis of vesicoureteric reflux in children. II. Comparison with radiological examinations. *Pediatr Radiol*. 2008; 38:54-63. <https://doi.org/10.1007/s00247-007-0528-8> PMID:17639371
- Ključevšek D, Battelino N, Tomažič M, Kersnik Levart T. A comparison of echo-enhanced voiding urosonography with X-ray voiding cystourethrography in the first year of life. *Acta Paediatr*. 2012; 101:e235-9. <https://doi.org/10.1111/j.1651-2227.2011.02588.x> PMID:22211993
- Ascenti G, Zimbaro G, Mazziotti S, et al. Harmonic US imaging of vesicoureteric reflux in children: usefulness of a second generation US contrast agent. *Pediatr Radiol*. 2004; 34:481-487. <https://doi.org/10.1007/s00247-004-1190-z> PMID:15107964
- Kis E, Nyitrai A, Varkonyi I, et al. Voiding urosonography with second-generation contrast agent versus voiding cystourethrography. *Pediatr Nephrol*. 2010; 25:2289-93. <https://doi.org/10.1007/s00467-010-1618-7> PMID:20686902
- Darge K, Beer M, Gordjani N, Riedmiller H. Contrast enhanced voiding urosonography with the use of a 2nd generation US contrast medium: preliminary results. *Pediatr Radiol*. 2004; 34:97S.
- Robrecht J, Darge K. In-vitro comparison of a 1st and a 2nd generation US contrast agent for reflux diagnosis. *Rofo*. 2007; 179:818-82532. <https://doi.org/10.1055/s-2007-963312> PMID:17638173
- Ključevšek D. Echo-enhanced voiding urosonography in children: state of the art. *Paediatr Croat*. 2012; 56 (Supl 1): 147-

150.

33. Darge K, Moeller RT, Trusen A et al. Diagnosis of vesicoureteric reflux with low-dose contrast-enhanced harmonic ultrasound imaging. *Pediatr Radiol.* 2005; 35:73–78. <https://doi.org/10.1007/s00247-004-1317-2> PMID:15448949

34. Duran C, Valera A, Alguersuari A, et al. Voiding urosonography: the study of the urethra is no longer a limitation of the technique. *Pediatr Radiol.* 2009; 39:124-31. <https://doi.org/10.1007/s00247-008-1050-3> PMID:19002449

35. Riccabona M, Avni FE, Blickman JG, et al. Imaging recommendations in paediatric urology: minutes of the ESPR workgroup session on urinary tract infection, fetal hydronephrosis,

urinary tract ultrasonography and voiding cystourethrography, Barcelona, Spain, June 2007. *Pediatr Radiol.* 2008;38:138-45. <https://doi.org/10.1007/s00247-007-0695-7> PMID:18071685

36. Riccabona M, Avni FE, Damasio MB, et al. ESPR Uroradiology Task Force and ESUR Paediatric Working Group—Imaging recommendations in paediatric urology, part V: childhood cystic kidney disease, childhood renal transplantation and contrast-enhanced ultrasonography in children. *Pediatr Radiol.* 2012; 42:1275-83. <https://doi.org/10.1007/s00247-012-2436-9> PMID:23001574