



Unique case of central retinal artery occlusion secondary to COVID-19 disease



Sudeep Acharya, Matthew Diamond, Shamsuddin Anwar*, Allison Glaser, Priya Tyagi

Staten Island University Hospital, Northwell Health, United States

ARTICLE INFO

Article history:

Received 1 June 2020

Received in revised form 8 June 2020

Accepted 8 June 2020

Keywords:

COVID-19

Infectious disease

Sepsis

ABSTRACT

SARS-COVID-2 has been noted to be associated with neurological symptoms and complications including stroke. Hypercoagulability associated with COVID-19 has been described as a “sepsis-induced coagulopathy” and may predispose to spectrum of thromboembolic events. We present a unique article of isolated central retinal artery occlusion secondary to SARS-COV 2.

© 2020 The Authors. Published by Elsevier Ltd. This is an open access article under the CC BY-NC-ND license (<http://creativecommons.org/licenses/by-nc-nd/4.0/>).

Case report

A 60-year-old Hispanic male with past medical history of hypertension, dyslipidemia, stable coronary artery disease and chronic obstructive pulmonary disease presented to the emergency department with persistent fever, cough, and worsening shortness of breath. Vitals were significant for fever of 101.2 F, tachypnea and pulmonary exam with bilateral expiratory wheeze. Chest radiography revealed bilateral reticular interstitial opacities consistent with viral pneumonia (Fig. 1) and he tested positive for SARS-CoV-2 by PCR testing. In the beginning, he required supplemental oxygen on nasal canula three liters but subsequently developed acute respiratory distress syndrome with cytokine release syndrome (Table 1). He was intubated and transferred to the intensive care unit on his third day of hospitalization and received COVID-19-directed therapy including hydroxychloroquine, azithromycin, and tocilizumab. He remained in the intensive care for total six days until he was extubated and transferred to the general medical floor.

On twelfth hospital day, he complained of sudden onset of painless loss of vision in the right eye. Upon examination the right pupil was unresponsive to light and absent accommodation reflex. The patient was promptly evaluated by the neurologist and emergent non-contrast computed tomographic (CT) imaging study of the head and angiogram were obtained which were unremarkable for any acute infarct or blood clot. Ophthalmology performed a bedside assessment of intraocular pressure and anterior and

posterior segment of the right eye. The anterior segment was clear and unremarkable, however, on examination of the posterior segment it was found that the right optic nerve had slightly indistinct margins and a cherry red spot with significant retinal whitening which confirmed the diagnosis of central retinal artery occlusion.

Discussion

Central retinal artery occlusion (CRAO) is an ophthalmic emergency and is akin to a myocardial infarction to the cardiologist and a cerebral stroke to the neurologist [1]. The prognosis is best determined by the particular type of CRAO. This includes: 1) non-arteritic permanent CRAO, 2) non-arteritic transient CRAO, 3) non-arteritic CRAO with cilioretinal sparing, and 4) arteritic CRAO [2].

Most patients experience a non-arteritic CRAO. In non-arteritic CRAO, the retinal artery is occluded from a platelet-fibrin thrombus or embolism from an atherosclerotic lesion or hypercoagulable state such as with COVID-19 [3]. The other subtypes of CRAO were ruled-out as this patient's CRAO did not resolve, cilioretinal sparing was not observed from ophthalmological examination and inflammatory markers (ESR/CRP) were not suggestive of giant cell arteritis. A review of the literature on PubMed did not demonstrate any documented case of CRAO associated with COVID-19. Thus, we are presenting the first case of isolated central retinal artery occlusion secondary to COVID-19. Hypercoagulability has emerged as a major cause of morbidity and mortality in patients with COVID-19 [4]. There have been numerous documented cases of deep venous thromboses, pulmonary emboli, and large-vessel ischemic strokes as a result of COVID-19 hypercoagulability. This is suspected to be due to a hyperinflammatory response caused by the SARS-CoV-2 virus [5].

* Corresponding author.

E-mail address: shamsduhs15@gmail.com (S. Anwar).

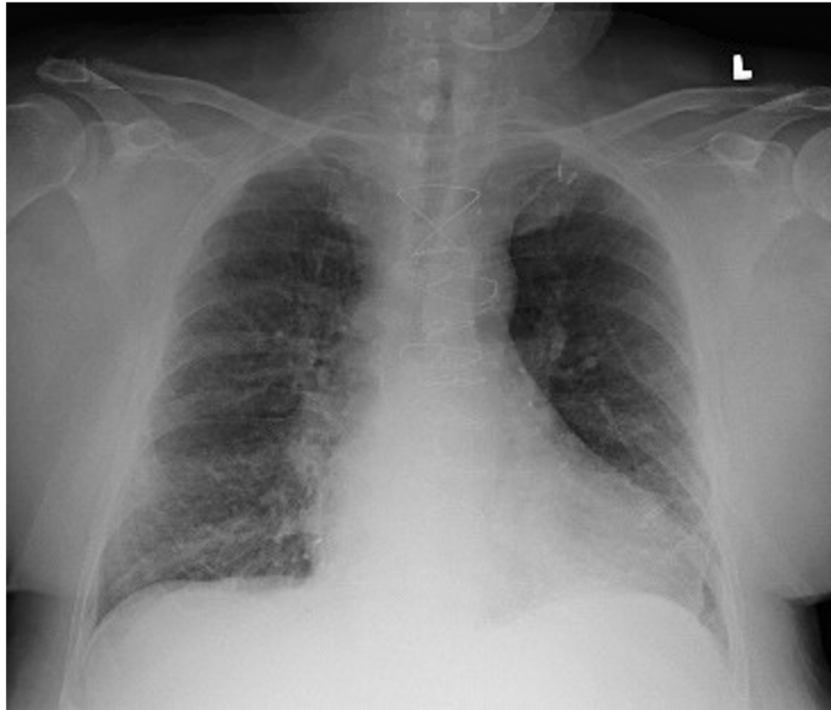


Fig. 1. Chest X-ray on admission.

Table 1
Inflammatory markers on admission.

INFLAMMATORY MARKER	LEVEL
Fibrinogen Assay	>700
D-dimer Assay	42,131
C-Reactive Protein	7.02
Ferritin	324
Procalcitonin	0.07
Interleukin-6	546.1

Elevated inflammatory markers including IL-6, CRP, ferritin, fibrinogen, and the D-Dimer were all observed in this patient contributing to an overall prothrombotic and hypercoagulable state. Physicians and healthcare providers must be aware of these vascular phenomena and maintain a high suspicion for acute ischemia and thrombosis in the proper clinical scenario as delaying intervention can result in irreversible destruction of vital tissue & morbidity [6].

The visual recovery after CRAO is usually very poor with no definitive treatment therapy available. The use thrombolytic agents and maneuvers such as ocular massage, use of intraocular hypotensive agents and anterior chamber paracentesis to dislodge the blood clot has been controversial with no proven benefit over the other [7,8].

Authorship statement

Manuscript title: Unique case of Central Retinal Artery Occlusion secondary to COVID-19 Disease

All persons who meet authorship criteria are listed as authors, and all authors certify that they have participated sufficiently in the work to take public responsibility for the content, including participation in the concept, design, analysis, writing, or revision of the manuscript. Furthermore, each author certifies that this material or similar material has not been and will not be submitted to or published in any other publication before its appearance in the Hong Kong Journal of Occupational Therapy.

Authorship contributions

Please indicate the specific contributions made by each author (list the authors' initials followed by their surnames, e.g., Y.L. Cheung). The name of each author must appear at least once in each of the three categories below.

Category 1

Conception and design of study: S.Anwar ;A.Glaser; S.Acharya
acquisition of data: S.Acharya; M.Diamond;P.Tyagi
analysis and/or interpretation of data:S.Anwar; A.Glaser;
P.Tyagi

Category 2

Drafting the manuscript: M.Diamond; S.Anwar;S.Acharya
revising the manuscript critically for important intellectual
content: A.Glaser; P.Tyagi

Category 3

Approval of the version of the manuscript to be published (the names of all authors must be listed):

S. Anwar; S. Acharya; M. Diamond; P. Tyagi; A. Glaser

Acknowledgement

All persons who have made substantial contributions to the work reported in the manuscript (e.g., technical help, writing and editing assistance, general support), but who do not meet the criteria for authorship, are named in the Acknowledgements and have given us their written permission to be named. If we have not included an Acknowledgements, then that indicates that we have not received substantial contributions from non-authors.

References

- [1] Oxley TJ, Mocco J, Majidi S, et al. Large-vessel stroke as a presenting feature of Covid-19 in the young. *N Engl J Med* 2020;382(20):e60, doi:http://dx.doi.org/10.1056/NEJMc2009787.
- [2] Varma DD, Cugati S, Lee AW, Chen CS. A review of central retinal artery occlusion: clinical presentation and management. *Eye (Lond)* 2013;27(6):688–97, doi:http://dx.doi.org/10.1038/eye.2013.25.

- [3] Greven CM, Slusher MM, Weaver RG. Retinal arterial occlusions in young adults. *Am J Ophthalmol* 1995;120(6):776–83, doi:[http://dx.doi.org/10.1016/s0002-9394\(14\)72731-x](http://dx.doi.org/10.1016/s0002-9394(14)72731-x).
- [4] Panigada M, Bottino N, Tagliabue P, et al. Hypercoagulability of COVID-19 patients in intensive care unit. A report of thromboelastography findings and other parameters of hemostasis. , doi:<http://dx.doi.org/10.1111/jth.14850> [published online ahead of print Apr 17], *J Thromb Haemost*. 2020;. doi: 10.1111/jth.14850.
- [5] Rotzinger DC, Beigelman-Aubry C, von Garnier C, Qanadli SD. Pulmonary embolism in patients with COVID-19: time to change the paradigm of computed tomography. *Thromb Res* 2020;190:58–9, doi:<http://dx.doi.org/10.1016/j.thromres.2020.04.011>.
- [6] Hayreh SS, Zimmerman MB, Kimura A, Sanon A. Central retinal artery occlusion. Retinal survival time. *Exp Eye Res* 2004;78(3):723–36, doi:[http://dx.doi.org/10.1016/s0014-4835\(03\)00214-8](http://dx.doi.org/10.1016/s0014-4835(03)00214-8).
- [7] Rudkin AK, Lee AW, Aldrich E, Miller NR, Chen CS. Clinical characteristics and outcome of current standard management of central retinal artery occlusion. *Clin Exp Ophthalmol* 2010;38(5):496–501, doi:<http://dx.doi.org/10.1111/j.1442-9071.2010.02280.x>.
- [8] Richard G, Lerche RC, Knospe V, Zeumer H. Treatment of retinal arterial occlusion with local fibrinolysis using recombinant tissue plasminogen activator. *Ophthalmology* 1999;106(4):768–73, doi:[http://dx.doi.org/10.1016/S0161-6420\(99\)90165-3](http://dx.doi.org/10.1016/S0161-6420(99)90165-3).