

# Comparative Evaluation of Peri-implant Soft and Hard Tissue with and without Application of Bisphosphonate on Implant Surface and Osteotomy Site – A Clinico-radiographic, Cone-beam Computed Tomographic Study

## Abstract

**Background:** The requisites to long-term success of dental implant are good-quality bone and healthy gingiva. Long-term risk with regard to dental implant is crestal bone loss. The cause of this crestal bone loss is inflammation of surrounding soft tissue and bone. One of the techniques used to prevent crestal bone loss includes the use of biological mediators. Bisphosphonates are antiresorptive drugs that act on osteoclasts and maintain bone density and strength by inhibiting osteoclast activity. **Materials and Method:** 16 systemically healthy patients aged between 20 and 50 years desirous of replacing single missing posterior tooth with an adequate width and height of edentulous space included in the study. 8 patients were treated with application of bisphosphonate on implant surface and osteotomy site and 8 patients were treated only with implant therapy. **Results:** Crestal bone level changes were observed both in the study and control group. At 12 months, bisphosphonate-treated group showed less amount of crestal bone loss than control group. **Conclusion:** Local application of bisphosphonate (sodium alendronate) application around the implant and osteotomy site shows reduction in the amount of crestal bone loss but it is not statistically significant when compared with control group.

**Keywords:** Bisphosphonates, crestal bone loss, dental implant

## Introduction

The use of endosseous implants to restore lost dentition has proved to be a successful treatment modality, providing the patient with near natural replacement of teeth. The most important criteria for the success of the dental implant are the presence of good quality and amount of bone around the implant. Adell *et al.*<sup>[1]</sup> were the first to indicate greater magnitude and occurrence of bone loss during the 1<sup>st</sup> year of prosthesis loading. Successful implant is defined in terms of bone loss around an implant restoration, which after the accepted crestal bone loss is not >1.5 mm during the 1<sup>st</sup> year after placement and should be not >0.2 mm during subsequent years.<sup>[2]</sup>

Modification of osseous tissues has been an ongoing area of research. Various techniques have been used to prevent crestal bone loss around dental implants. One of the techniques includes the use of biological mediators to improve the quality and quantity of bone. The use of bioactive coating enables a chemical bond between the implant surface and surrounding

bone tissue. Tetracycline enhances blood clot attachment and retention on the implant surface during the initial phase of the healing process and thus promotes osseointegration.<sup>[3]</sup>

Growth and differentiation factors accelerate and enhance the bone ingrowth and strengthen implant fixation. One group of such bioactive drugs are bone metabolism mediators such as bisphosphonates. Bisphosphonates are antiresorptive drugs that act on osteoclasts and maintain bone density and strength by inhibiting osteoclast activity.<sup>[4]</sup> Alendronate, a second-generation bisphosphonate, has been used for prevention and treatment of primary and secondary osteoporosis, Paget's disease, multiple myeloma, bone metastasis, etc., It is given intravenously so as to reduce alveolar bone loss in response to mucoperiosteal flap procedure. However, it was seen that the effect of amino bisphosphonate when given by intravenous route had inhibiting effect on bone resorption.<sup>[5]</sup> To avoid the side effect of systemic use, local delivery methods

This is an open access journal, and articles are distributed under the terms of the Creative Commons Attribution-NonCommercial-ShareAlike 4.0 License, which allows others to remix, tweak, and build upon the work non-commercially, as long as appropriate credit is given and the new creations are licensed under the identical terms.

For reprints contact: reprints@medknow.com

**How to cite this article:** Jahan S, Kaushik M, Wadhawan A. Comparative evaluation of peri-implant soft and hard tissue with and without application of bisphosphonate on implant surface and osteotomy site – A clinico-radiographic, cone-beam computed tomographic study. *Contemp Clin Dent* 2019;10:208-13.

**Shabnam Jahan,  
Mayur Kaushik,  
Amit Wadhawan**

*Department of Periodontology,  
Subharti Dental College,  
Meerut, Uttar Pradesh, India*

**Address for correspondence:**  
Dr. Shabnam Jahan,  
223/3 Sheikhpuri Roorkee  
247667, Uttarakhand, India.  
E-mail: docshabnamwaheed@  
gmail.com

Access this article online

**Website:**  
[www.contempclindent.org](http://www.contempclindent.org)

**DOI:** 10.4103/ccd.ccd\_340\_18

**Quick Response Code:**



have also been implicated. Topical application of 20 mg/ml of alendronate, as studied using microradiography pattern, is effective in reducing alveolar bone loss when delivered at surgical sites.<sup>[6]</sup>

Thus, the purpose of the present study was to evaluate the soft- and hard tissue changes around the implant with and without application of sodium alendronate solution on implant surface and osteotomy site clinically and radiographically by radiovisiography (RVG) and cone-beam computed tomography (CBCT).

## Materials and Methods

A prospective, randomized controlled trial was conducted in Subharti Dental College and Hospital, Meerut, India, on 16 systemically healthy patients (6 females and 10 males) aged between 20 and 50 years from October 2015 to December 2016. Inclusion criteria of the study included single missing posterior tooth with an adequate width and height of edentulous space available for the placement of implant, edentulous sites in maxillary and mandibular posterior regions, teeth extracted minimum 4 months before implant placement, adjacent teeth intact restored with functionally and esthetically good restorations restored with prosthesis precluding the addition of missing teeth.

Patients who are unable to perform routine oral hygiene procedures, periodontitis, patients with bruxism and parafunctional habits patients with uncontrolled diabetes (Glycosylated hemoglobin [HbA1c value] >5.7%), patients with bone disorders, pregnant and lactating women, patient with history of smoking, and patients with temporomandibular joint disorders were excluded from the study.

The study was approved by the Institutional Ethical Committee with a trial number SDC/IEC/2016/113. All selected participants who consented to participate received a standard treatment with single implant system (Alpha-bio SPI Dental Implant System, Israel). The patients were then explained about the treatment procedure and the associated risks and benefits and their written consent was obtained. The patients were randomly allocated into the following two groups with 8 patients in each group.

- Test (Group A): 8 patients were treated with application of sodium alendronate solution on implant surface and osteotomy site
- Control (Group B): 8 patients were treated only with implant therapy.

### Preparation of modified bisphosphonate solution

A second-generation amino bisphosphonate-sodium alendronate was used in this study as modified bisphosphonate solution. A dose of 35 mg sodium alendronate tablet (Osteofos®) was crushed in sterilized mortar pestle. Alendronate solution was prepared by mixing the powder with normal saline in Dappen dish. The concentration of solution was 20 mg in 1 ml normal saline solution.

Following initial examination and treatment planning, the selected patients underwent Phase I therapy. Patients were given one capsule of Augmentin 625 mg 1 hour before the procedure.

### Surgical procedures

After assessing the pretreatment records that included preoperative RVG and CBCT [Figures 1 and 2] that aided in identifying vital anatomic landmarks, a patient was prepared for implant placement. Strict asepsis was followed during the procedure. After achieving adequate

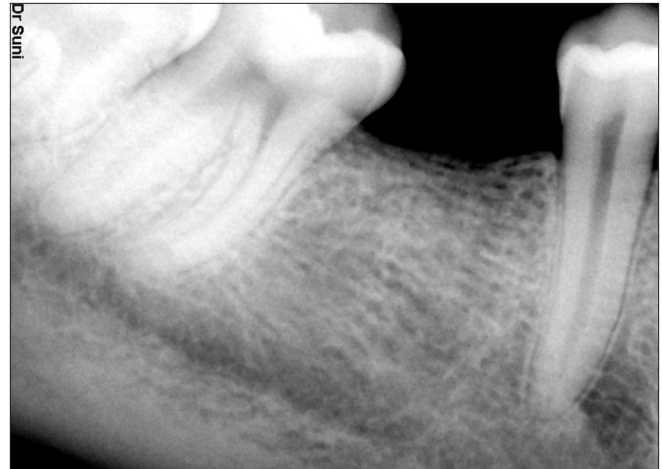

Figure 1: Preoperative radiovisiography

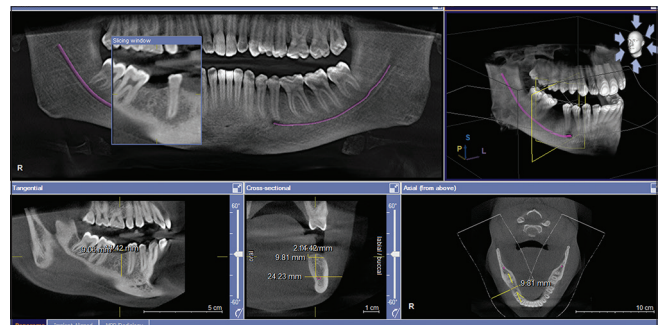


Figure 2: Preoperative cone-beam computed tomography

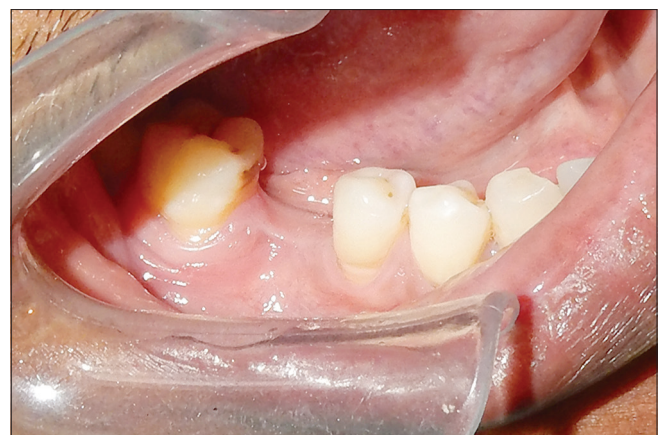

Figure 3: Preoperative view of edentulous ridge

local anesthesia, crestal incision was given to expose the alveolar ridge [Figure 3] with No. 12 Bard-Parker blade. Full-thickness flaps were elevated using periosteal elevator [Figure 4]. The optimal implant location was selected using a presurgical prosthetic guide. A lance drill was passed through surgical stent to the depth corresponding to the length of implant chosen. After that, the twist drill of 2 mm diameter was used at a drill speed of 1000 rpm and torque 30 N-cm with copious internal and external sterile saline irrigation [Figure 5]. The paralleling pin was placed into the implant site to check the proper alignment of the implant. Site was enlarged by subsequent drilling. Countersinking (2 mm) was done using next larger implant drill at a speed of 1000 rpm with constant irrigation [Figure 6]. The implant was removed under aseptic conditions from its sterile package with the help of torque ratchet and was dipped into prepared modified bisphosphonate solution [Figure 7]. Then, the same bisphosphonate solution was taken in a syringe and the osteotomy site was irrigated [Figure 8]. The implant was put into osteotomy site with an insertion torque of 30 N-cm at the crestal level. The cover screw was placed using the 0.05" hex driver [Figure 9]. At this point, the implant was immobile, which ensured primary stability.

The flap margins were then repositioned and sutured tension-free [Figure 10]. The position and angulation of the implant was confirmed by taking RVG.

Control (Group B) – Similar to the test group, after induction of local anesthesia, similar procedure was carried out. The only difference was that application of bisphosphonate was not done in the implant surface and osteotomy site.

### Second-stage surgery

After assessing the short healing period which Varied from 3 to 6 months, the second-stage implant surgery was done and the healing abutment was attached to implant that were left *in situ* for approximately for 10 days, following which the metal ceramic crown prosthesis was given [Figure 11]. Twelve-month follow-up included post-12 months RVG, CBCT, and clinical evaluation [Figures 12 and 13].

### Clinical and radiographic assessment

The assessment of soft-tissue changes was done at baseline, 3, 6, 9, and 12 months. The following parameters – Plaque Index, Modified Plaque Index,<sup>[7]</sup> Gingival Index, Modified Gingival Index,<sup>[8]</sup> Gingival Bleeding Index, Modified Sulcular Bleeding Index,<sup>[9]</sup>

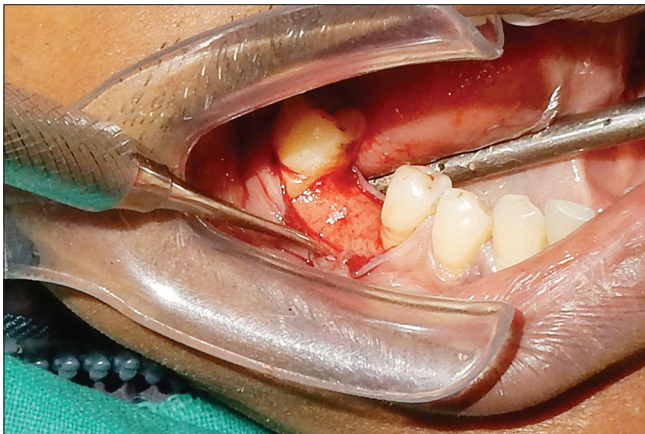


Figure 4: Incisions given and flap reflected

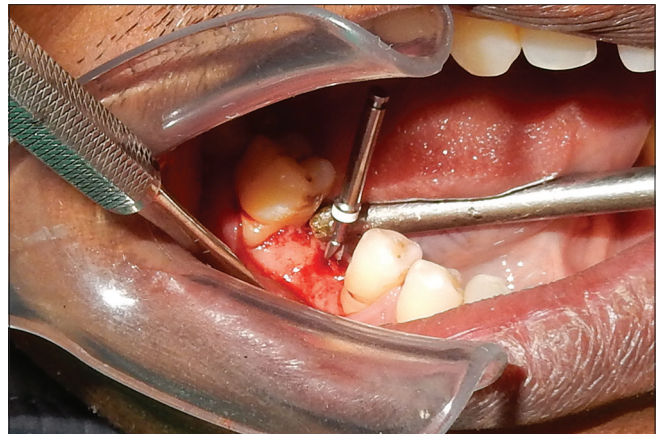

Figure 5: 2mm twist drill

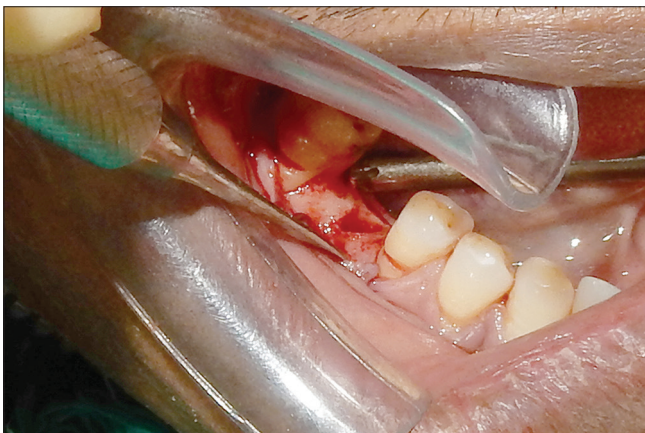


Figure 6: Osteotomy site prepared

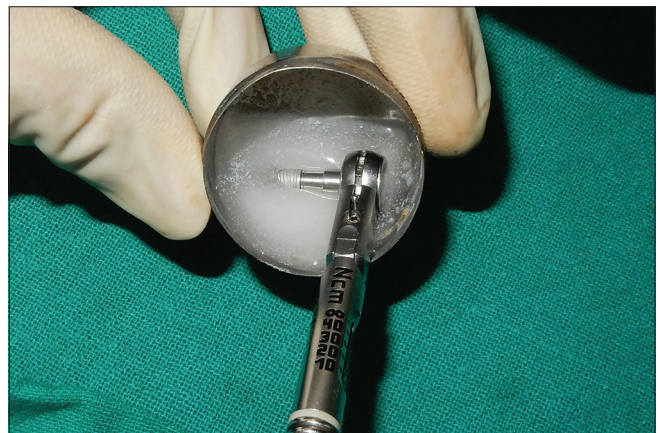

Figure 7: Implant coated with bisphosphonate solution

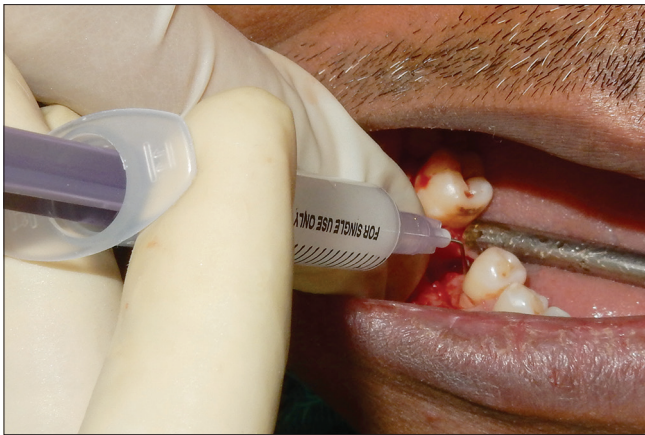

Figure 8: Osteotomy site irrigated with bisphosphonate solution

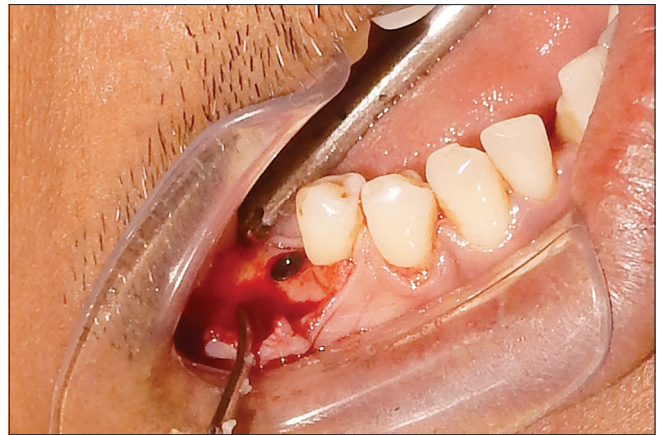

Figure 9: Implant placed

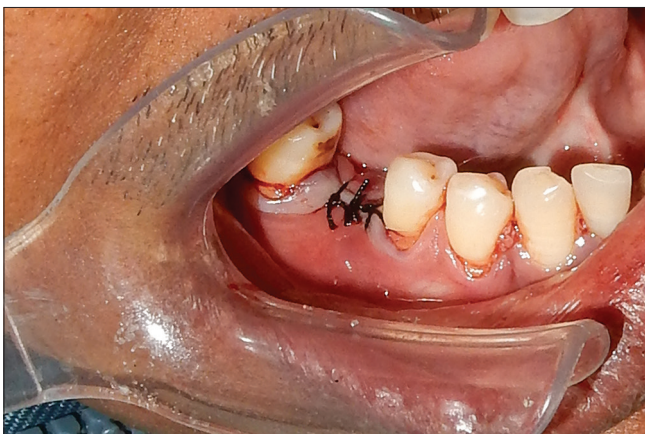

Figure 10: Sutures placed

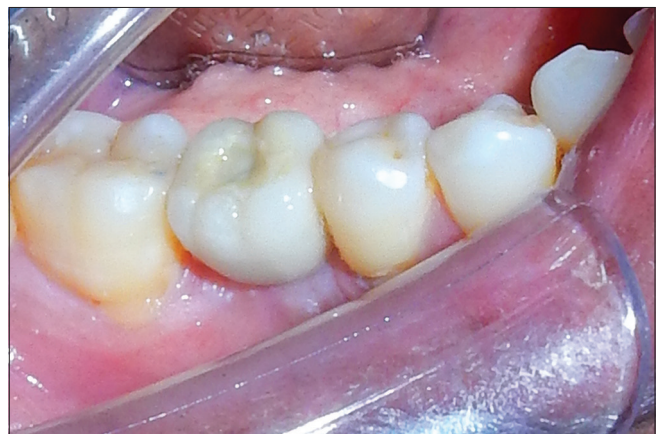

Figure 11: Crown placed

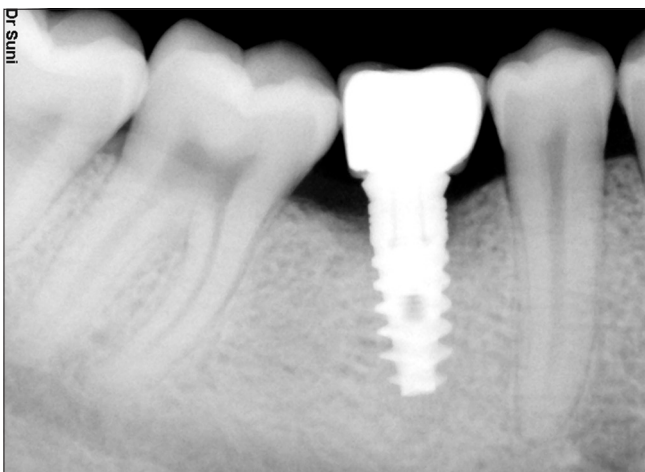


Figure 12: 12-month postoperative radiovisiography

Keratinized Mucosa Index,<sup>[10]</sup> and Probing Depth were recorded at four sites around implant (mesial, distal, buccal, and lingual) using plastic probe.

The measurements for crestal bone changes were made at baseline and 12 months after implant placement. The implant abutment junction was taken as a static reference

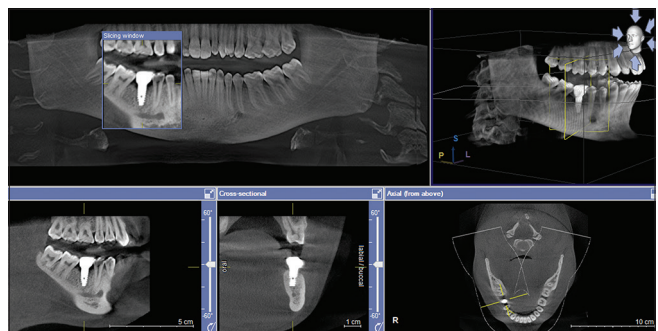


Figure 13: 12-month postoperative cone-beam computed tomography

line. The point of bone to implant contact was chosen as the bone level. Radiographs were taken using the RINN XCP system<sup>®</sup> (Dentsply, USA) by the standardized paralleling technique with the digital RVG (Sunl Ray<sup>®</sup> Sunl Imaging Micro system Inc.) to assess the amount of the mesial and distal bone loss around the implant. CBCT scan (Galileos-Sirona, CS 9300 Scanner<sup>®</sup>) was done to assess the buccal and lingual bone level around the implant. Postoperative CBCT scan was done 1 year after the placement of implant.

**Statistical analysis**

All the values were expressed in the form of mean and standard deviation. The statistical test used for intergroup comparison was unpaired *t*-test and for intragroup comparison was paired *t*-test on software SPSS 17.0 version (Alliance Cd Solutions, Kingsway Camp, Delhi, India). *P* < 0.05 indicated statistically significant difference between the group means at 5% level of significance.

**Results**

On intragroup comparison, both the groups showed improvement in full-mouth and implant-site soft-tissue parameters, However the bisphosphonate-treated group showed greater probing depth reduction and less gingival bleeding scores. The improvement though was not statistically significantly different between the bisphosphonate-treated group and control group. This indicates that both groups maintained comparable levels of oral hygiene until the 12-month follow-up [Table 1].

Crestal bone level changes were observed both in the study and control group. On intragroup comparison in both the groups, statistically significant crestal bone level changes were noted within 12 months. On intergroup comparison at 12 months, bisphosphonate-treated group showed less amount of crestal bone loss than control group with a *P* = 0.147 mesially, 0.087 distally, 0.125 buccally, and 0.392 lingually. However, the amount of crestal bone level changes were statistically not significant on intergroup comparison.

**Discussion**

The presence of crestal bone is one of the key factors that influences the appearance or maintenance of peri-implant soft-tissue architecture. Majority of crestal bone loss occurs during the 1<sup>st</sup> year of implant function, and it can be as much as 1.2 mm coronopically. Hence, crestal bone

preservation is a very important key to success in implant dentistry. According to Rimanchian *et al.*,<sup>[11]</sup> the mean bone loss was 1.08 mm at loading time and 1.43 mm after 2 years following implant insertion. Bisphosphate act exclusively on bone due to special affinity, where they deposit under newly formed Bone. Also bisphosphonate-loaded implant surfaces have been reported to improve implant osseointegration.<sup>[12]</sup>

In the present study, differences in the soft-tissue parameter scores for both the groups (full mouth and implant site) from baseline to 3 months and 12 months, respectively, and from 3 to 6 months, 6 to 9 months, and 9 to 12 months were not statistically significant. This was accomplished by the reinforcement of plaque control measures and oral hygiene maintenance instructions at various recall periods. These results are in accordance with the observations of previous studies.<sup>[9,13]</sup>

In the present study, the digital RVG (SuniRay® Suni Imaging Micro system Inc.) was taken to assess mesial and distal marginal bone loss and CBCT was used in this study to determine the marginal buccal and lingual peri-implant crestal bone levels. Results are in agreement with the previous studies.<sup>[14-16]</sup> In the present study, a second-generation amino bisphosphonate-sodium alendronate was used as modified bisphosphonate solution on implant surface and osteotomy site. A similar method was used by Zuffetti *et al.*,<sup>[17]</sup> in which a modified clodronate solution was used to irrigate the osteotomy site. The bisphosphonate-treated implant showed more contact with newly formed bone than the control implant.

In the present study, alendronate was chosen among the various bisphosphonates, as it belongs to the second-generation bisphosphonates which have a tenfold increased efficacy over the first-generation bisphosphonates like etidronate. The more potent drugs that belong to the third generation, for example, zoledronate and risedronate, were not used as they are not readily available.

In the current study, it was decided to use the local application of the drug as its long-term systemic use has been associated with osteonecrosis of jaw that is also called as bisphosphonate-related osteonecrosis of jaw (BRONJ).<sup>[18]</sup> Furthermore, patients with underlying bone disorders were excluded from the study.

In the current study, alendronate was used in the dosage of 20 mg/ml which was mixed with normal saline solution. The same concentration was used in previous studies and it was topically applied using surgical foam pellets. Yaffe *et al.*<sup>[5]</sup> demonstrated that on local application of this concentration, 10% of it was absorbed by the surgical site. Binderman *et al.*<sup>[19]</sup> evaluated various concentrations for local delivery of alendronate. In a study done by Stephen J Meraw, hydroxyapatite implant loaded with bisphosphonate showed that hydroxyapatite has high

**Table 1: Intergroup comparison of clinical parameters in test and control group from baseline to 3, 6, 9, and 12 months**

Parameter	Baseline	3 months	6 months	9 months	12 months
PL-FM	0.680	0.681	0.918	0.236	0.322
MPI- IS	0.000	0.830	0.843	1.000	0.157
GI-FM	0.697	0.104	0.063	0.688	0.754
MGI-IS	0.000	0.506	0.794	0.303	0.334
GBL-FM	0.078	0.325	0.319	0.276	0.520
MSBI-IS	0.000	0.594	0.246	0.915	1.000
KMI-IS	0.000	0.614	0.904	0.888	0.901
PD-IS	0.000	0.844	0.655	0.536	0.466

*P*<0.05 - significant. *P*>0.05 - Non significant. PI-FM=Plaque index full mouth, MPI-IS=Modified plaque index implant site, GI-FM=Gingival index full mouth, MGI-IS=Modified gingival index implant site, GBL-FM=Gingival bleeding index full mouth, MSBI-IS=Modified sulcular bleeding index implant site, KMI-IS=Keratinized mucosa index implant site, PD-IS=Probing depth implant site

affinity to bind with bisphosphonate and it is absorbed on hydroxyapatite surface. In these studies, alendronate was used to prevent the regional accelerated phenomenon. However, there was no sustained release of the drug at the target site. In the present study, alendronate was used to irrigate the osteotomy site, which would not provide sustained release of the drug in accordance with the above delivery methods. To calculate the amount of incorporated drug on to the titanium implant surface and osteotomy site, we need to do histochemical analysis for that we need to compromise one implant along with alveolar bone.

The current study demonstrated a decrease in the crestal bone height reduction at 12 months in the test group; however, there was no statistically significant difference in the decrease in the radiographic crestal bone height reduction between the groups. These findings are in accordance with a previous study done by Adell *et al.*

In our study, biomodification of implant surface was done to reduce the amount of peripheral peri-implant bone loss and to improve the fixation of an implant in the jaw bone. This data is in accordance with a study done by Oncu and Alaaddinoglu.<sup>[20]</sup>

The improvement in the test group which has been observed from baseline to that of 12 months may be attributed to the effect of alendronate, but no statistical significant effect was noted in the test group over the control group.

## Conclusion

Within the limitations of the present study, following conclusions can be made:

1. All implants survived at the end of 12-month period showing a survival rate of 100%.
2. Although there was reduction of bone loss seen around implants treated with alendronate, the results of the present study were not statistically significant.

## Financial support and sponsorship

Nil.

## Conflicts of interest

There are no conflicts of interest.

## References

1. Adell R, Lekholm U, Rockler B, Brånemark PI. A 15-year study of osseointegrated implants in the treatment of the edentulous jaw. *Int J Oral Surg* 1981;10:387-416.
2. Misch CE. Density of bone: Effect on treatment plans, surgical approach, healing, and progressive boen loading. *Int J Oral Implantol* 1990;6:23-31.
3. Persson LG, Ericsson I, Berglundh T, Lindhe J. Osseointegration

- following treatment of peri-implantitis and replacement of implant components. An experimental study in the dog. *J Clin Periodontol* 2001;28:258-63.
4. Sato M, Grasser W, Endo N, Akins R, Simmons H, Thompson DD, *et al.* Bisphosphonate action. Alendronate localization in rat bone and effects on osteoclast ultrastructure. *J Clin Invest* 1991;88:2095-105.
5. Yaffe A, Fine N, Alt I, Binderman I. The effect of bisphosphonate on alveolar bone resorption following mucoperiosteal flap surgery in the mandible of rats. *J Periodontol* 1995;66:999-1003.
6. Yaffe A, Golomb G, Breuer E, Binderman I. The effect of topical delivery of novel bisacylphosphonates in reducing alveolar bone loss in the rat model. *J Periodontol* 2000;71:1607-12.
7. Mombelli A, van Oosten MA, Schurch E Jr., Land NP. The microbiota associated with successful or failing osseointegrated titanium implants. *Oral Microbiol Immunol* 1987;2:145-51.
8. Apse P, Zarb GA, Schmitt A, Lewis DW. The Longitudinal effectiveness of osseointegrated dental implants. The Toronto study. Peri implant mucosal response. *Int J Periodontics Restorative Dent* 1991;11:95-111.
9. Misch CE. Implant success or failure: Clinical assessment in implant dentistry. In: Misch CE, editor. *Contemporary Implant Dentistry*. St. Louis: Mosby; 1993. p. 29-42.
10. Cox JF, Zarb GA. The longitudinal clinical efficacy of osseointegrated dental implants: A 3-year report. *Int J Oral Maxillofac Implants* 1987;2:91-100.
11. Rimanchian M, Biragn R. Clinical efficacy of Nysastan Screw implant system in the mandibular posterior regions: a prospective 2-year study. *J Islamic Dent Assoc* 2007;19:62-7.
12. Fleisch H. Development of bisphosphonates. *Breast Cancer Res* 2002;4:30-4.
13. Joly JC, de Lima AF, da Silva RC. Clinical and radiographic evaluation of soft and hard tissue changes around implants: A pilot study. *J Periodontol* 2003;74:1097-103.
14. Rajpal J, Gupta KK, Tendon P, Srivastava A, Chandra C. Assessment of hard and soft tissue changes around implants: A clinic-radiographic *in vivo* study. *J Dent Implant* 2014;4:126-34.
15. Hafez WK, Seif SA, Shawky H, Hakam MM. Platelet rich fibrin as a membrane for coverage of immediate implants: Case-series study on eight patients. *Tanta Dent J* 2015;11:203-10.
16. Wada M, Tsuiki Y, Suganami T, Ikebe K, Sogo M, Okuno I, *et al.* The relationship between the bone characters obtained by CBCT and primary stability of the implants. *Int J Implant Dent* 2015;1:3.
17. Zuffetti F, Bianchi F, Volpi R, Trisi P, Del Fabbro M, Capelli M, *et al.* Clinical application of bisphosphonates in implant dentistry: Histomorphometric evaluation. *Int J Periodontics Restorative Dent* 2009;29:31-9.
18. Melo MD, Obeid G. Osteonecrosis of the jaws in patients with a history of receiving bisphosphonate therapy: Strategies for prevention and early recognition. *J Am Dent Assoc* 2005;136:1675-81.
19. Binderman I, Adut M, Yaffe A. Effectiveness of local delivery of alendronate in reducing alveolar bone loss following periodontal surgery in rats. *J Periodontol* 2000;71:1236-40.
20. Oncu E, Alaaddinoglu EE. Effect of platelet-rich fibrin on osseointegration. *Int J Oral Maxillofac Implants* 2015;30:578-82.