

Original Research Article

## Anatomical Validation of Internal Iliac Vessels Assessed by Three-dimensional Angiographic Analysis

Yuya Takenaka<sup>1)</sup>, Naohito Beppu<sup>1)</sup>, Masaki Otani<sup>1)</sup>, Kazuma Ito<sup>1)</sup>, Ayako Imada<sup>1)</sup>, Takaaki Matsubara<sup>1)</sup>, Jihyung Song<sup>1)</sup>, Kei Kimura<sup>1)</sup>, Kozo Kataoka<sup>1)</sup>, Motoi Uchino<sup>2)</sup>, Hiroki Ikeuchi<sup>2)</sup> and Masataka Ikeda<sup>1)</sup>

1) Department of Gastroenterological Surgery, Division of Lower Gastrointestinal Surgery, Hyogo Medical University, Hyogo, Japan

2) Department of Gastroenterological Surgery, Division of Inflammatory Bowel Disease Surgery, Hyogo Medical University, Hyogo, Japan

### Abstract

**Objectives:** Anatomical understanding of the internal iliac vessels is important with the increasing frequency of minimally-invasive pelvic surgery. We aimed to investigate the branch patterns of internal iliac vessels, especially the veins.

**Methods:** This study included 30 patients with 60 half-pelvises who underwent minimally-invasive pelvic surgery. Branch patterns were assessed on surgical videos with a multi-detector computed tomography-based three-dimensional simulation. Branch patterns of the superior gluteal artery and vein (SGA and SGV), inferior gluteal artery and vein (IGA and IGV), internal pudendal artery and vein (IPA and IPV), and obturator artery and vein (ObA and ObV) were investigated.

**Results:** In the most frequent internal iliac vein (IIV) branch pattern, 67% of SGV branched from the IIV, 95% of the IGV branched from the IPV and 82% of the ObV branched from the IPV. According to Adachi's classification, 62% of IIVs were Type I and 33% Type IV. Although IIV branch patterns are heterogeneous, in individual patients with the most frequent branch patterns, good correlation (75-100%) of the branch patterns was observed between the internal iliac artery (IIA) and IIV, and between the right and left IIVs.

**Conclusions:** This study clarified the branch patterns of IIV. In patients with the most frequent branch patterns, good correlation of the branch patterns was observed between the IIA and IIV, and between right and left IIV. We believe this helps secure the safety and standardization of minimally-invasive pelvic surgery.

### Keywords

anatomic variation, internal iliac artery, internal iliac vein, pelvic surgery, multi-detector computed tomography

J Anus Rectum Colon 2023; 7(3): 186-195

### Introduction

In colorectal surgery, minimally invasive surgery (MIS) has been increasingly used and the analysis of national databases in several countries has demonstrated that approxi-

mately two-thirds of cases are performed by MIS[1-6]. In addition, the significance of LLND has increased as it has the potential to achieve good local control, and it has received attention both in Japan and in Western countries[7-10]. With transitioning to MIS from open surgery, ex-

tended surgery, such as lateral lymph node dissection (LLND) and total pelvic exenteration (TPE), are also performed by MIS due to its benefits with regard to less blood loss, fewer postoperative complications, and a shorter postoperative hospital stay[11-15].

However, the anatomical complexity of the internal iliac vessels, especially the veins, represents a serious problem for performing these extended surgical operations by MIS. Thus, MIS for these extended surgical operations were only performed in specialized centers. In particular, the internal iliac veins (IIVs) show significant variation, and injury of these veins causes massive bleeding. To solve those problems, several studies have attempted to investigate the branch patterns of the IIVs. However, these studies focused on common internal and external iliac veins, and the peripheral sides of the veins were not well investigated[16-20].

We have previously demonstrated our laparoscopic LLND approach. The key point is the identification of the internal iliac vein behind the internal iliac artery from the inner and outer sides. We then dissect this vein to the peripheral side to identify the route of the IIVs and their branches[21]. Our laparoscopic approach is useful for clarifying the anatomy of the IIVs and their branches. Additionally, before surgery, we have introduced 1-mm-slice three-phase multidetector row computed tomography (MDCT) reconstruction using a three-dimensional (3D) simulation system for patients for whom LLND or TPE is planned.

The present study aimed to investigate the routes of the internal iliac arteries (IIAs) and IIVs, as well as their branches by MDCT-based 3D simulation in addition to surgical videos, especially the anatomical characteristics of the IIVs and their branches. The target vessels are superior gluteal artery and vein (SGA and SGV), inferior gluteal artery and vein (IGA and IGV), internal pudendal artery and vein (IPA and IPV), and obturator artery and vein (ObA and ObV).

## Methods

### Patients

This study included 30 patients with 60 half-pelvises who underwent laparoscopic bilateral LLND or TPE for rectal cancer in our institution from 2018.8 to 2021.8. The branch patterns of IIA and IIV of these patients were assessed on surgical videos as well as a pre-operative CT-based 3D simulation. In all cases, the route of the IIAs and IIVs was identified on either a surgical video or a pre-operative CT-based 3D simulation. This study was performed in line with the principles of the Declaration of Helsinki. Informed consent was obtained in the form of opt-out on the website. Ethics approval was granted by the Ethics Committee of Hyogo Medical University (Date20200406/No.202006-014).

This study investigated the branch patterns of the SGA and SGV, the IGA and IGV, the IPA and IPV, and the ObA and ObV. Then, the correlation of the branch patterns between the IIA and IIV were investigated in the whole population and individual patients. In addition, secondary investigated the correlation of the branch patterns between the right and left side IIVs were investigated in the whole population and individual patients. Third, the branch patterns of the arteries and veins were classified by Adachi's classification[18], which is a common classification of the IIAs. Finally, the correlation between the branch patterns of IIV and clinical outcomes such as surgical time, blood loss and fluid collection was investigated.

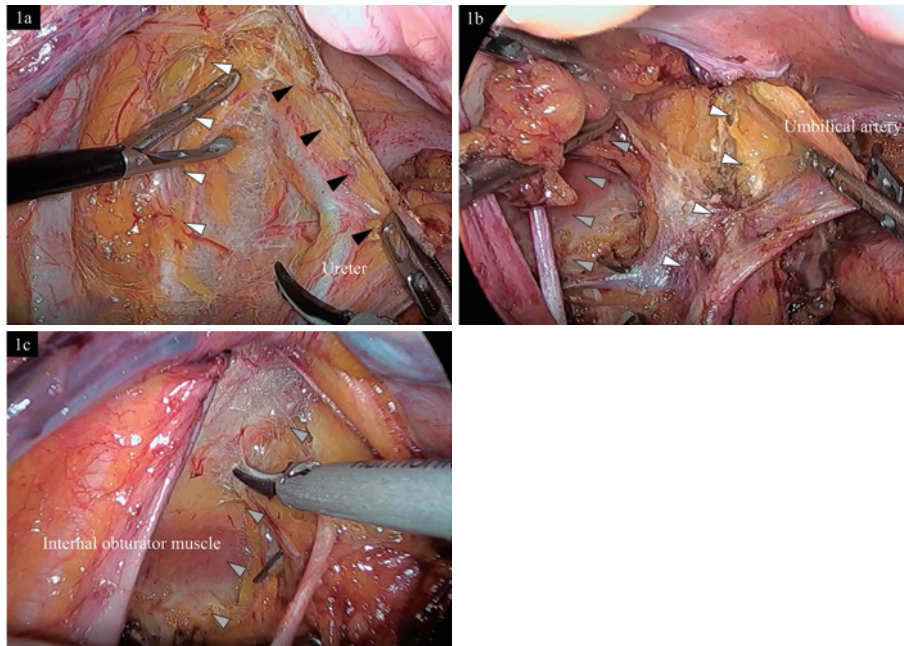
### Surgical videos

Surgical videos of LLND and TPE were retrospectively reviewed to identify the route of the IIAs and IIVs. In LLND and TPE in the lateral pelvic area, we first recognized the three fasciae: the ureterohypogastric nerve fascia (UNF), the vesicohypogastric fascia (VF), and the parietal pelvic fascia (PF) (Figure 1a, 1b, 1c). Second, we identified the routes of the IIAs and IIVs and their peripheral branches. Especially, IIVs and their peripheral branches run along the parietal fascia, which is the bottom of the region of LLND. Thus, we routinely dissect the inner and outer sides of the IIAs and IIVs to identify the routes of these vessels. Third, the fat and lymph nodes around these vessels were removed. This helps to identify the route of the IIAs and IIVs (Figure 2a, 2b).

### Pre-operative findings

All patients received preoperative contrast-enhanced CT. A triple-phase contrast study with a slice thickness of 1 mm was performed using a 128-detector row CT scanner. The obtained imaging datasets were analyzed using the SYNAPSE VINCENT image analysis system<sup>®</sup> (Fujifilm Medical Co., Tokyo, Japan), a 3D image processing software program. Three-dimensional simulation of the IIAs and IIVs involved the following steps. First: the CT data was input into the 3D simulation system. Early and washout phases of CT scanned at 25 and 120 seconds after the injection of contrast agent, respectively, were used. Second: the IIAs and IIVs, and their branches were manually plotted.

The SGA and SGV were defined as the vessels entering the superior foremen of the piriformis muscle. The IGA and IGV were defined as the vessels entering the inferior foremen of piriformis muscle. The IPA and IPV continue to the IIA and IIV and run through the inferior foremen of the piriformis muscle and Alcock's canal and under the perineum. The IPA and IPV are the terminal branches of the IIA and IIV. The IGA and IGV, and the IPA and IPV were determined based on the destination of the vessels, with the destination of the former being towards gluteal region and



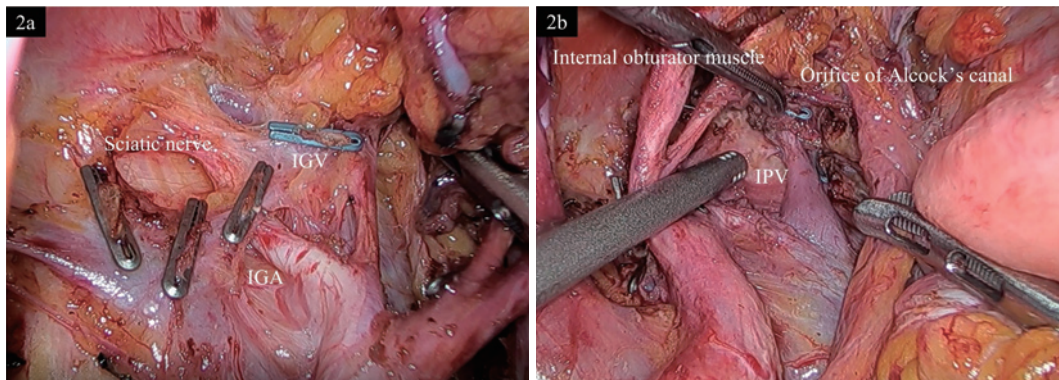
**Figure 1.** The three lateral pelvic fasciae (Left side).

1a: Ureterohypogastric nerve fascia (UNF).

1b: Vesicohypogastric fascia (VF).

1c: Parietal pelvic fascia (PF).

Black triangle indicates the UNF, White triangle indicates the VF, Gray triangle indicates the PF.



**Figure 2.** The main branches of the internal iliac artery and vein.

2a, Inner side of the internal iliac vein (IIV). The superior gluteal artery (SGA) / superior gluteal vein (SGV) runs dorsally, along the lumbar nerve.

IGA: inferior gluteal artery IGV: inferior gluteal vein

2b, Outer side of the IIV. The internal pudendal artery (IPA) / internal pudendal vein (IPV) run through the inferior foremen of the piriformis muscle and Alcock's canal.

the destination of the latter being towards the perineum. The ObA and ObV enter the obturator foramen. There has been no global consensus on the definition of the boundary between the IIV and IPV. We therefore defined the boundary as the level of the umbilical artery.

The branch patterns of the IIA and IIV were identified from surgical videos, which were checked by two colorectal

surgeons (YT and NB) with over ten years of experience in colorectal surgery. However, in some surgical videos, it was difficult to identify the routes of those vessels; thus, the 3D simulation of these vessels was simultaneously confirmed with surgical videos.

**Statistical analysis**

**Table 1.** Patient Characteristics.

Characteristic	Total (n=30)
Median age, years (range)	67 (47-78)
Sex, n (%)	
Male	21 (70%)
Female	9 (30%)
Median body mass index (range)	22.2 (16.3 - 27.1)
Diagnosis, n (%)	
Primary tumor	23 (77%)
Recurrent tumor	7 (23%)
Type of surgery, n (%)	
LAR with LLND	10 (34%)
ISR with LLND	6 (30%)
APR with LLND	7 (23%)
TPE	7 (23%)
Median surgical time, min (range)	787 (450-1041)
Median blood loss, ml (range)	147 (0-1170)

LLND: lymph node dissection LAR: low anterior resection APR: abdominoperineal resection  
ISR: intersphincteric resection TPE: total pelvic exenteration

Chi-square tests were used in the univariate analyses and p-values of <0.05 were considered statistically significant. JMP Pro 14.0 (SAS Institute, Cary, NC) was used to perform the statistical analyses.

## Results

### *Patients' characteristics (Table 1)*

Thirty patients with 60 half-pelvises were included. Twenty-one patients (70%) were male, and the median age was 67 (range: 47-78) years. Twenty-three (77%) patients were undergoing surgery for primary disease; 7 (23%) patients were undergoing surgery for recurrent disease. In addition, LAR, ISR, and APR with LLND were performed in 23 patients (77%) and the remaining 7 patients (23%) were analyzed by TPE. Bilateral LLND was performed in all patients.

### *Detection rates of the IIAs and IIVs, and their branches on surgical videos and CT-based 3D simulation (Figure 3)*

The SGA was identified by CT in all patients (100%), and on surgical videos in 58 half-pelvises (97%). The SGV was identified by CT and on surgical videos in 58 half-pelvises (97%) each. The identification rates of the SGA, SGV, IGA, IGV, ObA, ObV, IPA, and IPV by CT and on surgical videos are shown in the figure (Figure 3).

Remarkably, the IGA and IGV were not identified by surgical videos in more than half of the half-pelvises; CT findings were used in these cases. The IPV was identified by CT in 47 half-pelvises (78%) whereas it was detected on surgical video in all cases. Similarly, the ObV was identified

by CT in 44 half-pelvises (73%), while it was identified by surgical video in 58 cases (97%).

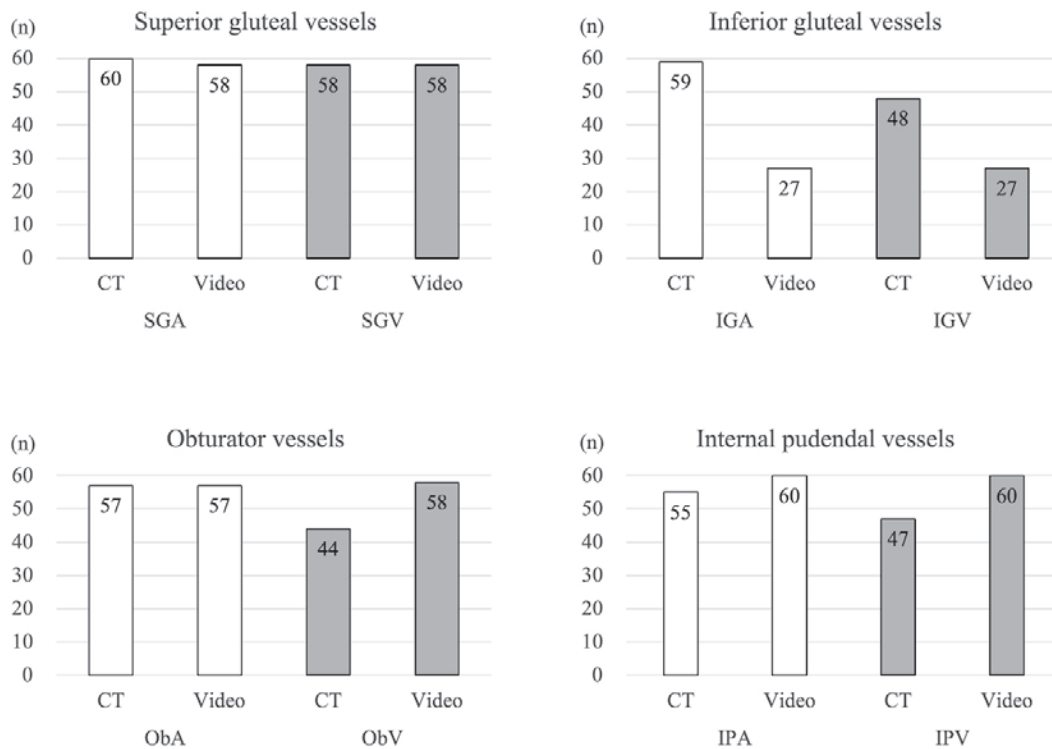
### *Comparison of the branch patterns of the IIA and IIV in the whole population (Figure 4)*

Figure 4 compares the branch patterns of IIAs and IIVs of the same name in the whole population. In 51 of 60 half-pelvises, the SGA (85%) branched from the IIA, and in 40 of 60 (67%) half-pelvises, the SGV branched from the IIV ( $p=0.06$ ). On the other hand, in 48 of 60 (80%) half-pelvises, the IGA branched from the IPA, and in 57 of 60 (95%) half-pelvises, the IGV branched from the IPV ( $p=0.03$ ). In addition, the ObA branched from the IIA, IPA, and SGA in 1 (2%), 52 (86%), and 7 (12%) half-pelvises, respectively, while the ObV branched from the IIV, IPV, and SGV in 7 (12%), 49 (81%) and 4 (7%) half-pelvises ( $p=0.02$ ). These outcomes demonstrated the branch patterns of the IIA and IIV. When compared to the whole population, the branches did not match.

### *Comparison of the branch patterns of the IIA and IIV in individual patients (Table 2)*

In 51 of 60 (85%) half-pelvises, the SGA branched from the IIA. In these 51 half-pelvises, the SGV branched from the IIV in 38 half-pelvises. Thus, in patients in whom the SGA branched from IIA, the SGV branched from the IIV in 38 of 51 (75%) half-pelvises.

Similarly, the IGA branched from the IPA in 48 of 60 (80%) half-pelvises. In all of these 48 (100%) half-pelvises, the IGV branched from the IPV. Thus, the IGV branched from the IPV in all patients in whom the IGA branched from the IPA.



**Figure 3.** The detection rate of IIA and IIV, and their branches on surgical videos and CT-based 3D simulation.

CT: computed tomography Video: Laparoscopic surgery video IIA: internal iliac artery IIV: internal iliac vein SGA: superior gluteal artery SGV: superior gluteal vein IGA: inferior gluteal artery IGV: inferior gluteal vein IPA: internal pudendal artery IPV: internal pudendal vein ObA: obturator artery ObV: obturator vein

In addition, the ObA branched from the IPA in 52 of 60 (87%) half-pelvises. Among these 52 half-pelvises, the ObV branched from the IPV in 42 half-pelvises. Thus, in patients in whom the ObA branched from the IPA, the ObV branched from the IPV in 42 of 52 (81%) half-pelvises.

These findings indicate that when arteries showed the most frequent branch patterns, there was a high degree of correlation between the branch patterns of the arteries and veins. On the other hand, in cases with rare artery branch patterns, the branch patterns of the arteries and veins did not match.

**Correlation of the branch patterns of the right and left IIV in the whole population (Figure 5)**

The SGV branched from the IIV on the right side in 16 of 30 patients and on the left side in 24 of 30 patients (p=0.06). On the other hand, the IGV branched from the IPV on the right side in 29 of 30 patients and on the left side in 28 of 30 patients. However, it branched from the IIV on the right side in one patient and from the SGV on the left side in 2 patients (p=0.08). The ObV branched from the IPV on the right side in 22 of 30 patients and on the left side in 27 of 30 patients; it branched from other veins in the remaining

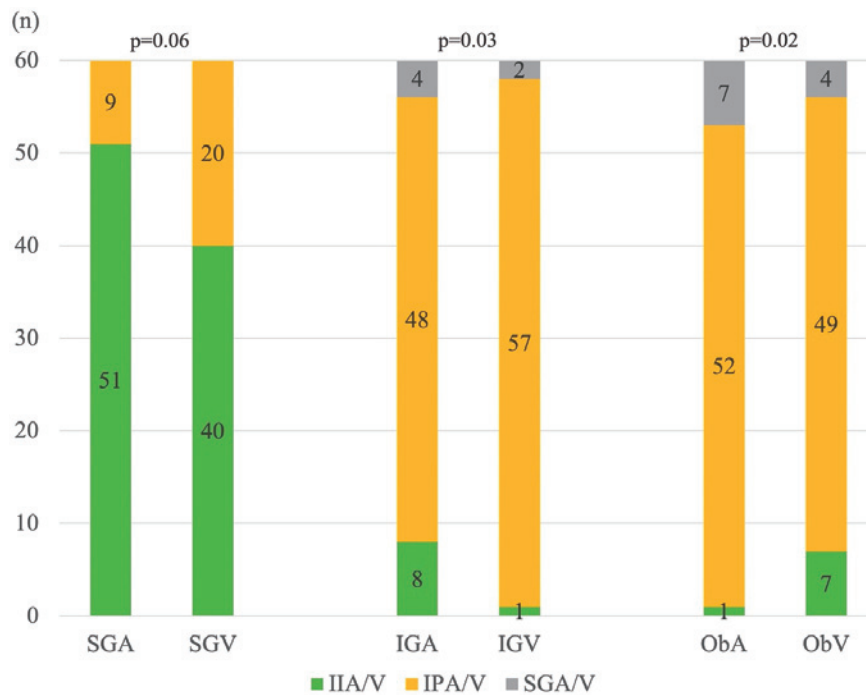
patients (p=0.25). These outcomes demonstrated that the branch patterns of the IIV on the right side and left side showed a low correlation in the whole population.

**Correlation of the branch patterns of right and left IIV in individual patients (Table 3)**

The right SGV branched from the IIV in 16 patients. Among these 16 patients, the SGV branched from the IIV on the left side in 13 patients (81%). Similarly, the IGV branched from the IPV on the right side in 29 patients. Among these 29 patients, the IGV branched from the IPV on the left side in 27 patients (93%). In addition, the ObV branched from the IPV on the right side in 22 patients. In these 22 patients, the ObV branched from the IPV on the left side in 21 patients (95%). Those findings indicate that in patients with the most frequent branch patterns of IIV, the branch patterns of the right and left IIV showed a good correlation.

**Adachi’s classification of arteries and veins (Figure 6, Supplementary Figure 1, Table 4)**

Adachi’s classification is often used for the classification of IIAs[21-25]. Thus, the present study classified the IIAs



**Figure 4.** Comparison of the branch patterns of the IIA and IIV in the whole population.

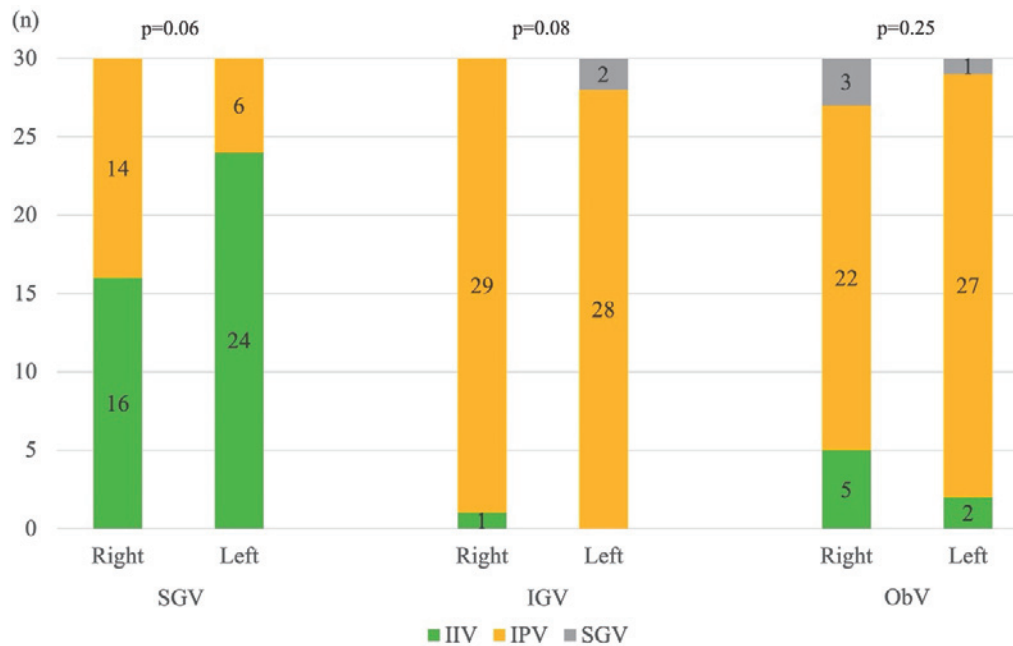
This figure compares the branch patterns of arteries and veins. These were not correlated. The SGA and SGV showed a trend towards correlation. Furthermore, there statistically significant differences were detected between the IGA and IGV and between the ObA and ObV.

IIA: internal iliac artery IIV: internal iliac vein SGA: superior gluteal artery SGV: superior gluteal vein IGA: inferior gluteal artery IGV: inferior gluteal vein IPA: internal pudendal artery IPV: internal pudendal vein ObA: obturator artery ObV: obturator vein

**Table 2.** Branch Patterns of the IIA and IIV in Individual Patients (n=60).

Artery	Vein	Correlation rate
SGA	IIA n=51 ⇨ SGV IIV n=38	⇨ 38/51 (75%)
	IPA n=9 ⇨ SGV IPV n=7	⇨ 7/9 (78%)
IGA	IIV n=2	
	IGA IIA n=8 ⇨ IGV IIV n=1	⇨ 1/8 (13%)
	IPV n=6	
ObA	SGV n=1	
	ObA IIA n=1 ⇨ ObV IIA n=0	⇨ 0/1 (0%)
	IPV n=3	
ObV	ObV IPA n=52 ⇨ ObV IPV n=42	⇨ 42/52 (81%)
	IIV n=7	
	SGV n=3	
ObV	ObV SGA n=7 ⇨ ObV SGV n=1	⇨ 1/7 (14%)
	IPV n=6	

IIA: internal iliac artery IIV: internal iliac vein SGA: superior gluteal artery SGV: superior gluteal vein IGA: inferior gluteal artery IGV: inferior gluteal vein IPA: internal pudendal artery IPV: internal pudendal vein ObA: obturator artery ObV: obturator vein



**Figure 5.** Comparison of the branch patterns between the right side and left side of the IIV in the whole population.

IIV: internal iliac vein SGV: superior gluteal vein IGV: inferior gluteal vein IPV: internal pudendal vein ObV: obturator vein

**Table 3.** Branch Patterns of the Right and Left Side of the IIV in Individual Patients (n=30).

	Right		Left	Correlation rate
SGV	IIV n=16	⇒	IIV n=13	13/16 (81%)
			IPV n=3	3/16 (19%)
IPV	IPV n=14	⇒	IIV n=11	11/14 (79%)
			IPV n=3	3/14 (21%)
IGV	IIV n=1	⇒	IIV n=0	0/1 (0%)
			IPV n=1	1/1 (100%)
IPV	IPV n=29	⇒	IPV n=27	27/29 (93%)
			SGV n=2	2/29 (7%)
ObV	IIV n=5	⇒	IIV n=2	2/5 (40%)
			IPV n=3	3/5 (60%)
	IPV n=22	⇒	IPV n=21	21/22 (95%)
			SGV n=1	1/22 (5%)
SGV	SGV n=3	⇒	IPV n=3	3/3 (100%)
			SGV n=0	0/3 (0%)

Correlation of branch patterns from the right to left side.

IIV: internal iliac vein SGV: superior gluteal vein IGV: inferior gluteal vein IPV: internal pudendal vein ObV: obturator vein

and IIVs according to Adachi’s classification (Supplementary Figure 1).

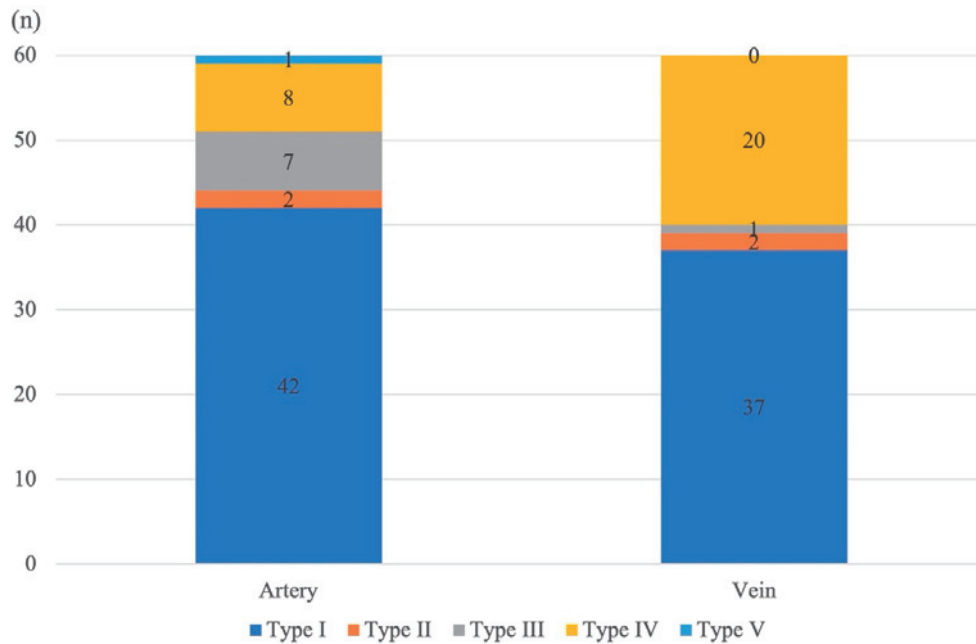
The most frequent pattern of the artery was Type I; this was observed in 42 of 60 half-pelvises (70%). The arteries of the remaining 18 (30%) half-pelvises were classified into various patterns. The most frequent pattern of veins was Type I, which was observed in 37 of 60 (62%) half-pelvises,

while 20 cases were classified as Type IV (Figure 6).

When the individual branches were divided, the veins were classified as Type I in 30 of 42 branches (71%) in which the arteries were classified as Type I (Table 4). For other Types (Type II, III, V) the rate of matching between artery and vein was ≤50%. This also indicates that when arteries showed the most frequent branch patterns (Type I), the branch patterns of the veins highly matched the patterns of the arteries. However, in cases with rare artery branch patterns (Type II, III, V), the branch patterns of the arteries did not match the branch patterns of the veins.

**Clinical outcomes for major and minor branch patterns of the vein (Table 5)**

In this study, 37 half-pelvises had veins of Adachi Type I (major branch patterns), and 23 half-pelvises had Types II, III, and IV (minor branch patterns). The clinical outcomes of the two groups were as follows: surgical time (median 125 min (range: 60-205 min) in major branch patterns vs. 106 min (range: 55-332 min) in minor branch patterns; p=0.32), blood loss (median 20 ml (range: 0-150 ml) in major branch patterns vs. median 10 ml (range: 0-110 ml) in minor branch patterns, p=0.57), fluid collection diagnosed by post-operative CT (19% in major branch patterns vs. 17% in minor branch patterns, p=0.92). There were no significant differences between the two groups.



**Figure 6.** Adachi's classification of arteries and veins.

**Table 4.** Correlation of Adachi's Classification in Individual Cases (n=60).

Artery	Vein	Correlation rate
Type I n=42	Type I n=30	30/42 (71%)
	Type IVa n=12	
Type II n=2	Type I n=1	1/2 (50%)
	Type II n=1	
Type III n=7	Type I n=4	1/7 (14%)
	Type II n=1	
	Type III n=1	
	Type IVa n=1	
Type IV n=8	Type I n=2	6/8 (75%)
	Type IV n=6	
Type V n=1	Type IVa n=1	0/1 (0%)
	Type V n=0	

Correlation of branch patterns from the artery to vein.

### Discussion

This study first investigated the branch patterns of the SGA and SGV, the IGA and IGV, the IPA and IPV, and the ObA and ObV. We found the most frequent branch patterns, with the IGV branching from the IPV in 57 of 60 half-pelvises (95%), and the ObV branching from the IPV in 49 of 60 (82%) half-pelvises (Figure 4). This is important information because the detection rates of the IGV and ObV on CT-based 3D simulation were 80% and 73% which is a relatively low score, respectively (Figure 3). Conversely, the routes of IGV and ObV were not observed on CT before surgery in approximately 20% of half-pelvises. The route of

the ObV is particularly important because it is routinely ligated when performing LLND. We should recognize that the ObV branches from the IPV, which is on the peripheral side of the umbilical artery, in over 80% of cases.

On the other hand, most SGAs branch from the IIA (85%), while more than 30% of SGVs branch from the IPV (Figure 4).

We also found that when the arteries showed the most frequent branch patterns (e.g., then SGA branches from the IIA, the IGA branches from the IPA, and the ObA branches from the IPA), the veins also showed the most frequent branch pattern (e.g., the SGV branches from the IIV, the IGV branches from the IPV, and the ObV branches from the IPV) (Table 2). In addition, in patients with the most frequent branch patterns, the right and left branch patterns of the IIV were well correlated (Table 3). This is clinically useful because the IIA and its branches are easy to identify pre-operatively by CT, and the branch patterns of veins were basically predictable in patients with the most frequent branch patterns of IIA. In addition, when performing LLND, after performing one side, the branch patterns of the IIV on the opposite side can be predicted. Certainly, some studies demonstrated the complex anatomy of IIVs and their branches[16-20]. However, the patterns of the IIV can basically be divided into two patterns: Adachi's classification Types I and IV. One reason for the complexity of the IIVs and their branches may be that many veins (e.g., the median sacral vein, lateral sacral vein, iliolumbar vein, and others) were not investigated in this study. Indeed, the anatomy of these veins would be complex; however, the branch patterns of the SGV, IGV and ObV can be simply summarized.



**Table 5.** Clinical Outcomes for Major and Minor Branch Patterns of Vein.

	Major branch patterns	Minor branch patterns	p value
Median surgical time for LLND, min (range)	125 (60-205)	106 (55-332)	0.32
Median blood loss for LLND, ml (range)	20 (0-150)	10 (0-110)	0.57
Fluid collection, cases (%)	7 (19)	4 (17)	0.92

LLND: lymph node dissection

We also found that veins could mainly be divided into two groups Adachi's classification Types I and IV (Figure 6, Supplementary Figure 2). Adachi's classification reflects the anatomical correlation among the IIA/IIV, IPA/IPV, SGA/SGV, and IGA/IGV. For veins, the IGV branched from the IPV (95%) in most half-pelvises, while 82% of ObVs branched from the IPV, which makes it simple to determine Adachi's classification of veins.

In this study, between major and minor branch patterns, there was no significant difference in surgical time, blood loss, or fluid collection (Table 5). Although further investigation is required, we consider that clarifying the branch patterns at surgery is useful for reducing blood loss and surgical time.

Finally, this study demonstrated the detection rates of the IIAs and IIVs, and their branches on surgical videos and CT-based 3D simulation. Indeed, the detection rate of arteries by CT-based 3D simulation was high. However, the detection rate of veins was not sufficient as the SGV was detected in 58 half-pelvises (97%), the IGV was detected in 48 half-pelvises (80%), the ObV was detected in 44 half-pelvises (73%), and the IPV was detected in 47 half-pelvises (78%). On the other hand, in the surgical videos, the SGV was detected in 58 half-pelvises (97%), the ObV was detected in 58 half-pelvises (97%), and the IPV was detected in 60 half-pelvises (100%). This high rate of detection by surgical video would be influenced by our surgical approach, and our LLND approach wherein the inner and outer sides of the IIVs and their branches were dissected to the peripheral side. These approaches not only prevent bleeding but also promote the anatomical understanding of the lateral pelvic area.

The present study was associated with some limitations. First, the frequency of brunch patterns based on the Adachi's classification in our study was slightly different from previous reports provably because this single-center study included limited number of patients. Second, this study focused on the main branch of each vessel, and some cases have two or three branches of each vessel. However, if we considered these vessels, the anatomical picture of the IIA and IIV would be confusing. Thus, the present study only focused on the main branch of each vessel. Finally, this was not blind study, however two experienced surgeons, both specializing in pelvic surgery, carefully reviewed the CT im-

ages to determine the branch pattern.

In conclusion, this first study to clarify the distal branch patterns of the IIV based on surgical findings combined with 3D simulation clearly showed that branch patterns of IIV have the same pattern of IIA, and that the right and left IIV have the same patterns in patients with the most frequent branch patterns of IIV. We believe that this will help to secure the safety and to achieve the standardization of pelvic surgery by MIS.

#### Conflicts of Interest

There are no conflicts of interest.

#### Author Contributions

Y. Takenaka: Project development, Data collection, Data management, Data analysis, Manuscript writing

N. Beppu: Project development, Data collection, Data analysis, Manuscript editing

M. Otani, K. Ito, A. Imada, T. Matsubara, J. Song, K. Kimura, K. Kataoka: Data collection

M. Uchino, H. Ikeuchi: Manuscript editing

M. Ikeda: Project development, Manuscript editing

#### Approval by Institutional Review Board (IRB)

Approval was granted by the Ethics Committee of Hyogo Medical University (Date20200406/No.202006-014).

#### References

- Guillou PJ, Quirke P, Thorpe H, et al. Short-term endpoints of conventional versus laparoscopic-assisted surgery in patients with colorectal cancer (MRC CLASICC trial): multicentre, randomised controlled trial. *Lancet*. 2005 May; 365(9472): 1718-26.
- Green BL, Marshall HC, Collinson F, et al. Long-term follow-up of the medical research council CLASICC trial of conventional versus laparoscopically assisted resection in colorectal cancer. *Br J Surg*. 2013 Jan; 100(1): 75-82.
- Lacy AM, Delgado S, Castells A, et al. The long-term results of a randomized clinical trial of laparoscopy-assisted versus open surgery for colon cancer. *Ann Surg*. 2008 Jul; 248(1): 1-7.
- Fleshman J, Sargent DJ, Green E, et al. The Clinical Outcomes of Surgical Therapy Study Group Laparoscopic colectomy for cancer is not inferior to open surgery based on 5-year data from the COST study group trial. *Ann Surg*. 2007 Oct; 246(4): 655-62.
- Colon Cancer Laparoscopic or Open Resection Study Group; Buunen M, Veldkamp R, Hop WC, et al. Survival after laparo-

- scopic surgery versus open surgery for colon cancer: long-term outcome of a randomised clinical trial. *Lancet Oncol.* 2009 Jan; 10(1): 44-52.
6. Yamamoto S, Inomata M, Katayama H, et al. Short-term surgical outcomes from a randomized controlled trial to evaluate laparoscopic and open D3 dissection for stage II/III colon cancer: Japan clinical oncology group study JCOG 0404. *Ann Surg.* 2014 Jul; 260(1): 23-30.
  7. Japanese Society for Cancer of the Colon and Rectum. General Rules for Clinical and Pathological Studies on Cancer of the Colon, Rectum, and Anus. 9th ed. Tokyo: Kanehara Shuppan.
  8. Malakorn S, Yang Y, Bednarski BK, et al. Who should get lateral pelvic lymph node dissection after neoadjuvant chemoradiation? *Dis Colon Rectum.* 2019 Oct; 62(10): 1158-66.
  9. Perez RO, São Julião GP, Vailati BB, et al. Lateral node dissection in rectal cancer in the era of minimally invasive surgery: a step-by-step description for the surgeon unacquainted with this complex procedure with the use of the laparoscopic approach. *Dis Colon Rectum.* 2018 Oct; 61(10): 1237-40.
  10. Malakorn S, Ouchi A, Sammour T, et al. Robotic lateral pelvic lymph node dissection after neoadjuvant chemoradiation: view from the West. *Dis Colon Rectum.* 2018 Sep; 61(9): 1119-20.
  11. Kim MJ, Oh JH. Lateral lymph node dissection with the focus on indications, functional outcomes, and minimally invasive surgery. *Ann Coloproctol.* 2018 Oct; 34(5): 229-33.
  12. Konishi T, Kuroyanagi H, Oya M, et al. Lateral lymph node dissection with preoperative chemoradiation for locally advanced lower rectal cancer through a laparoscopic approach. *Surg Endosc.* 2011 Jul; 25(7): 2358-9.
  13. Park JS, Choi GS, Lim KH, et al. Laparoscopic extended lateral pelvic node dissection following total mesorectal excision for advanced rectal cancer: initial clinical experience. *Surg Endosc.* 2011 Oct; 25(10): 3322-9.
  14. Liang JT. Technical feasibility of laparoscopic lateral pelvic lymph node dissection for patients with low rectal cancer after concurrent chemoradiation therapy. *Ann Surg Oncol.* 2011 Jan; 18(1): 153-9.
  15. Furuhashi T, Okita K, Nishidate T, et al. 2015. Clinical feasibility of laparoscopic lateral pelvic lymph node dissection following total mesorectal excision for advanced rectal cancer. *Surg Today.* 2015 Mar; 45(3): 310-4.
  16. Chong GOH, Lee YH, Hong DGY, et al. Anatomical variations of the internal iliac veins in the presacral area: clinical implications during sacral colpopexy or extended pelvic lymphadenectomy. *Clin Anat.* 2015 Jul; 28(5): 661-4.
  17. Cardinot TM, Aragão AHB, Babinski MA, et al. Rare variation in course and affluence of internal iliac vein due to its anatomical and surgical significance. *Surg Radiol Anat.* 2006 Aug; 28(4): 422-5.
  18. Kanjanasilp P, Ng JL, Kajohnwongsatit K, et al. Anatomical variations of iliac vein tributaries and their clinical implications during complex pelvic surgeries. *Dis Colon Rectum.* 2019 Jul; 62(7): 809-14.
  19. Shin M, Lee JB, Park SB, et al. Kim Multidetector computed tomography of iliac vein variation: prevalence and classification. *Surg Radiol Anat.* 2015 Apr; 37(3): 303-9.
  20. Hamabe A, Harino T, Ogino T, et al. Analysis of anatomical variations of intrapelvic vessels for advanced pelvic surgery. *BMC Surg.* 2020 Mar; 20(1): 47.
  21. Beppu N, Song J, Takenaka Y, et al. Laparoscopic lateral pelvic lymph node dissection combined with removal of the internal iliac vessels in rectal cancer: how to standardize this surgical procedure. *Tech Coloproctol.* 2021 May; 25(5): 579-87.
  22. Watanabe K, Shoja MM, Loukas M, et al. Buntaro Adachi (1865-1945): Japanese master of human anatomic variation. *Clin Anat.* 2012 Nov; 25(8): 957-60.
  23. Braithwaite JL. Variations in origin of the parietal branches of the internal iliac artery. *J Anat.* 1952 Oct; 86(4): 423-30.
  24. Roberts WH, Krishingner GL. Comparative study of human internal iliac artery based on Adachi classification. *Anat Rec.* 1967 Jun; 158(2): 191-6.
  25. Sakthivelavan S, Aristotle S, Sivanandan A, et al. Variability in the branching pattern of the internal iliac artery in Indian population and its clinical importance. *Anat Res Int.* 2014 Dec; 2014: 597103.

### Supplementary Files

#### Supplementary Figure 1. Adachi's classification.

Red double line indicates the level of the umbilical artery.

S: superior gluteal artery I: inferior gluteal artery P: internal pudendal artery

#### Supplementary Figure 2. Major vein branch patterns.

Most frequent type: the SGV branched from the IIV, the IGV and ObV branched from the IPV. Second frequent type: the SGV, IGV and ObV branched from the IPV. Red double line indicates the level of the umbilical artery. S: superior gluteal vein O: obturator vein I: inferior gluteal vein

Please find supplementary file(s);

<http://dx.doi.org/10.23922/jarc.2022-066>

Journal of the Anus, Rectum and Colon is an Open Access journal distributed under the Creative Commons Attribution-NonCommercial-NoDerivatives 4.0 International License. To view the details of this license, please visit (<https://creativecommons.org/licenses/by-nc-nd/4.0/>).