

Pediatrics

Acute Lobar Nephronia in an infant presented as a renal tumor

Yasir Masood^a, Ijaz Hussain^a, Ubaid ullah khan^b, Musab Umair Khalid^{b,*},
Muhammad Usman Javed^b

^a Shifa International Hospital Islamabad, Pakistan

^b Armed Forces Institute of Urology Rawalpindi, Pakistan



ARTICLE INFO

Keywords:

acute lobar nephronia
renal mass
pediatric tumors
Wilms' tumor
acute bacterial focal nephritis.

ABSTRACT

A case report of a 02-month-old infant referred to us with incidental bilateral renal masses on ultrasound, which was reported as nephroblastoma/Wilms tumor on CT scan, no signs, and symptoms of infection. Urine and blood cultures were negative, which led to a percutaneous renal biopsy which showed Acute Lobar Nephronia. The infant was started intravenous antibiotics which resulted in the resolution of bilateral renal masses on serial ultrasounds.

Introduction

Acute lobar nephronia (ALN) is a rare inflammatory condition that is characterized by interstitial bacterial infection of the parenchyma of the kidneys. First described by Rosenfield et al., in 1979, the first case in children was reported in 1985.^{1,2} Since then it is often misdiagnosed as renal tumors on ultrasound and CT scan. Mistreatment can lead to deleterious effects on children as compared to ALN which can be treated with a short course of antibiotics. A correct diagnosis is usual made with biopsy during open surgery for a renal tumor or percutaneous biopsy.

Here I present a case report of Acute Lobar nephronia presented to us as nephroblastoma/Wilms tumor.

Case report

A 02-month-old infant was referred to us by a pediatrician with incidental finding of bilateral renal masses on ultrasound followed by a CT scan without contrast reported as nephroblastoma/Wilms tumor. He had an episode of fever 02 weeks ago, treated partially by the local general practitioner with antibiotics, afebrile now and irritable, tolerating oral feeding. No family history of any malignancy, Examination was unremarkable except left palpable renal mass, non-tender.

Investigation was ordered, his total leucocyte count was 19,900 with 52% neutrophils, Hemoglobin was 11.1 and C-reactive protein was 19.1. The rest of the investigation was normal. Blood culture and urine culture were sent which came back negative for any growth. CT scan with contrast was done, which was reported as nephroblastoma/Wilms tumor

as the differential diagnosis (Fig. 1).

Keeping in mind the differential diagnosis, ultrasound-guided needle biopsy of the renal mass was done, histopathology showed an abundance of neutrophils with an inflammatory process, no evidence of malignancy was found.

The patient was started on IV antibiotics for 01 week followed by oral antibiotics for 3 weeks and followed with serial ultrasounds weekly. A gradual decrease in the size of renal masses were noted on the serial ultrasounds.

DMSA was done after 06 weeks to confirm and see the scarring of the kidneys. DMSA scan showed the photopenic area at the upper pole of the right kidney and middle of the left kidney (Fig. 2). Which indicates the loss of nephrons in this area due to scarring. Now the patient is on follow up to check the recurrence or progression to a renal abscess.

Discussion

Acute lobar nephronia (ALN), also termed as acute focal nephritis or acute focal bacterial nephritis, is a non-liquefactive localized severe infection of the interstitium of the parenchyma of the kidney involving one or more of the renal lobes. ALN was first described in adults by Rosenfield et al., in 1979 and was subsequently reported in children by Lawson et al., in 1985.^{1,2}

Wilms tumor is a very rare cancer of the kidney that mostly occurs in childhood. It has a prevalence of 1 in 10000 among children. It occurs due to mutation in Wilms tumor 1 (WT1) or Wilms tumor 2 (WT2) genes. The tumor is malignant. Nephrectomy is the sole treatment option and is

* Corresponding author.

E-mail addresses: ubaidkhandr@gmail.com (U. khan), musabumair923@gmail.com (M.U. Khalid).

<https://doi.org/10.1016/j.eucr.2020.101450>

Received 9 September 2020; Received in revised form 7 October 2020; Accepted 11 October 2020

Available online 16 October 2020

2214-4420/© 2020 The Authors.

Published by Elsevier Inc.

This is an open access article under the CC BY-NC-ND license

(<http://creativecommons.org/licenses/by-nc-nd/4.0/>).

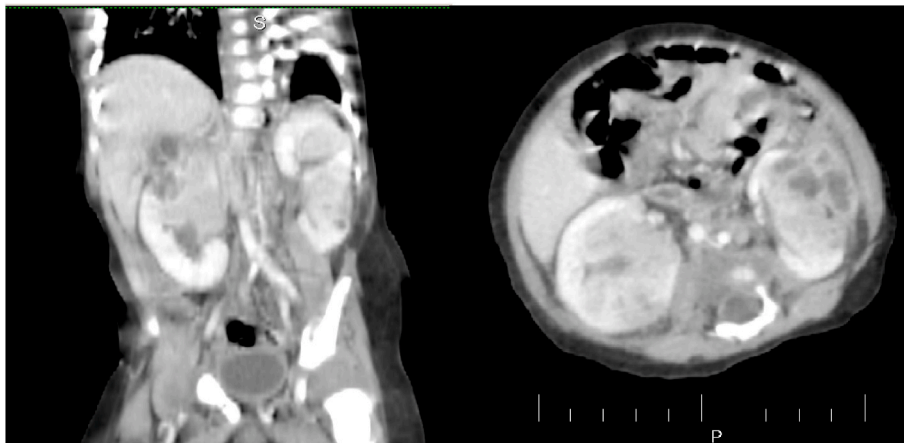


Fig. 1. Contrast enhanced CT abdomen showed bilateral renal masses.

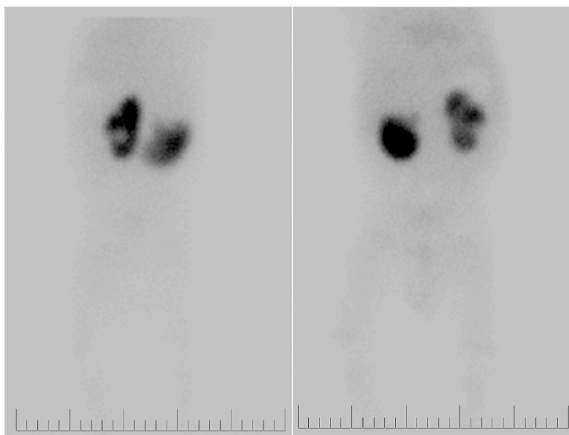


Fig. 2. DMSA scan.

curative with 5-year post survival rate around 90%.

Most of the wilm's tumors are unilateral, only 5% are bilateral prognosis of bilateral wilm's tumor has improved over time but it is poorer compared to unilateral wilm's tumor. It has a survival rate of 63% which is considerably less than the unilateral tumor.

The clinical presentations of ALN include fever, flank pain, leukocytosis, pyuria, and bacteriuria, in most of the cases, which are similar to those with renal abscess or acute pyelonephritis. The blood parameters are similar to that of any systemic infections with neutrophilic leukocytosis and high CRP levels. The blood and urine cultures may or may not be negative.³

Imaging has a critical role in the management of the disease. Ultrasound is the gold standard in identifying the nature of the lesion, consistency, liquefaction, perinephric extension, the inflamed thick renal

capsule, perinephric space collection, involvement of hilum can be ascertained by ultrasonography.⁴

Computed tomography (CT) is considered to be the most sensitive and accurate imaging modality for the diagnosis of ALN. CT scan with IV contrast has got better anatomical delineation providing more information on the lesion aspects, which goes in favor of ALN. The lesion presents as focal or global enlargement of the kidney. The cortico-medullary differentiation is essentially blunted by edema with calyceal effacement.⁵

The role of a DMSA scan is important in the follow-up of the cases. It provides us with the information of photopenic areas in the kidney which eventually leads to renal scarring and progression of the lesion into pyelonephritis. There is a decrease in the risk of any significant complications following renal mass biopsy. Additionally, biopsies performed using fine needles have shown to be more accurate, probably due to the improvement in the cytological techniques that have allowed a better and more accurate diagnosis of benign and malignant masses.

Once diagnosed, ALN can be treated simply with a course of IV and oral antibiotics as compared to a renal tumor, often misreported, has a long term treatment regimen with deleterious side effects. Other differentials of ALN are nephrogenic rest, nephroblastoma, and xanthogranulomatous pyelonephritis.

References

1. Rosenfiled AT, Gilckman MG, Taylor KJ, Crade M, Hodson J. Acute focal bacterial nephritis (acute lobar nephronia). *Radiology*. 1979;132:553–561.
2. Lawson GR, White FE, Alexander FW. Acute focal bacterial nephritis. *Arch Dis Child*. 1985;60:475e7.
3. Cheng CH, Tsau YK, Lin TY. Effective duration of antimicrobial therapy for the treatment of acute lobar nephronia. *An Pediatr*. 2006;117:E84–E89.
4. Vijayakumar M, Prahlad N, Nandhini G, Prasad N, Muralinath S. Child with acute lobar nephronia. *Indian J Nephrol*. 2010;20:162–165.
5. Piccoli G, Colla L, Maass J, et al. Acute pyelonephritis: a new approach to an old entity. *J Nephrol*. 2005;18:474–496.