



## Original article

# Acute distal biceps ruptures: single incision repair by use of suture anchors<sup>☆</sup>



Rafael Almeida Maciel\*, Priscilla Silva Costa, Eduardo Antônio Figueiredo, Paulo Santoro Belangero, Alberto de Castro Pochini, Benno Ejnisman

Universidade Federal de São Paulo, Departamento de Ortopedia e Traumatologia, Centro de Traumatologia do Esporte, São Paulo, SP, Brazil

## ARTICLE INFO

## Article history:

Received 27 January 2016

Accepted 31 May 2016

Available online 9 March 2017

## Keywords:

Elbow/surgery

Elbow/injuries

Treatment outcome

## ABSTRACT

**Objective:** Clinical and functional assessment of the surgical treatment for acute injury of the distal insertion of the biceps brachial performed with a surgical technique using a single incision in proximal forearm and fixation with suture anchors in the radial tuberosity.

**Methods:** This study reviewed the medical records of patients who underwent surgical treatment of distal biceps injury during the period between January 2008 and July 2014. In a mean follow-up of 12 months, 22 patients with complete and acute injury, diagnosed through physical examination and imaging studies, were functionally assessed in the postoperative period regarding the range of motion (degrees of flexion-extension and pronation-supination), the presence of pain (VAS), the Andrews-Carson-score, and the Mayo Elbow Performance Score (MEPS).

**Results:** During the postoperative follow-up assessment, no patient reported pain by VAS scale; all were satisfied with the esthetic appearance of the surgery. The range of articular movement remained unchanged at 95.4% of patients, with the loss of 8° of supination in one patient. No changes in muscle strength were observed. The results of the Andrews-Carson score were good in 4.6% and excellent in 95.4% of cases; the MEPS presented 100% of excellent results. The rate of complications was 27.2%, similar to the literature.

**Conclusion:** Surgical repair of acute injury of the distal biceps through a single incision in the proximal forearm and fixation with two suture anchors in the radial tuberosity is an effective and safe therapeutic option, allowing early motion and good functional results.

© 2016 Sociedade Brasileira de Ortopedia e Traumatologia. Published by Elsevier Editora Ltda. This is an open access article under the CC BY-NC-ND license (<http://creativecommons.org/licenses/by-nc-nd/4.0/>).

<sup>☆</sup> Study conducted at the Universidade Federal de São Paulo, Departamento de Ortopedia e Traumatologia, Centro de Traumatologia do Esporte, Grupo de Ombro e Cotovelo, São Paulo, SP, Brazil.

\* Corresponding author.

E-mail: [rafaelalmeidamaciel@gmail.com](mailto:rafaelalmeidamaciel@gmail.com) (R.A. Maciel).

<http://dx.doi.org/10.1016/j.rboe.2017.03.004>

2255-4971/© 2016 Sociedade Brasileira de Ortopedia e Traumatologia. Published by Elsevier Editora Ltda. This is an open access article under the CC BY-NC-ND license (<http://creativecommons.org/licenses/by-nc-nd/4.0/>).

## Lesão do bíceps distal aguda: reparo por via única e fixação por âncora de sutura

### R E S U M O

#### Palavras-chave:

Cotovelo/cirurgia

Cotovelo/lesões

Resultado de tratamento

**Objetivo:** Avaliação clínica e funcional do tratamento cirúrgico da lesão aguda da inserção distal do bíceps braquial pela técnica cirúrgica por via de acesso única no antebraço proximal e fixação com âncoras de sutura na tuberosidade radial.

**Método:** Estudo feito por meio da revisão dos prontuários de pacientes submetidos a tratamento cirúrgico de lesão da inserção distal do bíceps braquial entre janeiro de 2008 e julho de 2014. Em um seguimento médio de 12 meses, 22 pacientes com lesão completa e aguda, diagnosticados por exame físico e exames de imagem, foram avaliados funcionalmente no pós-operatório por meio da mensuração da amplitude de movimentos (graus de flexoextensão e pronosupinação), pela presença de dor (EVA) e pelas escores de Andrews-Carson e Mayo Elbow Performance Score (MEPS).

**Resultados:** Durante a avaliação dos pacientes no seguimento pós-operatório, nenhum paciente referia dor pela escala EVA e todos estavam satisfeitos com a aparência estética da cirurgia. A amplitude de movimento articular encontrava-se inalterada em 95,4% dos pacientes, com a perda de 8° de supinação em um paciente. Os resultados segundo o escore de Andrews-Carson foram bons em 4,6% e excelentes em 95,4% dos casos; no MEPS, observaram-se 100% de resultados excelentes. A taxa de complicações foi de 27,2%, valor semelhante aos dados da literatura.

**Conclusão:** O tratamento cirúrgico das lesões agudas do bíceps distal por via única com fixação com o uso de duas âncoras de sutura mostrou-se uma opção terapêutica segura e eficaz, permitiu movimentação precoce e bons resultados clínicos e funcionais.

© 2016 Sociedade Brasileira de Ortopedia e Traumatologia. Publicado por Elsevier Editora Ltda. Este é um artigo Open Access sob uma licença CC BY-NC-ND (<http://creativecommons.org/licenses/by-nc-nd/4.0/>).

## Introduction

Injuries of the distal insertion of the biceps brachii are uncommon, with an incidence of 1.2 per 100,000 patients per year.<sup>1</sup> The most common mechanism of injury is characterized by an eccentric muscle contraction, with the elbow flexed at 90° and the forearm in supination, occurring predominantly in the dominant upper limb of males around 40–50 years.<sup>2</sup>

Surgical treatment is superior to conservative approach regarding clinical and functional results. Conservative treatments usually lead to muscle weakness, mobility disorders, and esthetic deformities.<sup>3,4</sup>

Numerous surgical techniques are reported for the reinsertion of distal biceps, through double or single access route, with different fixation methods, among which the most commonly used are bone tunnel, interference screw, endobutton, and suture anchor.<sup>5</sup> Clinical studies have demonstrated the advantages of single access route, with excellent results in repairs using suture anchors.<sup>6,7</sup>

This study aimed to describe a minimally invasive surgical technique for repair of the distal biceps tendon through two double-loaded suture anchors, as well as to describe its clinical and functional results.

## Material and methods

This study reviewed the medical records of patients who underwent surgical treatment of distal biceps brachii

insertion injury during the period between January 2008 and July 2014.

At first, 39 cases of distal biceps injury were retrieved. Inclusion criteria were distal, isolated and closed biceps lesion; less than six weeks between injury and surgical treatment; use of the same surgical technique; and a minimum postoperative follow-up of six months. Exclusion criteria were partial and chronic injuries of the distal biceps tendon; surgical technique with double access route; fixation material other than suture anchors; use of graft for tendon fixation; and postoperative follow-up of less than six months. Thus, after reviewing charts, 22 patients were included in the present study (Table 1).

Lesions were diagnosed by physical examination (hook test) and imaging (magnetic resonance imaging [MRI] or ultrasound) confirming a complete rupture of the distal insertion of the biceps.

Patients were assessed regarding range of motion with a goniometer, which measured the degrees of flexion-extension and pronosupination, and presence of pain, assessed by the visual analog scale (VAS); the Andrews-Carson<sup>8</sup> and the Mayo Elbow Performance Score (MEPS) scores were applied.<sup>9</sup>

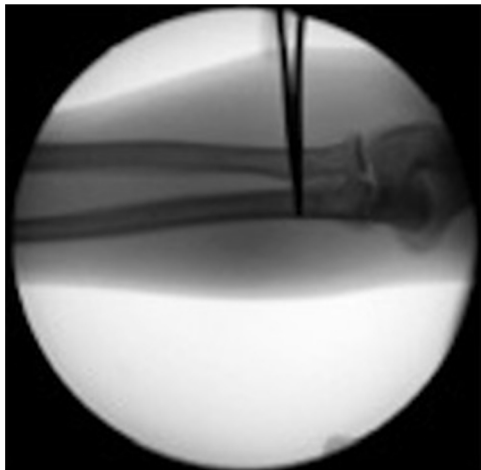
All patients signed an informed consent form prior to their participation in this study, which was submitted to the evaluation and approval of the Ethics Committee for Research in Human Beings.

## Surgical technique

All patients were positioned in horizontal dorsal decubitus position; the affected upper limb was prepared without a

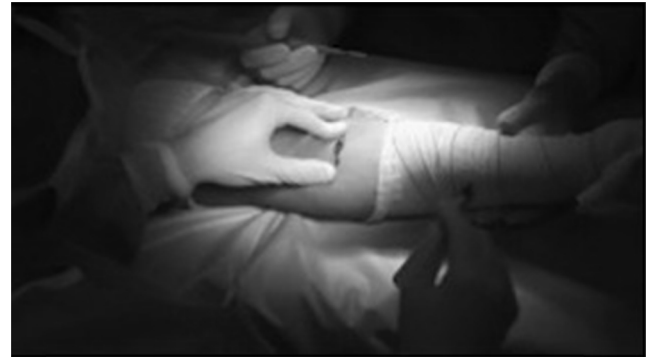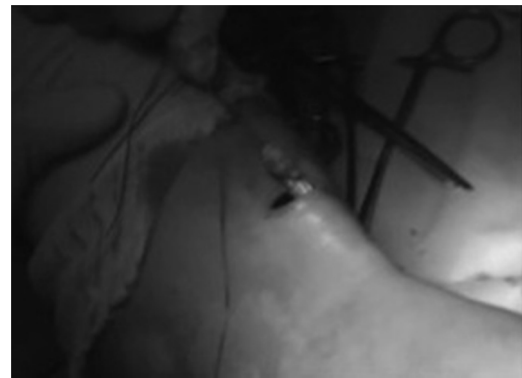**Table 1 – Epidemiological data of patients with acute injury of the distal biceps brachii insertion.**

	Age	Sex	Dominance
1	53	M	+
2	35	M	
3	43	M	+
4	31	M	+
5	39	M	+
6	67	M	+
7	65	M	+
8	37	M	+
9	61	M	+
10	42	M	+
11	47	M	+
12	40	M	
13	38	M	+
14	64	M	+
15	35	M	+
16	41	M	
17	56	M	+
18	55	M	+
19	36	M	
20	28	M	+
21	38	M	+
22	43	M	+

**Fig. 1 – Intraoperative location of the radial tuberosity, using radioscopy.**

tourniquet, as the authors believe that the use of a tourniquet increases the difficulty of the procedure by limiting the mobilization of the distal biceps tendon.

A single access route was created approximately 2.5 cm from the cubital flexion crease, guided by fluoroscopy for initial location of the radial tuberosity on its ulnar edge (Fig. 1). A 5-cm surgical incision in the anterior region of the proximal third of the forearm, at the radial tuberosity, in the transverse plane, with careful dissection of soft tissues, allowed the search in the superficial plane for the distal biceps tendon stump, proximally retracted (Fig. 2). Traction sutures were passed through the biceps tendon in its tendinous portion to enable its mobilization and re-approximation at its anatomical insertion, at the ulnar edge of the radius, with the forearm in complete supination and at 10° of elbow flexion (Fig. 3). The

**Fig. 2 – Single access route.****Fig. 3 – Traction suture in the ruptured distal biceps tendon.**

soft tissue and the lacertus fibrosus were released to allow increased mobility when necessary. The radial tuberosity was exposed by delicately displacing soft tissues, thus avoiding neurological and vascular injury. Then, the radial tuberosity was debrided for removal of residual tendon tissue and scarring, in order to allow bleeding, aiming to potentiate adhesion of the reinsertion.

Two 3-mm suture anchors, loaded with high-resistance filaments, were positioned in the radial tuberosity, aligned (one proximal and one distal), with approximately 1 cm distance between them. Two independent sutures were passed through the regularized distal stump, with self-locking stitches, to allow the tendon to be re-attached to the bone (Fig. 4). The distal anchor repair was fixated first to establish the length of the tendon; then, proximal anchor repairs were fixated, which allowed the tendon footprint to be recreated maximizing tendon-bone contact area.

Stability of the repair was confirmed under direct visualization, with evaluation of the biceps brachii tendon tension. Wound was then stitched, with approximation of the subcutaneous tissue and sterile dressing.

## Results

The present study included 22 patients with acute and complete injury of the distal biceps brachii insertion. All patients were male, with a mean age of 45 years (28–67). Dominant limb was affected in 18 cases (81.8%).



**Fig. 4 – Self-locking stitch to allow the tendon to be re-approximated to the bone.**

All patients presented elbow flexion against resistance with the forearm in supination as the mechanism of trauma; only two occurred during sports training. All patients underwent physical examination with hook test, which was found to be positive in 19 patients (86.3%). The following complementary exams were requested: elbow radiographs (front and profile) in all cases; 14 elbow MRIs (63.6%); and eight ultrasounds (36.3%) for confirmation and assessment of the elbow lesion.

Mean time between injury and surgery was eight days (1–35).

Mean follow-up was 12 months (6–18). During postoperative follow-up assessment, no patient reported pain by VAS scale; all were satisfied with the esthetic appearance of the surgery. Range of motion remained unchanged at 95.4% of patients, with loss of 8° of supination in one patient. Results of the Andrews-Carson score were good in 4.6% and excellent in 95.4% of cases; MEPS presented excellent results in 100%.

In the present sample, a complication rate of 27.2% was observed. Six cases were reported: four patients presented neuropraxia of the lateral cutaneous nerve of the forearm; one, radial neuropraxia; and one, partial loss of ROM, but without clinical repercussions during daily activities and with improvement in clinical follow-up.

Return to activity and the practice of sports occurred in three months, at the same level as before injury.

## Discussion

Distal biceps tendon ruptures represent 3% of biceps ruptures.<sup>10</sup> However, a recent study by Safran and Graham<sup>1</sup> showed an approximate incidence of 10%. It occurs preferentially in males in the fifth and sixth decades of life, mostly in the dominant limb, and trauma mechanism is mainly an eccentric biceps contraction on a flexed elbow. In the present study, only male patients were included, with a mean age of 45 years, involvement of the dominant side in 86% of the lesions, analogous to the literature data.<sup>3</sup>

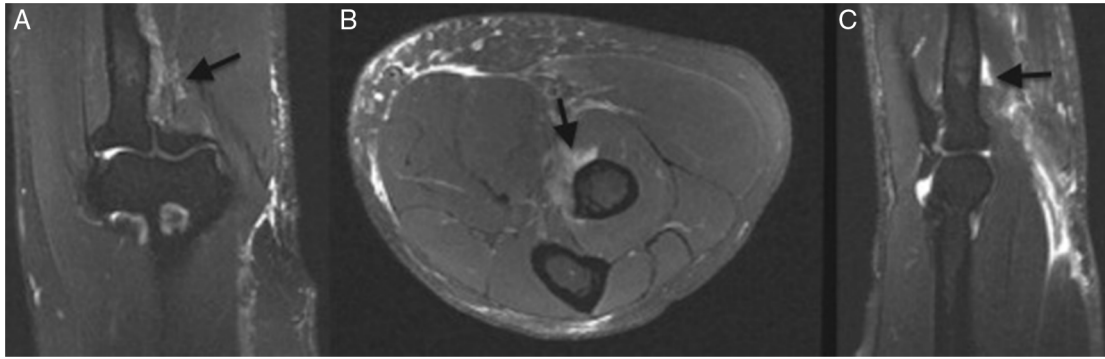
Diagnostic evaluation of acute distal biceps injury is initiated by medical history and physical examination, with

specific tests such as the hook test. Based on clinical history, with reports of the main trauma mechanism by eccentric contraction, followed by clinical development of pain, edema, and ecchymoses in the cubital fossa, as well as a positive hook test, we can establish distal biceps injury as the main diagnostic hypothesis. In the literature, the hook test presents a sensitivity and specificity of 100%.<sup>11</sup> Nonetheless, complete rupture, degree of retraction of the tendon stump, and presence of associated lesions were confirmed through additional tests. Ultrasonography allows identification of lesion as partial or complete, with studies showing 95% sensitivity and 71% specificity. It is also possible to determine degree of retraction of the tendon stump.<sup>12</sup> This exam is inexpensive and easy to perform in Brazil; therefore, it was used in 40% of the sample. MRI is considered the gold standard exam for definitive diagnosis; it also aids surgical planning and discards associated lesions.<sup>13</sup> Thus, this method was preferred and applied in 60% of the present cases (Fig. 5).

The best treatment for distal biceps injuries, whether conservative or surgical, is no longer questioned in the literature.<sup>14</sup> Conservative treatment results in muscle weakness, with loss of supination force of approximately 40% and flexion force of approximately 30%, as well as restrictions in activities of daily living.<sup>4</sup> Thus, the authors agree with the literature, reserving conservative modality for patients who cannot be submitted to surgery and elderly patients with low functional demands.<sup>4,14</sup>

Surgical treatment is the chosen approach and should be performed as early as possible; a period of up to six weeks has been established, as it allows recovery and mobilization of the retracted distal biceps tendon and, thus, allows anatomical fixation of the tendon in the radial tuberosity. Another important factor is to avoid closure of the space previously occupied by the tendon to the place of its insertion, by fibrous tissue and/or pseudotendon. This closure leads to changes in local anatomy, caused by adhesions and local fibrosis, hindering safe exposure and the identification and protection of noble structures, especially the lateral cutaneous nerve of the forearm. The lateral cutaneous nerve is located laterally to the distal biceps tendon, close to the radial tuberosity; it may be affected in both rupture and surgical reinsertion, being responsible for the most frequent complication in this type of procedure.<sup>3,15,16</sup> Therefore, the present approach allows for a safe dissection of soft tissues; the tunnel of the distal biceps tendon can be visualized, with tendon excursion to its reinsertion point. This reduces the risk of neurological injuries, which reduces the rates of complications related to the time period between injury and surgical repair. This approach also allows restoration of forearm supination force and elbow flexion to near pre-injury level.<sup>6</sup>

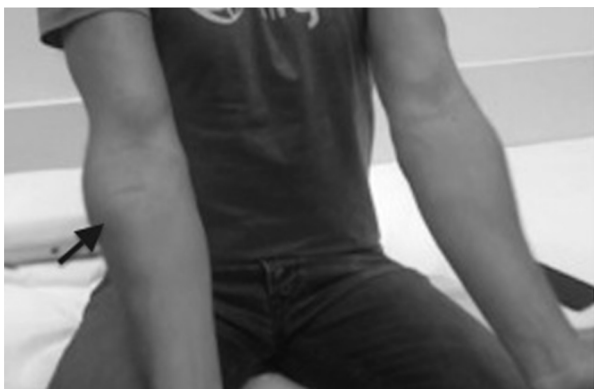There is no consensus in the literature regarding best approach and best method of fixation for distal biceps ruptures, and there are many possibilities. Grewal et al.,<sup>17</sup> in their randomized clinical trial, observed no difference in results when comparing single and double access routes. In 2014, a systematic review by Watson et al.<sup>18</sup> found small differences, although not statistically significant, when comparing rates of complications between these routes; the authors stated that more research was needed. The authors opted for a single access route, created 2.5 cm from the cubital fold, 5-cm long



**Fig. 5 – T2-weighted magnetic resonance imaging of the forearm after injury, with fat suppression, showing complete rupture of the distal biceps (arrows). A, coronal cut; B, axial cut; C, sagittal cut.**

with transverse orientation, as this approach provides excellent visualization of the radial tuberosity, allows resection of the stump of the distally-retracted ruptured tendon and limited dissection of soft parts, reduces the risks of complications, and has a better esthetic result (Fig. 6). The choice of a single access route on the radial tuberosity, in which the correct forearm positioning for maximum supination and semi-flexion for the reinsertion of the distal tendon of the biceps are important, is based on the anatomical knowledge described by Mazzocca et al.,<sup>19</sup> supplemented by other anatomical studies that describe the footprint of the distal biceps tendon region located in postero-ulnar radial tuberosity, measuring 21 mm in length and 7 mm in width.<sup>20,21</sup>

Due to the availability of different fixation methods for the reinsertion of the distal biceps, each with its own characteristics, advantages, and disadvantages, several biomechanical studies comparing these methods have been conducted, showing divergent results, powering the doubt of which method is preferential. Mazzocca et al.<sup>5</sup> assessed the four most common methods of treatment (bone tunnel, endobutton, interference screw, and suture anchors) in cadaveric elbows subjected to cyclic loads of 50 N force from 0° to 90° flexion and concluded that the endobutton technique presents greater resistance to failure. However, most clinical studies use suture anchors as a method of comparison between the available fixation techniques, observing optimal clinical and functional



**Fig. 6 – Clinical evaluation at four weeks postoperative, with evaluation of surgical scar in the proximal forearm (arrow).**

results.<sup>3,22</sup> Few clinical studies with the use of endobutton are available; therefore, new studies are needed to allow a better comparison of the latter two techniques.<sup>23</sup> In the present study, reinsertion was made with two suture anchors, which reestablished length and recreated the footprint of the tendon. In the present practice, this material is available, and good surgical results in short- and long-term follow-up were achieved with this technique, without loss of fixation.

In the present sample, complication rate was 27.2%, similar to that reported in the literature, which is 26.4%.<sup>18</sup> Associated with this factor, during follow-up 4.6% good and 95.4% excellent results were observed in the Andrews-Carson score, as well as 100% excellent results in the MEPS scale. These findings confirm the satisfactory results of this surgical technique. Most common complication was neuropraxia of the lateral cutaneous nerve of the forearm; this was also mentioned in most studies as the main complication.<sup>18</sup> Recovery from neurological symptoms occurred in the first months of postoperative follow-up. Neuropraxia of the radial nerve was observed in the patient with the longest time period between injury and surgical procedure (35 days).

All patients followed the specific rehabilitation protocol set forth by this group. The repair allowed early passive movement within one week postoperatively; a sling was used for two weeks, and active movements were initiated at four weeks, which evidenced the effectiveness of this method of fixation. Mean time to return to activities with a level similar to that presented before injury was three months, with no complaints and with a high satisfaction index.

## Conclusion

Early surgical repair of acute injury of the distal biceps through a single incision at the proximal forearm and fixation with two suture anchors in the radial tuberosity is an effective and safe therapeutic option, allowing early motion and good functional results.

## Conflicts of interest

The authors declare no conflicts of interest.

## REFERENCES

1. Safran MR, Graham SM. Distal biceps tendon ruptures: incidence, demographics, and the effect of smoking. *Clin Orthop Relat Res.* 2002;(404):275-83.
2. Morrey BF. Biceps tendon injury. *AAOS Instr Course Lect.* 1999;48:405-10.
3. Sutton KM, Dodds SD, Ahmad CS, Sethi PM. Surgical treatment of distal biceps rupture. *J Am Acad Orthop Surg.* 2010;18(3):139-48.
4. Baker BE, Bierwagen D. Rupture of the distal tendon of the biceps brachii. Operative versus non-operative treatment. *J Bone Joint Surg Am.* 1985;67(3):414-7.
5. Mazzocca AD, Burton KJ, Romeo AA, Santangelo S, Adams DA, Arciero RA. Biomechanical evaluation of 4 techniques of distal biceps brachii tendon repair. *Am J Sports Med.* 2007;35(2):252-8.
6. Lemos SE, Ebramzadeh E, Kvitne RS. A new technique: in vitro suture anchor fixation has superior yield strength to bone tunnel fixation for distal biceps tendon repair. *Am J Sports Med.* 2004;32(2):406-10.
7. John CK, Field LD, Weiss KS, Savoie FH 3rd. Single-incision repair of acute distal biceps ruptures by use of suture anchors. *J Shoulder Elbow Surg.* 2007;16(1):78-83.
8. Andrews JR, Carson WG. Arthroscopy of the elbow. *Arthroscopy.* 1985;1(2):97-107.
9. Brigato RM, Mouraria GG, Kikuta FK, Coelho SP, Cruz MA, Zoppi Filho A. Functional evaluation of patients with surgically treated terrible triad of the elbow. *Acta Ortop Bras.* 2015;23(3):138-41.
10. Morrey BF, Askew LJ, An KN, Dobyns JH. Rupture of the distal tendon of the biceps brachii: a biomechanical study. *J Bone Joint Surg Am.* 1985;67(3):418-21.
11. O'Driscoll SW, Goncalves LB, Dietz P. The hook test for distal biceps tendon avulsion. *Am J Sports Med.* 2007;35(11):1865-9.
12. Lobo LG, Fessell DP, Miller BS, Kelly A, Lee JY, Brandon C, et al. The role of sonography in differentiating full versus partial distal biceps tendon tears: correlation with surgical findings. *Am J Roentgenol.* 2013;200(1):158-62.
13. Fitzgerald SW, Curry DR, Erickson SJ, Quinn SF, Friedman HF. Distal biceps tendon injury: MR imaging diagnosis. *Radiology.* 1994;191(1):203-6.
14. Chillemi C, Marinelli M, De Cupis V. Rupture of the distal biceps brachii tendon: conservative treatment versus anatomic reinsertion - clinical and radiological evaluation after 2 years. *Arch Orthop Trauma Surg.* 2007;127(8):705-8.
15. Chiavaras MM, Jacobson JA, Billone L, Lawton JM, Lawton J. Sonography of the lateral antebrachial cutaneous nerve with magnetic resonance imaging and anatomic correlation. *J Ultrasound Med.* 2014;33(8):1475-83.
16. Kelly EW, Morrey BF, O'Driscoll SW. Complications of repair of the distal biceps tendon with the modified two-incision technique. *J Bone Joint Surg Am.* 2000;82(11):1575-81.
17. Grewal R, Athwal GS, MacDermid JC, Faber KJ, Drosdowech DS, El-Hawary R, et al. Single versus double-incision technique for the repair of acute distal biceps tendon ruptures. A randomized clinical trial. *J Bone Joint Surg Am.* 2012;94(13):1166-74.
18. Watson JN, Moretti VM, Schwindel L, Hutchinson MR. Repair techniques for acute distal biceps tendon ruptures: a systematic review. *J Bone Joint Surg Am.* 2014;96(24):2086-90.
19. Mazzocca AD, Cohen M, Berkson E, Nicholson G, Carofino BC, Arciero R, et al. The anatomy of the bicipital tuberosity and distal biceps tendon. *J Shoulder Elbow Surg.* 2007;16(1):122-7.
20. Athwal GS, Steinmann SP, Rispoli DM. The distal biceps tendon: footprint and relevant clinical anatomy. *J Hand Surg Am.* 2007;32(8):1225-9.
21. Hutchinson HL, Gloystein D, Gillespie M. Distal biceps tendon insertion: an anatomic study. *J Shoulder Elbow Surg.* 2008;17(2):342-6.
22. Sarda P, Qaddori A, Nauschutz F, Boulton L, Nanda R, Bayliss N. Distal biceps tendon rupture: current concepts. *Injury.* 2013;44(4):417-20.
23. Giacalone F, Dutto E, Ferrero M, Bertolini M, Sard A, Pontini I. Treatment of distal biceps tendon rupture: why, when, how? Analysis of literature and our experience. *Musculoskelet Surg.* 2015;99 Suppl. 1:67-73.