

Received: 2013.06.30
Accepted: 2013.07.16
Published: 2013.10.18

Solitary paraganglioma of the hypoglossal nerve: A case report with magnetic resonance imaging findings

Authors' Contribution:
Study Design A
Data Collection B
Statistical Analysis C
Data Interpretation D
Manuscript Preparation E
Literature Search F
Funds Collection G

ABCDEF 1 **Mehmet Beyazal**
ABE 1 **Alpaslan Yavuz**
ABCDE 1 **Özkan Ünal**
ABCDEF 2 **Hakan Çankaya**
ABCE 3 **Deniz Yılmaz**

1 Department of Radiology, School of Medicine, Yüzüncü Yıl University, Van, Turkey
2 Department of Otorhinolaryngology, School of Medicine, Yüzüncü Yıl University, Van, Turkey
3 Department of Pathology, School of Medicine, Yüzüncü Yıl University, Van, Turkey

Corresponding Author: Mehmet Beyazal, e-mail: drbeyazal@hotmail.com

Patient: Female, 58
Final Diagnosis: Solitary paraganglioma of the hypoglossal nerve
Symptoms: Neck pain
Medication: —
Clinical Procedure: Surgical resection
Specialty: Otolaryngology

Objective: Rare disease

Background: Paragangliomas are rare neuroendocrine tumors originating in the neural crest. Only a few cases of hypoglossal paraganglioma have been reported in the published literature. The localization of hypoglossal paragangliomas close to the carotid artery precludes determination of tumor origin preoperatively.

Case Report: A 58-year-old female patient was admitted due to neck pain. During physical examination, a significant mass could not be palpated in the upper left part of the neck, despite sensitivity during palpation. Atrophy and left deviation of the left half of the tongue was observed. MRI of the neck revealed a lesion located superior to the carotid bifurcation between the left internal carotid artery and external carotid artery. There was atrophy in the left half of the tongue. The neck mass displaced the left internal carotid artery anteriorly and medially. The operation was performed with left lateral cervical access. This lesion, which derived from the hypoglossal nerve, was excised. Following histopathological evaluation, the lesion was diagnosed as paraganglioma.

Conclusions: Hypoglossal paraganglioma is quite rare and there are no established criteria for preoperative diagnosis. Hypoglossal paraganglioma must be considered to determine treatment options if a lateral neck mass and ipsilateral tongue atrophy are present at the level of the 12th cranial nerve tract.

Key words: solitary paraganglioma • hypoglossal nerve • hemiatrophy of tongue • magnetic resonance imaging

Full-text PDF: <http://www.amjcaserep.com/download/index/idArt/889509>



1028



—



3



10

Background

Paragangliomas are rare neuroendocrine tumors, usually situated along the parasympathetic nervous system and originating from the neural crest. During embryonic development, migration and differentiation of neural crest cells may cause these lesions to occur in unexpected anatomical locations [1]. Paragangliomas are most often seen in the carotid body, vagus, jugular and tympanic ganglia, the temporal bone along Arnold's and Jacobson's nerve tracts, and within laryngeal, orbital, or nasal tissues [2]. To date, fewer than 10 cases have been reported in the literature [1,3]. The localization of hypoglossal paragangliomas close to the carotid artery precludes determination of tumor origin preoperatively [3]. Diagnosis of hypoglossal paraganglioma by preoperative imaging has been reported in only 1 case [3]. A case has been reported of hypoglossal paraganglioma diagnosed preoperatively, suspected as a schwannoma based on radiological findings and clinical examination [1].

In this report, we present a case of a paraganglioma derived from the extracranial part of the hypoglossal nerve, suspected based on pre-operative MRI.

Case Report

A 58-year-old Asian female patient was admitted due to neck pain, which occurred occasionally over the previous 2 years, with increasing severity in recent weeks. Moreover, the patient was experiencing difficulty swallowing. During physical examination, a significant mass could not be palpated in the upper left part of the neck, despite sensitivity during palpation. Atrophy and left deviation of the left half of the tongue was observed. Results of complete blood count and biochemical tests were within normal limits. In the neck MRI, a mildly hyperintense lesion was found, located superior to the carotid bifurcation between the left internal carotid artery (ICA) and external carotid artery (ECA) by T2-weighted images. This lesion was hypointense on T1-weighted images. Significant enhancement was present on post-contrast T1-weighted images. Moreover, there was atrophy in the left half of the tongue (Figure 1). The neck mass displaced the left ICA anteriorly and medially (Figure 2).

The operation was performed with left lateral cervical access. The cranial nerves were identified by isolating the upper neck arteries and veins. A mass lesion was found. The hypoglossal nerve was extending towards and entering the expanding mass. This lesion, derived from the hypoglossal nerve, was excised. Results of examination of the other cranial nerves were normal in the early postoperative period. Following histopathological evaluation, the lesion was diagnosed as paraganglioma (Figure 3).

Six month postoperative follow up, left sided-tongue atrophy persisted, but the patient did not have difficulty in swallowing.

Discussion

Embryologically, paragangliomas are thought to originate in the third and fourth branchial arches. Neuroblast migration and differentiation may result in the formation of neural crest cells at unusual sites [1]. Some studies have demonstrated the presence of fibers of the autonomous nervous system along the inside of the hypoglossal nerve. These observations support the existence of hypoglossal nerve paraganglioma [2].

The hypoglossal nerve can be divided into 2 main parts: intracranial and extracranial. Rootlets of the hypoglossal nerve leave the medulla through the anterolateral sulcus. These roots enter the hypoglossal canal and pass through the posterolateral vertebral artery. The hypoglossal nerve exits the external orifice of the hypoglossal canal, at which point the extracranial parts begin. The hypoglossal nerve extends downwards through the medial internal jugular vein through the posteromedial ICA after exiting the external orifice of the hypoglossal canal. Subsequently, it passes between the ICA and the internal jugular vein. The nerve extends to the tongue after passing slightly medial of the ICA [4].

Despite multiple imaging modalities, hypoglossal paraganglioma may not be differentiated from more common carotid body tumor or vagal paraganglioma [5]. It is thought that the position of the hypoglossal nerve relative to the ICA is significant for diagnosis and differential diagnosis. Carotid body tumors are located between the ICA and the ECA at the level of the carotid bifurcation. This specifically displaces the ICA posteriorly. Carotid body paraganglioma may be misdiagnosed as carotid bifurcation expansion in vagal paraganglioma [6]. However, vagal paraganglioma has been reported to displace the ICA anteriorly and medially without causing expansion on carotid bifurcation [7]. In this case, the tumor was placed distal to the carotid bifurcation and displaced the ICA anteriorly and medially. Paragangliomas are hypervascular tumors. Paragangliomas have a characteristic magnetic resonance appearance based on their vascularity. Serpiginous areas of signal void showing high vascular flow were interspersed among areas of high signal intensity caused by slowly flowing blood and tumor cells. This appearance, called "salt-and-pepper", is apparent in the T2-weighted images [8].

Hypoglossal paraganglioma cases usually present as a painless lateral neck mass. Additionally, there may be complaints of dysphonia, occasional dysphagia, tinnitus, and altered taste. Due to lower motor neuron hypoglossal paralysis, ipsilateral tongue wasting and related wasting with deviation of the tongue may be present [1]. Farr et al. identified a case of hypoglossal paraganglioma extending from the hypoglossal canal to the

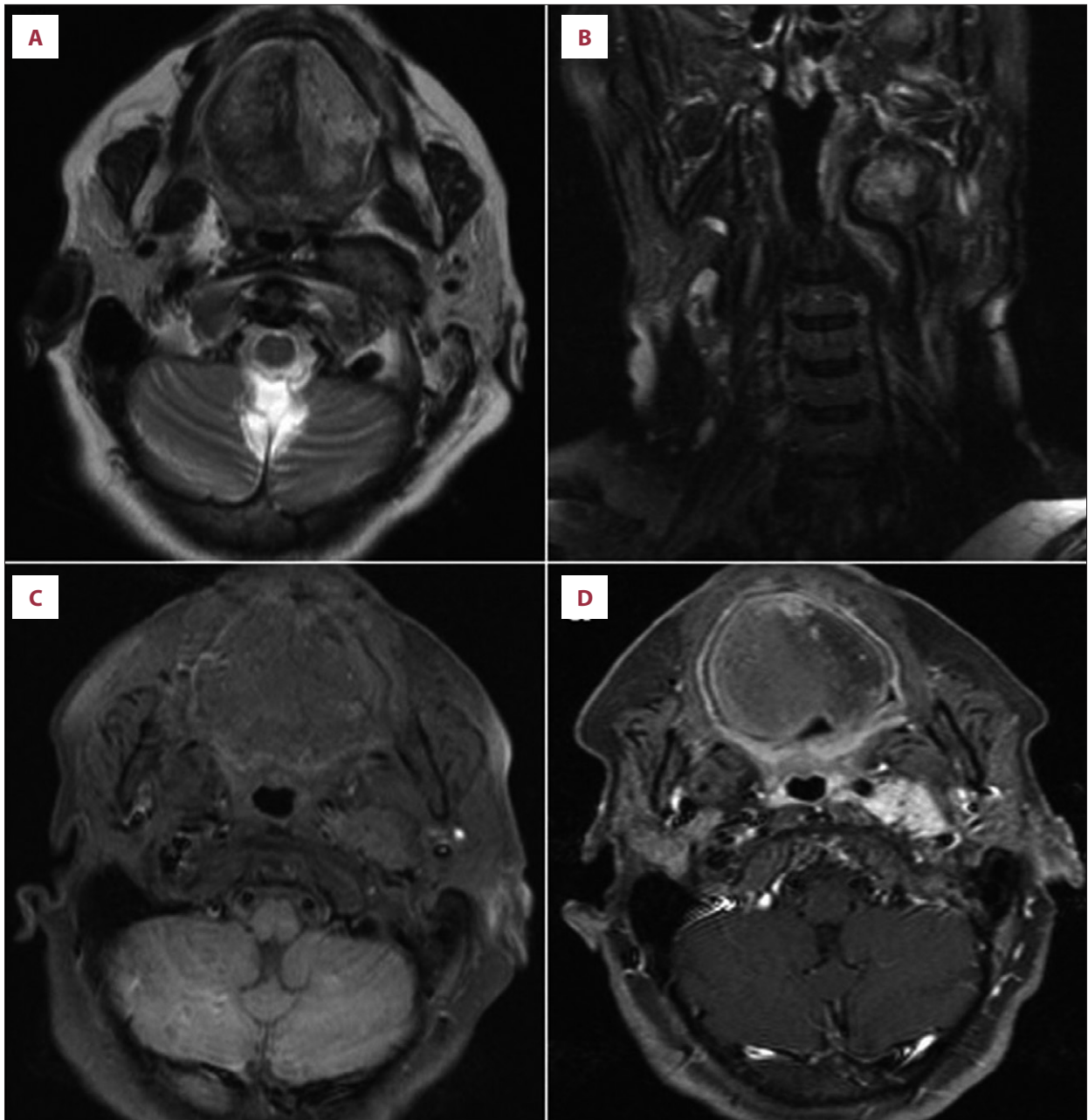


Figure 1. Mildly hyperintense and “salt and pepper” looking lesion, located superior to left carotid bifurcation level between left ICA and ECA, is observed on T2 weighted axial (A) and coronal (B) imaging. Hypointense lesion on T1 weighted axial (C) imaging. Postcontrast T1-weighted axial (D) images demonstrates increased contrast enhancement of lesion. On axial images, atrophy is observed on left half of tongue. Lesion pushed left ICA to anterior and medial.

foramen magnum and posterior fossa. In this case, the clinical findings related to medulla compression were identified [3].

Because malignant change occurs in about 12% of sporadic cases, the most appropriate treatment for head and neck paraganglioma is surgical removal. Publications on preoperative embolization of neck paraganglioma are available. Cessation of blood flow is effective in tumor bed obliteration and the reduction of

bleeding during surgery [9]. Surgical resection of hypoglossal paraganglioma frequently results in hypoglossal dysfunction during the post-operative period, with possible need for post-operative rehabilitation. Radiation therapy may be effective treatment for paragangliomas. Although radiation therapy cannot completely heal the tumor, it has several advantages in reducing morbidity due to surgery in large lesions [1]. Moreover, gamma knife surgery is used as an alternative method of resection to

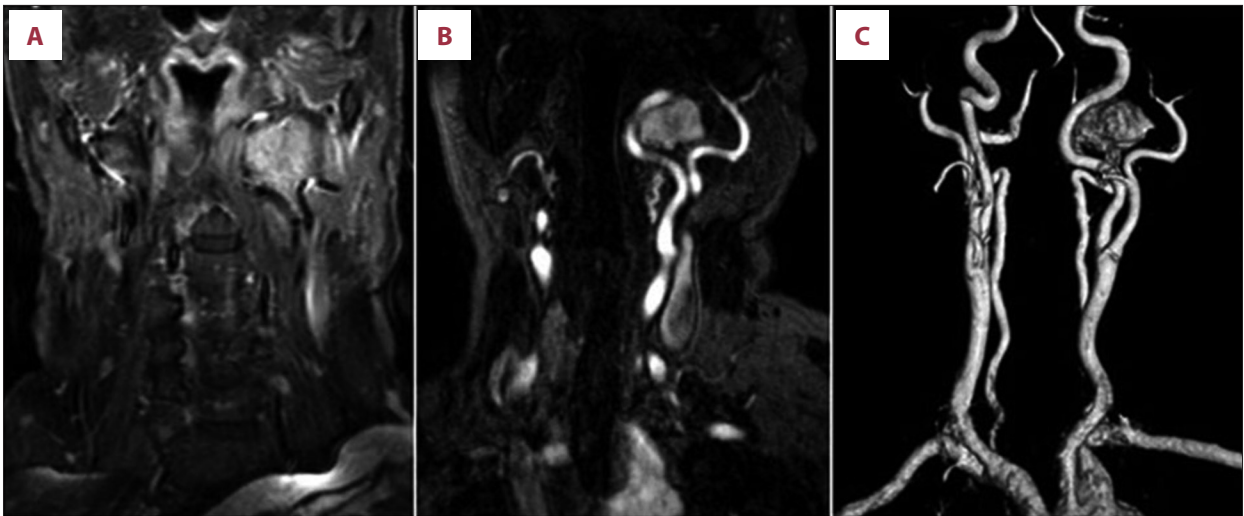


Figure 2. Coronal postcontrast T1-weighted images (A) shows increased contrast enhancement. Coronal multiplanar reformation (B) and maximum intensity projection (C) contrast-enhanced MR angiography images demonstrates lesion localized superior to the carotid bifurcation level, between left ICA and ECA. Lesion pushed left ICA to anterior and medial.

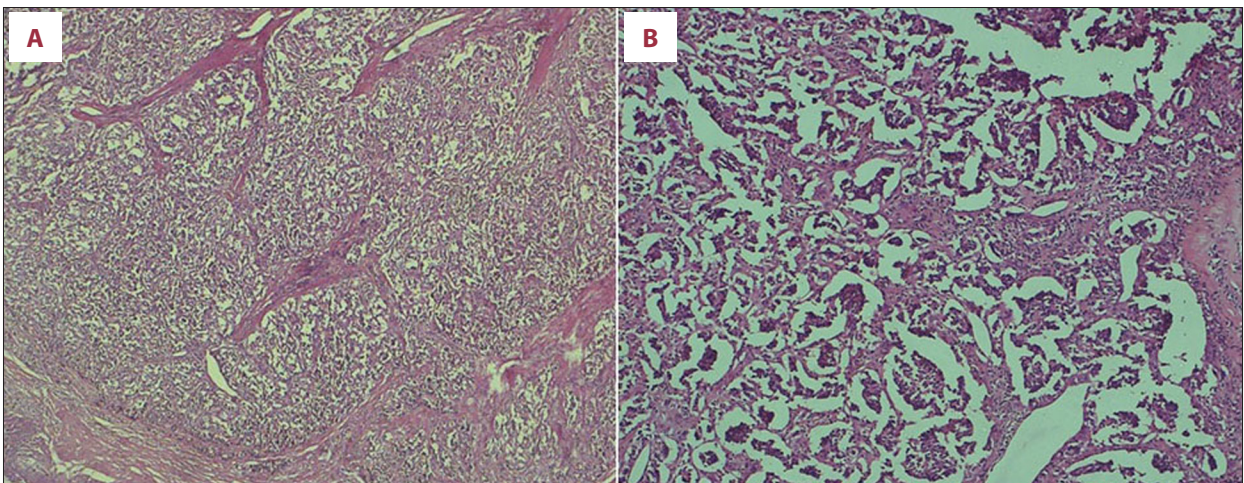


Figure 3. Paraganglioma. Eosinophilic cytoplasm cells are observed as nested arbitrarily along with fibrovascular septa (HE $\times 50$) Zellballen formation is observed for paraganglioma (HE $\times 100$) (B).

reduce morbidity related to tumor treatment. Gamma knife surgery is more effective and has fewer adverse effects compared to conventional fractionated external beam radiotherapy [10].

Conclusions

Hypoglossal paraganglioma is quite rare and there are no established criteria for preoperative diagnosis. Hypoglossal

paraganglioma must be considered in deciding on treatment options if lateral neck mass and ipsilateral tongue atrophy are present at the level of the 12th cranial nerve tract.

Declaration of interest

This work was not funded by any government or nongovernment organization. There is no conflict of interest for any author of this manuscript.

References:

1. Raza K, Kaliaperumal C, Farrell M et al: Solitary paraganglioma of the hypoglossal nerve: case report. *Neurosurgery*, 2011; 68: 1170-74
2. Santovito D, Conforti M, Varetto G, Rispoli P: Paraganglioma of the hypoglossal nerve. *J Vasc Surg*, 2009; 49: 1053-55
3. Farr MR, Martin TP, Walsh AR, Irving RM: A case of paraganglioma of the hypoglossal nerve. *J Laryngol Otol*, 2010; 124: e3

4. Bademci G, Yaşargil MG: Microsurgical anatomy of the hypoglossal nerve. *J Clin Neurosci*, 2006; 3: 841–47
5. Fink DS, Benoit MM, Lamuraglia GM, Deschler DG: Paraganglioma of the hypoglossal nerve. *Laryngoscope*, 2010; 120: S147
6. Thabet MH, Kotob H: Cervical paragangliomas: diagnosis, management and complications. *J Laryngol Otol*, 2001; 115: 467–74
7. Nettekville JL, Jackson CG, Miller FR et al: Vagal paraganglioma: a review of 46 patients treated during a 20-year period. *Arch Otolaryngol Head Neck Surg*, 1998; 124: 1133–40
8. Olsen WL, Dillon WP, Kelly WM et al: MR imaging of paragangliomas. *AJR Am J Roentgenol*, 1987; 148: 201–4
9. Shintani T, Oyake D, Kanayama R et al: Rare localization of paraganglioma in head and neck. *Auris Nasus Larynx*, 2003; 30: 149–52
10. Hafez RF, Morgan MS, Fahmy OM: The safety and efficacy of gamma knife surgery in management of glomus jugulare tumor. *World J Surg Oncol*, 2010; 8: 76