

# Myxoid Chondrosarcoma of the Sinonasal Cavity in a Child: a Case Report

Yeo Ju Kim, MD<sup>1</sup>  
Soo Ah Im, MD<sup>1</sup>  
Gye-Yeon Lim, MD<sup>1</sup>  
Ho Jong Chun, MD<sup>1</sup>  
Hyun Jin Park, MD<sup>1</sup>  
Min Sik Kim, MD<sup>2</sup>  
Yeong Jin Choi, MD<sup>3</sup>

## Index terms:

Myxoid chondrosarcoma  
Sinonasal cavity  
Child  
Computed tomography (CT)  
Magnetic resonance (MR)  
PET-CT

## Korean J Radiol 2007; 8: 452-455

Received May 4, 2006; accepted  
after revision October 13, 2006.

<sup>1</sup>Department of Radiology, Kangnam St. Mary's Hospital, The Catholic University of Korea, Seoul 137-701, Korea;

<sup>2</sup>Department of Otolaryngology-Head and Neck Surgery, Kangnam St. Mary's Hospital, The Catholic University of Korea, Seoul 137-701, Korea;

<sup>3</sup>Department of Clinical Pathology, Kangnam St. Mary's Hospital, The Catholic University of Korea, Seoul 137-701, Korea

## Address reprint requests to:

Soo Ah Im, MD, Department of Radiology, Kangnam St. Mary's Hospital, The Catholic University of Korea, 505, Banpo-dong, Seocho-gu, Seoul 137-701, Korea.  
Tel. (822) 590-1552  
Fax. (822) 599-6771  
e-mail: saim@catholic.ac.kr

Chondrosarcomas are malignant tumors of cartilage that rarely involve the sinonasal region, and myxoid chondrosarcoma is a rare histologic variant of chondrosarcoma that usually occurs in the soft tissue of extremities. Although several case reports and results of small series of chondrosarcomas in the sinonasal region in children are available, myxoid type chondrosarcoma is extremely rare. We recently experienced a case of low grade myxoid chondrosarcoma involving the sinonasal cavity in a 10-year-old boy, and here we report its radiologic-pathologic findings. In this case, chondroid calcification on CT and septal and marginal enhancement on MRI suggested a chondrosarcoma. Whole body PET-CT demonstrated no definite metastatic lesion and a low peak standardized uptake value primary tumor. However, no definite distinguishing imaging features were observed that distinguished low grade myxoid chondrosarcoma from conventional chondrosarcoma.

**C**hondrosarcomas are malignant mesenchymal tumors of cartilage, and usually involve the long bone and pelvis. Less than 10% of chondrosarcomas are found in the head and neck region. Chondrosarcomas can occur at any age, but the majority present between the 5th and 7th decades (1). Therefore, chondrosarcomas of the head and neck in children are rare; only about 13 cases of sinonasal chondrosarcoma in children have been reported (1, 2).

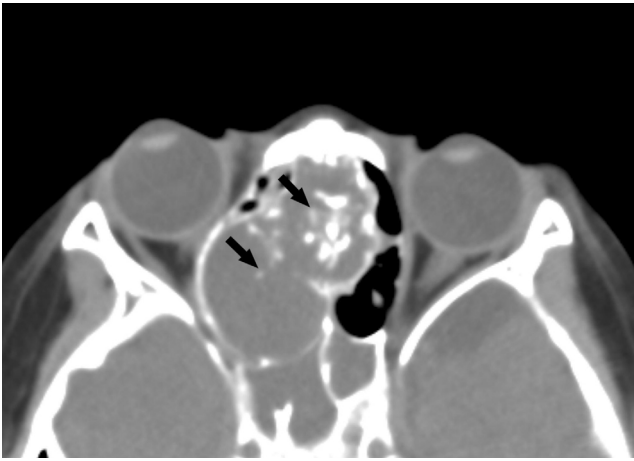
Myxoid chondrosarcoma is a rare histologic variant of chondrosarcoma, and is characterized by abundant chondroid matrix and malignant chondroblastic cells arranged in cords resembling chordoma (2, 3). Myxoid chondrosarcomas are typically located in the limbs in older patients, and only rarely originate in the head and neck in children (2). To the best of our knowledge, only one case report of myxoid type chondrosarcoma in the sinonasal region in a child is available (2).

We report a case of myxoid chondrosarcoma involving the sinonasal cavity in a child and describe its computed tomography (CT), magnetic resonance imaging (MRI) and whole body positron emission tomography-computed tomography (PET-CT) appearances, in addition to histopathologic findings.

## CASE REPORT

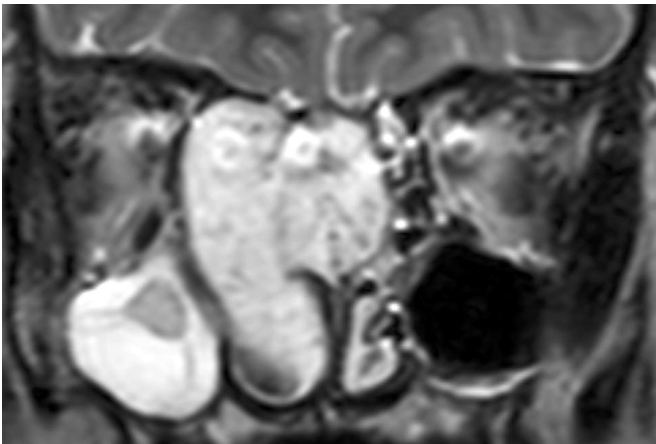
A 10-year-old boy presented with bloody rhinorrhea of one month duration from the right side of the nasal cavity. On nasal endoscopy, a large, polypoid mass was observed to fill the right nasal cavity causing deviation of the lateral nasal wall to the right. CT showed a lobulated, low attenuating mass with ring and arc calcifications in the right nasal cavity and nasal septum, measuring about 4.9 × 3.3 × 2.9 cm (Fig. 1).

## Myxoid Chondrosarcoma of Sinonasal Cavity in a Child

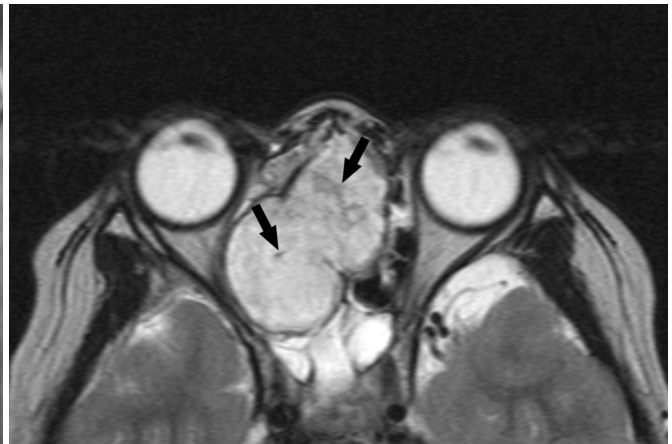

**Fig. 1.** Non-enhanced axial CT scan showing a lobulated hypodense mass in the right nasal cavity and nasal septum, containing ring and arc calcifications (arrows). The bony margins of the medial orbital wall were thin and expanded, without definite evidence of bony destruction.

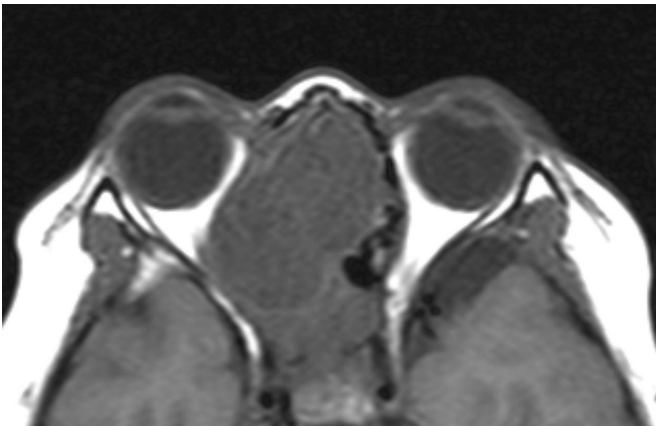
The mass extended beyond the nasal septum into the right ethmoid sinus and had caused pressure erosion of the adjacent bony margins of the cribriform plate and medial orbital wall. However, no definite bony destruction was demonstrated. After intravenous infusion of contrast medium, subtle internal septal enhancement of the mass was observed. Coronal and axial T2-weighted MR images (TR/TE, 4128/100) revealed more accurately the anatomical relationships of the mass (Figs. 2A, B), which was located in the right nasal cavity and nasal septum, and extending into the right ethmoid sinus. The mass had displaced and compressed the right medial orbital wall laterally and the cribriform plate superiorly, and mass was homogeneously hypointense on T1-weighted images (Fig. 2C) and heterogeneously hyperintense on T2-weighted images (Figs. 2A, B). It showed mainly peripheral and septal-like enhancement on contrast-enhanced T1-



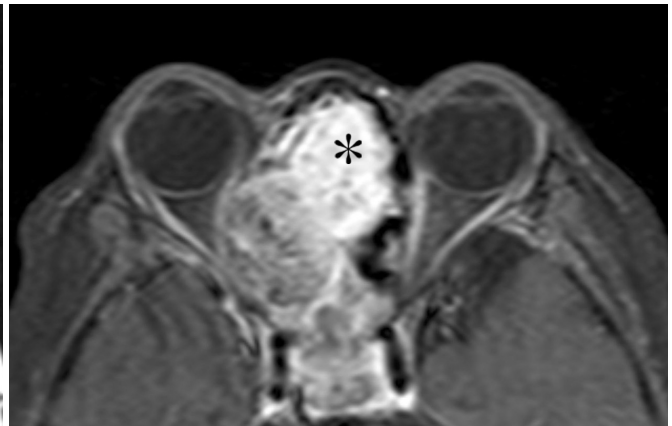A



B



C



D

**Fig. 2. A, B.** Coronal and axial T2 weighted MR images (TR/TE, 4530/110) showing a high signal intensity mass located in the right posterior nasal cavity and on the nasal septum, and extending into the right ethmoid sinus. Areas of low signal intensity (arrows) on T2-weighted images corresponded to matrix mineralization on CT images. The mass displaced and compressed the right medial orbital wall laterally and the cribriform plate superiorly.  
**C.** Axial T1 weighted image (TR/TE, 921/11) showing the homogeneously hypointense mass.  
**D.** Contrast-enhanced T1-weighted image showing peripheral and septal-like enhancement with a focal area of strong enhancement (asterisk) at the anterior portion of the mass.

weighted images and regional inhomogeneously strong enhancement at its anterosuperior portion (Fig. 2D). Areas of low signal intensity were seen on T2-weighted MR images (Fig. 2B), which corresponded to matrix mineralization on CT images (Fig. 1). An endoscopic biopsy was performed in the nasal cavity, and the preliminary pathologic diagnosis was of myxoid chondrosarcoma or chordoma, due to the presence of a cord-like cellular arrangement with a myxoid background. Whole body PET-CT with a low-dose CT protocol was performed at the 17th day after biopsy. PET-CT revealed a mild F18-fluorodeoxyglucose (FDG) uptake area (pSUV, peak standardized uptake value = 2.7) in the lesion without a definite metastatic lesion (Fig. 3).

The patient underwent subtotal resection of the mass; some residual mass remained in the ethmoid sinus and nasal septum. The removed tumor was a pale gray, soft to firm, polypoid mass measuring  $4.7 \times 3.0 \times 3.0$  cm. Histologically, there were scattered pleomorphic chondroblasts with thin anastomosing strands surrounded by a myxoid stroma; cellular areas were arranged in cords (Fig. 4). The presence of a characteristic cord-like cellular arrangement resembling chordoma and strong positivity for S-100 protein and vimentin led to a final diagnosis of myxoid chondrosarcoma. The low cellular atypia, few mitoses, and low cellularity observed represented a low grade tumor. We could not prove the presence of the specific t(9; 26) translocation which is regarded as another pathognomonic feature of myxoid chondrosarcoma because the RT-PCR technique and primer required were unavailable.

After surgery, the patient underwent radiation therapy on the remaining primary tumor, and subsequently the remaining tumor showed a decreased size and enhance-

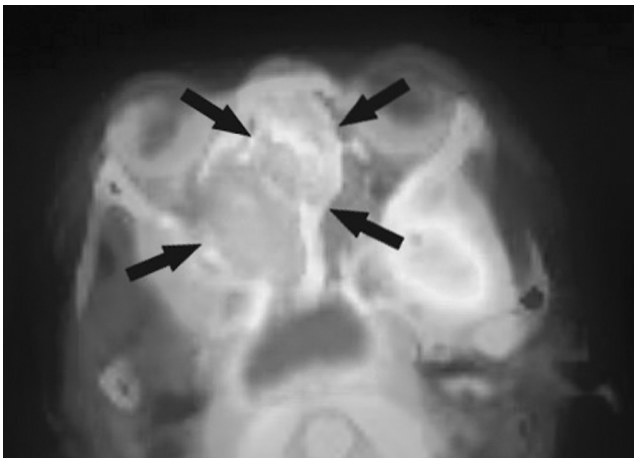
ment on follow up CT.

## DISCUSSION


Myxoid chondrosarcoma is a rare histologic variant of chondrosarcoma, and the vast majority of lesions arise in the soft tissue of the extremities with the thigh being the single most common location (3, 4). Myxoid chondrosarcoma rarely originates in the head and neck and is extremely rare in patients younger than 20 years of age. These tumors typically possess a t(9; 22) translocation, which is not seen in conventional chondrosarcoma. They also have a quite different clinical course with a high rate of local recurrence and eventually a high rate of late death (5).

According to Kilpatrick et al. (6), the more aggressive clinical behavior of myxoid chondrosarcoma is reflected by its radiologic features, which include a permeative pattern of osseous destruction and associated soft tissue mass. Matrix mineralization is frequently apparent on CT scans, though, it is not extensive. The extensive myxoid stroma of myxoid chondrosarcoma has an exceptionally high water content with low attenuation by CT and very high signal intensity by T2-weighted MR (6), and this MRI enhancement pattern of myxoid chondrosarcoma depends on tumor heterogeneity (4). Although intralesional hemorrhage is common pathologic finding, it is uncommon by MRI. Extracompartmental extension, cortical destruction and a soft tissue mass were also found (4).

Murphey et al. (3) reported that regardless of specific pathologic types, chondrosarcoma has features in common with cartilaginous tumors as it has high water content, a



**Fig. 3.** PET-CT image showing mild F18-fluorodeoxyglucose (FDG) uptake (pSUV = 2.7) (arrows) in the right nasal cavity and on the nasal septum.



**Fig. 4.** Photomicrograph of the resected tumor (Hematoxylin & Eosin,  $\times 400$ ). A cord-like cellular arrangement of pleomorphic chondroblasts (arrows) with thin anastomosing strands is shown surrounded by myxoid stroma (asterisks).



lobular type architecture, and peripheral enchondral calcification. The slow growth shown this tumor may induce signs of pressure erosion on adjacent bone rather than destruction.

Our case demonstrated very low attenuation on CT and high signal intensity on T2-weighted MR images; representing the high water content of myxoid stroma. Some portion of the mass in the nasal septum and ethmoid sinus showed heterogeneously intense enhancement, and the remaining portion in the right nasal cavity showed peripheral and septal-like enhancement. As reported by Tateishi et al. (4), our case also showed some hemorrhagic foci microscopically, did not show any evidence of hemorrhage on MR or CT images. However, extracompartmental extension was absent in our case. Only pressure erosions were observed at adjacent bony structures (excepting the nasal septum), rather than a permeative pattern of osseous destruction, which is one of the features of myxoid chondrosarcoma. In fact, our case demonstrates the typical imaging findings of conventional chondrosarcoma rather than any specific findings of myxoid chondrosarcoma.

The precise role of FDG-PET for bone and soft tissue tumors has not been well established in pediatric oncology. However, Brenner et al. (7) reported that the combination of pSUV on PET imaging and histopathologic tumor grading in chondrosarcoma might be helpful for determining a more accurate prognosis. Depending on pSUV values, they divided chondrosarcomas into two groups, i.e. low risk (low-grade irrespective of pSUV and intermediate- or high-grade tumor with  $pSUV \leq 4$ ) and high risk (intermediate- or high-grade tumor with  $pSUV > 4$ ) (7).

Recent advances in imaging have allowed the acquisition of physiological information in chondrosarcoma that complements that structural detail provided by traditional techniques, such as, dynamic contrast enhanced perfusion MR and diffusion weighted imaging (DWI). By dynamic contrast enhanced perfusion MR, chondrosarcoma shows hypoperfusion and is essentially 'cold' (8). Quantitative DWI may be useful for differentiating chondrosarcoma from other poorly contrast-enhanced and T2-prolonged bone masses because of its low apparent diffusion coefficient value (9).

The treatment of choice for chondrosarcomas is wide local excision. Kawaguchi et al. (10) reported that wide excision for myxoid chondrosarcoma was effective for achieving local tumor control, irrespective of previous excision or recurrence. Chemotherapy and radiation therapy have limited roles in cases of chondrosarcoma, as the disease is generally insensitive to these treatments. However, radiation therapy may be used when a tumor

has been excised incompletely or is located in surgically inaccessible region. The most frequent metastatic sites are lung and regional lymph nodes (3). In particular, myxoid chondrosarcoma has been reported to have a high potential for pulmonary metastasis, regardless of its histologic grade (3, 10).

In conclusion, although the occurrence of myxoid chondrosarcoma arising from the sinonasal cavity is extremely rare in children, chondrosarcoma can be diagnosed in combination with chondroid calcification by CT and by septal and marginal enhancement on MR. In our case, low grade myxoid chondrosarcoma in the sinonasal cavity had imaging features resembling those of conventional chondrosarcoma, and showed no imaging features that definitely distinguished it from conventional chondrosarcoma.

### References

1. Gadwal SR, Fanburg-Smith JC, Gannon FH, Thompson LD. Primary chondrosarcoma of the head and neck in pediatric patients: a clinicopathologic study of 14 cases with a review of the literature. *Cancer* 2000;88:2181-2188
2. Joÿrg S, August C, Stoll W, Alberty J. Myxoid chondrosarcoma of the maxilla in a pediatric patient. *Eur Arch Otorhinolaryngol* 2006;263:195-198
3. Murphey MD, Walker EA, Wilson AJ, Kransdorf MJ, Temple HT, Gannon FH. From the archives of the AFIP: imaging of primary chondrosarcoma: radiologic-pathologic correlation. *Radiographics* 2003;23:1245-1278
4. Tateishi U, Hasegawa T, Nojima T, Takegami T, Arai Y. MRI features of extraskeletal myxoid chondrosarcoma. *Skeletal Radiol* 2006;35:27-33
5. Antonescu CR, Argani P, Erlandson RA, Healey JH, Ladanyi M, Huvos AG. Skeletal and extraskeletal myxoid chondrosarcoma: a comparative clinicopathologic, ultrastructural, and molecular study. *Cancer* 1998;83:1504-1521
6. Kilpatrick SE, Inwards CY, Fletcher CD, Smith MA, Gitelis S. Myxoid chondrosarcoma (chordoid sarcoma) of bone: a report of two cases and review of the literature. *Cancer* 1997;79:1903-1910
7. Brenner W, Conrad EU, Eary JF. FDG PET imaging for grading and prediction of outcome in chondrosarcoma patients. *Eur J Nucl Med Mol Imaging* 2004;31:189-195
8. Kothary N, Law M, Cha S, Zagzag D. Conventional and perfusion MR imaging of parafalcine chondrosarcoma. *AJNR Am J Neuroradiol* 2003;24:245-248
9. Hayashida Y, Hirai T, Yakushiji T, Katahira K, Shimomura O, Imuta M, et al. Evaluation of diffusion-weighted imaging for the differential diagnosis of poorly contrast-enhanced and T2-prolonged bone masses: Initial experience. *J Magn Reson Imaging* 2006;23:377-382
10. Kawaguchi S, Wada T, Nagoya S, Ikeda T, Isu K, Yamashiro K, et al. Extraskeletal myxoid chondrosarcoma: a Multi-Institutional Study of 42 Cases in Japan. *Cancer* 2003;97:1285-1292