

An alternative method in the diagnosis of intrabiliary lesions: Percutaneous endobiliary brush biopsy

Mustafa Ozdemir¹, Tunahan Dertli¹, Omer Faruk Sevinc², Onur Taydas¹, Gurkan Danisan¹, Omer Faruk Ates¹, Mehmet Halil Ozturk¹

¹Department of Radiology, Sakarya University School of Medicine, Sakarya, Turkiye; ²Department of Radiology, Kocaeli City Hospital, Kocaeli, Turkiye

Abstract

Background and Aim: Biliary strictures can occur as a result of various benign or malignant processes. The aim of this study is to evaluate the effectiveness and reliability of percutaneous endobiliary brush biopsy in the diagnosis of intrabiliary lesions.

Materials and Methods: This retrospective, single-center study was conducted between January 2022 and April 2023, involving a total of 16 patients. Of the patients, 10 were male (62.5%), and 6 were female (37.5%). The average age of the patients was 68.1±8. All patients underwent the procedure using an endobiliary biopsy brush under ultrasound and fluoroscopic guidance.

Results: Technical success was achieved in all patients (100%). Cell detection was not observed in biopsy samples from 2 patients (12.5%), resulting in a diagnostic success rate of 87.5%. Access was made to the right biliary system in 14 patients (87.5%) and to the left biliary system in 2 patients (12.5%). Biopsy locations included the common bile duct in 12 patients (75%), hepatic hilum in 2 patients (12.5%), and bilioenteric anastomosis line in 2 patients (12.5%). The mean fluoroscopy time was 16.2±7.1 minutes. The average radiation dose was 660±370 mSv. Pathological diagnosis revealed malignancy in 8 patients (50%) and benign findings in 6 patients (37.5%). Liver abscess requiring drainage developed in 2 patients (12.5%).

Conclusion: Percutaneous endobiliary brush biopsy performed under imaging guidance is an effective and reliable method for the diagnosis of biliary lesions.

Keywords: Brush biopsy; biliary stricture; cholestasis; interventional radiology.

Introduction

Biliary strictures can arise from various benign and malignant processes. Despite continuous advancements in non-invasive imaging techniques such as ultrasonography (US), computed tomography (CT), and magnetic resonance imaging (MRI), biliary system pathologies lack effective imag-

ing characteristics.^[1,2] In this context, benign conditions such as postoperative strictures and inflammation may exhibit clinical and imaging features similar to malignancies.^[3] Another challenging scenario is the occurrence of restenosis after curative or palliative surgical interventions. Distinguishing postoperative fibrotic strictures from those secondary to malignancy recurrence can be challenging when planning advanced treatment.^[4]

The primary method for diagnosing neoplasms involves determining the histological and pathological characteristics of biopsy samples through tissue sampling.^[5,6] The most significant challenge in evaluating biliary system neoplasms via tissue sampling is the difficulty in obtaining biopsy material with sufficient diagnostic value.

Percutaneous Transhepatic Biliary Drainage (PTBD) is a well-defined, minimally invasive alternative to endoscopic methods in the treatment of obstructive jaundice.^[7] PTBD allows for tissue sampling from the bile ducts using appropriate tools during the procedure, as it provides access to the biliary system. Since the first study on Percutaneous Endobiliary Brush Biopsy (PEFB) was published in 1980, this method has progressively advanced, with the use of more sophisticated devices and systems.^[8] However, to date, there are only a few studies on the reliability and applicability of PEFB, including results and success rates. Therefore, this study aims to examine the PEFB data conducted at our center, addressing the need for more data in this field.

Materials and Methods

This study has been approved by the Sakarya University Faculty of Medicine Clinical Studies Ethics Committee (date: 13/04/2023, no: 137) and conducted in accordance with the Declaration of Helsinki. In this retrospective case series, PEFB procedures performed on a total of 16 patients at our interventional radiology clinic between January 2022 and April 2023 were evaluated. All patients presented with biliary obstruction. Of the patients, 10 were male (62.5%), and 6 were female (37.5%). The average age of the patients was 68.1±8.

The decision to perform PEFB was made by a council consisting of gastroenterologists, general surgeons, oncologists, and interventional radiologists. In 8 patients, endoscopic tissue sampling was unsuccessful due to postoperative anatomical changes or tumor compression, while in the remaining 8 patients, PEFB was chosen directly without attempting endoscopic methods due to the planned treatment of obstructive jaundice.

Eight patients had a known history of malignancy. Two patients (12.5%) had a history of colon cancer, 2 patients (12.5%) had gallbladder cancer, 2 patients (12.5%) had breast cancer, and 2 patients (12.5%) had stomach cancer. All these patients had undergone surgical or chemotherapeutic treatment. In 8 patients (50%), there was no known history of malignancy.

How to cite this article: Ozdemir M, Dertli T, Sevinc OF, Taydas O, Danisan G, Ates OF, Ozturk MH. An alternative method in the diagnosis of intrabiliary lesions: Percutaneous endobiliary brush biopsy. *Hepatology Forum* 2024; 5(4):167–170.

Received: January 03, 2023; **Accepted:** March 05, 2023; **Available online:** September 10, 2024

Corresponding author: Onur Taydas; Sakarya Universitesi Tip Fakultesi, Radyoloji Anabilim Dalı, Sakarya, Turkiye

Phone: +90 264 888 40 00; **e-mail:** taydasonur@gmail.com

 OPEN ACCESS
This work is licensed under a Creative Commons Attribution-NonCommercial 4.0 International License.

Hepatology Forum - Available online at www.hepatologyforum.org

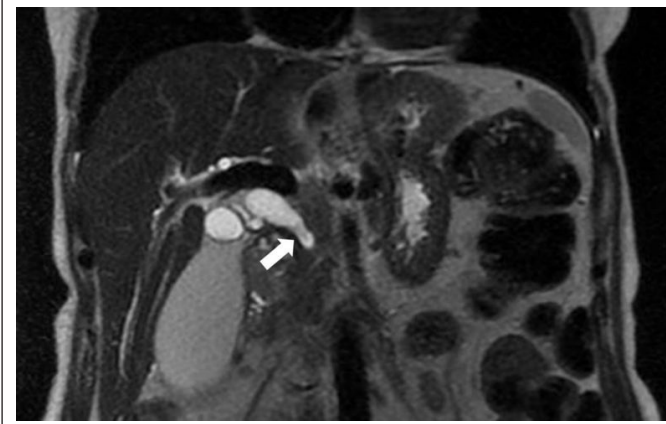


Figure 1. In the coronal T2-weighted magnetic resonance image of a 60-year-old female patient with hyperbilirubinemia, a hypointense lesion (arrow) is observed distal to the common bile duct (CBD), accompanied by dilation of the proximal bile ducts

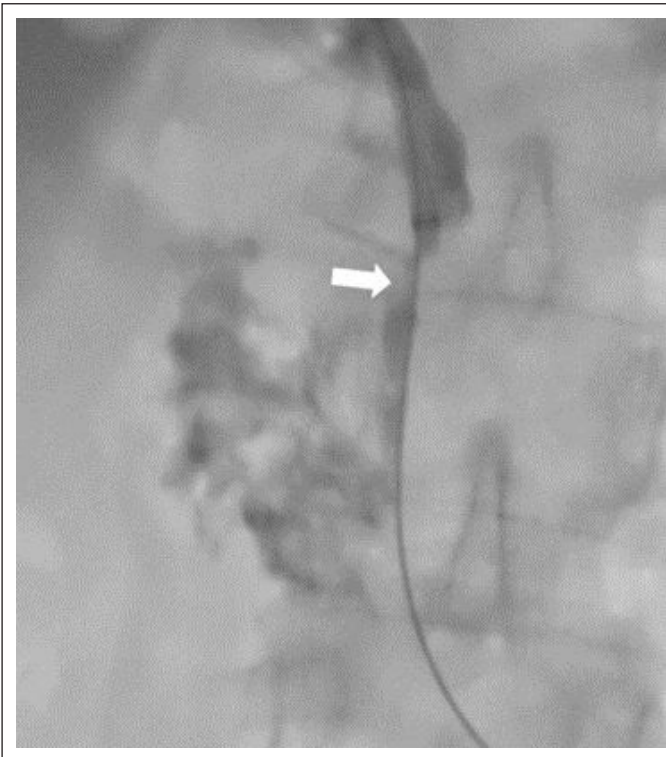


Figure 2. In the percutaneous transhepatic cholangiography image of a 60-year-old female patient with hyperbilirubinemia, a focal stricture (arrow) is observed distal to the common bile duct (CBD), accompanied by dilation of the proximal bile ducts.

All procedures were performed by an interventional radiologist with 5 years of experience in PEFB. To confirm biliary obstruction, MRI was used in 8 patients (Fig. 1), CT in 4 patients, and US in 4 patients. All patients underwent the procedure under local anesthesia and sedoanalgesia, with entry made into the right biliary system in 14 patients (87.5%) and the left biliary system in 2 patients (12.5%). All procedures were conducted in our angiography unit (Siemens, Artis Zee, Erlangen,

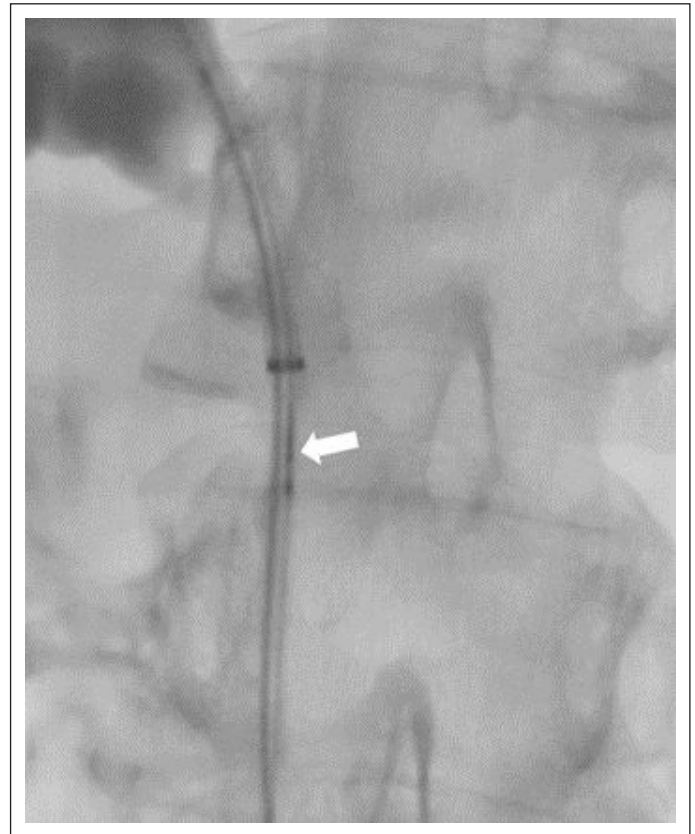


Figure 3. In the percutaneous transhepatic cholangiography image of a 60-year-old female patient with hyperbilirubinemia, the procedure of obtaining a biopsy using an endobiliary brush from the focal stricture (arrow) distal to the common bile duct is observed.

Germany). Prophylactic antibiotic therapy was administered to all patients before the procedure.

For endobiliary brush biopsies, a microbiliary initial access set (Accustick, Boston Medical, Ireland), 0.035-inch standard hydrophilic wire (Zipwire, Boston Medical, Ireland), 7F long vascular sheath (Flexor, Cook Medical, Ireland), and 5.2F brush biopsy material (Canmed, Turkey) were used. First, the area where the lesion was located was determined using the long vascular sheath (Fig. 2). After that, the biopsy brush was passed over the lesion through the wire at least three times to obtain samples (Fig. 3). Tissue samples were placed in formalin solution. After the procedure, all patients had an 8-10F biliary drainage catheter (Flexima, Boston Medical, Ireland) inserted.

The primary outcome measures of our study were technical success and complication rates. Additionally, the average fluoroscopy time and average radiation exposure, calculated in millisieverts (mSv), were assessed. Complications requiring hospitalization for less than 48 hours, managed with minimal therapy or observation, were classified as minor, while complications requiring hospitalization for more than 48 hours or major therapy were considered major. Follow-up imaging was conducted with CT in 8 patients and USG in 6 patients. The advanced follow-up of 2 patients was not performed at our center.

MedCalc (Medcalc ver.12, Ostend, Belgium) was used for statistical analysis. Descriptive statistics were given as median (minimum – maximum) and mean±standard deviation. Categorical variables were stated as frequencies and percentages.

Results

In all 16 patients who underwent PEFB, at least three samples were obtained using correct positioning and biopsy tools, resulting in a technical success rate of 100%. Biliary obstructions were identified in all cases through cholangiography. The locations of obstructions were the common bile duct in 12 patients (75%), hepatic hilum in 2 patients (12.5%), and bilioenteric anastomosis line in 2 patients (12.5%). The mean fluoroscopy time for the patients was 16.2±7.1 minutes, with an average radiation dose of 660±370 mSv.

The biochemical values of the examined patients were significant for cholestasis, with an average total bilirubin value of 9.5±6.5 µmol/L, direct bilirubin value of 4.9±3.3 µmol/L, indirect bilirubin value of 4.6±3.2 µmol/L, gamma-glutamyl transferase (GGT) value of 340±210 IU/L, and alkaline phosphatase (ALP) value of 438±333 IU/L.

Biopsy material obtained from 14 out of the 16 examined patients was deemed sufficient for histopathological diagnosis, while in 2 patients (12.5%), cell detection was not observed in the biopsy samples, resulting in a diagnostic success rate of 87.5%.

Pathological diagnosis in 8 patients (50%) revealed malignancy, while 6 patients (37.5%) had benign findings. Two out of the 16 patients (12.5%) developed liver abscesses requiring drainage after the procedure, classified as major complications.

Discussion

The most significant finding of our study is the demonstration that endobiliary brush biopsy (PEFB) is a method with high technical and diagnostic success rates and a low complication rate. Currently, tissue sampling for cytological and histological characterization of tumor cells, as well as the identification of specific subtypes based on immunohistochemistry, plays a crucial role in determining future individualized treatment protocols. Thus, the precise diagnosis and management of neoplasms constitute a significant component of medical practice.^[5,6] Various methods are employed for this purpose, each having its advantages and disadvantages. Percutaneous endobiliary brush biopsy is particularly utilized when endoscopic methods prove unsuccessful. Although there are differences in technical and diagnostic success rates reported in the literature for PEFB used in biliary obstructions, our study demonstrated a technical success rate of 100%, a diagnostic success rate of 87.5%, and a complication rate of 12.5%. A retrospective case study by Augustin et al.^[9] reported a technical success rate of 100%, a diagnostic success rate of 92.3%, and a complication rate of 15.4%. In a recent meta-analysis conducted by Jeon et al.,^[10] the diagnostic specificity and sensitivity of endobiliary brush biopsy were found to be 81% and 100%, respectively, with a reported major complication rate of 3.1%.

Given that the characterization of tumor cells through cytological and histological examination, as well as the identification of specific subtypes based on immunohistochemistry, influences future treatment protocols, the accurate diagnosis and management of neoplasms remain critical aspects. Different sampling methods are employed for biliary obstructions, leading to variations in accuracy and sensitivity.^[11] Since most biliary neoplasms originate from the biliary endothelium, luminal approaches for biopsy material extraction hold promise for high diagnostic success.^[11–13] Techniques based on endoscopy, particularly endoscopic retrograde cholangiopancreatography (ERCP)-assisted biliary brush biopsy and endoscopic ultrasound-guided fine-needle aspiration biopsy, are considered more reliable and successful diagnostic methods when used in combination.^[14,15]

PEFB can be considered as an alternative method when ERCP-based methods fail in the treatment of obstructive jaundice. However, one limitation of the PEFB method is its limited biopsy depth, leading to insufficient diagnosis of lymph node metastases, tumor infiltration, and external compressions.^[16–18]

Limitations of our study include its retrospective nature and a relatively small number of patients. Therefore, future studies with a larger sample size and multicenter collaboration should be conducted. Additionally, our study did not establish a control group between endoscopic methods and PEFB, making a direct comparison between these two methods incomplete.

Conclusion

In conclusion, PEFB is a method with relatively low complication rates and high sensitivity and accuracy in biliary strictures. It should be considered when endoscopic access proves unsuccessful.

Ethics Committee Approval: The Sakarya University Clinical Research Ethics Committee granted approval for this study (date: 13.04.2023, number: 137).

Author Contributions: Concept – MO, TD, OFS, OT, GD, OFA, MHO; Design – MO, TD, OFS, OT, GD, OFA, MHO; Supervision – MO, TD, OFS, OT, GD, OFA, MHO; Analysis and/or Interpretation – MO, TD, OFS, OT, GD, OFA, MHO; Literature Search – MO, TD, OFS, OT, GD, OFA, MHO; Writing – MO, TD, OFS, OT, GD, OFA, MHO; Critical Reviews – MO, TD, OFS, OT, GD, OFA, MHO.

Conflict of Interest: The authors have no conflict of interest to declare.

Use of AI for Writing Assistance: Not declared.

Financial Disclosure: The authors declared that this study has received no financial support.

Peer-review: Externally peer-reviewed.

References

- Magnuson TH, Bender JS, Duncan MD, Ahrendt SA, Harmon JW, Regan F. Utility of magnetic resonance cholangiography in the evaluation of biliary obstruction. *J Am Coll Surg* 1999; 189:63–72.
- Hann LE, Greatrex KV, Bach AM, Fong Y, Blumgart LH. Cholangiocarcinoma at the hepatic hilum: sonographic findings. *AJR Am J Roentgenol* 1997; 168:985–989.
- Baron RL, Stanley RJ, Lee JK, et al. A prospective comparison of the evaluation of biliary obstruction using computed tomography and ultrasonography. *Radiology* 1982; 145:91–98.
- Li TF, Ren KW, Han XW, et al. Percutaneous transhepatic cholangiobiospy to determine the pathological cause of anastomotic stenosis after cholangiojejunostomy for malignant obstructive jaundice. *Clin Radiol* 2014; 69:13–17.
- Singh A, Gelrud A, Agarwal B. Biliary strictures: diagnostic considerations and approach. *Gastroenterol Rep (Oxf)* 2015; 3:22–31.
- Valle JW, Borbath I, Khan SA, et al. Biliary cancer: ESMO Clinical Practice Guidelines for diagnosis, treatment and follow-up. *Ann Oncol* 2016; 27(suppl 5):v28–v37.
- Zhao XQ, Dong JH, Jiang K, Huang XQ, Zhang WZ. Comparison of percutaneous transhepatic biliary drainage and endoscopic biliary drainage in the management of malignant biliary tract obstruction: a meta-analysis. *Dig Endosc* 2015; 27:137–145.
- Elyaderani MK, Gabriele OF. Brush and forceps biopsy of biliary ducts via percutaneous transhepatic catheterization. *Radiology* 1980; 135:777–778.
- Augustin AM, Steingrüber M, Fluck F, Goetze O, Bley TA, Kickuth R. Percutaneous endobiliary forceps biopsy of biliary strictures for histopathological examination. *Diagn Interv Radiol* 2020; 26:339–344.

10. Jeon TY, Choi MH, Yoon SB, Soh JS, Moon SH. Systematic review and meta-analysis of percutaneous transluminal forceps biopsy for diagnosing malignant biliary strictures. *Eur Radiol*. 2022 Mar;32(3):1747-1756. doi: 10.1007/s00330-021-08301-1.
11. Rossi M, Cantisani V, Salvatori FM, et al. Histologic assessment of biliary obstruction with different percutaneous endoluminal techniques. *BMC Med Imaging* 2004; 4:3.
12. Savader SJ, Lynch FC, Radvany MG, et al. Single-specimen bile cytology: a prospective study of 80 patients with obstructive jaundice. *J Vasc Interv Radiol* 1998; 9:817-821.
13. Jailwala J, Fogel EL, Sherman S, et al. Triple-tissue sampling at ERCP in malignant biliary obstruction. *Gastrointest Endosc* 2000; 51:383-390.
14. Moura DTH, de Moura EGH, Matuguma SE, et al. EUS-FNA versus ERCP for tissue diagnosis of suspect malignant biliary strictures: a prospective comparative study. *Endosc Int Open* 2018; 6:E769-E777.
15. Weilert F, Bhat YM, Binmoeller KF, et al. EUS-FNA is superior to ERCP-based tissue sampling in suspected malignant biliary obstruction: results of a prospective, single-blind, comparative study. *Gastrointest Endosc* 2014; 80:97-104.
16. Sato M, Inoue H, Ogawa S, et al. Limitations of percutaneous transhepatic cholangioscopy for the diagnosis of the intramural extension of bile duct carcinoma. *Endoscopy* 1998; 30:281-288.
17. Duzenli T, Koseoglu H, Akti ES, Yilmaz B. Endoscopic Retrograde Cholangiopancreatography in Patients with Post-Operative Bile Duct Injuries: Experience of a Tertiary Center in Turkey. *Eur J Ther* 2021; 27(2): 142-148.
18. Fu X, Qi H, Qiu Z, Jiang W, Chen Z, Gao F. Outcomes of two types of iodine-125 seed delivery with metal stents in treating malignant biliary obstruction: a systematic review and meta-analysis. *Diagn Interv Radiol*. 2023;29(3):509-519.