

# CASE REPORT

Nagoya J. Med. Sci. 73. 197 ~ 203, 2011

## TOTAL EN BLOC SPONDYLECTOMY FOR L2 CHORDOMA: A CASE REPORT

NORIMITSU WAKAO<sup>1</sup>, SHIRO IMAGAMA<sup>1</sup>, ZENYA ITO<sup>1</sup>, KEI ANDO<sup>1</sup>,  
KENICHI HIRANO<sup>1</sup>, RYOJI TAUCHI<sup>1</sup>, AKIO MURAMOTO<sup>1</sup>, HIROKI MATSUI<sup>1</sup>,  
TOMOHIRO MATSUMOTO<sup>1</sup>, YUKIHIRO MATSUYAMA<sup>1</sup> and NAOKI ISHIGURO<sup>1</sup>

<sup>1</sup>*Department of Orthopedic Surgery, Nagoya University, Nagoya, Japan*  
<sup>2</sup>*Department of Orthopedic Surgery, Hamamatsu University School of Medicine,  
Hamamatsu City, Shizuoka, Japan*

### ABSTRACT

Chordoma is a rare vertebral tumor that develops from the chorda. The high malignant potential of this tumor, which is associated with a poor life prognosis, has been recognized particularly in the case of tumors originating at the mobile spine. In recent years, en bloc resections of such tumors and an increasing emphasis on a complete local cure have resulted in a certain degree of improvement in the prognosis.

This case concerns a 61-year-old male with an L2 chordoma on whom en bloc spondylectomy was performed using a combined anterolateral retroperitoneal, and posterior approach. During the follow-up period, since the transplanted bone was fractured and the rod was broken, a reoperation was performed. Although the surgical margin became intralesional, a favorable course without any metastasis or recurrence during a 10-year postoperative follow-up has been observed. The presenting symptoms, imaging studies, and related literature are reviewed in this report. Thus, the method used in this case may also be considered potentially effective in achieving a radical cure in advanced cases with a local recurrence.

Key Words: Lumbar spine, Chordoma, Total en bloc spondylectomy, Surgical treatment

This is an Open Access article distributed under the Creative Commons Attribution-NonCommercial-NoDerivatives 4.0 International License. To view the details of this license, please visit (<http://creativecommons.org/licenses/by-nc-nd/4.0/>).

### INTRODUCTION

Chordoma is a rare vertebral tumor that develops from the chorda, which is a fetal remnant. Despite the fact that it is histologically slow-growing, the highly malignant potential of this tumor, which is associated with a poor life prognosis, has been recognized particularly in the case of tumors originating at sites other than the sacrum. However, in recent years, en bloc resections of the tumor and increasing emphasis on a complete local cure have enabled a certain degree of improvement in the prognosis. In the present case, we performed a total en bloc spondylectomy for an L2 chordoma. Although the resection was intralesional, we observed a favorable course without any metastasis or recurrence during a 10-year postoperative follow-up. This report contains the details of this case and a review of the pertinent literature.

---

Corresponding Author: Norimitsu Wakao,

Department of Orthopedic Surgery, Nagoya University Graduate School of Medicine, 65 Tsurumai-cho,  
Showa-ku, Nagoya 466-8550, Japan

Phone: +81-52-744-1908, Fax: +81-52-744-2260, E-mail: [nwakao@med.nagoya-u.ac.jp](mailto:nwakao@med.nagoya-u.ac.jp)

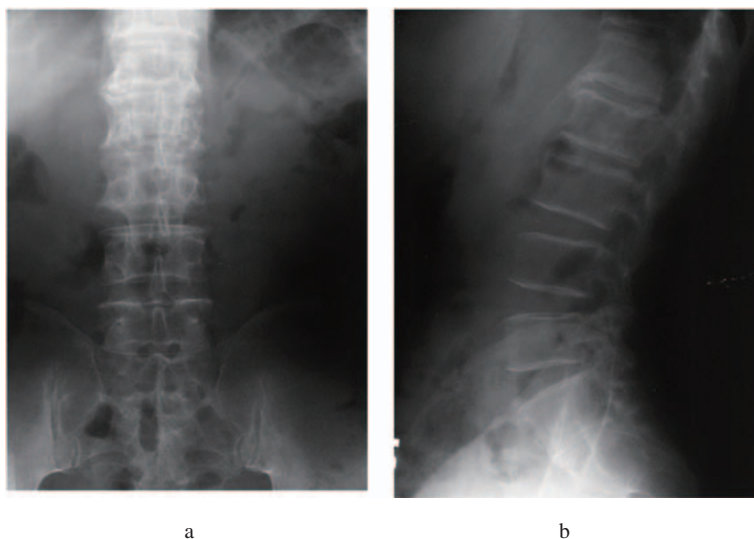
## CASE REPORT

A 61-year-old male presented with low back and right lower-extremity pain. He gradually developed low back pain of no obvious origin. Right lower extremity pain also developed 2 years later. After diagnostic imaging at a nearby hospital indicated the presence of a metastatic spinal neoplasm, a biopsy was performed. Bone metastasis from renal carcinoma was then diagnosed. A subsequent search for a primary lesion was unsuccessful, and the patient was referred to our hospital.

During a physical examination at the initial diagnosis, no abnormalities were detected in either muscle strength or sensation, though a slight tenderness was noted in the lumbar area.

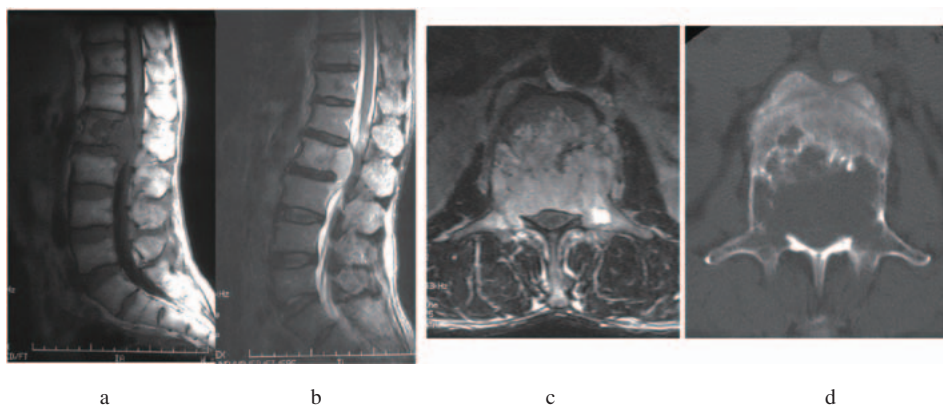
At the initial examination, an X-ray lateral view revealed an osteoclasia extending from the center to the posterior of a vertebral body (Fig. 1 a, b). MRI showed a lesion that partially protruded into the spinal canal at L2; it was hypointense on T1-weighted images and hyperintense on T2-weighted images, and gadolinium administration produced no contrast effect (Fig. 2 a, b, c, d). No metastatic foci were evident on scintigraphy or head/chest CT (data not shown). The second biopsy conducted in our institution proved this tumor to be a chordoma. As for the progression-stage classification on the basis of imaging findings, the tumor was seen to extend from the vertebral body center to the spinal canal/right pedicle. It was classified as a 4–10 zone and intraosseus to extradural according to the Weinstein-Bosiani-Biagini (WBB) classification,<sup>1)</sup> and as type 5 according to the surgical classification of a vertebral tumor (SCVT) advocated by Tomita.<sup>2)</sup> To resect the tumor as a single mass, we decided to perform a total en bloc spondylectomy using a combined anterolateral, retroperitoneal, and posterior approach to this case.

The operation was initiated from the posterior. The segment artery and its bifurcation were treated, and the pedicle was severed with a T-saw. The L2 vertebral arch, including spinous process/transverse process/inferior and superior facets, was resected en bloc. Using pedicle screws, two vertebrae above and two below were fixed (T12-L4). Next, using a left anterolateral-retroperitoneal approach, the lumbar segmental artery was ligated, the area around the vertebral body was bluntly dissected manually, and the L2 vertebral body was resected as a single mass.

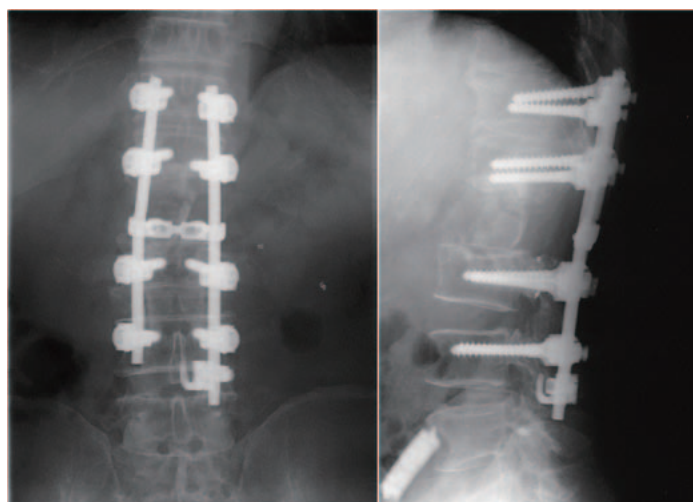


**Fig. 1** X-ray images at initial examination; A-P view (a) and lateral view (b).

## TOTAL EN BLOC SPONDYLECTOMY FOR L2 CHORDOMA




**Fig. 2** Tumor partially protruding into pedicle and spinal canal. MR and CT images.  
 a: MR T1-weighted sagittal image, b: MR T2-weighted sagittal image, c: MR T2-weighted axial image,  
 d: CT axial image.



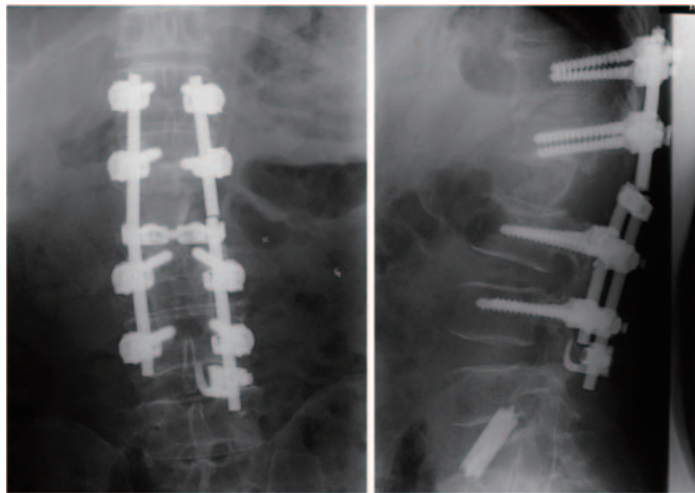
**Fig. 3** After first operation (total en bloc spondylectomy), fusion area was T12-L4 with instruments.

An iliac bone transplant was performed to provide an anterior strut graft (Fig. 3). Operative time was 13 hours 25 minutes, and the volume of bleeding was 1945 ml. CT images after the operation showed that a total spondylectomy had been completed (Fig. 4).

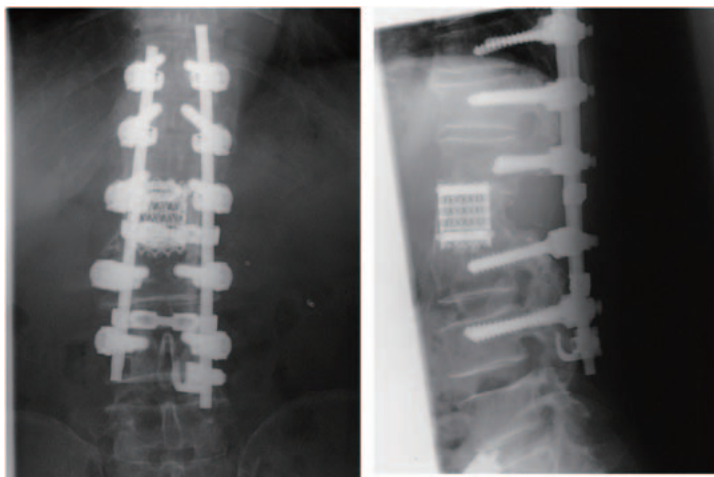
After the primary operation, no adjuvant therapy (including radiation/chemotherapy) was administered. The subsequent course was favorable and without any complications. However, low back pain developed when the patient carried a heavy load 5 months after the operation. Since the transplanted bone was fractured and the rod was broken (Fig. 5), a reoperation was performed. The fusion level was extended from a T11-L4 with instruments. The transplanted bone was removed via a left anterolateral approach and replaced by a titanium cage filled with autologous fibula bone (Fig. 6). A histopathological examination of the tissues surrounding the transplanted bone was performed, but it revealed no tumor cells or any evidence of infection. At present, 10



**Fig. 4** CT images after primary operation. L2 was totally resected. a: CT axial view, b: CT sagittal reconstruction image. c: CT coronal reconstruction image.




**Fig. 5** Five months after primary operation; transplanted bone was fractured and rod was broken.

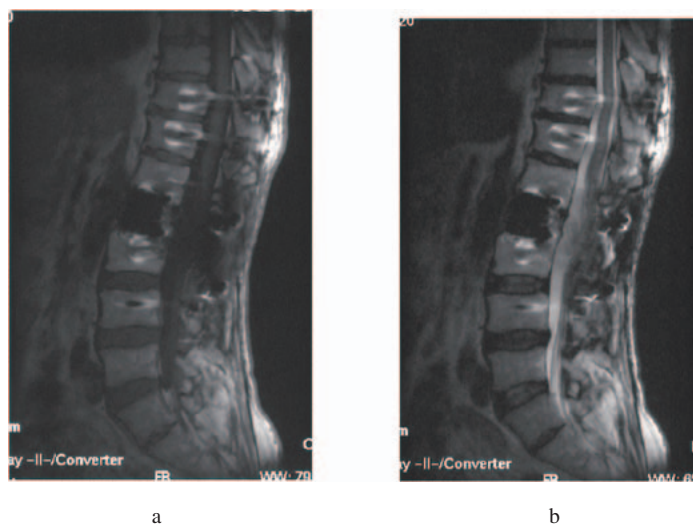


**Fig. 6** After second operation, fusion area was T11-L4 with instruments; transplanted bone was removed and a titanium cage filled with autologous fibula bone was used.

## TOTAL EN BLOC SPONDYLECTOMY FOR L2 CHORDOMA



**Fig. 7** CT images 10 years after second operation. Transplanted mesh cage implant with fibula was fused. a: CT axial view, b: CT sagittal reconstruction image. c: CT coronal reconstruction image.



**Fig. 8** MR images obtained 10 years after the second operation; no recurrence/metastasis detected. a: MR T1-weighted sagittal image; b: MR T2-weighted sagittal image.

years postoperatively, the patient's course has been favorable, with no recurrence/metastasis, nor was any subsequent implant failure detected on CT images (Fig. 7) or MRI (Fig. 8).

## DISCUSSION

Chordoma is a tumor that develops from the chorda, which is a fetal remnant. Chordoma accounts for approximately 1% of primary bone tumors and approximately 3% of primary malignant bone tumors; it exhibits a predilection for males aged 40–60 years.<sup>3)</sup> Chordoma has been known to occur in the sacrum in 50–80% of cases, in the base of the skull in 35%, and



in the cervical vertebrae in 10%; an occurrence in the thoracic or lumbar spine is rare. The central location of these tumors often renders total resection difficult, and these tumors display a marked clinical malignancy with frequent local recurrence/metastasis. Moreover, since only minimal benefit is derived from adjuvant therapy, such as radiotherapy or chemotherapy, treatment is particularly difficult.

As opposed to cases originating in the sacrum, it is almost impossible to achieve a wide surgical margin in the lumbar spine because of the need for spinal cord preservation, and yet control of a local recurrence is essential for preserving life.<sup>4)</sup> Reflecting these difficulties, local recurrence/metastasis rates have been reported to be high in cases originating in the lumbar spine compared with cases sacral in origin, in which recurrences are usually observed 1–3 years after the initial operation.<sup>5)</sup> Prior to the 1980s, piecemeal resection was a common treatment plan for lumbar spine chordoma, with a majority of such cases developing a recurrence within 3 years and exhibiting a poor prognosis.<sup>6)</sup> Subsequently, however, en bloc spondylectomy, which aims for a higher radical cure rate, has been increasingly performed. Recently, the long-term clinical outcome for localized cases (SCVT type 1, 2) has improved remarkably.<sup>7)</sup>

After the MEDLINE search was conducted for the key words “spinal chordoma spondylectomy,” 46 case reports of lumbar spine chordoma in the literature were reviewed, 9 of which were subjected to en bloc resection; information regarding their excision margin and prognosis was available.<sup>4,8,9)</sup> In only 3 of these 9 cases, patients survived for more than 5 years, underscoring that even if an en bloc spondylectomy is performed, the rates of recurrence and tumor-related death remain high. Moreover, if the tumor extends to the pedicle, the surgical margin inevitably becomes intralesional. However, apart from the detached pedicle, a margin can be secured wherever a soft tissue barrier exists. Therefore, when compared with the conventional piecemeal procedure, an en bloc spondylectomy ensures a reduced residual tumor and less contamination by tumor cells during an operation; both these factors are advantageous for recurrence prevention. Unlike other malignant tumors, chordoma generally resists radiotherapy or chemotherapy. Thus, development of a radical treatment method including total en bloc spondylectomy would provide the key to overcoming this tumor.

The patient mentioned in this report has shown a favorable course without any metastasis or recurrence during a 10-year postoperative follow-up, despite the fact that the tumor was an SCVT 5 type and involved an intralesional resection. Thus, the method used in this case may also be considered potentially effective for achieving a radical cure in advanced cases.

## CONCLUSION

We performed a total en bloc spondylectomy for a chordoma of the rare L2 generation. The tumor has not recurred for a period of over 10 years postoperatively, and the total gross section of the tumor is significant even should the surgical margin become intralesional.

## REFERENCES

- 1) Boriani S, Biagini R, De Iure F. En bloc resections of bone tumors of the thoracolumbar spine. A preliminary report on 29 patients. *Spine*, 1996 15; 21 (16): 1927–31.
- 2) Kawahara N, Tomita K, Matsumoto T. Total en bloc spondylectomy for primary malignant vertebral tumors. *Chir Organi Mov*, 1998; 83 (1–2): 73–86.
- 3) General Rules for Clinical and Pathological Studies on Malignant Bone Tumors. (The 3rd Edition): The Japanese Orthopaedic Association Committee of Tumors: Kanehara & Co., Ltd. July 2000.
- 4) Bergh P, Kindblom LG, Gunterberg B. Prognostic factors in chordoma of the sacrum and mobile spine: a

## TOTAL EN BLOC SPONDYLECTOMY FOR L2 CHORDOMA

- study of 39 patients. *Cancer*, 2000; 88 (9): 2122–2134.
- 5) Boriani S, Chevalley F, Weinstein JN. Chordoma of the spine above the sacrum. Treatment and outcome in 21 cases. *Spine*, 1996; 21 (13): 1569–1577.
  - 6) Ariel IM, Verdu C. Chordoma: an analysis of twenty cases treated over a twenty-year span. *J Surg Oncol*, 1975; 7 (1): 27–44.
  - 7) Heary RF, Vaccaro AR, Benevenia J. “En-bloc” vertebrectomy in the mobile lumbar spine. *Surg Neurol*, 1998; 50 (6): 548–56.
  - 8) Hsu KY, Zucherman JF, Mortensen N. Follow-up evaluation of resected lumbar vertebral chordoma over 11 years: a case report. *Spine*, 2000; 25 (19): 2537–2540.
  - 9) Bosma JJ, Pigott TJ, Pennie BH. En bloc removal of the lower lumbar vertebral body for chordoma. Report of two cases. *J Neurosurg*, 2001; 94 (2 Suppl): 284–291.

