
Case Report

Aggressive Childhood-onset Papillary Craniopharyngioma Managed With Vemurafenib, a BRAF Inhibitor

Constance L. Chik,¹ Frank K. H. van Landeghem,^{2,3} Jacob C. Easaw,⁴ and Vivek Mehta⁵

¹Division of Endocrinology and Metabolism, Department of Medicine, University of Alberta, Edmonton, AB T6G 2G3, Canada; ²Department of Laboratory Medicine & Pathology, University of Alberta, Walter Mackenzie Health Sciences Centre, Edmonton, AB T6G 2B7, Canada; ³Cancer Research Institute of Northern Alberta (CRINA), University of Alberta, Edmonton, AB T6G 2E1, Canada; ⁴Cross Cancer Institute, University of Alberta, Edmonton, AB T6G 1Z2, Canada; and ⁵Division of Neurosurgery, Department of Surgery, University of Alberta, Walter Mackenzie Health Sciences Centre, Edmonton, AB T6G 2B7, Canada

ORCID number: 0000-0001-9609-0896 (C. L. Chik).

Received: 27 October 2020; Editorial Decision: 11 March 2021; First Published Online: 16 March 2021; Corrected and Typeset: 23 April 2021.

Abstract

The papillary subtype of craniopharyngioma (CP) rarely occurs in children and commonly presents as a suprasellar lesion. Patients with papillary CPs frequently harbor the *BRAF*-V600E mutation, and treatment with a BRAF inhibitor results in tumor shrinkage in several patients. Herein, we report a patient with childhood-onset papillary CP treated with vemurafenib for 40 months after multiple surgeries. At age 10, he presented with growth failure secondary to an intrasellar cystic lesion. He had 3 transsphenoidal surgeries before age 12 and a 4th surgery 25 years later for massive tumor recurrence. Pathology showed a papillary CP with positive *BRAF*-V600E mutation. Rapid tumor regrowth 4 months after surgery led to treatment with vemurafenib that resulted in tumor reduction within 6 weeks. Gradual tumor regrowth occurred after a dose reduction of vemurafenib because of elevated liver enzymes. He had further surgeries and within 7 weeks after stopping vemurafenib, there was massive tumor recurrence. He resumed treatment with vemurafenib before radiation therapy and similar tumor shrinkage occurred within 16 days. In this patient with childhood-onset papillary CP that was refractory to multiple surgeries, the use of vemurafenib resulted in significant tumor shrinkage that allowed for the completion of radiation therapy and tumor control.

Key Words: vemurafenib, papillary craniopharyngioma, *BRAF* mutation

Craniopharyngiomas (CPs) are rare epithelial tumors that typically arise in the suprasellar region of the brain, and patients commonly present with symptoms of increased

intracranial pressure, visual impairment, and endocrine deficiencies [1]. The papillary subtype of CPs (PCPs) occur predominantly in adults, with 95% of patients harboring

the *BRAF*-V600E mutation, and lead to activation of the Ras/Raf/MEK/ERK pathway [2]. In comparison, the adamantinomatous subtype of CPs (ACPs) have a bimodal peak of incidence (5–15 years and 45–60 years), with 65% of patients having mutations in exon 3 of *CTNNB1* (β -catenin), resulting in Wnt activation and alterations of the MEK/ERK pathway [1, 3]. The distinct clinical features, mutations, and exclusive epigenetic and expression profiles of the 2 subtypes of CPs suggest their distinct pathogenesis [4]. Initial management of CPs includes surgery and/or radiation therapy, and recurrence or residual CPs can be hard to manage and are frequently associated with significant morbidity and mortality [1]. The dramatic responses of several patients to treatments with a BRAF inhibitor with or without an MEK inhibitor [5–12] implies an oncogenic role of *BRAF* mutations in PCPs. Herein, we describe a patient with childhood-onset PCP managed with 3 transsphenoidal surgeries and presented 25 years later with aggressive recurrence in spite of further surgeries. The confirmation of a PCP with *BRAF*-V600E mutation led to treatment with vemurafenib, a BRAF inhibitor, and this resulted in a significant tumor reduction that allowed for completion of radiation therapy and stabilization of the residual tumor. Written informed consent for publication of the clinical details and clinical images was obtained from the patient.

Case Report

History and examination

A 37-year-old man presented with a 1-year history of severe headache associated with vomiting, visual impairment, and recurrent sinus infections. This was associated with a decline in his strength and reduced libido. He has fathered 2 children, ages 3 and 6. His height was 182 cm and his weight was 106 Kg, giving him a body mass index of 32 kg/M². There was bitemporal hemianopsia on clinical examination. Endocrine investigations confirmed hypopituitarism (Table 1). He started treatment with hydrocortisone, levothyroxine, and topical testosterone gel. Magnetic

Resonance Imaging (MRI) showed a 3.4-cm enhancing mass in the sella, with suprasellar extension and chiasmal compression (Fig. 1A).

Review of the only available medical record, a discharge summary of his 3rd surgery by his pediatric endocrinologist, indicated that at age 10 he underwent investigations for severe headaches and falling off of the growth curve for several years. Investigations showed an intrasellar mass lesion on MRI of the sella, delayed bone age and hypopituitarism. Transsphenoidal surgery showed a cystic lesion. He started treatment with levothyroxine and his growth velocity normalized. With image evidence demonstrating the recurrence of a large cystic sellar lesion causing chiasmal compression over the next 2 years, he had 2 additional transsphenoidal surgeries. Pathologic report from his 3rd surgery in 1991 showed a CP with no further characterization. He was discharged on hydrocortisone and levothyroxine. The patient recalled he had blood tests and both medications were discontinued 2 years after his 3rd surgery. There was no information available on any endocrine testing completed. He attained an adult height of 181 cm, well within the target centile range of his parents from 170 to 187 cm. Other than recurrent sinusitis, he was well until age 36, when he experienced increased headaches and vision decline.

To manage his massive tumor recurrence, the patient had his 4th transsphenoidal surgery with an intraoperative MRI (Fig. 1B). Pathology revealed a PCP (Fig. 2A, upper panel), and immunohistochemical staining for β -catenin showed translocation into the nucleus in approximately 5% of the tumor cells (Fig. 2A, middle panel). The proliferation index Ki-67 was variable, being as high as 50% in the basal layer of the epithelial tumor (Fig. 2A, lower panel). Molecular testing confirmed positive mutation for *BRAF*-V600E and additional testing completed at MD Anderson Hospital (Houston, TX) showed negative mutation in exon 3 of *CTNNB1*.

After surgery, his symptoms improved for 2 weeks before he noted recurrence of headache, nausea, vomiting, and vision changes. With rapid tumor regrowth confirmed on MRI 41 days after surgery, the patient was assessed for

Table 1. Hormonal results prior to his fourth transsphenoidal surgery indicating hypopituitarism

Test	Value	Reference Range
Cortisol	38 nmol/L	85–620 nmol/L
Free thyroxine	4.3 pmol/L	9.0–23.0 pmol/L
Total testosterone	<0.2 nmol/L	8.0–29.5 nmol/L
Insulin growth factor 1	74 μ g/L	84–246 μ g/L
Prolactin	1.2 μ g/L	<21.0 μ g/L
Luteinizing hormone	0.3 U/L	<12.0 U/L
Follicle Stimulation hormone	0.7 U/L	<7.0 U/L
Thyroid Stimulation hormone	1.54 mU/L	0.2–4.0 mU/L

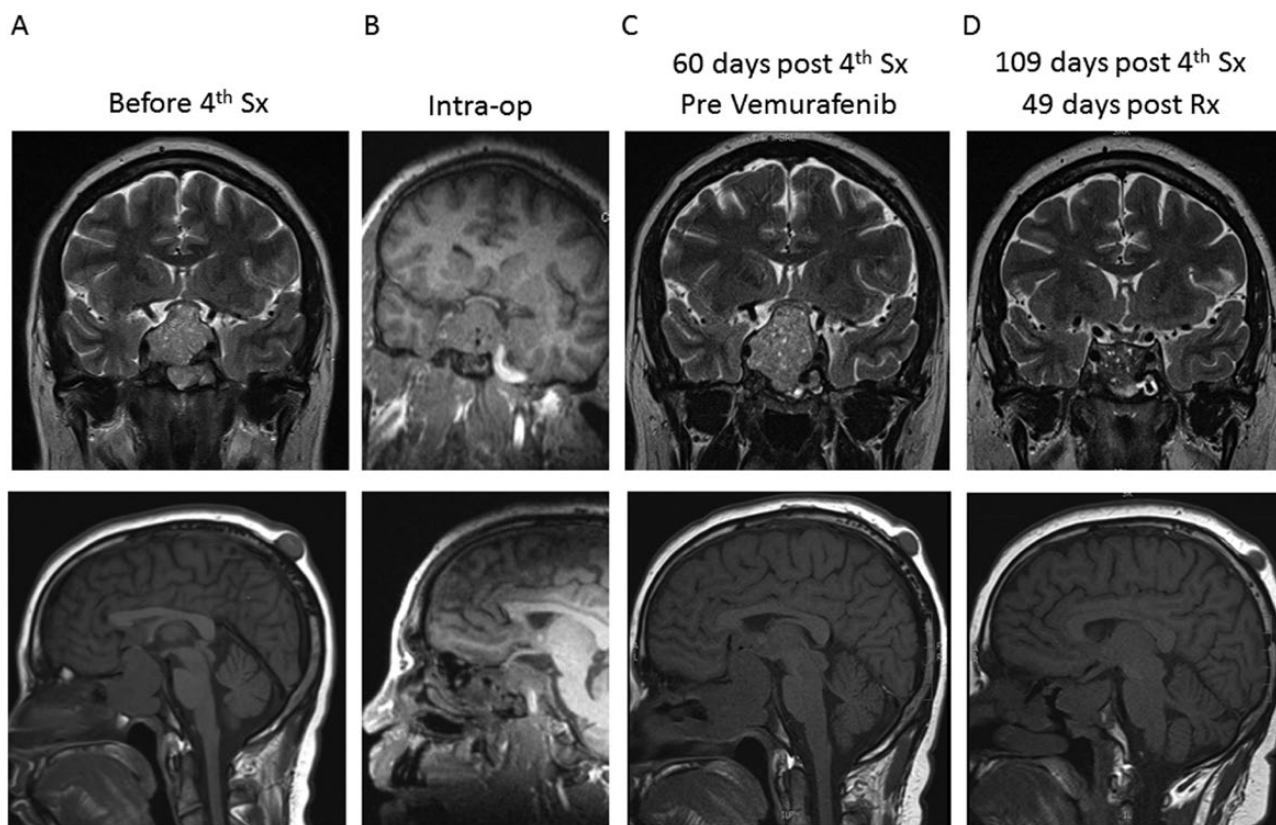


Figure 1. MRI scans around the time of his 4th transsphenoidal surgery and after treatment with vemurafenib. **A:** MRI scans before surgery that demonstrated a 3.4-cm enhancing mass in the sella with extension into the suprasellar cistern causing elevation of the optic chiasm. **B:** Intraoperative MRI that showed partial resection of the tumor. **C:** MRI scans 60 days after the 4th transsphenoidal surgery that showed rapid tumor regrowth. **D:** MRI scans that showed a 55% reduction in tumor size 49 days after treatment with vemurafenib. Abbreviations: Intra-op, Intraoperative MRI; MRI, Magnetic resonance imaging; Rx, treatment with vemurafenib; Sx, surgery.

further treatment. Options considered included radiation therapy, further surgical resection, or medical therapy with a BRAF inhibitor.

Vemurafenib therapy and follow-up

Sixty days after surgery (Fig. 1C), he started treatment with a BRAF inhibitor, vemurafenib 960 mg twice daily, provided through the Director's privilege of the Cross Cancer Institute (Edmonton, AB), as the medication was not covered by his insurance plan. The patient noted clinical improvement within 5 days and there was a 55% reduction in tumor volume after 49 days (Fig. 1D). However, 5 months after treatment, he developed arthralgia, myalgia, photosensitivity, and elevated liver enzymes, and the dose of vemurafenib was reduced by 50%. With modest tumor regrowth, the dose of vemurafenib was increased to 75% and the tumor was stable for 8 months.

With further vision decline from a cystic lesion on the left side (Fig. 3A), he had a craniotomy for further resection of the tumor (Fig. 3B) that was complicated by a cerebrospinal fluid leak requiring surgical repair and additional tumor resection via the transsphenoidal

approach. Pathology revealed a PCP and, compared with the tumor prior to treatment with vemurafenib, immunohistochemistry for β -catenin showed fewer tumor cells with nuclear expression, and Ki-67 of the basal layer was lower at 8% (Fig. 2B).

Thirty-four days after his 5th transsphenoidal surgery, his severe headache recurred and there was MRI evidence of rapid tumor regrowth (Fig. 3C). On full dose vemurafenib and high dose dexamethasone, his symptoms improved, and within 16 days a similar reduction in tumor volume was noted (Fig. 3D). He completed intensity-modulated radiotherapy, 5400 cGY in 30 fractions. Postradiation, he has continued treatment with vemurafenib until the present time. He had intermittent dose interruptions because of liver enzyme elevations and intolerance to the treatment.

Seventeen months after radiation therapy, there was gradual enlargement of a cystic component in the area of the optic chiasm (Fig. 4A). He had gamma knife radiotherapy, and MRI after 3 months showed a reduction in size of the cystic component and a further improvement of the residual PCP (Fig. 4B). Related to his treatments, including at times high dose dexamethasone, he had significant weight gain, steroid-induced diabetes requiring treatment with insulin while on

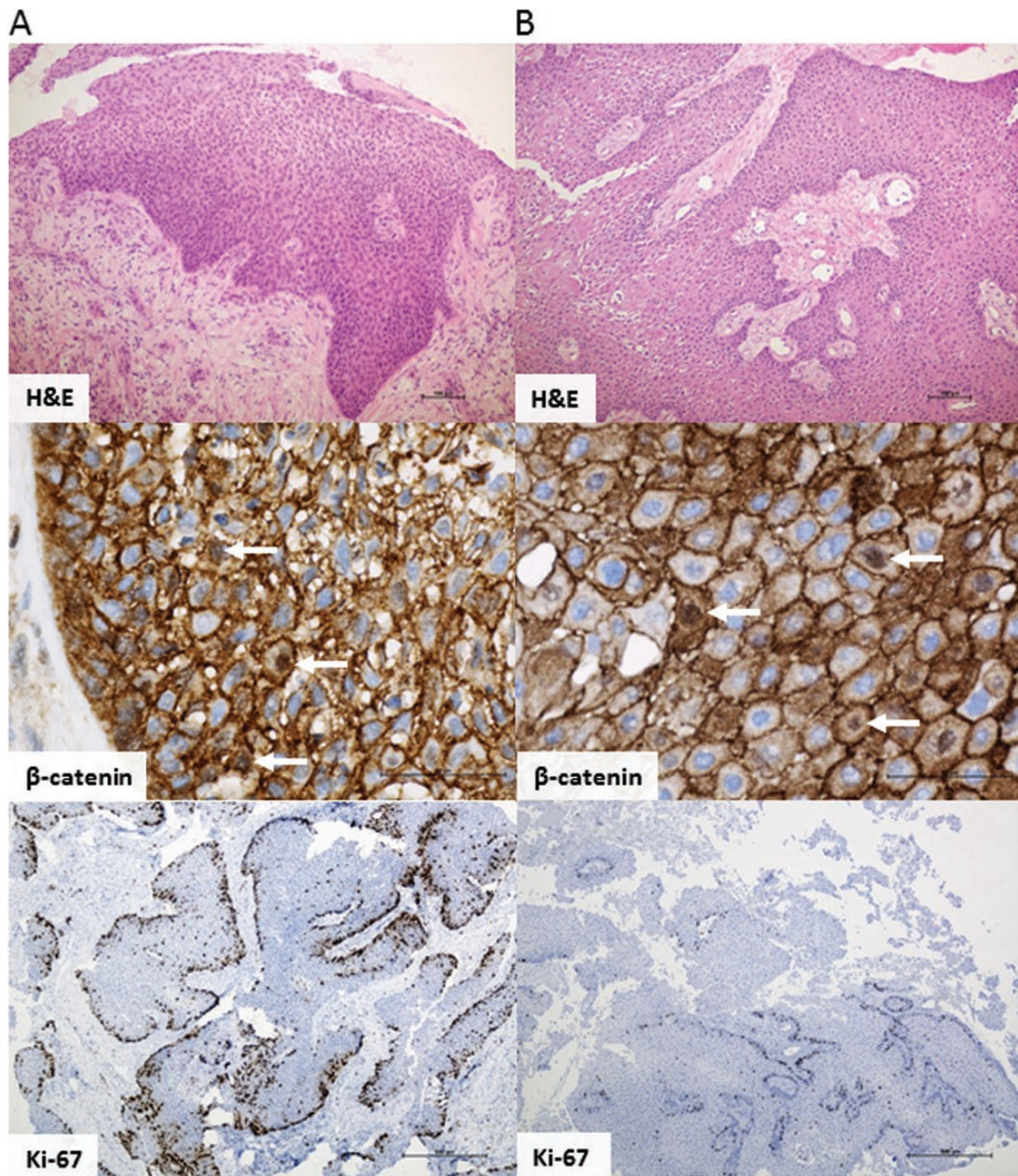


Figure 2. Pathology of the PCP from his 4th and 5th transsphenoidal surgeries. **A:** H&E staining that showed well-differentiated non-keratinizing squamous epithelium (upper panel); IHC staining for β -catenin that showed positive expression in the cytoplasm and 5% of tumor cells with nuclear expression (middle panel); IHC for the proliferation index, Ki-67, was varying and up to 50% in basal layers (lower panel). **B:** H&E staining that showed a PCP (upper panel), IHC for β -catenin that showed fewer tumor cells with nuclear expression (middle panel), and Ki-67 that showed up to 8% in basal layers (lower panel) after treatment with vemurafenib for 63 weeks. Abbreviations: H&E, hematoxylin and eosin; IHC, immunohistochemical; PCP, papillary craniopharyngioma.

high dose dexamethasone, and worsening of his partial central diabetes insipidus, managed with desmopressin 0.1 mg at bedtime. On a diabetic meal plan, his recent hemoglobin A1c was 5.4% and he had no issues with hyponatremia or other electrolyte abnormalities. In spite of the compromised vision, his quality of life has been acceptable and he has been able to assist in the care of his daughters.

Discussion

Positive *BRAF* mutations have been identified in many cancer types, including melanomas, colorectal cancers, and thyroid cancers [13]. In the treatment of melanomas, the addition of an MEK inhibitor to BRAF inhibition reduces the emergence of tumor resistance and the development of secondary squamous cell skin carcinomas, as well

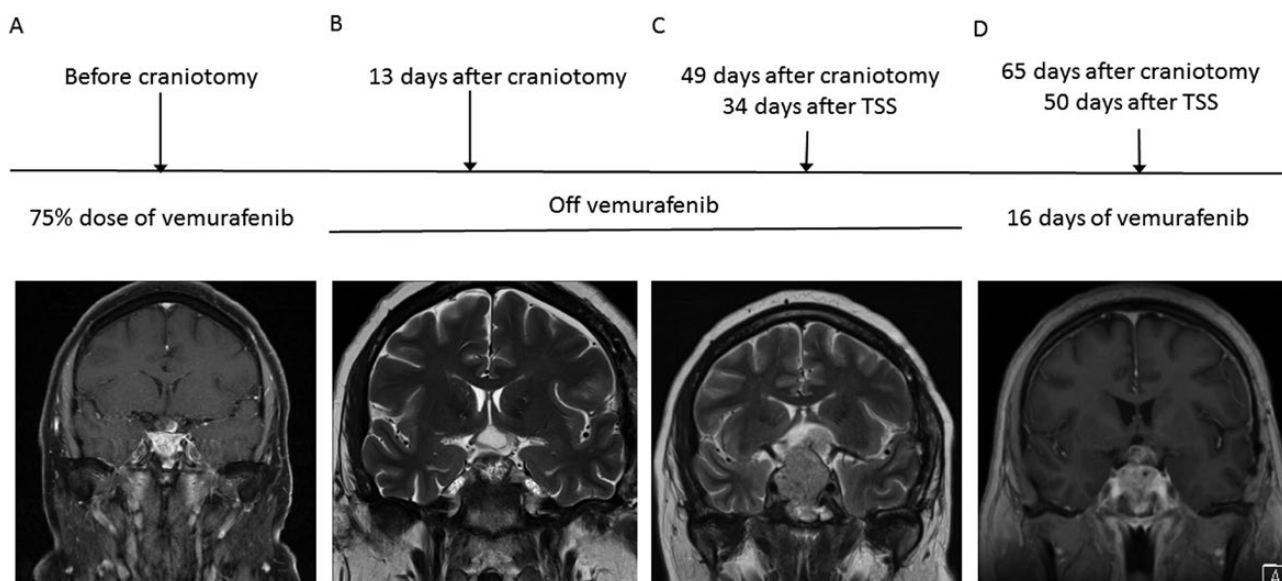


Figure 3. MRI scans before and after his craniotomy followed by his 5th transsphenoidal surgery and treatment with vemurafenib. **A:** MRI scan demonstrating tumor regrowth, more cystic than solid by the optic apparatus while on a 75% dose of vemurafenib. **B:** MRI scan 13 days after a craniotomy that showed partial tumor resection. **C:** MRI scan 34 days after his 5th transsphenoidal surgery that showed rapid tumor regrowth while off treatment with vemurafenib. **D:** MRI scan after 16 days treatment with full dose vemurafenib, and there was a 55% reduction in tumor size. Abbreviations: MRI, Magnetic resonance imaging; TSS, transsphenoidal surgery.

as improves the patient's survival [14]. The recognition of *BRAF-V600E* mutations in PCP led to the use of a BRAF inhibitor in patients with PCPs [5–12].

Together with our patient, 9 patients with PCPs have been treated with either vemurafenib or dabrafenib, a BRAF inhibitor, and 5 in combination with trametinib, an MEK inhibitor (summarized in Table 2). Regardless of the protocol used, all had favorable responses, at least initially, ranging from partial to complete tumor resolution, and the earliest response was noted a few days after treatment. The duration of treatment was variable ranging from 7 weeks to over 2 years, and the first 6 reported cases were treated for less than 1 year. With the exception of 1 patient who received dabrafenib and trametinib after biopsy of his PCP [10], all had recurrent tumors in which 1 or multiple prior surgical attempts had failed.

Based on treatments of other types of cancers such as melanomas, adverse effects including rash, fever, arthralgia, fatigue, alopecia, nausea, photosensitivity, and elevated liver enzymes occur in 5% to 50% of patients treated with BRAF inhibitors [15]. Other adverse effects of BRAF and MEK inhibitors of relevance to the management of patients similar to ours include hyperglycemia, with potential worsening of glycemic control in patients with known diabetes (reported with dabrafenib but not vemurafenib), and hyponatremia or other electrolyte imbalances due to nephrotoxicity [15, 16]. In our patient, elevation of liver enzymes and arthralgia led to a dose interruption of vemurafenib and rapid tumor regrowth. His electrolytes have remained normal while on

desmopressin, and hyperglycemia only occurred when he was on high dose dexamethasone.

Fifteen months after treatment with vemurafenib, the patient required additional surgeries followed by radiation therapy. Re-initiation of treatment resulted in similar tumor shrinkage. Further dose reduction from elevated liver enzymes may have contributed to the growth of a cystic component that was managed successfully with gamma knife radiotherapy. The subsequent tumor reduction probably reflects the combined effect of radiation therapy and treatment with a BRAF inhibitor. Our patient's response differed from a previous patient who had prior surgeries and radiation therapy in which a dose interruption of 3 months resulted in a partial response followed by rapid tumor regrowth and discontinuation of therapy [5].

Our patient is unusual because he has childhood-onset PCP rather than ACP, as less than 2% of the CPs presented in children are of the papillary subtype even though 1 of the 3 patients in the discovery set used for exome sequencing that identified the *BRAF* mutation in PCPs was from a 9 year old [2]. Another interesting aspect of the case is the apparent improvement of his hypopituitarism after his childhood surgeries, though we were not able to obtain the results of his original endocrine investigations. Evidence in support of his improved hypopituitarism included his adult height that was 2.5 cm above his midparental height and that he fathered 2 children without growth hormone or testosterone replacement therapy. In general, worsening rather than recovery of pituitary function occurs after surgical treatment of CPs [1, 17]. However, in a case series of

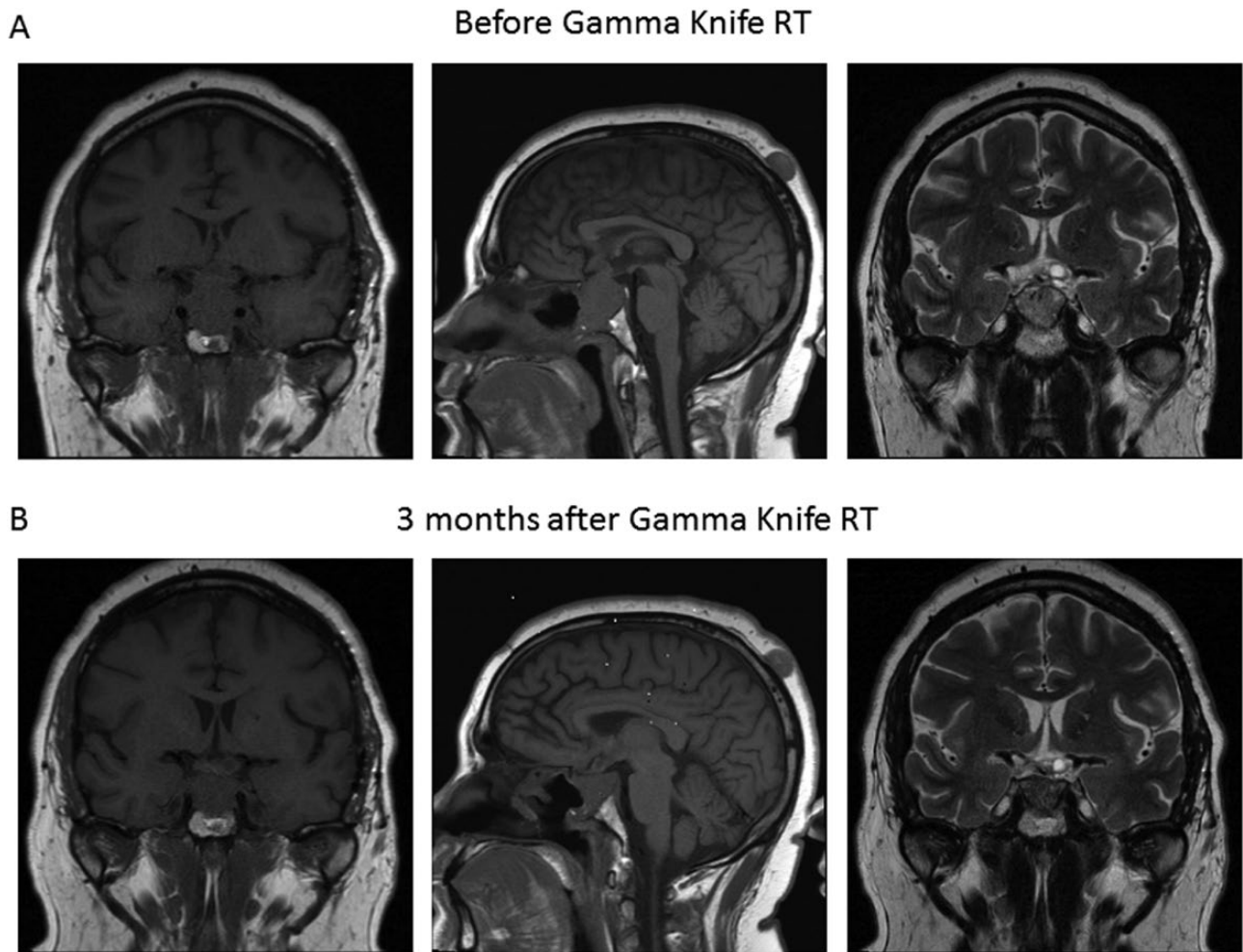


Figure 4. MRI scans before and after gamma knife radiotherapy. **A:** MRI scans demonstrating a gradual enlargement of a cystic component in the area of the optic chiasm while on a 50% dose of vemurafenib. **B:** MRI scans 3 months after gamma knife radiotherapy that showed a reduction in size of the cystic component as well as the residual papillary craniopharyngioma. Abbreviations: MRI, Magnetic resonance imaging; RT, radiotherapy.

16 adult patients with PCPs, 7 had improved anterior pituitary function months after surgery [17].

Fujio et al [18] recently proposed that patients older than 18 years, absence of calcification, and supradiaphragmatic location are the 3 presurgical diagnostic criteria for PCP that can predict patients with a positive *BRAF* mutation and therefore suitable for neoadjuvant treatment with a *BRAF* inhibitor [18]. The proposed diagnostic criteria have not been validated and probably would not be applicable to our patient who has childhood-onset PCP. Moreover, all the patients with PCPs treated with a *BRAF* inhibitor and summarized in Table 2 had pathological confirmation of a positive *BRAF* mutation.

Certain MRI features may also predict *BRAF*-mutated PCPs and may be of potential use to assess patients for the treatment with a *BRAF* inhibitor before surgery. In a recent study, the presence of 3 of 5 MR features, suprasellar in location, spherical, predominantly solid, homogeneously enhancing, and with a thickened pituitary stalk, can predict

a *BRAF*-mutated CP with high sensitivity and specificity [19]. Even though the initial MR is no longer available, 3 of the 5 features, suprasellar in location, predominantly solid, and with a thickened pituitary stalk were probably absent in our patient. The usefulness of the MRI features in excluding ACP is unclear.

Among multiple biomarkers that may predict tumor recurrence [20, 21], 2 were assessed—the proliferative index Ki-67 and nuclear localization of β -catenin. Before treatment with vemurafenib, Ki-67 was as high as 50% in the basal layer. After treatment with vemurafenib for 14 months, Ki-67 of the basal layer was much lower at 8%. Similar to our patient, a reduction in Ki-67 from 22.1% to <0.5% has been reported in a patient after treatment with dabrafenib followed by trametinib for 57 days [6]. In both patients, this allowed for completion of radiation therapy. In our patient, 10 months after re-initiation of vemurafenib in conjunction with radiation therapy, there was only minimal tumor progression

Table 2. Response and adverse reactions to targeted molecular therapy in *BRAF*-V600E–positive papillary craniopharyngiomas

Case	Age	Gender	Previous Treatments + Treatment After Targeted Therapy	Drugs and Total Duration of Treatment	Response to Treatment	Adverse Reactions
Aylwin et al [5]	57 (27 at diagnosis)	Female	Surgery × 2, RT + surgical repair for CSF leak	Vemurafenib 960 mg bid; total: 10 m, 3-m interruption after 3 m	Initial—PR (MRI—near total); after interruption, PR with tumor regrowth after 7 m	CSF leak with meningitis from tumor reduction Low-grade fever
Brastianos et al [6]	39	Male	Surgery × 5 + surgery and RT at day 38	Dabrafenib 150 mg bid; trametinib 2 mg bid after 21 days; total: 1.7 m	PR (MRI—85% and 81% reduction in solid and cystic component at 35 days stable disease after 18 m.	
Roque et al [7]	47	Female	Surgery, ommaya for cyst aspiration and RT	Dabrafenib 150mg bid + trametinib 2 mg bid; total: 7 m	CR (MRI—disappearance of the tumor) clinical improvement	Intermittent fever
Rostami et al [8]	65	Male	Surgery	Dabrafenib 150 mg bid; trametinib 2 mg bid after 21 days; total: 3.5 m	PR (MRI—near total 91% reduction) clinical improvement	Fever
Himes et al [9]	52 (47 at diagnosis)	Male	Surgery, RT	Dabrafenib 150 mg bid; dose reduction after several weeks; total: 12 m	PR (decrease in tumor size at 6 m); stable disease 1 year off therapy	Arthralgia
Juratli et al [10]	21	Male	Surgery (biopsy)	Dabrafenib 150 mg bid; trametinib 2 mg daily; total: 6 m (ongoing)	PR (MRI > 80% response at 6 m)	
Berstein et al [11]	60	Male	Surgery × 4, RT	Dabrafenib 150 mg bid; trametinib 2 mg daily after 14 days; total: 28 m (ongoing)	CR (100% tumor reduction at 2 m); best clinical response after 3 m	Verrucal keratosis
Rao et al [12]	35	Male	Shunt for hydrocephalus Craniotomy	Dabrafenib 150 mg bid; total: over 24 m	PR (MRI at 2 m); CR of solid component at 24 m	None
Chik et al	37 (10 at diagnosis)	Male	4 prior surgeries + 2 surgeries followed by RT and gamma knife	Vemurafenib 960 mg bid; intermittent dose reduction after 3.7 m, 1.5 m interruption after 14.7 m; total: 4 0m (ongoing)	PR (MRI, 55% tumor reduction at 15 m); after interruption, similar reduction after 0.5 m	Arthralgia, myalgia, elevated liver enzymes, severe sun sensitivity

Abbreviations: CR, complete response; CSF, cerebrospinal fluid; m, months; PR, partial response; RT, radiotherapy.

even when the dose of vemurafenib had to be reduced or interrupted because of elevated liver enzymes. Possible reasons for the sustained response would reflect a reduction in the Ki-67 from the use of vemurafenib and the beneficial effect of radiation therapy.

The finding of nuclear localization of β -catenin in our patient with PCP is of interest, and this occurs in the absence of mutation in exon3 of *CTNNB1*, which encodes for β -catenin. Whereas aberrant/nuclear localization of β -catenin is present in 79% of patients with ACPs regardless of the mutation status of *CTNNB1* and can predict disease recurrence, this only occurs in <2% of patients with PCPs [20, 22]. In our patient, around 5% of tumor cells demonstrated nuclear localization of β -catenin prior to treatment with vemurafenib, with a lower percentage of positive tumor cells after treatment. As only exon 3 of *CTNNB1* was examined in our patient, we cannot exclude a *CTNNB1* mutation in another exon; alternatively, there might be another trigger of this aberrant activation of the Wnt/ β -catenin signaling. Although most studies indicate that *CTNNB1* and *BRAF* mutations are mutually exclusive and represent the main drivers of the 2 distinct subtypes of CPs [23–26], co-existing mutations of *BRAF-V600E* and *CTNNB1* were noted in 2 of 13 patients with ACPs in 1 study [27]. Moreover, CPs with mixed histological features of ACP and PCP account for 5% to 11% in older series [28–30] even though CPs with mixed histology are not included in the 2016 World Health Organization classification of tumors of the central nervous system [31]. Unfortunately, his childhood pathology samples were no longer available for further study to address whether his original tumor had features of ACP.

In summary, our case adds to the existing literature on the beneficial effect of a BRAF inhibitor in the management of patients with PCPs. The precise role of a BRAF inhibitor with or without an MEK inhibitor in the management of PCPs, in the neoadjuvant setting, after partial or total surgical resection, alone or in combination with radiation surgery, and the optimal duration of treatment will await the results from the ongoing clinical trials.

Acknowledgments

The authors would like to acknowledge the excellent care provided by Dr Tammy McNab.

Additional Information

Correspondence: Constance L. Chik, MD, PhD, Division of Endocrinology and Metabolism, 9-111D Clinical Sciences Building, Uni-

versity of Alberta, Edmonton, AB T6G 2G3, Canada. E-mail: cchik@ualberta.ca.

Disclosures: The authors have no relevant financial interests or conflict of interests to disclose.

Data Availability: Data sharing is not applicable to this article, as no datasets were generated or analyzed.

References and Notes

- Müller HL, Merchant TE, Warmuth-Metz M, Martinez-Barbera JP, Puget S. Craniopharyngioma. *Nat Rev Dis Primers*. 2019;5(1):1-19.
- Brastianos PK, Taylor-Weiner A, Manley PE, et al. Exome sequencing identifies BRAF mutations in papillary craniopharyngiomas. *Nat Genet*. 2014;46(2):161-165.
- Sekine S, Shibata T, Kokubu A, et al. Craniopharyngiomas of adamantinomatous type harbor beta-catenin gene mutations. *Am J Pathol*. 2002;161(6):1997-2001.
- Hölsken A, Sill M, Merkle J, et al. Adamantinomatous and papillary craniopharyngiomas are characterized by distinct epigenomic as well as mutational and transcriptomic profiles. *Acta Neuropathol Commun*. 2016;4:1-13.
- Aylwin SJ, Bodi I, Beaney R. Pronounced response of papillary craniopharyngioma to treatment with vemurafenib, a BRAF inhibitor. *Pituitary*. 2016;19(5):544-546.
- Brastianos PK, Shankar GM, Gill CM, et al. Dramatic response of BRAF V600E mutant papillary craniopharyngioma to targeted therapy. *J Natl Cancer Inst*. 2015;108(2):djv310.
- Roque A, Odia Y. BRAF-V600E mutant papillary craniopharyngioma dramatically responds to combination BRAF and MEK inhibitors. *CNS Oncol*. 2017;6(2):95-99.
- Rostami E, Witt Nyström P, Libard S, Wikström J, Casar-Borota O, Gudjonsson O. Recurrent papillary craniopharyngioma with BRAFV600E mutation treated with neoadjuvant-targeted therapy. *Acta Neurochir (Wien)*. 2017;159(11):2217-2221.
- Himes BT, Ruff MW, Van Gompel JJ, et al. Recurrent papillary craniopharyngioma with BRAF V600E mutation treated with dabrafenib: case report. *J Neurosurg*. 2018:1-5.
- Juratli TA, Jones PS, Wang N, et al. Targeted treatment of papillary craniopharyngiomas harboring BRAF V600E mutations. *Cancer*. 2019;125(17):2910-2914.
- Bernstein A, Mrowczynski OD, Greene A, et al. Dual BRAF/MEK therapy in BRAF V600E-mutated primary brain tumors: a case series showing dramatic clinical and radiographic responses and a reduction in cutaneous toxicity. *J Neurosurg*. 2020;133(6):1704-1709.
- Rao M, Bhattacharjee M, Shepard S, Hsu S. Newly diagnosed papillary craniopharyngioma with BRAF V600E mutation treated with single-agent selective BRAF inhibitor dabrafenib: a case report. *Oncotarget*. 2019;10(57):6038-6042.
- Dankner M, Rose AAN, Rajkumar S, Siegel PM, Watson IR. Classifying BRAF alterations in cancer: new rational therapeutic strategies for actionable mutations. *Oncogene*. 2018;37(24):3183-3199.
- Robert C, Karaszewska B, Schachter J, et al. Improved overall survival in melanoma with combined dabrafenib and trametinib. *N Engl J Med*. 2015;372(1):30-39.

15. Welsh SJ, Corrie PG. Management of BRAF and MEK inhibitor toxicities in patients with metastatic melanoma. *Ther Adv Med Oncol*. 2015;7(2):122-136.
16. Wanchoo R, Jhaveri KD, Deray G, Launay-Vacher V. Renal effects of BRAF inhibitors: a systematic review by the Cancer and the Kidney International Network. *Clin Kidney J*. 2016;9(2):245-251.
17. La Corte E, Younus I, Pivari F, et al. BRAF V600E mutant papillary craniopharyngiomas: a single-institutional case series. *Pituitary*. 2018;21(6):571-583.
18. Fujio S, Juratli TA, Arita K, et al. A clinical rule for preoperative prediction of BRAF mutation status in craniopharyngiomas. *Neurosurgery*. 2019;85(2):204-210.
19. Yue Q, Yu Y, Shi Z, et al. Prediction of BRAF mutation status of craniopharyngioma using magnetic resonance imaging features. *J Neurosurg*. 2018;129(1):27-34.
20. Prieto R, Pascual JM. Can tissue biomarkers reliably predict the biological behavior of craniopharyngiomas? A comprehensive overview. *Pituitary*. 2018;21(4):431-442.
21. Coury JR, Davis BN, Koumas CP, Manzano GS, Dehdashti AR. Histopathological and molecular predictors of growth patterns and recurrence in craniopharyngiomas: a systematic review. *Neurosurg Rev*. 2020;43(1):41-48.
22. Li Z, Xu J, Huang S, You C. Aberrant membranous expression of β -catenin predicts poor prognosis in patients with craniopharyngioma. *Ann Diagn Pathol*. 2015;19(6):403-408.
23. Guadagno E, de Divitiis O, Solari D, et al. Can recurrences be predicted in craniopharyngiomas? β -catenin coexisting with stem cells markers and p-ATM in a clinicopathologic study of 45 cases. *J Exp Clin Cancer Res*. 2017;36(1):1-11.
24. Goschzik T, Gessi M, Dreschmann V, et al. Genomic alterations of adamantinomatous and papillary craniopharyngioma. *J Neuropathol Exp Neurol*. 2017;76(2):126-134.
25. Malgulwar PB, Nambirajan A, Pathak P, et al. Study of β -catenin and BRAF alterations in adamantinomatous and papillary craniopharyngiomas: mutation analysis with immunohistochemical correlation in 54 cases. *J Neurooncol*. 2017;133(3):487-495.
26. Yoshimoto K, Hatae R, Suzuki SO, et al. High-resolution melting and immunohistochemical analysis efficiently detects mutually exclusive genetic alterations of adamantinomatous and papillary craniopharyngiomas. *Neuropathology*. 2018;38(1):3-10.
27. Larkin SJ, Preda V, Karavitaki N, Grossman A, Ansoorge O. BRAF V600E mutations are characteristic for papillary craniopharyngioma and may coexist with CTNNB1-mutated adamantinomatous craniopharyngioma. *Acta Neuropathol*. 2014;127(6):927-929.
28. Szeifert GT, Sipos L, Horváth M, et al. Pathological characteristics of surgically removed craniopharyngiomas: analysis of 131 cases. *Acta Neurochir (Wien)*. 1993;124(2-4):139-143.
29. Weiner HL, Wisoff JH, Rosenberg ME, et al. Craniopharyngiomas: a clinicopathological analysis of factors predictive of recurrence and functional outcome. *Neurosurgery*. 1994;35(6):1001-1010; discussion 1010.
30. Crotty TB, Scheithauer BW, Young WF Jr, et al. Papillary craniopharyngioma: a clinicopathological study of 48 cases. *J Neurosurg*. 1995;83(2):206-214.
31. Buslei R, Rushing EJ, Giangaspero F, Paulus W, Buser PC, Santaga S. Craniopharyngiomas. In: Louis DN, Ohgaki H, Wiestler OD, Cavenee WK, eds. *WHO Classification of Tumors of the Central Nervous System*. 4th ed. Lyon: IARC Press; 2016:324-329.