

Case Report



Disappearance of a Distal Shunt Catheter: A Case Report of an Unusual Cause of Shunt Malfunction

Doyub Kim ¹, Hae Yu Kim ¹, Sung-Chul Jin ¹, and Sungjoon Lee ^{1,2}

¹Department of Neurosurgery, Inje University Haeundae Paik Hospital, Busan, Korea

²Department of Neurosurgery, Samsung Medical Center, Sungkyunkwan University School of Medicine, Seoul, Korea



Received: Jan 17, 2020

Revised: Mar 6, 2020

Accepted: Mar 6, 2020

Address for correspondence:

Sungjoon Lee

Department of Neurosurgery, Samsung Medical Center, Sungkyunkwan University School of Medicine, 81 Irwon-ro, Gangnam-gu, Seoul 06351, Korea.

E-mail: potata98@naver.com

Copyright © 2020 Korean Neurotraumatology Society

This is an Open Access article distributed under the terms of the Creative Commons Attribution Non-Commercial License (<https://creativecommons.org/licenses/by-nc/4.0/>) which permits unrestricted non-commercial use, distribution, and reproduction in any medium, provided the original work is properly cited.

ORCID iDs

Doyub Kim

<https://orcid.org/0000-0002-4623-9303>

Hae Yu Kim

<https://orcid.org/0000-0002-6588-050X>

Sung-Chul Jin

<https://orcid.org/0000-0001-5282-9329>

Sungjoon Lee

<https://orcid.org/0000-0002-1675-0506>

Conflict of Interest

The authors have no financial conflicts of interest.

ABSTRACT

Shunt malfunction is a common complication in patients who undergo ventriculoperitoneal shunt (VPS) placement for the treatment of hydrocephalus. A plethora of reports regarding shunt malfunctions due to distal catheter migration have been demonstrated in the literature. However, to our knowledge, there have been no reports thus far of shunt malfunctions caused by the complete disappearance of a distal catheter. A 70-year-old man was admitted to our hospital for progressive gait disturbance beginning approximately 5 months ago. He received a VPS for posthemorrhagic hydrocephalus and was doing well over the course of 18 months of follow-up. Since no increase in the size of the ventricle was observed on brain computed tomography taken at the outpatient clinic, we tried to readjust the pressure setting of his programmable shunt valve to relieve his symptoms. Without any progression, we discovered later by chance that the distal shunt catheter was missing. Shunt revision surgery was performed. At the 2-year follow-up, a slight improvement in gait was observed. Although it is very rare, the distal catheter can disappear without any noticeable symptoms. If shunt malfunction is suspected, it is important to check whether the entire shunt system is structurally intact.

Keywords: Hydrocephalus; Complications; Ventriculoperitoneal shunt; Shunt malfunction; Distal catheter migration

INTRODUCTION

Hydrocephalus is a pathologic condition characterized by active distension of the ventricular system in the brain as a result of inadequate passage of cerebrospinal fluid (CSF) from its point of production within the cerebral ventricles to its point of absorption into the systemic circulation.¹⁴ Hydrocephalus is a common complication following various intracranial pathologies.⁴ The placement of a ventriculoperitoneal shunt (VPS) is widely adopted surgical procedure for the treatment of this condition.¹¹ Due to the popularity of this procedure, there have been marked technical advancements in the manufacturing of shunt devices. However, the VPS is associated with multiple complications.^{2,3,11} Distal catheter migration is a complicated form of mechanical shunt failure.³ Recently, we experienced a patient with shunt malfunction secondary to distal catheter disappearance. By reviewing the course of treatment

of this patient in detail, we will discuss the cause of our initial failure in making diagnosis of shunt malfunction. In addition, we will attempt to infer how the distal catheter disappeared with the help of a relevant literature review. To our knowledge, this is the first report of this very unusual form of distal catheter migration in the literature.

CASE REPORT

A 70-year-old man was admitted to our clinic for progressive gait disturbance. He had undergone aortic valve replacement surgery 11 years ago, and had been taking warfarin ever since. Three years ago, he underwent a retromastoid suboccipital craniotomy to remove a right vestibular schwannoma. Unfortunately, an intracerebellar hemorrhage developed 2 months after the surgery, and posthemorrhagic hydrocephalus developed as a consequence. A VPS (Codmann Hakim Programmable Valve; Johnson & Johnson Co., Boston, MA, USA) was placed. All connection sites between the catheters and the reservoir was reinforced with a tie using 3-0 black silk. After the operation, he had been doing well for 18 months.

He complained of a recent tendency to trip that began 5 months before admission. At the outpatient clinic, we performed brain computed tomography (CT) first to look for any signs of shunt malfunction. Since CT showed no change in ventricle size, we decided to lower the shunt pressure setting and to observe any symptom improvement in the patients. However, the patient did not get better despite repeated subsequent adjustments of shunt pressure. While attempting to examine the cause of his gait disturbance, we became aware of the fact, by chance, that the distal catheter was not visible on an outside chest X-ray film (**FIGURE 1**).

At the time of admission, the patient's vital signs were stable, and his body temperature was 36.3°C. He had not suffered any abdominal symptoms, and physical examination showed no tenderness or rebound tenderness in the abdomen. Upon neurological examination, his mental status was indicative of slight drowsiness, and his orientation was intact. Mild cognitive dysfunction was observed. However, there was little difficulty with communication.

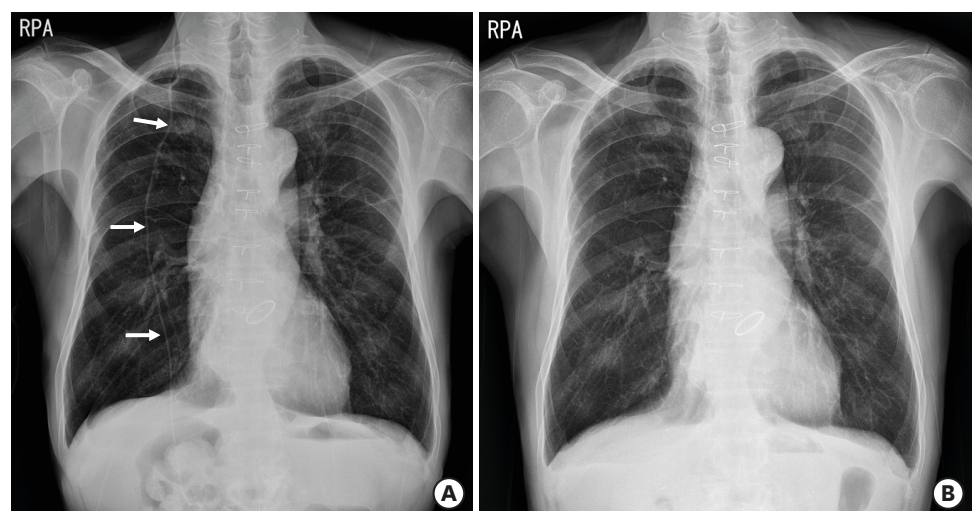


FIGURE 1. (A) Last chest plain radiograph taken 5 months before symptom presentation of the patient. At that time, the distal shunt catheter was clearly seen (white arrows). (B) A chest plain radiograph was taken immediately after noticing that the distal catheter was missing from the outside film completely by chance. The distal catheter that was seen in the previous plain radiograph was gone.

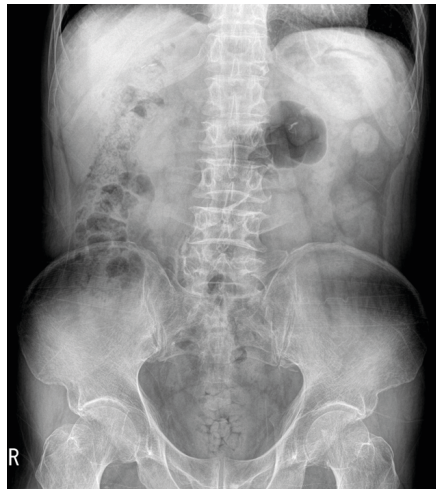


FIGURE 2. Simple abdomen plain radiograph taken after admission. The disconnected distal catheter could not be found anywhere in the abdominal cavity.

The motor power of both the upper and lower limbs was assessed as grade 4/5, and he could walk a short distance with assistance. According to the laboratory tests, the whole white blood cell count was 6.13×10^9 count/L (reference range, 4.0 to 10.0), and the CRP level was 0.2 mg/dL (reference range, <0.3). A set of plain X-rays revealed that the distal catheter was missing (**FIGURE 2**). Additional abdominal CT was performed to locate the retained distal catheter in the abdominal cavity, but it failed to be found. No intraabdominal organ abnormalities associated with shunt catheter migration were observed.

Under the diagnosis of shunt malfunction secondary to disconnection and disappearance of the distal catheter, shunt revision surgery was performed. As we exposed the shunt valve, the proximal shunt system seemed to be working well. No CSF collection was observed at the disconnected site juxta of the shunt valve reservoir. A subcutaneous tract where the missed distal catheter previously located was observed, and it seemed that CSF coming from the valve was continuously drained through this tract. A new distal catheter was connected to the shunt valve, and its distal tip was inserted into the peritoneal cavity through a new subcutaneous tunnel. We did not explore the abdominal cavity to look for the hidden distal catheter.

The postoperative course was uneventful, and the patient was discharged 8 days after the surgery. During the 2-year follow-up, the patient was in good condition, and no complications related to the operation were observed. His gait had improved, and he could walk without assistance, although some difficulty remained.

DISCUSSION

The most interesting point of this case is the whereabouts of the missing distal catheter. Since we could not locate the catheter in the patient's body, it was clear that the distal catheter had escaped from the body. We do not have any hard evidence. However, we can infer how this incident occurred by reconstructing a plausible scenario with reported possible incidents in the literature.

Surprisingly, distal catheter scan migrate into various regions of the body.²⁾ Migrations into the bowel, bladder, heart, umbilicus, vagina, scrotum, pleural cavity, pulmonary

artery, oral and anal protrusions, and even the peri-implant space of the breast have been reported.^{1,2,6-10,12,13,15,16,18)} Our patient had not experienced any symptoms or signs related to distal catheter migration. If so, the most reasonable escape route would be the anus. Other body openings, such as the mouth or the urethra, could not be passed without notice. Additionally, any anatomical breakage of other body parts or walls without any symptoms is highly unlikely. Perforation of the bowel by the distal catheter is potentially a lethal condition either by ascending intracranial infections or by peritonitis resulting in sepsis.^{2,15)} In contrast, there are few reports that have shown spontaneous healing of the perforated bowel without any signs of infection in the abdominal cavity.¹⁶⁾ We think a similar incident occurred in our patient. The distal catheter first perforated the bowel. Its peristaltic movements pulled the catheter inside the bowel, and the catheter was excreted with feces. Then, the perforation site healed spontaneously without any symptoms or signs. Despite the lack of solid evidence, we think this is the most plausible scenario explaining this mysterious incident.

In numerous instances, technical advancements often change physicians' features of clinical practices. The use of programmable shunt valves is now popular in VPS surgeries ever since the introduction of the VPS in the late 1980s to early 1990s.⁵⁾ In the era of nonadjustable shunt devices, checking the mechanical integrity by taking a series of plain radiographs along the shunt system was a routine diagnostic examination if a shunt malfunction was suspected. Even a trivial functional problem, such as under- or overdrainage, requires revision surgery. Therefore, it was important that all the possible causes for shunt malfunction were considered before deciding on another invasive surgery. However, the programmable valve enabled us to adjust its pressure noninvasively, and it had brought about a trend of adjusting the pressure setting and waiting first rather than going over all the necessary examinations at once when a functional failure of the shunt was suspected.

By retrospectively reviewing the brain CT scout image taken when the patient initially complained of symptoms at the outpatient clinic, the distal catheter was found to be missing (**FIGURE 3A**). A few fluoroscopic skull X-rays had been taken to confirm the shunt valve

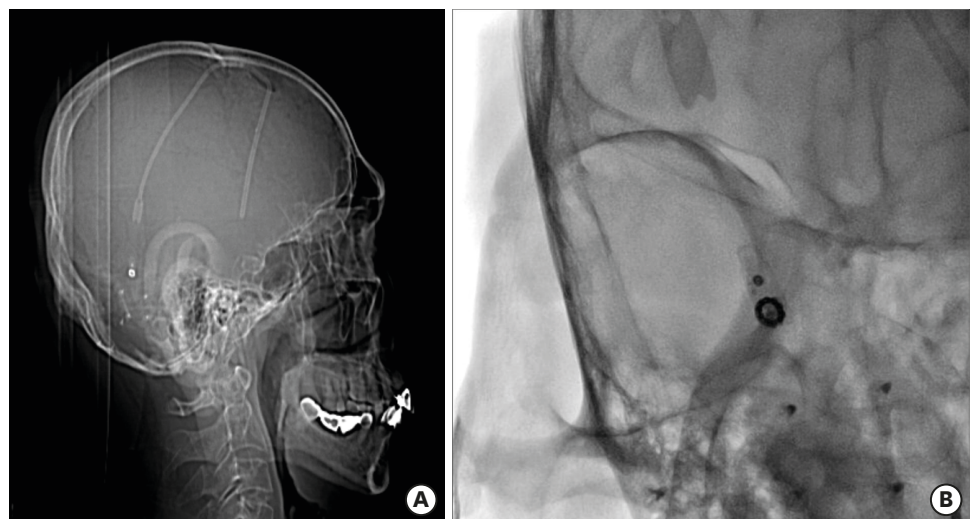


FIGURE 3. (A) Brain computed tomography scout film taken when the patient initially complained of progressive gait disturbance at the outpatient clinic. By retrospectively reviewing this image, we became aware that the distal catheter was missing and that it was already gone 5 months before admission. (B) One of the skull plain radiographs taken in between a period of 5 months from the initial symptom presentation to admission. It was a magnified image to confirm the shunt pressure setting which made it difficult to notice the absence of the distal catheter.

setting. We magnified the field of view to read the gauze precisely, and it limited the field of view, making it difficult to discover the disintegrity of the shunt system (**FIGURE 3B**). This is an inborn human error called ‘inattentive blindness’, which Simons and Charbris described through their innovative psychiatric study using gorillas.¹⁷⁾ We missed the proper diagnosis initially because we did not doubt. Unless an urgent situation is evident, such as rapidly deteriorating acute hydrocephalus, approaching the patient step by step and moving from simple to complicated work-up procedures might be reasonable. However, a delay in the proper diagnosis cannot be justified and must be kept as short as possible. Mechanical failure is one of the leading causes of the shunt malfunction.¹⁾ Our case reminded us that a disruption of mechanical integrity of the shunt system is still an important cause of shunt malfunction, which should be kept in mind as a possibility.

CONCLUSION

Although it is a rare incident, shunt malfunction due to distal catheter migration can occur, and neurosurgeons should always keep in mind this possibility. If shunt malfunction is suspected, it is always important to check that the entire shunt system is structurally intact. Careful inspection of the catheter-connecting sites should be the first step.

REFERENCES

1. Agarwal R, Allen A, Green L. Ventriculoperitoneal shunt catheter migration in a patient with breast implants resulting in a peri-implant cerebrospinal fluid pseudocyst. *Radiol Case Rep* 14:221-225, 2019
[PUBMED](#) | [CROSSREF](#)
2. Allouh MZ, Al Barbarawi MM, Asfour HA, Said RS. Migration of the distal catheter of the ventriculoperitoneal shunt in hydrocephalus: a comprehensive analytical review from an anatomical perspective. *Clin Anat* 30:821-830, 2017
[PUBMED](#) | [CROSSREF](#)
3. Bates P, Rajderkar D. Common and uncommon causes of ventriculoperitoneal shunt malfunction diagnosed on plain radiographs. *Curr Probl Diagn Radiol* 47:317-323, 2018
[PUBMED](#) | [CROSSREF](#)
4. Bergsneider M, Miller C, Vespa PM, Hu X. Surgical management of adult hydrocephalus. *Neurosurgery* 62 Suppl 2:643-659, 2008
[PUBMED](#) | [CROSSREF](#)
5. Black PM, Hakim R, Bailey NO. The use of the Codman-Medos Programmable Hakim valve in the management of patients with hydrocephalus: illustrative cases. *Neurosurgery* 34:1110-1113, 1994
[PUBMED](#) | [CROSSREF](#)
6. Glatstein MM, Roth J, Scolnik D, Haham A, Rimon A, Koren L, et al. Late presentation of massive pleural effusion from intrathoracic migration of a ventriculoperitoneal shunt catheter: case report and review of the literature. *Pediatr Emerg Care* 28:180-182, 2012
[PUBMED](#) | [CROSSREF](#)
7. Hermann EJ, Zimmermann M, Marquardt G. Ventriculoperitoneal shunt migration into the pulmonary artery. *Acta Neurochir (Wien)* 151:647-652, 2009
[PUBMED](#) | [CROSSREF](#)
8. Houten JK, Smith S, Schwartz AY. Vaginal migration of ventriculoperitoneal shunt catheter and cerebrospinal fluid leak as a complication of hysterectomy. *World Neurosurg* 104:1046.e13-1046.e14, 2017
[PUBMED](#) | [CROSSREF](#)
9. Low SW, Sein L, Yeo TT, Chou N. Migration of the abdominal catheter of a ventriculoperitoneal shunt into the mouth: a rare presentation. *Malays J Med Sci* 17:64-67, 2010.
[PUBMED](#)
10. Mohammadi A, Hedayatiasl A, Ghasemi-Rad M. Scrotal migration of a ventriculoperitoneal shunt: a case report and review of literature. *Med Ultrason* 14:158-160, 2012.
[PUBMED](#)

11. Patwardhan RV, Nanda A. Implanted ventricular shunts in the United States: the billion-dollar-a-year cost of hydrocephalus treatment. *Neurosurgery* 56:139-145, 2005
[PUBMED](#) | [CROSSREF](#)
12. Pohlman GD, Wilcox DT, Hankinson TC. Erosive bladder perforation as a complication of ventriculoperitoneal shunt with extrusion from the urethral meatus: case report and literature review. *Pediatr Neurosurg* 47:223-226, 2011
[PUBMED](#) | [CROSSREF](#)
13. Ralston A, Johnson A, Ziemer G, Frim DM. Transcardiac migration of ventriculoperitoneal shunt requiring open cardiac surgery: case report and review of the literature. *Childs Nerv Syst* 33:703-707, 2017
[PUBMED](#) | [CROSSREF](#)
14. Rekaté HL. A contemporary definition and classification of hydrocephalus. *Semin Pediatr Neurol* 16:9-15, 2009
[PUBMED](#) | [CROSSREF](#)
15. Riccardello GJ Jr, Barr LK, Bassani L. Bowel perforation presenting with acute abdominal pain and subcutaneous emphysema in a 14-year-old girl with an abandoned distal peritoneal shunt catheter: case report. *J Neurosurg Pediatr* 18:325-328, 2016
[PUBMED](#) | [CROSSREF](#)
16. Sharifian A, Abdollahi A, Maddah G, Anaraki F, Alvandipour M, Abbasi Sahebi M, et al. Spontaneous transanal protrusion of ventriculoperitoneal catheter: a case report. *Acta Med Iran* 51:135-138, 2013.
[PUBMED](#)
17. Simons DJ, Chabris CF. Gorillas in our midst: sustained inattention blindness for dynamic events. *Perception* 28:1059-1074, 1999
[PUBMED](#) | [CROSSREF](#)
18. Wani AA, Ramzan A, Wani MA. Protrusion of a peritoneal catheter through the umbilicus: an unusual complication of a ventriculoperitoneal shunt. *Pediatr Surg Int* 18:171-172, 2002
[PUBMED](#) | [CROSSREF](#)