

Prenatal diagnosis of de novo monosomy 18p deletion syndrome by chromosome microarray analysis

Three case reports

Hong Qi, MD*, Jianjiang Zhu, MM, Shaoqin Zhang, MM, Lirong Cai, BS, Xiaohui Wen, MM, Wen Zeng, BS, Guodong Tang, BS, Yao Luo, MM

Abstract

Rationale: Monosomy 18p deletion syndrome refers to a rare chromosomal disorder resulting from the part deletion of the short arm of chromosome 18. Prenatal diagnosis of de novo 18p deletion syndrome is a challenge due to its low incidence and untypical prenatal clinical presentation.

Patient concerns: Three cases received amniocentesis due to increased nuchal translucency (INT), high risk for Down syndrome, and INT combined intrauterine growth retardation (IUGR), respectively.

Diagnosis: The 3 cases were diagnosed with de novo monosomy 18p deletion syndrome by amniocentesis and chromosome microarray analysis (CMA).

Interventions: Karyotype analysis and CMA were used to analyze the abnormal chromosome.

Outcomes: Case 1 and case 2 revealed 13.87 and 12.68 Mb deletions by array-CGH analysis, respectively. Case 3 revealed 6.9 Mb deletions in 18p11.32p11.31 and 7.5 Mb deletions in 18p11.23p11.21 by SNP array. All of the pregnancies were terminated due to the abnormal chromosome.

Lessons: The fetal phenotype of monosomy 18p deletion syndrome shows great variability and may not be evident during the pregnancy. CMA may be served as an effective tool for the diagnosis of prenatal monosomy 18p deletion syndrome diagnosis.

Abbreviations: AFI = amniotic fluid index, CMA = chromosome microarray analysis, CRL = crown-rump length, INT = increased nuchal translucency, IUGR = intrauterine growth retardation, MSS = maternal serum screening, NF = nuchal fold, NIPT = noninvasive prenatal testing.

Keywords: chromosome microarray analysis, intrauterine growth retardation, monosomy 18p, nuchal translucency, prenatal diagnosis

1. Introduction

Monosomy 18p deletion syndrome refers to a rare chromosomal disorder resulting from the part deletion of the short arm of chromosome 18. The incidence of the disorder could be estimated to be about 1:50,000 live-born infants worldwide.^[1] The most common clinical features of 18p deletion syndrome include

cognitive disorders, growth retardation and mild facial deformity (e.g., low nasal bridge, protruding ears).^[2] Most of the cases have a *de novo* pure terminal deletion.^[3] Majority cases were accidentally diagnosed while undergoing clinical evaluation for abnormal clinical manifestations, such as short stature, mental retardation.^[1,4] The survival outcome of this syndrome varies widely from months to decades depending on the severity.^[5] Moreover, 18p deletion may influence the intelligence development.^[2,3] It has been revealed family members affected by an identical 18p deletion have significantly variable intelligence levels.^[1] However, currently, there is no specific treatment for 18p deletion, except speech therapy and early educational programs may help to improve the performances of the children.^[3] Therefore, the prenatal diagnosis of monosomy 18p syndrome is important for early prevention and management.

Despite technical development in prenatal detection and evaluation over decades, prenatal diagnosis of monosomy 18p syndrome still presents as a challenge in clinical practice may due to its varied and untypical clinical presentation. In clinical practical the prenatal diagnosis of this chromosome imbalance usually represents an unexpected finding at villocentesis or amniocentesis.^[6] Conventional karyotype analysis could not be used to diagnose 18p deletion (<10 Mb) due to inherent technological limitations. Recently, chromosome microarray

Editor: N/A.

The authors have no funding and no conflicts of interest to disclose.

Prenatal Diagnosis Center, Haidian Maternal and Child Health Hospital, Beijing, PR China.

* Correspondence: Hong Qi, Prenatal Diagnosis Center, Beijing Haidian Maternal and Child Health Hospital, No. 33 Haidian South Road, Beijing 100080, PR China (e-mail: qihong_2009@sina.com).

Copyright © 2019 the Author(s). Published by Wolters Kluwer Health, Inc. This is an open access article distributed under the terms of the Creative Commons Attribution-Non Commercial-No Derivatives License 4.0 (CCBY-NC-ND), where it is permissible to download and share the work provided it is properly cited. The work cannot be changed in any way or used commercially without permission from the journal.

Medicine (2019) 98:14(e15027)

Received: 23 October 2018 / Received in final form: 17 February 2019 /

Accepted: 6 March 2019

<http://dx.doi.org/10.1097/MD.0000000000015027>

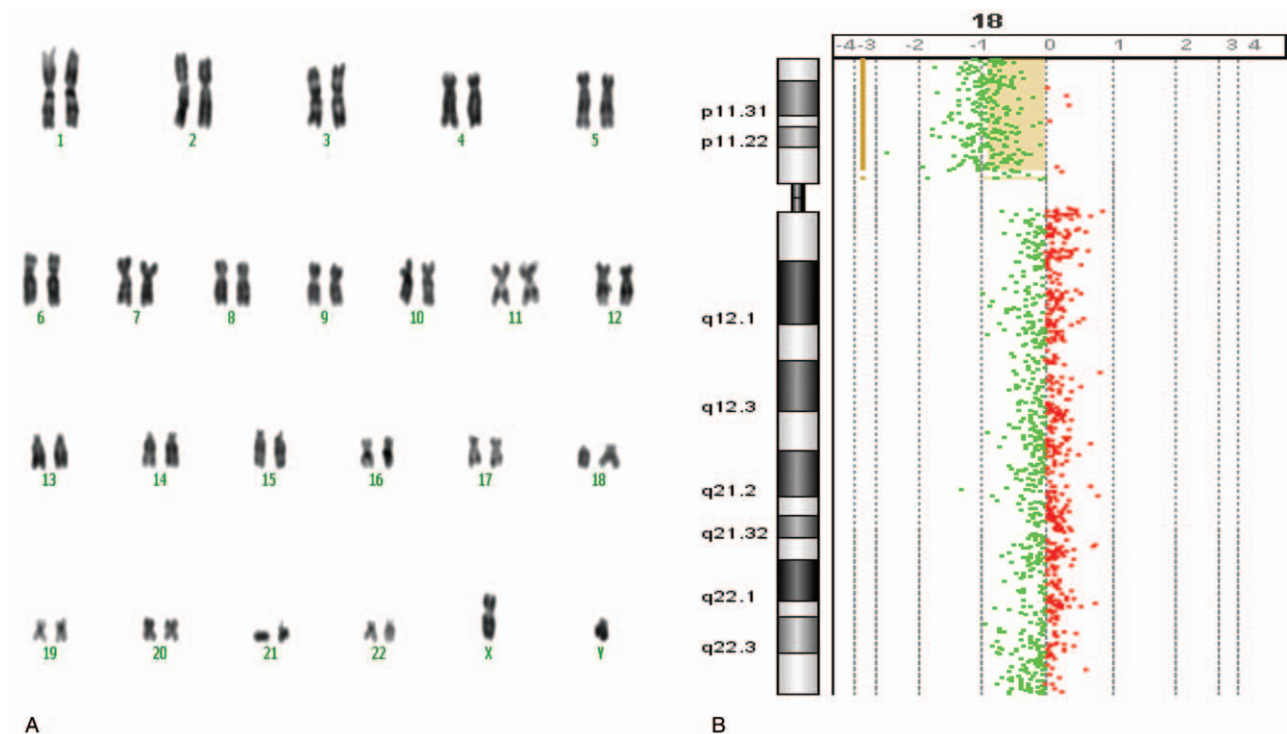


Figure 1. Prenatal diagnosis of Case 1 with monosomy 18p deletion syndrome. (A) The results of karyotype analysis [46, XY, del (18) (cen→qter)]. (B) The results of array-CGH. The 18p11.32–p11.21 deletion is 13.87 Mb in size (14316–13885255).

analysis (CMA) can identify chromosomal microdeletion/microduplication that undetected by conventional karyotyping analysis, which has been confirmed as a reasonable and effective alternative tool for prenatal diagnosis and genetic counseling.^[7,8] Here we present prenatal diagnosis of 3 cases with *de novo* monosomy 18p deletion syndrome by using amniocentesis and CMA.

2. Case report

This study was approved by the Institutional Review Board of Haidian Maternal and Child Health Hospital (Ethical approval number: 2018-27) and followed the tenets of the Declaration of Helsinki. Informed written consent was obtained from the patient for publication of this case report and accompanying images.

2.1. Case 1

A 32-year-old G4P0 woman (husband 38 years old) underwent amniocentesis at 20 weeks' gestation, in setting of increased nuchal translucency (INT) (5.1 mm) and a 5.4 cm crown-rump length (CRL) at 12 weeks' gestation. This couple had a history of 2 previous spontaneous abortions. Chromosome karyotype revealed that the fetus had an abnormal karyotype of 46, XY, del (18) (cen→qter) (Fig. 1A) whereas those of the parents were normal. INT was still detected at 23 weeks and 33 weeks. The fetal ultrasound at 23 weeks of gestation showed 11 mm nuchal fold (NF) and intrauterine growth retardation (IUGR). There was no abnormal finding in ultrasonic cardiogram examination. Amniotic fluid index (AFI) was 3.8 at 34 weeks. The fetus showed passive flexion package status, without fetal movement and IUGR was confirmed by ultrasonography. The parents decided to

terminate this pregnancy at 34 weeks of gestation based on abnormal karyotype, oligohydramnios and IUGR. Ultrasound examination before terminating pregnancy showed an AFI of 4.5 and a 10.9 mm NF. After terminating pregnancy, skeletal muscle samples of dead fetus were immediately obtained to isolate DNA. Then, array-CGH analysis of DNA samples by using 8 × 60K commercial arrays (Agilent Technologies, Santa Clara, CA) revealed 13.87 Mb deletions from 18p11.21 to pter (Fig. 1B).

Fetal autopsy showed a male fetal with a 1540 g weight and a 43 cm length, presenting as IUGR, mild ptosis, flat nasal bridge, small jaw, large and protruding ears, mild edema of the neck subcutaneous tissue, and complicated with splenomegaly, hepatocyte hydropic degeneration, right cryptorchidism, umbilical cord edema and placental villus dysplasia.

2.2. Case 2

A 32-year-old G2P0 Chinese woman with normal ultrasound findings during the whole pregnancy period was enrolled. The second trimester maternal serum screening (MSS) blood test (AFP + free βHCG + uE3, PerkinElmer) showed free βHCG 46.70 ng/mL (2.58 MOM), hAFP 24U/mL (0.91 MOM), and uE₃ 1.93 nmol/L (0.47 MOM), suggesting a high risk of Down syndrome (1:20) (trisomy 18 1:29100). Therefore, she underwent amniocentesis at 18 weeks of gestation to perform karyotype analysis, which revealed a 46, XX, 18p- (Fig. 2A). Furthermore, blood samples were obtained by using percutaneous umbilical blood sampling to further perform array-CGH analysis of the abnormal karyotype. Array-CGH revealed 12.68 Mb deletions from 18p11.32–p11.21 (Fig. 2B). The pregnancy was terminated at 32 weeks of gestation due to the chromosome abnormal. Cytogenetic examination of the parents was normal.

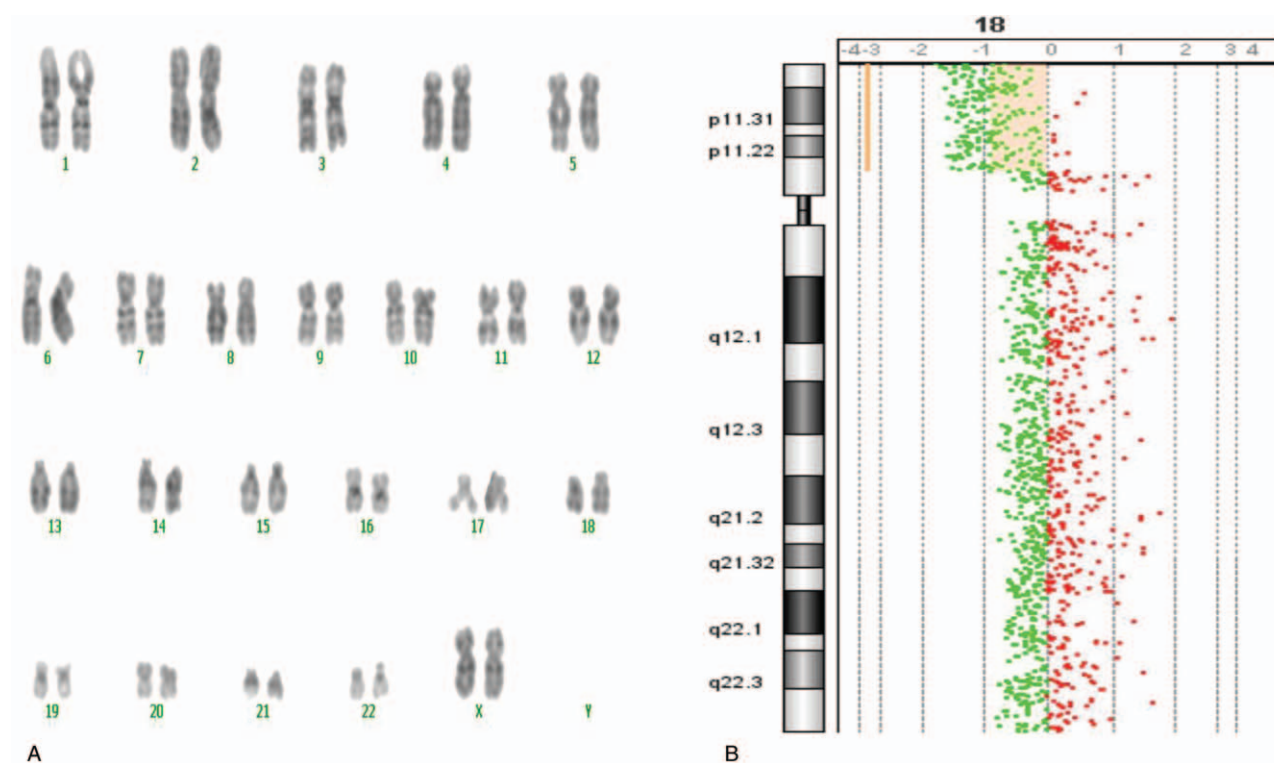


Figure 2. Prenatal diagnosis of monosomy 18p deletion syndrome in Case 2. (A) The results of karyotype analysis (46, XX, 15p+, 18p-). (B) The results of array-CGH. The 18p11.32–p11.21 deletion is 12.68 Mb in size (14316–12691471).

Autopsy showed a female dead fetus with 46 cm length and 2270 g weight. Physical characteristics were present as round face, ocular hypertelorism, flat nasal bridge, short protruding upper lip, protruding tongue, large ear, and ear edge curled. Lungs, liver, and spleen were revealed as congestion.

2.3. Case 3

A 31-year-old G1P0 Chinese woman received amniocentesis due to INT from a value of 3.3 mm for 4.8 cm of CRL at 11+4 weeks to 4.9 mm for 5.91 cm of CRL at 12+2 weeks of gestation. Noninvasive prenatal testing (NIPT) for T21, T18, and T13 showed a low risk level at 13 weeks. Amniocentesis was performed at 18 weeks of gestation. The fetus karyotype was 46, XN, del (18) (p11.2) (Fig. 3A), and further SNP array (Affymetrix 750K) revealed 6.9 Mb deletions in 18p11.32p11.31 and 7.5 Mb deletions in 18p11.23p11.21 (Fig. 3B). The fetus ultrasonography showed a characteristic of IUGR at 23 weeks. The fetal measurements corresponded to the stated gestational age.

The pregnancy was terminated at 23 weeks of gestation. The autopsy showed a dead fetus with a weight of 700 g, presenting with ocular hypertelorism, low-set ears, pinna abnormality, and depressed nasal bridge. No gross malformations were observed.

3. Discussion

About 2/3 cases of Monosomy 18p are due to spontaneous (*de novo*) deletions.^[9] It is occurred randomly for unknown reasons (sporadically). While most of cases result from terminal deletion of 18p, 16% cases with monosomy 18p deletion syndrome were reported as a result of an unbalanced whole arm translocation.^[10] Clinical features of monosomy 18p deletion

syndrome typically include mild to moderate mental retardation, an mean full scale IQ of 69 (ranged from 51 to 99), short stature, round face with short protruding philtrum, palpebral ptosis, and large ears with detached pinnae.^[11] These clinical features vary among individual cases. Moreover, it is notable that these features usually cannot be detected by prenatal ultrasound examinations in the early stages of pregnancy. Prenatal diagnosis of monosomy 18p deletion syndrome usually represents as an unexpected finding during villocentesis or amniocentesis. Thus, accurate prenatal diagnosis is important for cases with a suspected monosomy 18p deletion syndrome. However, reports of the prenatal diagnosis of monosomy 18p are rare.^[12–15]

It is reported that abnormal findings from prenatal testing or screening approaches may be useful for screening of monosomy 18p deletion syndrome. The second trimester MSS blood test is usually used to evaluate the risk level of Down syndrome by measuring 3 proteins (AFP, hCG, uE3) produced from the fetus and the placenta. In our report, the MSS of Case 2 showed a result of free β HCG (2.58 MOM), hAFP (0.91 MOM), and uE₃ (0.47 MOM), suggesting a high risk for Down syndrome. High risk of MSS may also indicate other chromosomal abnormalities

Abnormal findings in prenatal ultrasound examination may also suggest the development of monosomy 18p deletion syndrome. INT or HPE are confirmed as the common ultrasonic characteristics of monosomy 18p deletion syndrome.^[16–19] Sepulveda^[20] reported 2 cases of monosomy 18p with INT in association with brain and face anomalies on a first-trimester scan. Kim et al^[18] and Yakut et al^[16] showed that the INT at first trimester was the only prenatal finding for the fetus with del (18p) syndrome. Similarly, prenatal ultrasound also can detect heart diseases in fetus including ventricular hypertrophy, patent ductus arteriosus and tetralogy of Fallot, which occur in ~10% of the

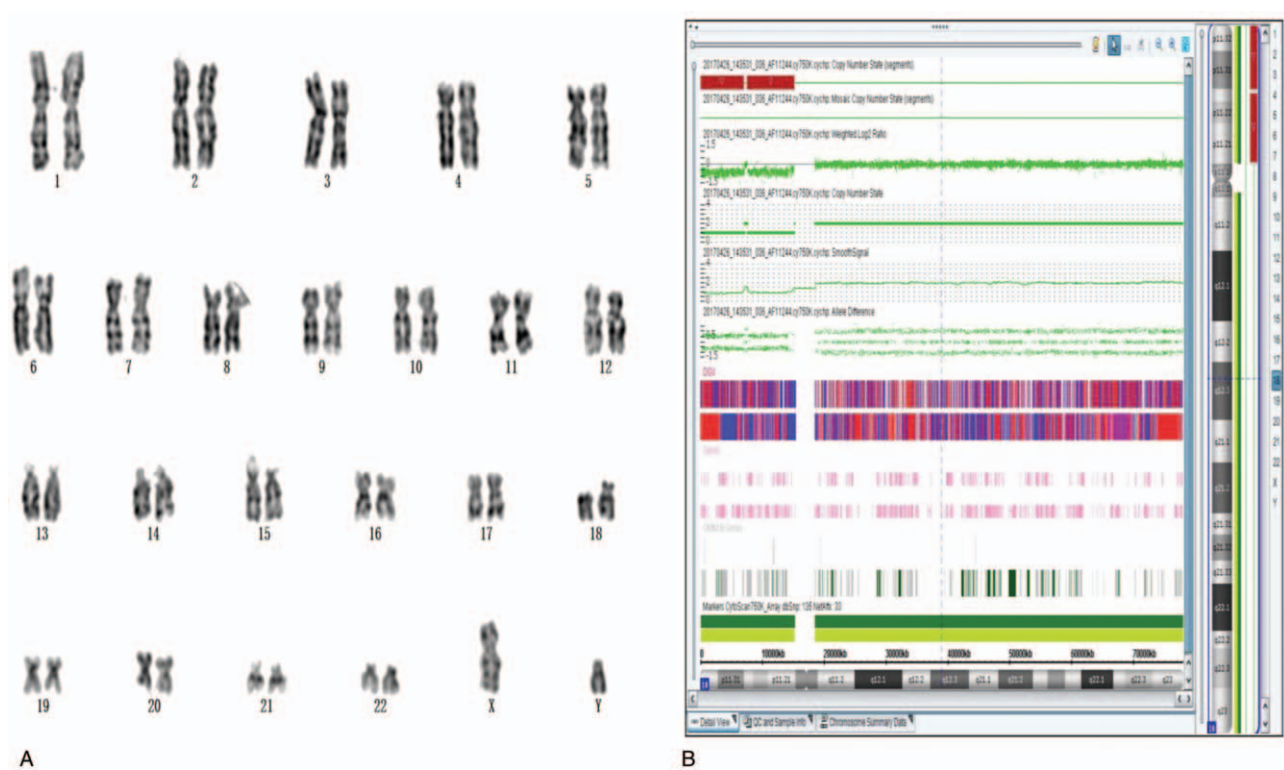


Figure 3. Prenatal diagnosis of monosomy 18p deletion syndrome in Case 3. (A) The results of karyotype analysis (46, XY, 18p-). (B) The results of array-SNP. The 18p11.32p11.31 deletion is 6.9 Mb in size (136227-7080664) and the 18p11.23p11.21 deletion is 7.5 Mb in size (7579979-15170636). SNP=single nucleotide polymorphism.

18p deletion individual.^[12,21] In this report, INT was found at 12 weeks of gestation in Case 1 and Case 3, which further assisted the diagnosis of monosomy 18p deletion syndrome. IUGR were found in the Case1 and Case3. Previous reports have confirmed the correlation between IUGR and chromosomal microdeletions.^[22,23] Several cases of tetrasomy 18p with IUGR has been reported.^[24,25] However, 18p deletion syndrome with IUGR has not yet been reported in prenatal diagnosis.

CMA is superior to standard karyotype in detection of chromosomal microdeletion/microduplication.^[8] Therefore, CMA is recommended as an additional prenatal screening item while conventional prenatal tests including blood test, ultrasonography examination and invasive prenatal diagnosis revealed abnormal findings (such as INT, HPE, and IUGR) of fetus.^[26,27] In this study, Case 1, 2 and 3 were definitely diagnosed as monosomy 18p by array-CGH, array-CGH and SNP array, respectively.

In conclusion, the fetal phenotype of monosomy 18p deletion syndrome shows great variability and may not evident during the pregnancy. Until now, there is no constant prenatal finding in this chromosomal imbalance. INT, a high risk factor of Down syndrome, and abnormal ultrasonic findings (such as IUGR) suggest monosomy 18p deletion syndrome. CMA may be served as an effective tool for the diagnosis of prenatal monosomy 18p deletion syndrome diagnosis.

Acknowledgments

The authors thank all 3 probands and their families for their cooperation. The authors thank Be creative lab (Beijing) for their expert laboratory work and analyses.

Author contributions

Clinical Consultation: Hong Qi, Shaoqin Zhang

Data Collection: Hong Qi, Lirong Cai, Xiaohui Wen, Wen Zeng, Guodong Tang, Yao Luo

Data curation: Lirong Cai, Xiaohui Wen, Wen Zeng, Guodong Tang, Yao Luo.

Follow-up: Shaoqin Zhang

Investigation: Hong Qi, Shaoqin Zhang.

Literature Search: Jianjiang Zhu

Manuscript Preparation: Jianjiang Zhu, Hong Qi

Methodology: Jianjiang Zhu, Lirong Cai, Xiaohui Wen, Wen Zeng, Guodong Tang, Yao Luo.

Resources: Hong Qi, Shaoqin Zhang, Lirong Cai, Xiaohui Wen, Wen Zeng, Guodong Tang, Yao Luo.

Writing – Original Draft: Hong Qi, Jianjiang Zhu.

Writing – Review & Editing: Hong Qi.

References

- Maranda B, Lemieux N, Lemyre E. Familial deletion 18p syndrome: case report. *BMC Med Genet* 2006;7:60.
- Hasi-Zogaj M, Sebold C, Heard P, et al. A review of 18p deletions. *Am J Med Genet C Semin Med Genet* 2015;169:251–64.
- Turleau C. Monosomy 18p. *Orphanet J Rare Dis* 2008;3:4.
- Xu LJ, Wu LX, Yuan Q, et al. A case of 18p deletion syndrome after blepharoplasty. *Int Med Case Rep J* 2017;10:15–8.
- de Ravel TJ, Thiry P, Frysns JP. Follow-up of adult males with chromosome 18p deletion. *Eur J Med Genet* 2005;48:189–93.
- Fogu G, Capobianco G, Cambosu F, et al. Prenatal diagnosis and molecular cytogenetic characterisation of a de novo 18p deletion. *J Obstet Gynaecol* 2014;34:192–3.

- [7] Shaffer LG, Dabell MP, Fisher AJ, et al. Experience with microarray-based comparative genomic hybridization for prenatal diagnosis in over 5000 pregnancies. *Prenat Diagn* 2012;32:976–85.
- [8] Wapner RJ, Martin CL, Levy B, et al. Chromosomal microarray versus karyotyping for prenatal diagnosis. *N Engl J Med* 2012;367:2175–84.
- [9] Schinzel A. *Catalogue of Unbalanced Chromosome Aberrations in Man*. 2nd Rev. and Expanded ed. Berlin; New York: Walter de Gruyter; 2001.
- [10] McGhee EM, Qu Y, Wohlferd MM, et al. Prenatal diagnosis and characterization of an unbalanced whole arm translocation resulting in monosomy for 18p. *Clin Genet* 2001;59:274–8.
- [11] Sebold C, Soileau B, Heard P, et al. Whole arm deletions of 18p: medical and developmental effects. *Am J Med Genet A* 2015;167A:313–23.
- [12] Yi Z, Yingjun X, Yongzhen C, et al. Prenatal diagnosis of pure partial monosomy 18p associated with holoprosencephaly and congenital heart defects. *Gene* 2014;533:565–9.
- [13] Portnoi MF, Gruchy N, Marlin S, et al. Midline defects in deletion 18p syndrome: clinical and molecular characterization of three patients. *Clin Dysmorphol* 2007;16:247–52.
- [14] Chen CP, Chern SR, Wang W, et al. Prenatal diagnosis of partial monosomy 18p (18p11.2->pter) and trisomy 21q (21q22.3->qter) with alobar holoprosencephaly and premaxillary agenesis. *Prenat Diagn* 2001;21:346–50.
- [15] Hu H, Hao J, Yao H, et al. Prenatal diagnosis of de novo partial trisomy 18p and partial monosomy 18q recurrent in a family with fatal aortic coarctation. *Gene* 2013;517:132–6.
- [16] Yakut S, Simsek M, Pestereli HE, et al. Del (18p) syndrome with increased nuchal translucency revealed in prenatal diagnosis. *Genet Couns* 2011;22:317–9.
- [17] Gocke H, Muradow I, Stein W. The fetal phenotype of the 18p-syndrome. Report of a male fetus at twenty-one weeks. *Ann Genet* 1988;31:60–4.
- [18] Kim YM, Cho EH, Kim JM, et al. Del (18p) syndrome with increased nuchal translucency in prenatal diagnosis. *Prenat Diagn* 2004;24:161–4.
- [19] Yin Z, Zhang K, Ni B, et al. Prenatal diagnosis of monosomy 18p associated with holoprosencephaly: case report. *J Obstet Gynaecol* 2017;37:804–6.
- [20] Sepulveda W. Monosomy 18p presenting with holoprosencephaly and increased nuchal translucency in the first trimester: report of 2 cases. *J Ultrasound Med* 2009;28:1077–80.
- [21] Pearl W. Heart disease associated with deletion of the short arm of chromosome 18. *Pediatr Cardiol* 1989;10:174–6.
- [22] Goumy C, Gay-Bellile M, Salaun G, et al. A novel 2q14.1q14.3 deletion involving *GLI2* and *RNU4* genes associated with partial corpus callosum agenesis and severe intrauterine growth retardation. *Birth Defects Res A Clin Mol Teratol* 2016;106:793–7.
- [23] Bouman A, Weiss M, Jansen S, et al. An interstitial de-novo microdeletion of 3q26.33q27.3 causing severe intrauterine growth retardation. *Clin Dysmorphol* 2015;24:68–74.
- [24] Jung PS, Won HS, Cho IJ, et al. A case report of prenatally diagnosed tetrasomy 18p. *Obstet Gynecol Sci* 2013;56:190–3.
- [25] Gocke H, Muradow I, Zerres K, et al. Mosaicism of isochromosome 18p. Cytogenetic and morphological findings in a male fetus at 21 weeks. *Prenat Diagn* 1986;6:151–7.
- [26] Practice Bulletin No. 162: Prenatal Diagnostic Testing for Genetic Disorders. *Obstet Gynecol* 2016;127:e108–22.
- [27] Committee Opinion No. 682: microarrays and next-generation sequencing technology the use of advanced genetic diagnostic tools in obstetrics and gynecology. *Obstet Gynecol* 2016;128:e262–8.