

ORIGINAL INVESTIGATION

Superior Extended Nasal Myocutaneous Island Flap: An Alternative to Forehead Flap Reconstruction of the Nose

Simon Madorsky, MD,* Anthony Do, MS2, and Orr Meltzer, BS

Abstract

Importance: Medium and large nasal defects are mostly addressed with paramedian forehead flap reconstruction. The superior extended nasal myocutaneous island (SENMI) flap offers an alternative that can be single stage and can avoid a gross deformity.

Objective: To describe a new flap for nasal reconstruction of medium and large nasal defects and to define the flap's limitations and indications.

Design, Setting, and Participants: This original study was a retrospective case series of patients who underwent SENMI flap reconstruction from 2008 to 2018 at a private tertiary referral center—Skin Cancer and Reconstructive Surgery Center (SCARS Center). Participants included all consecutive patients of the senior author who had undergone SENMI flap from September 2012 to December 2018, consisting of 53 patients. Indications for surgery were mostly skin cancer defects, postreconstructive, and post-traumatic deformities. IRB approval was obtained from the St. Joseph Health Center for Clinical Research.

Main Outcomes and Measures: The location of the defects was defined. The vertical length of flap advancement was measured. Number of stages required to achieve functional and aesthetic goals was reported. Appearance rating after the first stage was assessed.

Results: A total of 53 patients [mean age 68 (range 30–92) years; 26 (49%) female and 27 (51%) male] were included in the case series. Reconstructed areas included 8 in the upper two-thirds of the nose (dorsum and sidewall), 34 in nasal tip, 32 in nasal ala, 12 in soft tissue triangle and infratip, and 13 full thickness defects of the alar rim. The flap advancing distance defined the nature of flap mobility. Of 53 patients, 41 had up to 2.0 cm of flap advancement and 12 had 2.0 to 3.2 cm of advancement. Of 52 patients aesthetically evaluated, 43 had mild or no detectable shape deformity on photographic evaluation after one stage. Single stage was performed in 25 patients, two stages in 21 patients, and three stages in 7 patients. Functional nasal valve stenosis was present in 18 patients (33%) after one stage. Partial flap ischemia occurred in two patients (4%).

Conclusions and Relevance: SENMI flap is an effective technique for nasal reconstruction. It offers a single- or two-stage alternative with less temporary deformity in comparison with forehead flap reconstruction.

Introduction

Medium and large defects in the lower third of the nose traditionally demand reconstruction with the versatile paramedian forehead flap. However, another approach to nasal reconstruction with a single-stage procedure followed a

different evolutionary track that was first documented in the 19th century. It evolved from V-Y advancements to true superior nasal myocutaneous island flaps.

The earliest documented reports of this evolution were well summarized by Mazzola in his 1990 response to an

Skin Cancer and Reconstructive Surgery Center (SCARS Center), Newport Beach, California, USA.

*Address correspondence to: Simon Madorsky, MD, Skin Cancer and Reconstructive Surgery Center (SCARS Center), 180 Newport Center Drive Ste. #158, Newport Beach, CA 92660, USA, Email: smadorsky@scarscenter.com

© Simon Madorsky et al. 2020; Published by Mary Ann Liebert, Inc. This Open Access article is distributed under the terms of the Creative Commons Attribution Noncommercial License (<http://creativecommons.org/licenses/by-nc/4.0/>) which permits any noncommercial use, distribution, and reproduction in any medium, provided the original author(s) and the source are cited.

KEY POINTS

Question: What are the indications, limitations, and aesthetic outcomes of the superior extended nasal myocutaneous island (SENMI) flap for nasal reconstruction?

Findings: SENMI demonstrated to be a versatile flap that can replace the forehead flap for nasal defects up to 3 cm based on the data set of 53 patients. It was completed as a single stage in 25 patients, whereas 21 patients required a second-stage procedure to achieve functional and aesthetic goals, and 7 patients required a third stage.

Meaning: The SENMI flap is an effective alternative to forehead flap reconstruction for various nasal defects of a medium-to-large size.

article recapitulating the V-Y bipediced glabellar flap. The flap was conceived in 1846 by Neumann and extensively reported by Szymanowski in 1870.¹

In 1967, Rieger described another aggressive form of a vertical V-Y advancement leaving a broad pedicle on one side only. In this seminal publication, he credited Esser's 1917 article on island flaps. Rieger's flap used the upper two-thirds of the nose to fill defects around the tip not exceeding 2 cm. The lack of release from a wide lateral myocutaneous pedicle led to added superior tension on the nasal tip and a standing cone deformity at the axis of rotation.²

In a more contemporary publication in 1979, Zook summarized the versatility of the true V-Y advancement flaps for various facial defects. Eighteen patients had superiorly based flaps to repair the nasal tip with maximum advancement of 2 cm.³ However, these were not true island flaps as he did not undermine his flaps or provide the fascia and muscle release necessary to limit the tension of closure.

In 1985, Marchac detailed a modification of Rieger's frontonasal flap in 50 patients. He narrowed the broad pedicle of Rieger's flap to a myocutaneous pedicle at the inner canthus. This axial myocutaneous flap was supplied by and tethered to the medial canthal area vessels.⁴

Martire in 1995 described a single case of a myocutaneous axial rotation island flap with lateral pedicle based on the "transverse part of the nasal muscle." In essence, he lowered Marchac's pedicle to the lateral nasal sidewall and created a true superiorly based island flap. The superior donor site was closed in a V-Y manner. The flap was claimed to close defects >2 cm and even defects involving the rim. However, the flap lacked skin preservation efficiency by requiring skin resection lateral to the defect.⁵

Ohsumi's dorsonasal V-Y advancement island flap (1998) was a much smaller modification of Martire's flap. This was a true superior island flap based on the lateral nasal artery to repair 9 mm defects in the nasal tip, soft tissue triangle, and alar rim in three patients.⁶

Ercocen in 2002 described a single case of the first extended superior nasal island flap. This V-Y dorsal nasal island flap had bipediced blood supply of lateral nasal arteries and repaired a nasal tip defect with an advancement distance of 2.5 cm.⁷

Wiley and Papadopoulos in 2008 presented the largest number to date of the smaller superior nasal island flaps based on a single muscle pedicle (sling) technique. In this 61-patient review, majority were small defects of 1 to 2 cm, whereas 6 patients had defects of 2.1–2.8 cm presumably treated with a combination of flaps.⁸

Over the past 10 years (2008–2018), the senior author (S.J.M.) has performed 231 superior nasal island flaps. Since 2012, the technique has evolved with an extension of the flap into the glabella and forehead while preserving vascular supply within the unilateral myofascial sling. This modification, labeled as superior extended nasal myocutaneous island (SENMI) flap, has proven to be robust and predictable while offering unique advantages in reconstruction of the lower third of the nose. This study analyzes 53 consecutive patients who had been treated with the SENMI flap. The indications, complications, and limitations of the flap are evaluated and summarized.

Methods**Study design**

After IRB review and approval was obtained from the St. Joseph Health Center for Clinical Research, a retrospective chart review was done to select all the patients who had the SENMI flap utilized from 2008 to 2018. Waiver of informed consent was granted by the IRB committee.

The classification of the extended version of the 231 superior nasal island flaps is arbitrarily determined by its extent onto the nasal glabella or the forehead. This study was limited to the 53 flaps extending to and past the glabella. All of the patients' charts were reviewed for functional outcome, whereas 52 out of 53 patients with available postoperative photos were evaluated for aesthetic outcome and received a rating score of 1, 2, or 3. A rating of 1 was given if there was no visible deformity; a rating of 2 if there was some flap thickness, obvious scar visibility, or mild asymmetry; and rating of 3 if there was an obvious deformity. Staged procedures were determined to be those that took place in the operating room to achieve optimal outcome and patient satisfaction. Functional or aesthetic indications for staged procedures included nasal valve stenosis, thickness of the myocutaneous flap pedicle, scar revision, asymmetry correction, or contour deformity correction. Nonsurgical procedures done in the office, such as triamcinolone injections or dermabrasion, were not considered staged procedures and were not reported. The assessment of functional outcome is limited to patient self-reporting and not by any objective criteria.

Surgical technique

The flap is designed by extending the incisions superiorly from the defect (Fig. 1). Because the pedicle is based laterally, the downward arc of rotation will produce an ipsilateral pull on the cutaneous island with lower third of nose defects. As a result, the flap design should compensate for that by initially curving away from the side of the arc and the pedicle.

The choice of pedicle and blood supply side can be based on variables such as surgeon preferences, pre-existing scarring, or other surgical incisions. Lateral defects use ipsilateral pedicle. Slightly off the midline defects can also use contralateral pedicle if necessary.

Once the side of the blood supply is determined, the flap is outlined on the skin. The length of the superior extended nasal island flap is based on two factors: the location of the defect and the elasticity of the nasal dorsal skin. The further caudal the defect's location, the longer the island flap needs to be. The goal is to displace the donor defect further cephalically, away from the thick skin of the tip and the lower dorsum. The skin of the upper dorsum and the glabella have greater elasticity. Consequence of shorter flap is greater tension of closure in the mid dorsum and twisting of the nasal tip.

Width of the defect also extends the flap length. The wider the defect, the longer the convergence of the flap sides. In other words, the angle of convergence has to re-

main acute. In many cases, the convergence cannot begin until the flap sides are at the mid dorsum due to poor skin elasticity. So, the inelastic skin and width of the defect push the flap extension into the glabella and forehead.

The angle of inclination of the flap is determined by the location of the defect. Inclination is defined by the tilt away from the vertical. Placement of incisions may be guided by anatomic subunit considerations such as avoidance of crossing the nasal alar groove. That incision across would obliterate the groove. The compensation of the pull of the arc of rotation would also guide the flap inclination. The final flap direction is best placed in the midline of the forehead glabella.

Once the flap direction is designed, the incisions are placed through the full thickness of the skin, leaving the underlying muscle fascia undisturbed (Fig. 1B). The ipsilateral incision depth is critical to avoid injuring the blood supply of the myofascial pedicle below. From that point, the dermis is elevated off the muscle fascia utilizing a blade dissection technique. This is a scraping/pushing technique avoiding direct blade pressure. The plane of separation is between the deepest sebaceous glands of the deepest dermis and above the thin muscle fascia. Tolerances of this dissection plane are very tight, and meticulous technique is critical. In some patients, this may be a natural plane with quick elevation, but in some patients, this plane is nonexistent and

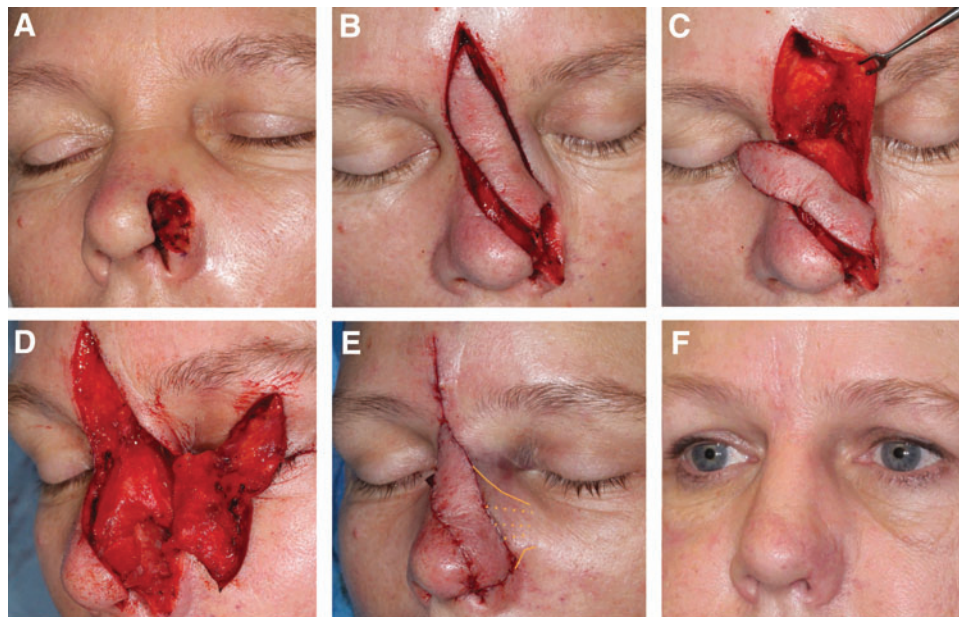


Fig. 1. Construction of the SENMI flap. (A) 2.1 × 1.8 cm full thickness defect on nasal ala, tip, and soft tissue triangle. (B) Surgical preparation and flap extension to forehead. (C) Flap mobility. (D) Pedicled flap viewed laterally and septal cartilage graft for nasal support. (E) Immediate postoperative with superimposed boundaries of myofascial pedicle release. (F) Final aesthetic outcome 5 months postoperatively after two stages. SENMI, superior extended nasal myocutaneous island.

requires 30 minutes of significant effort to elevate. A large majority of patients have an identifiable plane based on the senior author's experience. The extent of the skin elevation over the pedicle depends on multiple factors, but usually extends to the nasal cheek junction.

The incision contralateral to the pedicle is then taken through the muscle plane, cauterizing the vessels within. At that point, through that incision the myocutaneous flap is elevated off the nasal cartilages and bone (Fig. 1C). The elevation continues over the piriform aperture and medial maxilla, releasing the deep fascial attachments.

The muscle pedicle can then be cut at its superior (cephalic) and inferior (caudal) attachments. These cuts release the pedicle for needed rotation. Here too are critical landmarks. Superiorly lies the angular artery that may or may not need to be cut for flap release. Additional release may be required below the medial canthus through the pedicle. The fibers that limit release of the flap are actually sensory nerves. They can be identified with meticulous dissection and cut sparing the angular artery.⁹ The medial canthus itself must be avoided.

The inferior (caudal) release of the muscle pedicle is easier to perform. The variable alar artery and its branches are in the path of that release and should be preserved.⁹ But even when injured, no postoperative ischemia has been observed. This release can extend past the alar base around the inferior extent of the piriform aperture if needed.

The maximal release can allow the cutaneous portion of the flap to advance up to 3 cm caudally (Fig. 2). With experience, the surgeon will limit the dissection and release to what is necessary for flap movement.

The flap reattachment is another critical step of the operation, because it is at this juncture that nasal tip twisting can occur. Nasal tip symmetrical cephalic rotation is an accept-

able intraoperative consequence, and is expected to resolve as edema subsides. Some cases require septal cartilage grafts for nasal tip or nasal valve support (Fig. 1D). The grafts can resist cephalic rotation in higher tension closures.

Secondary procedures involve scar revision or dermabrasion. Some cases require sectioning of the muscle pedicle due to its thickness at the caudal edge. This thickness can impinge on the internal nasal valve, impacting the airway. The secondary procedures can easily be performed under local anesthesia.

Although anticoagulation worsens deep blood collection and swelling, it is not an absolute contraindication to the procedure.

Results

Over the past 6 years, 53 patients were treated with the SENMI flap. Table 1 gives patient demographics and indications for surgery. When analyzing defect size, an emphasis was placed on the advancing distance of the flap itself rather than the size of the defect. In all the cases, the SENMI flap advanced over the height of the defect, not the width. Figure 3 presents the histogram of advancing distances, with an average advancing distance of 1.67 (SD 0.5) cm. The minimum and maximum advancing distances were 0.6 and 3.2 cm, respectively.

Table 2 gives how many defects were located in the upper two-thirds of the nose, tip, ala, soft tissue triangle/infratip, and alar rim organized by flap advancing distance. Defects of the dorsum and sidewall were combined into the category of upper two-thirds of the nose. Alar rim defects were all full thickness defects. Because a single patient's defect may overlap two defined defect locations, a total of 99 defect locations are documented in Table 2.

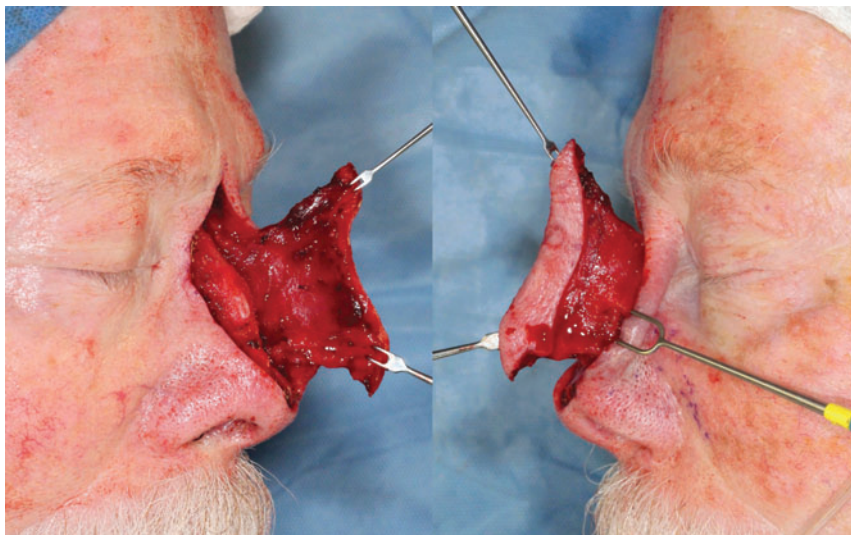


Fig. 2. Mobility and vascular reliability of the SENMI flap depend on the wide release of the myofascial pedicle.

Table 1. Patient demographics for superior extended nasal myocutaneous island flap

Characteristics	
No. of patients	53
Gender (%)	26 females (49%), 27 males (51%)
Age range	30–92
Mean, median age	68, 69
Indication for surgery	
Basal cell carcinoma	40
Squamous cell carcinoma	4
Melanoma	4
Merkel cell carcinoma	2
Scar revision	3

This table displays patient demographic data and indication for surgery. Statistical data were rounded up to the nearest data.

The largest distribution included the nasal tip with 34 defects including that location.

The extension of the SENMI flap to the forehead or glabella showed a correlation trend with the advancing distance. The SENMI flap tended to extend to the glabella when the flap advanced up to 2 cm. When the flap advancing distance was >2 cm, the flap tended to extend to the forehead.

Owing to the availability of post-operative photographs, 52 out of 53 patients were evaluated for aesthetic complications and assigned appearance ratings after the first stage of surgery, while all 53 patients were evaluated for functional complications (Fig. 4). Aesthetic assessment was completed by a three-person unanimous vote of the center's research staff. Out of the 52 cases reviewed, 6 cases (12%) were rated as 1 (unnoticeable reconstruction), 37 cases (71%) were rated as 2 (mild shape deformity—scar edge visibility, mild asymmetry, and nasal wall fullness), and 9 cases (17%) were rated as 3 (obvious deformity—alar notching/retraction or twisted/asymmetric tip).

Aesthetic complications included 6 cases (12%) of nasal shape distortion or twisting, 7 cases (13%) with alar rim retraction and notching, 20 cases (38%) with flap thickness, 4 cases (8%) with sidewall fullness, and 24 cases (46%) with scar visibility.

Functional complications included 18 cases (33%) of nasal valve stenosis that were surgically addressed and 2 cases (4%) with ischemia [1 case of epidermolysis (2%) and 1 case of partial thickness ischemia]. Patient with partial flap ischemia had an ipsilateral lateral extended nasal island flap (LENI flap) in addition to the SENMI flap, based on ipsilateral blood supply.¹⁰ Of the 53 cases, 24 cases (45%) required septal cartilage grafts, 11 (20%) required a skin graft, 1 required an ethmoid bone graft, and 11 (20%) cases required additional island flaps. Two of the additional flaps were LENI flaps. The second patient with a concurrent LENI flap based on contralateral blood supply had no complications.

The SENMI flap was employed as a single-stage procedure in 25 cases (46%), a two-stage procedure in 22 cases (41%), and a three-stage procedure in 7 cases (13%). Non-surgical procedures to improve aesthetic outcomes such as triamcinolone injections or dermabrasions were excluded.

Discussion

The SENMI flap has been the product of evolution of the senior author's technique and serves as the latest progression of related flaps used in nasal reconstruction. The SENMI flap presents a realistic alternative to the paramedian forehead flap for reconstruction of medium to large nasal defects. The flap has the ability to advance up to 3 cm and can extend caudally to the alar rim. This potentially single-stage technique can be challenged by a version of the forehead flap single-stage technique.¹¹ However, that flap has very limited applications as has later been clarified

Fig. 3. Histogram of advancing distances in 53 cases of the SENMI flap.

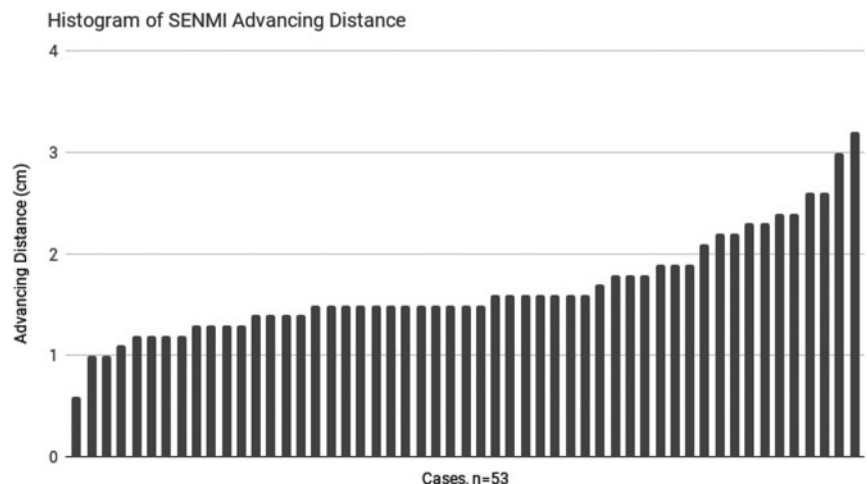


Table 2. Number of defect locations and flaps organized by advancing distance range and extension to forehead

Defect location	Advancing distance ranges (cm)					Total locations
	<1	1<1.5	1.5<2.0	2.0<2.5	≥ 2.5	
Dorsum/sidewall (upper two-third of nose)	0	0	4	2	2	8
Tip	0	10	17	4	3	34
Ala	0	9	15	5	3	32
Soft tissue triangle/infratip	2	2	7	1	0	12
Alar rim/(full thickness defect)	2	3	6	2	0	13
Total	4	24	49	14	8	99

Extension of flap	Advancing distance ranges (cm)					Total flaps
	<1	1<1.5	1.5<2.0	2.0<2.5	≥ 2.5	
ETF	0	0	4	6	4	14
ETG	2	13	22	1	1	39
Total flaps	2	13	26	7	5	53

This table documents distribution of defects on the nose. The superior extended nasal myocutaneous island flap can repair a single defect extending to two locations such as the tip and ala. Thus, the total number of locations (99) is larger than the number of cases (53). This table also indicates how many cases extended into the glabella (ETG) or past the glabella and into the forehead (ETF).

ETF, extended to forehead; ETG, extended to glabella.

by the author.¹² The SENMI flap has a more predictable vascular supply and a broad range of applications in nasal reconstruction.

Despite its utility as a single-stage reconstruction, two stages were performed in half of the cases. Tip reconstruction had a significantly higher rate of second stages. Additional stages addressed incision visibility, flap thickness, pedicle fullness with nasal valve im-

pingement, or alar rim distortion. The propensity of nasal tip twisting when repairing tip defects can be a vexing challenge, but is mostly avoidable with extending the flap narrowing more cephalically into the forehead. Many of these issues can also be minimized with cartilage grafting to strengthen the nasal tip. The outcome of most secondary flap surgeries was minimally detectable signs of reconstruction.

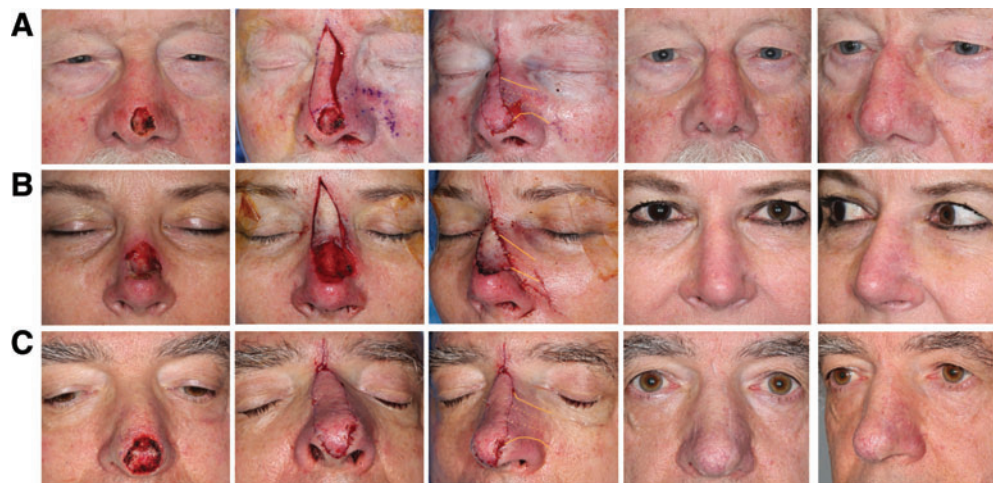

Fig. 4. Before and after photographs of the SENMI flap. Boundaries of myofascial pedicle release are superimposed on immediate postoperative images. **(A)** 1.4 × 1.4 cm defect on nasal tip, 1.4 cm advancement distance, flap extension into glabella, two stages, and final aesthetic outcome 3 months postoperatively. **(B)** 2.4 × 2.2 cm defect on nasal dorsum/sidewall, 2.4 cm advancement distance, flap extension into forehead, one stage, and final aesthetic outcome 1 year 2 months postoperatively. **(C)** 2.1 × 1.8 cm defect on nasal tip/infratip, 1.8 cm advancement distance, flap extension into glabella, two stages, and final aesthetic outcome 6 months postoperatively.

The vascular resiliency of the flap is demonstrated by the 12 cases extended to forehead with some extending to mid forehead. No vascular compromise of the longest flaps occurred. The only tip ischemia occurred in a flap where the blood supply was compromised by another flap—LENI competing for the same ipsilateral blood supply.¹⁰ The vascular supply of the SENMI flap is based on branches of the angular artery, including the lateral nasal artery and alar artery in some cases. The extension of the dorsal nasal artery and its central artery branch into the forehead reliably supplies the flap extension into the forehead.¹³

SENMI flap's advantages include its tissue efficiency—minimal to no tissue is discarded, unlike flaps such as the bilobed flap. SENMI flap is potentially a single-stage reconstruction, particularly in the upper two-thirds of the nose. It also avoids temporary deformity of the visible flap pedicle, unlike the nasolabial fold transposition and the forehead flaps. The absence of exposed pedicle that either bleeds, crusts, or requires skin grafting creates a cleaner postoperative course. Finally, patients' preoperative acceptance of the SENMI flap is much better than a forehead flap in the senior author's experience.

The limitations of the SENMI flap include wide lower third defects traditionally reserved for forehead flaps.

The flap should also not cross the nasal alar groove to avoid its effacement. In ala defects, the SENMI flap curves aggressively toward the tip before straightening through the dorsum, avoiding most of the nasal alar groove. Twisting of the nasal tip can also be largely avoided by keeping the SENMI flap wide through the middle portion of the nose and then tapering it into the forehead. Thus, the wider defects extend higher into the forehead. Defects higher on the dorsum also extend higher into the forehead.

Although advancing distance up to 3 cm was demonstrated in our study, most patients will only tolerate up to 2.5 cm of flap advancement. Finally, the SENMI flap can be challenging to dissect and more technically demanding than a forehead flap. In some cases, forehead flap is an easier flap to surgically execute.

The SENMI flap offers a unique alternative to the forehead flap for nasal reconstruction. It also supplants some indications for nasolabial fold transposition flaps and bilobed flaps. In some cases, the SENMI flap can be used for reconstruction of alar rim full thickness defects in

conjunction with other internal lining techniques. It has a predictable vascular supply and excellent cosmetic outcome. It is a single-stage reconstruction in nearly half of the nasal defects in our study.

Authors' Contributions

All authors had full access to design and conduct of the study; collection, management, analysis, and interpretation of the data; preparation, review, or approval of the article; and decision to submit the article for publication.

Acknowledgment

We thank An Ta, BS, for assisting with administrative work. Written permission was obtained to include her name and she was compensated for her contributions.

Author Disclosure Statement

No competing financial interests exist.

Funding Information

Grants funding was received from the Skin Cancer and Reconstructive Surgery Foundation.

References

- Mazzola R. Bipedicled flaps for the nasal tip. *Plast Reconstr Surg.* 1990;85(6):997–998.
- Rieger RA. A local flap for repair of the nasal tip. *Plast Reconstr Surg.* 1967;40(2):147–149.
- Zook EG, Van Beek AL, Russell RC, Moore JB. V-Y advancement flap for facial defects. *Plast Reconstr Surg.* 1980;65(6):786–797.
- Marchac D, Toth B. The axial frontonasal flap revisited. *Plast Reconstr Surg.* 1985;76(5):686–694.
- Martire L, Colares JH, Reis JMD, Fernandes L. Nasal tip repair with axial flap of nasal muscle. *Aesthetic Plast Surgery.* 1995;19(6):527–530.
- Ohsumi N, Ishikawa T, Shibata Y. Reconstruction of nasal tip defects by dorsonasal V-Y advancement island flap. *Ann Plast Surg.* 1998;40(1):18–22.
- Ercocen AR, Can Z, Emiroglu M, Tekdemir I. The V-Y island dorsal nasal flap for reconstruction of the nasal tip. *Ann Plast Surg.* 2002;48(1):75–82.
- Wiley A, Papadopoulos DJ, Swanson NA, Lee KK. Modified single-sling myocutaneous island pedicle flap: series of 61 reconstructions. *Dermatol Surg.* 2008;34(11):1527–1535.
- Whetzel TP, Mathes SJ. Arterial anatomy of the face: an analysis of vascular territories and perforating cutaneous vessels. *Plast Reconstr Surg.* 1992;89(4):591–603; discussion 604–595.
- Madorsky SJ, Ta A. Use of a lateral extended nasal island flap for nasal reconstruction. *JAMA Facial Plast Surg.* 2019;21(5):434–439.
- Park SS. The single-stage forehead flap in nasal reconstruction. An alternative with advantages. *Arch Facial Plast Surg.* 2002;4:32–36.
- Park SS. Revisiting the single-stage forehead flap in nasal reconstruction. *JAMA Facial Plast Surg.* 2013;15(5):383–384.
- Faris C, van der Eerden P, Vuyk H. The midline central artery forehead flap. A valid alternative to supratrochlear-based forehead flaps. *JAMA Facial Plast Surg.* 2105;17(1):16–22.