

Orbital Fat Volume After Treatment with Topical Prostaglandin Agonists

Jessica Y. Chen,¹ Alan Le,²⁻⁴ Joseph Caprioli,^{2,4} JoAnn A. Giaconi,^{2,4} Kouros Nouri-Mahdavi,^{2,4} Simon K. Law,^{1,2,4} Laura Bonelli,^{2,4} Anne L. Coleman,^{2,4,6} and Joseph L. Demer²⁻⁵

¹Computational and Systems Biology Interdepartmental Program, University of California, Los Angeles, California, United States

²Department of Ophthalmology, University of California, Los Angeles, California, United States

³Bioengineering Interdepartmental Program, University of California, Los Angeles, California, United States

⁴Stein Eye Institute, University of California, Los Angeles, California, United States

⁵Department of Neurology, University of California, Los Angeles, California, United States

⁶Department of Epidemiology, Jonathan and Karin Fielding School of Public Health, University of California, Los Angeles, California, United States

Correspondence: Joseph L. Demer, Stein Eye Institute, 100 Stein Plaza, UCLA, Los Angeles, CA 90095-7002, USA; jld@sei.ucla.edu.

Received: September 19, 2019

Accepted: April 21, 2020

Published: May 26, 2020

Citation: Chen JY, Le A, Caprioli J, et al. Orbital fat volume after treatment with topical prostaglandin agonists. *Invest Ophthalmol Vis Sci.* 2020;61(5):46. <https://doi.org/10.1167/iovs.61.5.46>

PURPOSE. Topical prostaglandin analogs (PGAs) are common treatment for primary open-angle glaucoma (POAG) but reportedly may cause adnexal fat atrophy. We asked if patients with POAG treated with PGAs have abnormalities in orbital fat volume (OFV).

METHODS. We studied 23 subjects with POAG who had never experienced intraocular pressure (IOP) exceeding 21 mm Hg and were treated long term with PGAs, in comparison with 21 age-matched controls. Orbital volume, non-fat orbital tissue volume, and OFV were measured using high-resolution magnetic resonance imaging.

RESULTS. Subjects with POAG had been treated with PGAs for 39 ± 19 months (SD) and were all treated within the 4 months preceding study. In the region from trochlea to orbital apex, OFV in POAG was significantly less at 9.8 ± 1.9 mL than in the control subjects at 11.1 ± 1.3 mL ($P = 0.019$). However, between the globe-optic nerve junction (GONJ) and trochlea, OFV was similar in both groups. Width and cross sectional area of the bony orbit were significantly smaller in POAG than in controls ($P < 0.0001$). Posterior to the GONJ, the average orbital cross-sectional area was 68.2 mm² smaller, and the orbital width averaged 1.5 mm smaller throughout the orbit, in patients with POAG than in controls.

CONCLUSIONS. Patients with POAG who have been treated with PGAs have lower overall OFV than controls, but OFV in the anterior orbit is similar in both groups. Lower overall OFV in POAG may be a primary association of this disorder with a horizontally narrower bony orbit, which may be a risk factor for POAG at nonelevated IOPs.

Keywords: orbit, prostaglandins, magnetic resonance imaging

Glaucoma is the leading cause of irreversible blindness.^{1,2} Prostaglandin analogs (PGAs) are commonly applied topically to the eye as first-line treatment for primary open angle glaucoma (POAG) because they reduce intraocular pressure (IOP) through facilitation of aqueous outflow³⁻⁶ and are convenient and well tolerated. However, topical PGA agents reportedly cause periorbital fat atrophy, deepening of the superior sulcus, ptosis,⁷⁻⁹ and have been claimed to induce enophthalmos in some patients.^{7,10,11} Recently, Higashiyama et al. used standard magnetic resonance imaging (MRI) to compare orbital fat volume (OFV) in nine patients treated monocularly with brimatoprost for various secondary glaucomas for at least 11 months, reporting mean OFV to be significantly smaller in the treated than nontreated eye.¹² There is no comparable study of the effects of PGAs in POAG without abnormally elevated IOP.

The pathogenic role of IOP elevated well above the statistically normal range of up to 22 mm Hg is undis-

puted in congenital and juvenile glaucoma,¹³ angle closure,¹⁴ uveitic,¹⁵ and traumatic glaucoma,¹⁶ because IOP is typically highly elevated and progression of optic neuropathy is decisively attenuated when IOP is normalized in these disorders. Nevertheless, elevated IOP is no longer a diagnostic criterion for POAG, recognizing that many such patients, including the great majority of Asians,¹⁷⁻²² do not exhibit abnormally high IOP,²³ yet they suffer progressive glaucomatous optic neuropathy even at lower IOPs.²⁴ Such observations mandate consideration of other causes of POAG. Eye movement-related deformation of the optic nerve (ON) has been suggested as another possible mechanical etiology for optic neuropathy in POAG.²⁵⁻²⁹ Adduction may be particularly pathogenic, because ON length is insufficient to avert tethering the globe in adduction.^{25,27-29} Optical coherence tomography shows that when adduction exceeds 26 degrees,³⁰ deformations of the ON head and Bruch's membrane greatly exceed those during extreme IOP

elevation,³¹ or deformations recently proposed as pathological to retina.³²

The human horizontal oculomotor range is ± 55 degrees, meaning that people can maximally abduct and adduct to that angle.^{33,34} Although eye movements are usually smaller during sedentary activities or when the head is restrained in the laboratory or clinic, saccades and vestibular quick phases of 25 to 45 degrees are intrinsic to the large gaze shifts that are typical when the head and body are unrestrained.³⁵ Vestibular slow phase eye movements during active head rotation may reach 40 degrees eccentricity in healthy people,³³ whereas slow phases during passive, whole-body rotation can exceed 35 degrees.³⁶ In healthy people, and in combination with catch-up saccades, reach 30 degrees even in unilateral vestibular deafferentation.³⁷ Despite head restraint, vertical saccades of up to 30 degrees can be made from horizontal eccentricities of up to 50 degrees.³⁸

Magnetic resonance imaging has demonstrated significant globe retraction in adduction of only about half the oculomotor range in patients who have POAG with²⁹ and without²⁷ abnormally elevated IOP, but not in healthy controls. This globe retraction suggests that adduction tethering induces mechanical strain on the globe's suspensory tissues, including the orbital fat. However, it is not clear whether abnormally great globe retraction in adduction in POAG is due to abnormally great ON traction in such patients, versus more compliant retrobulbar tissues providing less mechanical resistance to normal ON traction in adduction. If topical PGAs do induce atrophy of retrobulbar orbital fat, the remaining tissues might become more compliant. Such a finding of orbital fat atrophy would then suggest that the observed globe retraction in adduction in POAG patients who have been treated with PGAs is merely an epiphenomenon of therapy, rather than related to the pathogenesis of the disease.

Another consideration in evaluating the possible effect of PGAs is the total volume of the orbit itself. Possible variations in the size and shape of the orbit have not been previously considered in relationship to PGA therapy.

In this study, we sought to clarify the foregoing questions through high resolution, surface coil MRI of OFV and orbital dimensions in patients with POAG without abnormally elevated IOP who had been treated with topical PGA drugs. We aimed to extend the literature beyond the small number of previously-reported patients who were monocularly treated for secondary glaucoma¹² and to evaluate the anatomic compartments where the orbital fat resides.

METHODS

Subjects

This study was conducted according to a protocol approved by the Institutional Review Board for Protection of Human Subjects of the University of California, Los Angeles, and conformed to the tenets of the Declaration of Helsinki. Subjects gave written informed consent prior to participation.

Included were 23 patients (13 females, 10 males, average age 63 ± 11 years (SD), range 52–83 years) diagnosed by a coauthor who is a glaucoma specialist to have POAG, but who had never had an IOP exceeding 21 mm Hg, with or without treatment. Subjects in the POAG group included 11 Asians, 11 Caucasians, and 1 African American. This distri-

bution of ethnicity did not differ significantly from that of the control group (χ^2 ; $P > 0.1$). All patients had been cumulatively treated with topical PGAs for an average of 39 ± 19 months and had been treated within the four months preceding the study. Six patients were treated with bimatoprost, 11 with latanoprost, five with tafluprost, one with travoprost. Most patients also received additional topical glaucoma medications. Patients were excluded if they had previously undergone intraocular surgeries besides those for cataract, glaucoma, refractive error; or if they had orbital disease, or if they had any other cause for optic neuropathy. Because patients with POAG at our institution are almost universally treated with topical PGAs, it was not possible to recruit a control group with POAG who were not exposed to these drugs.

A healthy control group without POAG was recruited through advertisement, consisting of 15 females and 6 males, with average age 62 ± 10 years (range 47–78 years). Subjects in the control group included two Asians, 11 Caucasians, and 8 African Americans. Control subjects were required to have corrected visual acuity of 20/20 in each eye, normal IOP, no history of ocular surgeries besides those for cataract or refractive error, no ocular trauma, and no other ocular disorder except for refractive error or lens opacity. None had been treated with PGAs or any other ocular hypotensive agents.

Magnetic Resonance Imaging

An author performed high resolution MRI using a 1.5T General Electric Signa scanner and custom surface coils (Medical Advances, Milwaukee, WI) with T2 fast spin echo pulse sequence as described.^{39,40} To minimize movement artifacts, subjects monocularly fixated an illuminated, fiber optic target in central gaze. Axial 2-mm-thick images (100×100 mm field of view, 256×256 matrix) including both orbits were obtained to determine distances between the orbital apex, globe-optic nerve junction (GONJ), and trochlea. Quasi-coronal sets of 17–20, 2mm thick planes perpendicular to the long orbital axis were obtained separately for each orbit (field of view 80×80 mm, 256×256 matrix, resolution 312 microns).

Image Analysis

Quasicoronal images were rotated as necessary to align the midline of the brain to vertical. Using the program *ImageJ64* (W. Rasband, National Institutes of Health, Bethesda, MD, USA), the extraocular muscles, ON, globe, orbit, blood vessels, and large nerves were manually traced in contiguous, quasi-coronal planes from the deep orbit to the trochlea (Fig. 1). Segmentation and measurements were performed independently by two graders to ascertain agreement. All subsequent measurements and calculations were automated through *ImageJ* macro scripts, ensuring rigor and reproducibility. Orbit volume (OV) was calculated by summing areas within the orbital borders in each image plane from the orbital apex to the trochlea, which was selected as an anatomic reference because it is fixed to the medial orbital wall. The summed areas were then integrated through all image planes by multiplying by the 2-mm image plane thickness to obtain the OV. We determined OFV by subtracting from the orbital areas, the cross-sectional areas of the other intraorbital tissues, including globe, muscles, nerves, and blood vessels (Fig. 1), then multiplying by the 2mm image plane thickness.

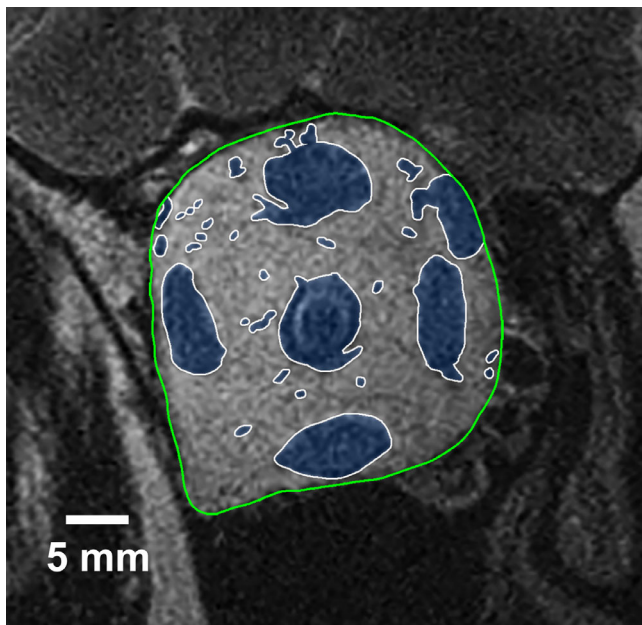


FIGURE 1. Quasicoronal MRI in the mid-portion of a representative right orbit, whose bony walls are outlined in green. Intraorbital structures including extraocular muscles, ON, and blood vessels, are outlined in white and shaded blue. Orbital fat represents the remaining orbital area excluding structures shaded in blue.

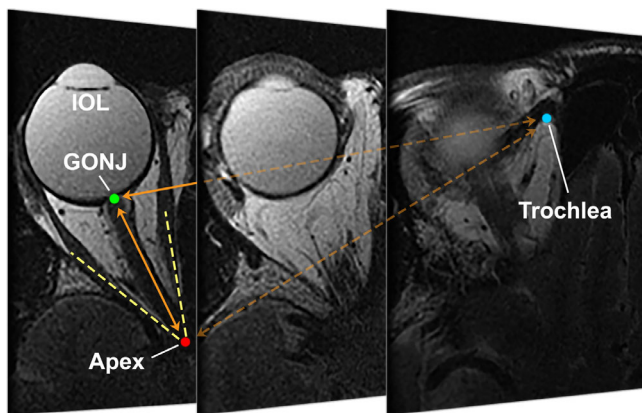


FIGURE 2. Axial MRI of representative orbit in pseudophakic subject, with contiguous 2 mm thick image planes arranged from inferior at mid-globe at left, to superior at right with the plane including the trochlea. GONJ, globe-optic nerve junction; IOL, intraocular lens.

Axial images were used to measure Cartesian distances in three dimensions across multiple planes between the trochlea, GONJ, and orbital apex. The orbital apex was defined in axial planes by the intersection of lines running formed by the centers of the lateral and medial rectus muscles (Fig. 2).

The orbit does not have a regular shape amenable to simple geometric description. Therefore the horizontal width of the orbit was determined by averaging its horizontal dimension within the central 60% of its vertical extent, as sampled at 15 equal intervals (Fig. 3). Horizontal width was averaged in each MRI plane from the GONJ to the trochlea to compute average orbital width. Using analogous parameters, average vertical height of the orbit was also obtained.

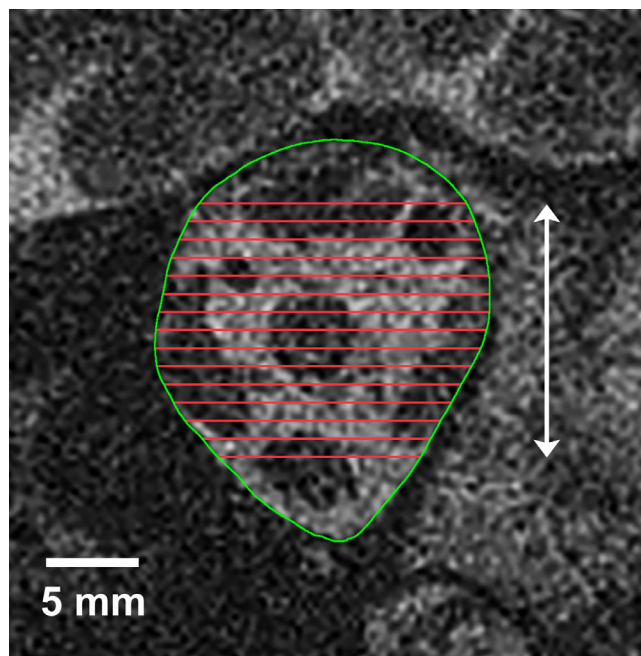


FIGURE 3. Horizontal width of each quasicoronal image was sampled 15 times (red lines) at uniformly-spaced vertical intervals spanning the middle 60% of the vertical extent of the orbit (white arrow). These measurements were averaged to compute orbital width in each image plane.

Statistical Analysis

To account for possible intraocular correlation between eyes of the same subject, statistical analysis was conducted with generalized estimating equations (GEE) implemented in SPSS software (Version 24.0; IBM Corp., Armonk, NY, USA), designating the eye as a within-subject variable, and including effects of subject age and race as factors. Models were repeated using only POAG and Asian versus non-Asian race as factors. Type 1 error characteristics of GEE are superior to *t*-testing for the data.⁴¹ Statistical significance was defined as $P < 0.05$. All measurements were independently duplicated by two authors, and subjected to Bland-Altman analysis to ascertain reproducibility.

RESULTS

Reproducibility

Agreement between measurements of OV by two independent observers was evaluated by Bland-Altman analysis, as illustrated in Figure 4. This analysis yielded a minimal bias of 0.023 that is about 0.14% of the 16.8 mL average.

Orbital Fat Volume

Although total OFV from apex to trochlea in POAG was significantly less than in controls, the difference was driven by the posterior orbit, not by the anterior orbit. Volume of fat in the whole orbit measured from apex to trochlea (Fig. 5A) was significantly less in POAG without abnormally elevated IOP at 9.7 ± 1.9 mL (SD) than in controls at 10.9 ± 1.3 mL ($P = 0.019$). Fat volume in only the deep orbit from the orbital apex to GONJ was also significantly less in POAG at 6.0 ± 1.7 mL for POAG than in controls at 7.5 ± 1.6 mL

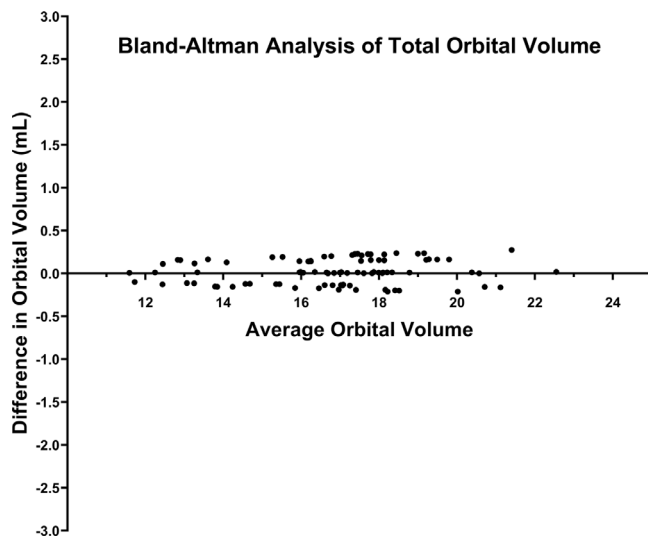


FIGURE 4. Bland-Altman plot of agreement between two independent observers measuring OV in all subjects. Abscissa plots the averages of each pair of measurements, and ordinate the differences within these pairs.

($P = 0.001$). However, in the anterior orbit between GONJ and the trochlea, the two groups had similar fat volumes: 3.7 ± 0.9 mL for POAG and 3.5 ± 0.9 mL for controls ($P = 0.465$). The total volume of intraorbital tissues, comprising the globe, ON, muscle, nerves, and blood vessels, did not differ significantly between POAG (6.5 ± 1.2 mL) and controls (6.4 ± 1.1 mL, $P = 0.610$).

Total OV measured from the apex to the trochlea was significantly less in patients with POAG at 16.3 ± 2.5 mL than in controls at 17.4 ± 2.0 mL ($P = 0.019$, Fig. 5B). The individual data points in Figure 5B suggest a possible bimodal distribution in the POAG group. This pattern is not attributable to sex because males and females were similarly distributed throughout the range of measurements.

Orbital Depth

The distances between the apex, trochlea, and GONJ were similar at about 41 mm in POAG and controls ($P > 0.08$, Fig. 6). Because the GONJ is a feature of the posterior globe, this indicates that anteroposterior globe position was similar in the two groups.

Orbital Dimensions

This difference in OV between patients with POAG and controls is attributable to difference in orbital profile, exemplified by the two MRI images taken at the same image plane immediately posterior to the GONJ as illustrated in Figure 7. Patients with POAG had significantly smaller average orbital cross-sectional areas than controls throughout the orbit, with the exception of only the two most anterior image planes that were similar (Fig. 8). In the range from 0 and 28 mm posterior to the GONJ, the average difference in orbital cross-sectional areas between controls and patients with POAG was 68.2 mm² (range 43.3 to 79.7 mm²). Orbits were also significantly narrower horizontally in POAG than in controls (Fig. 9, $P < 0.001$, analysis of variance [ANOVA]), again with the exception of only the two most anterior image

planes. The average difference in width of the orbit from 0 to 28 mm posterior to the GONJ between controls and patients with POAG was 1.5 mm (range 1.3–1.7 mm). Similarly, the vertical dimension of the orbit was significantly greater in controls than in POAG ($P < 0.001$, ANOVA). The average difference in orbital width between groups in the 28 mm region just posterior to the GONJ was 0.8 mm (range 0.4–1.1 mm).

Effects of Age, Race, and Sex

Multivariate analysis showed that age and race had insignificant effects on overall OFV ($P = 0.679$ and $P = 0.388$, respectively), posterior fat volume between the apex and GONJ ($P = 0.292$, $P = 0.154$, respectively), and OV anterior to the GONJ ($P = 0.939$, $P = 0.840$, respectively). Multivariate analysis was repeated using only Asian vs. non-Asian race and POAG as factors. In this limited model, Asian race had insignificant effects on total OFV ($P = 0.896$), posterior OFV between the apex and GONJ ($P = 0.746$), total OV ($P = 0.387$), and OFV between the GONJ and trochlea ($P = 0.311$); only the former two differed significantly between controls and subjects with POAG in the limited model ($P = 0.029$ and 0.006 , respectively). However, when the model for total OV included only Asian versus non-Asian race and POAG as factors, the presence of POAG was not significant ($P = 0.326$). The absence of a predictive influence of POAG on total OV in the foregoing case is attributable to the strong effect of Asian vs. non-Asian race, which when used as the sole input in a model yields extremely high significance ($\chi^2 = 2816$; $P < 0.0005$). The strong effect of Asian race was also evident when the comparison for total OV was limited to healthy control subjects ($\chi^2 = 2259$ ($P < 0.0005$)). Among healthy controls, mean OV was 15.7 ± 1.8 mL (SD) in Asians, but 17.4 ± 1.9 mL in non-Asians.

Because of the observed imbalance in sex among controls with 15 females and 6 males, the possibility of confounding by differences based on sex was investigated. There was a significant difference in OV between females and males in both the control and POAG groups ($P = 0.02$, $P = 0.003$, respectively), with average OV 18.4 ± 0.6 mL in control males, 17.6 ± 0.6 mL in males with POAG. Both groups of females had lower OV than both groups of males: 16.9 ± 0.3 mL in control females, and 15.4 ± 0.4 mL in females with POAG. When controls and subjects with POAG were pooled, the OV of males was significantly greater at 17.9 ± 0.4 mL than females at 16.2 ± 0.3 mL ($P = 0.001$).

We employed a bootstrap approach to investigate whether these gender differences had confounded the apparent significant differences in OV and total OFV between controls and subjects with POAG. Subgroup analyses were repeated with five different random samples formed by random exclusion of individual females from the control group to achieve the same gender balance as in the POAG group in whom the full sample already included gender balance. Statistical analyses were repeated after these different random exclusions of female subjects. The 1.1 to 1.2 mL less OV in patients with POAG than controls remained significant after gender-balancing of all random comparison groups (range $P = 0.0018$ – 0.007), with average 17.6 ± 0.4 mL OV in gender-balanced controls, and 16.4 ± 0.4 mL in subjects with POAG. The difference in total OFV also remained significant at about 1.2 mL after gender balancing the control subgroup (range $P = 0.002$ to 0.005), with average 11.0 ± 0.3 mL OFV in gender-balanced

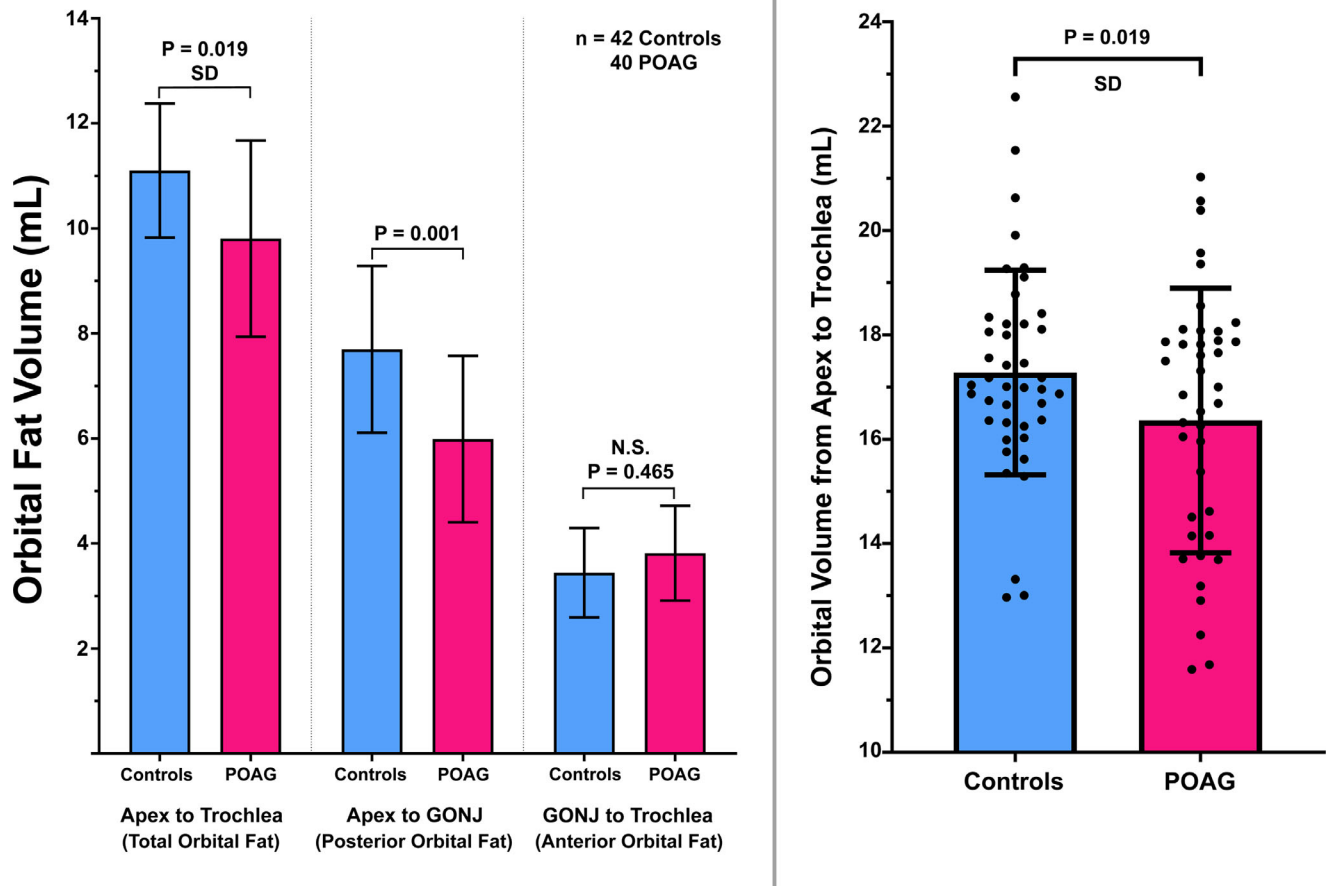


FIGURE 5. Orbital fat volume (OFV) (A) OFV in controls and patients with POAG without abnormally elevated IOP who were treated with topical PGAs. While total OFV from apex to trochlea in POAG was significantly less in patients than controls (*left paired columns*), the difference was driven by the posterior orbit from apex to the GONJ (*middle paired columns*). In the anterior orbit from the GONJ to the trochlea (*right paired columns*), OFV was similar in the two groups. (B) Total orbital volume (OV) of patients with POAG was significantly less than in controls. SD, standard deviation; N.S., not significant.

controls and 9.8 ± 0.3 mL in subjects with POAG. The persistence of these statistically significant differences after gender balancing randomization of subsamples suggests that gender differences do not account for the findings of subnormal OV and OFV in subjects with POAG.

DISCUSSION

This study demonstrates that patients with POAG at low IOP who have been treated with topical PGAs do indeed have less total orbital fat than age matched healthy control subjects not treated with PGAs. However, the volume of fat in the orbit anterior to the GONJ, the region most directly exposed to topical PGA treatment, did not significantly differ between patients with POAG and controls. Only in the deeper orbit, beginning in planes 2 to 4 mm anterior to the GONJ and deeper, did patients with POAG have less fat than controls. Because the combined volume of non-fat orbital structures such as extraocular muscles, nerves, and vessels, was similar in both groups, the lesser orbital fat in patients with POAG is due to their smaller bony orbits. Consequently, the lesser orbital fat volume in patients with POAG is unlikely to be the consequence of PGA exposure, but rather related to POAG itself. Direct measure-

ment of orbital size confirmed that patients with POAG have both horizontally and vertically narrower bony orbits than controls throughout in the orbit except most anteriorly (Fig. 7), although orbital depth was similar in the two groups. Taken together, these findings fulfill the main aim of the study and support the inference that topical PGA exposure are not the cause of subnormal OFV in patients with POAG at normal IOP. Moreover, these results instead suggest the possibility that a horizontally narrower bony orbit might be a risk factor for POAG at normal IOP. However, since Asian subjects with and without POAG had smaller OV than non-Asians, the possibility of a relationship between orbital size and POAG at normal IOP warrants further investigation.

The Higashiyama et al.¹² study used MRI to compare OFV in nine patients treated monocularly with brimatoprost for secondary glaucomas for at least 11 months. These authors reported mean OFV to be significantly smaller in the treated than nontreated eye. However, the modest 0.04 level of statistical significance for this small study was driven by a single patient who had an abnormally high OFV in the untreated fellow orbit.¹²

The present study was motivated by recognition that adipogenesis is inhibited by PGAs through activation of the FP receptor, which may cause fat atrophy.^{42,43} Common

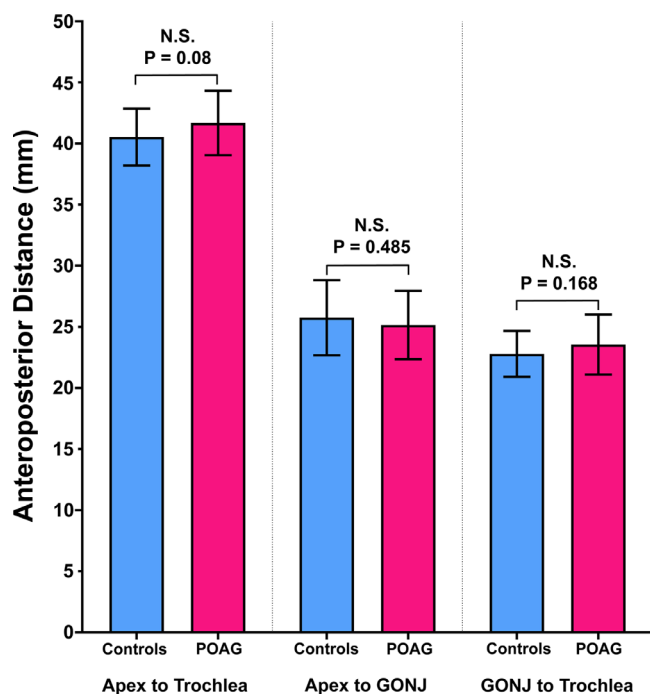


FIGURE 6. Anteroposterior dimensions of the orbit and position of the GONJ, did not differ between patients with POAG and the controls. N.S., not significant.

PGAs used today to reduce IOP include latanoprost, timolol, bimatoprost, travoprost, and tafluprost, as well as fixed combinations like latanoprost-timolol, bimatoprost-timolol, travoprost-timolol, and tafluprost-timolol.⁴⁴ Several clinical features have been associated with prostaglandin periorbitopathy that may occur in about half of patients after more than one year bilateral treatment with topical latanoprost: deepening of the upper eyelid sulcus, upper blepharoptosis, effacement of the lower eyelid fat pads, and inferior scleral show.^{11,45,46} One retrospective study has suggested that enophthalmos may occur in eyes unilaterally treated with latanoprost.⁴⁷ However, enophthalmos is not typically reported in patients with POAG and would not have been significant in the small unilateral treatment study by Higashiyama et al.,¹² except with the inclusion of one marked outlier case.

Orbital geometry may have some relationship to POAG without elevated IOP, or perhaps to the relatively high prevalence of the low IOP form of POAG in Asians.¹⁷⁻²¹ The bony orbit has been reported to be slightly larger in older than younger people⁴⁸ and to enlarge in thyroid eye disease,⁴⁹ although we are unaware of any reports of changes in bony orbital size associated with exposure to PGA drugs. While we cannot exclude this possibility, it seems improbable that PGA drugs applied topically to the ocular surface would alter the deep bony orbit without altering the orbital fat or anterior orbit. This study shows that the Asian orbit is smaller than the non-Asian orbit and smaller in females than males. Further study seems warranted to disentangle the association of smaller orbital size and susceptibility to POAG at low IOP in Asians. While this association might be causal, it could also be an incidental result of one or more common factors influencing both conditions.

There is reason to suppose that orbital geometry may influence development of glaucoma through an IOP inde-

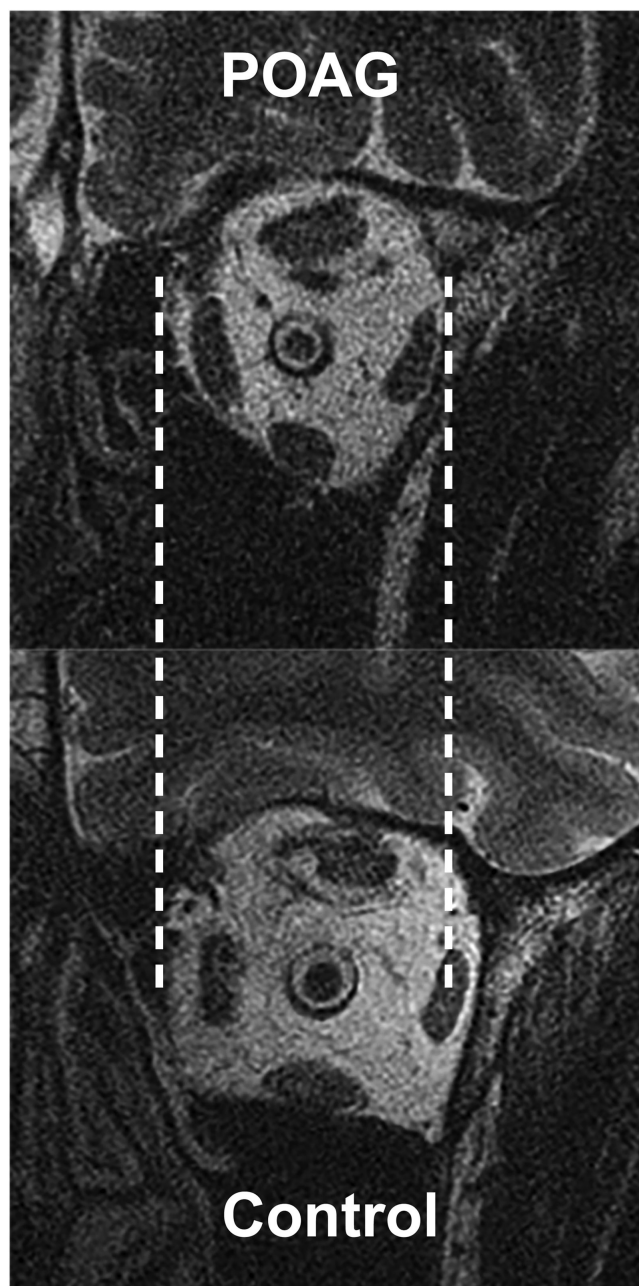


FIGURE 7. Quasicoronal MRI just posterior to the GONJ illustrating that the orbit of a typical patient with POAG is horizontally narrower than that of a representative control.

pendent mechanism. There is evidence that when the globe adducts, the ON becomes tethered, pulls against the GONJ and causes medial translation and retraction of the globe.^{25,27,29,30} Because orbits of subjects with POAG are horizontally narrower and vertically shorter than normal even up to 4 mm anterior to the globe-optic nerve junction, this may restrict mediolateral globe translation, increase globe retraction, and increase tension along the taut ON in adduction. If PGA had actually reduced posterior OFV, this might have ameliorated ON tethering in adduction by allowing the globe to shift posteriorly. However, the present study did not find evidence of any reduction of retrobulbar OFV caused by topical PGA agents. Absence of topical PGA

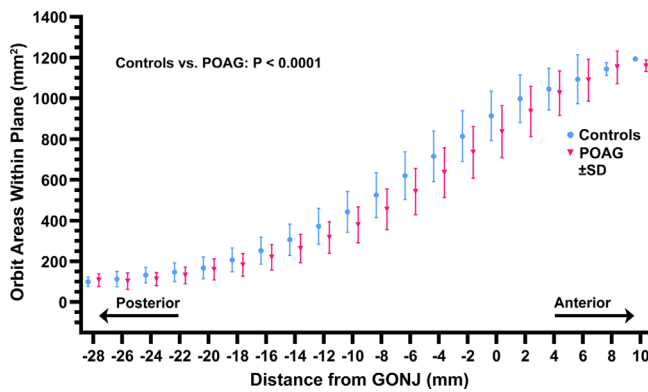


FIGURE 8. Mean cross-sectional area of the orbit along its antero-posterior extent in patients with POAG and controls. Except at the extreme ends of the orbit, cross-sectional area was significantly less in POAG than in controls. Differences between groups were significant at $P < 0.0001$ by ANOVA. SD, standard deviation.

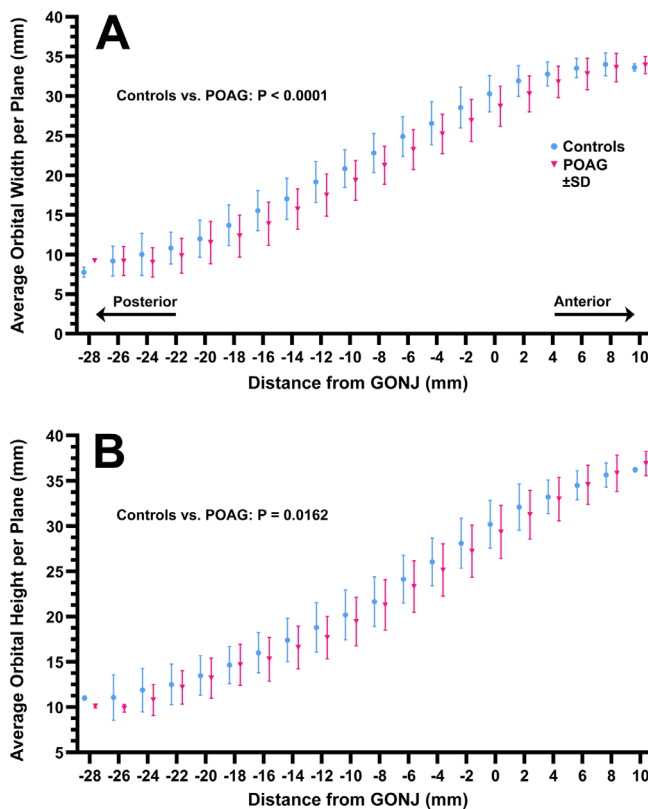


FIGURE 9. Mean orbital dimensions along the anteroposterior extent of the orbit in patients with POAG and controls. (A) Width. (B) Height. Differences between groups were significant at $P < 0.0001$ by ANOVA. SD, standard deviation.

effects on posterior OFV is not surprising in view of the extensive anterior tissue barriers and high vascularity of the orbit that would inhibit penetration of topical agents into the deep orbit. Absence of an effect of PGA agents on anterior orbital fat volume also argues against an effect of these agents on deep bony orbital size.

Not all patients with POAG at normal IOP exhibited a similar degree of orbital narrowing. The distribution of data raises the possibility that apparently lower OV in the POAG group might be attributable to a subgroup of at least

eight orbits of patients with POAG having OV both less than the other patients with POAG and also less than the controls (Fig. 5B). This study took the unbiased approach of including every data observation. The current study was not designed with power to detect possible subgroup effects such as bimodal distribution of OV, so its significance, and the possible effects of outliers generally, cannot be known with certainty. However, even if OV is actually normal in some patients with POAG who do not have elevated IOP, the findings nevertheless argue against any effects of PGA therapy in reduction of posterior OFV in this disease.

Acknowledgments

Disclosure: J.Y. Chen, None; A. Le, None; J. Caprioli, None; J.A. Giaconi, None; K. Nouri-Mahdavi, None; S.K. Law, None; L. Bonelli, None; A.L. Coleman, None; J.L. Demer, None

References

1. Kapetanakis VV, Chan MP, Foster PJ, et al. Global variations and time trends in the prevalence of primary open angle glaucoma (POAG): a systematic review and meta-analysis. *Br J Ophthalmol*. 2016;100:86–93.
2. Kingman S. Glaucoma is second leading cause of blindness globally. *Bull World Health Organ*. 2004;82:887–888.
3. Li T, Lindsley K, Rouse B, et al. Comparative effectiveness of first-line medications for primary open-angle glaucoma: A systematic review and network meta-analysis. *Ophthalmology*. 2016;123:129–140.
4. Wang K, Xu L, Yuan Z, et al. Intraocular pressure-lowering efficacy and safety of bimatoprost 0.03% therapy for primary open-angle glaucoma and ocular hypertension patients in China. *BMC Ophthalmol*. 2014;14:21.
5. Winkler NS, Fautsch MP. Effects of prostaglandin analogues on aqueous humor outflow pathways. *J Ocul Pharmacol Ther*. 2014;30:102–109.
6. Aptel F, Cucherat M, Denis P. Efficacy and tolerability of prostaglandin analogs: a meta-analysis of randomized controlled clinical trials. *J Glaucoma*. 2008;17:667–673.
7. Shrirao N, Khurana M, Mukherjee B. Prostaglandin-associated periorbitopathy. *Indian J Ophthalmol*. 2016;64:459.
8. Peplinski LS, Albani Smith K. Deepening of lid sulcus from topical bimatoprost therapy. *Optom Vis Sci*. 2004;81:574–577.
9. Jayaprakasam A, Ghazi-Nouri S. Periorbital fat atrophy—an unfamiliar side effect of prostaglandin analogues. *Orbit*. 2010;29:357–359.
10. Tappeiner C, Perren B, Iliev ME, et al. [Orbital fat atrophy in glaucoma patients treated with topical bimatoprost—can bimatoprost cause enophthalmos?]. *Klin Monbl Augenheilkd*. 2008;225:443–445.
11. Rabinowitz MP, Katz LJ, Moster MR, et al. Unilateral prostaglandin-associated periorbitopathy: a syndrome involving upper eyelid retraction distinguishable from the aging sunken eyelid. *Ophthalm Plast Reconstr Surg*. 2015;31:373–378.
12. Higashiyama T, Minamikawa T, Kakinoki M, et al. Decreased orbital fat and enophthalmos due to bimatoprost: Quantitative analysis using magnetic resonance imaging. *PLoS One*. 2019;14:e0214065.
13. Chang I, Caprioli J, Ou Y. Surgical management of pediatric glaucoma. *Dev Ophthalmol*. 2017;59:165–178.
14. Zhang X, Liu Y, Wang W, et al. Why does acute primary angle closure happen? Potential risk factors for acute primary angle closure. *Surv Ophthalmol*. 2017;62:635–647.

15. Tan AN, Cornelissen MF, Webers CAB, et al. Outcomes of severe uveitic glaucoma treated with Baerveldt implant: can blindness be prevented? *Acta Ophthalmol.* 2018;96:24–30.
16. Bai HQ, Yao L, Wang DB, et al. Causes and treatments of traumatic secondary glaucoma. *Eur J Ophthalmol.* 2009;19:201–206.
17. Shi D, Funayama T, Mashima Y, et al. Association of HK2 and NCK2 with normal tension glaucoma in the Japanese population. *PLoS One.* 2013;8:e54115.
18. Iwase A, Suzuki Y, Araie M, et al. The prevalence of primary open-angle glaucoma in Japanese: The Tajimi Study. *Ophthalmology.* 2004;111:1641–1648.
19. Ha A, Kim YK, Jeoumg JW, et al. Association of angle width with progression of normal-tension glaucoma. A minimum 7-year follow-up study. *JAMA Ophthalmol.* 2019;137:13–20.
20. Zhao J, Solano MM, Oldenburg CE, et al. Prevalence of normal-tension glaucoma in the Chinese population: a systematic review and meta-analysis. *Am J Ophthalmol.* 2019;199:101–110.
21. Kim CS, Seong GJ, Lee NH, et al. Prevalence of primary open-angle glaucoma in central South Korea. The Namil study. *Ophthalmology.* 2011;118:1024–1030.
22. Sakata R, Yoshitomi T, Iwase A, et al. Factors associated with progression of Japanese open-angle glaucoma with lower normal intraocular pressure. *Ophthalmology.* 2019;126:1107–1116.
23. Kim JA, Kim TW, Lee EJ, et al. Lamina cribrosa morphology in glaucomatous eyes with hemifield defect in a Korean population. *Ophthalmology.* 2019;126:692–701.
24. Killer HE, Pircher A. Normal tension glaucoma: review of current understanding and mechanisms of the pathogenesis. *Eye (Lond).* 2018;32:924–930.
25. Demer JL. Optic nerve sheath as a novel mechanical load on the globe in ocular duction. *Invest Ophthalmol Vis Sci.* 2016;57:1826–1838.
26. Wang X, Fisher LK, Milea D, et al. Predictions of optic nerve traction forces and peripapillary tissue stresses following horizontal eye movements. *Invest Ophthalmol Vis Sci.* 2017;58:2044–2053.
27. Demer JL, Clark RA, Suh SY, et al. Magnetic resonance imaging of optic nerve traction during adduction in primary open-angle glaucoma with normal intraocular pressure. *Invest Ophthalmol Vis Sci.* 2017;58:4114–4125.
28. Shin A, Yoo L, Park C, Demer JL. Finite element biomechanics of optic nerve sheath traction in adduction. *J Biomech Eng.* 2017;139:1010101–10101010. doi:10.1115/1.4037562.
29. Demer JL, Clark RA, Suh SY, et al. Optic nerve traction during adduction in open angle glaucoma with normal versus elevated intraocular pressure. *Curr Eye Res.* 2020;45:199–210.
30. Suh SY, Le A, Shin A, et al. Progressive deformation of the optic nerve head and peripapillary structures by graded horizontal duction. *Invest Ophthalmol Vis Sci.* 2017;58:5015–5021.
31. Wang YX, Jiang R, Wang NL, et al. Acute peripapillary retinal pigment epithelium changes associated with acute intraocular pressure elevation. *Ophthalmology.* 2015;122:2022–2028.
32. Fortune B. Pulling and tugging on the retina: mechanical impact of glaucoma beyond the optic nerve head. *Inv Ophthalmol Vis Sci.* 2019;60:26–35.
33. Laurutis VP, Robinson DA. The vestibulo-ocular reflex during human saccadic eye movements. *J Physiol (Lond).* 1986;373:209–233.
34. Guitton D, Volle M. Gaze control in humans: eye-head coordination during orienting movements to targets within and beyond the oculomotor range. *J Neurophysiol.* 1987;58:427–459.
35. Anastasopoulos D, Zivara N, Hollands M, Bronstein A. Gaze displacement and inter-segmental coordination during large whole body voluntary rotations. *Exp Brain Res.* 2009;193:323–336.
36. Tian JR, Shubayev I, Baloh RW, Demer JL. Impairments in the initial horizontal vestibulo-ocular reflex of older humans. *Exp Brain Res.* 2001;137:309–322.
37. Tian J-R, Crane BT, Ishiyama A, Demer JL. Three dimensional kinematics of rapid compensatory eye movements in humans with unilateral vestibular deafferentation. *Exp Brain Res.* 2007;182:143–155.
38. Crane BT, Tian J, Demer JL. Kinematics of vertical saccades during the yaw vestibulo-ocular reflex in humans. *Invest Ophthalmol Vis Sci.* 2005;46:2800–2809.
39. Demer JL, Dusyanth A. T2 fast spin echo magnetic resonance imaging of extraocular muscles. *JAAPOS.* 2011;15:17–23.
40. Demer JL, Clark RA. Magnetic resonance imaging demonstrates compartmental muscle mechanisms of human vertical fusional vergence. *J Neurophysiol.* 2015;113:2150–2163.
41. Huang J, Huang JY, Chen Y, Ying GS. Evaluation of approaches to analyzing continuous correlated eye data when sample size is small. *Ophthalmic Epidemiol.* 2018;25:45–54.
42. Choi HY, Lee JE, Lee JW, et al. In vitro study of antiadipogenic profile of latanoprost, travoprost, bimatoprost, and tafluprost in human orbital preadipocytes. *J Ocul Pharmacol Ther.* 2012;28:146–152.
43. Taketani Y, Yamagishi R, Fujishiro T, et al. Activation of the prostanoid FP receptor inhibits adipogenesis leading to deepening of the upper eyelid sulcus in prostaglandin-associated periorbitopathy. *Invest Ophthalmol Vis Sci.* 2014;55:1269–1276.
44. Liu AW, Gan LY, Yao X, Zhou J. Long-term assessment of prostaglandin analogs and timolol fixed combinations vs prostaglandin analogs monotherapy. *Int J Ophthalmol.* 2016;9:750–756.
45. Nakakura S, Yamamoto M, Terao E, et al. Prostaglandin-associated periorbitopathy in latanoprost users. *Clin Ophthalmol.* 2015;9:51–56.
46. Yoshino T, Fukuchi T, Togano T, et al. Eyelid and eyelash changes due to prostaglandin analog therapy in unilateral treatment cases. *Jpn J Ophthalmol.* 2013;57:172–178.
47. Karslioglu MZ, Hosal MB, Tekeli O. Periocular changes in topical bimatoprost and latanoprost use. *Turk J Med Sci.* 2015;45:925–930.
48. Ugradar S, Lambros V. Orbital volume increases with age: a computed tomography-based volumetric study. *Ann Plast Surg.* 2019;83:693–696.
49. Ugradar S, Goldberg RA, Rootman DB. Bony orbital volume expansion in thyroid eye disease. *Ophthalmic Plast Reconstr Surg.* 2019;35:434–437.