



Case report

Re-exposure causing rapid onset of vancomycin induced thrombocytopenia

Brent Boodhai*, Aarti Maharaj, Carmina Aybar Rodriguez, Yu Shia Lin

Maimonides Medical Centre, Brooklyn, New York



ARTICLE INFO

Article history:

Received 21 November 2021

Received in revised form 9 January 2022

Accepted 9 January 2022

Available online xxxx

Keywords:

Vancomycin

Vancomycin induced thrombocytopenia

Thrombocytopenia

Re-exposure

Drug rash

Rapid onset

ABSTRACT

Vancomycin is used for the treatment of gram-positive infections. The increasing prevalence of methicillin-resistant *Staphylococcus aureus* since the 1980 s has led to a significant increase in the clinical utility of vancomycin in the United States. The diagnosis of vancomycin induced thrombocytopenia (VIT) poses a challenge since it requires the exclusion of other etiologies of thrombocytopenia, such as infectious or immunologic diseases and alternative drugs. Physicians should be aware that VIT is a rare but important complication of IV vancomycin therapy and failure to recognize this diagnosis may lead to a delay in discontinuation of vancomycin and serious complications

© 2022 Published by Elsevier Ltd.
CC_BY_NC_ND_4.0

Introduction

Vancomycin is used for the treatment of gram-positive infections. The increasing prevalence of methicillin-resistant *Staphylococcus aureus* since the 1980 s has led to a significant increase in the clinical utility of vancomycin in the United States [1]. Vancomycin-induced immune thrombocytopenia (VIT) is a rare adverse event. In this case, we present severe VIT which occurred within 12 h after re-administration of vancomycin.

Case presentation

A case of a 45-year-old female patient with a past medical history of type 2 diabetes mellitus and hypertension re-presented to the Emergency Department after a new onset rash, which developed two days after being discharged. On her initial hospital admission, she presented with headache, photophobia, and fever for four days. Intravenous (IV) vancomycin and ceftriaxone were empirically started on day 1, and a battery of investigations were performed. Lumbar puncture and blood cultures were both negative. However, magnetic resonance imaging of the brain revealed multiple infarcts

suggestive of embolic disease. Transthoracic echocardiogram showed a small filamentous structure on the ventricular aspect of the aortic valve, supportive of a vegetation. She eventually completed 9 days total of IV vancomycin and ceftriaxone for the treatment of infective endocarditis and was discharged on IV ceftriaxone and daptomycin on day 9.

She was readmitted on day 11 for a new onset rash that was generalized, painless, and mostly distributed on the bilateral upper limbs and abdomen. She denied fever and difficulty breathing. Prior to this episode, she disclosed that she had an allergy to non-steroidal anti-inflammatory drugs which manifested as an urticarial rash.

Her blood pressure was 153/98 mm Hg, heart rate was 86 beat per minute, respiratory rate was 16 beat per minute and temperature was 98.6 Fahrenheit. Her cardiovascular and respiratory examinations were unremarkable. There were generalized, serpiginous, non-desquamating, pruritic, blanchable, nontender macules which were distributed most prominently on the upper limbs and abdomen.

The laboratory results showed white blood cell count of 21,000/uL, hemoglobin of 10 mg/dl and platelet of 262,000/uL. Comparatively, the platelet count on prior discharge (day 9) was 207,000/uL. All other investigations were noncontributory. Her initial management included cessation of both antimicrobials, and she was administered first generation antihistamines and corticosteroids. Subcutaneous heparin was also given for thromboprophylaxis. IV vancomycin was reinstated for infective endocarditis on day 12 since she had previously tolerated it well.

* Correspondence to: 4001 New Utrecht Avenue Apartment 3 M, Brooklyn 11219, New York.

E-mail addresses: boodhai123@hotmail.com, bboodhai@maimonidesmed.org (B. Boodhai).

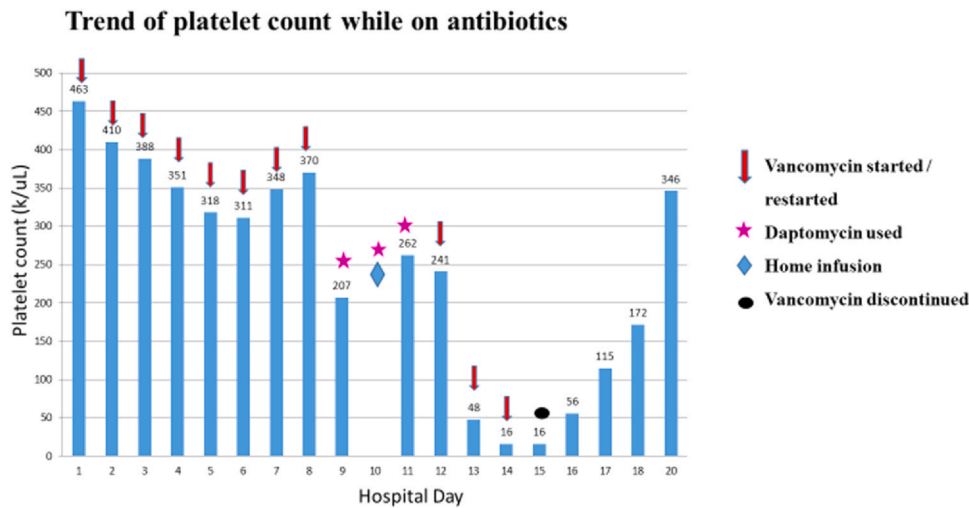


Fig. 1. Trends of platelet count for our patient during her two hospital admissions.

On day 13, she described worsening of the rash with associated decrease in platelet count to 48,000/uL. There was no evidence of bleeding or clinical manifestation of thrombocytopenia. 4 T score was found to be intermediate. Heparin was discontinued on day 14 but the decrease in platelets perpetuated. Platelet value on day 15 was 16,000/uL. Given the chronology of events, vancomycin was thought to be the possible offending agent and was discontinued on day 15.

Intravenous ceftaroline was started as a substitute for continuation of infective endocarditis treatment. The platelet count gradually improved and reached the normal ranges within three days of discontinuation of medications as illustrated by Fig. 1. Heparin induced platelet antibodies resulted as negative. Serum testing for Drug Dependent Platelet Antibodies was sent to Versiti Wisconsin, Inc. which yielded a positive result for vancomycin IgG by flow cytometry only when vancomycin was present and negative results when vancomycin was not present, confirming the diagnosis of vancomycin induced thrombocytopenia (VIT). Vancomycin was then labeled as inciting an adverse drug event for this patient to avoid future catastrophic consequences.

Discussion

Vancomycin is a glycopeptide antibiotic and commonly reported side effects include nephrotoxicity, ototoxicity and red man syndrome. The increasing prevalence of methicillin-resistant Staphylococcus aureus since the 1980s has led to a significant increase in the clinical utility of vancomycin in the United States [1].

While reported as early as 1985, VIT has historically been documented as a lesser-known side effect and the true incidence is unknown. A cross-sectional retrospective study of vancomycin use and its adverse reactions showed the occurrence of thrombocytopenia in patients being treated with vancomycin to be 7.1% [2]. Although the pathogenesis of VIT is not well understood, it is postulated that vancomycin binds to platelet glycoproteins (most frequently GPIIb/IIIa receptor) and induces the generation of antibodies which attach to the drug-platelet complex causing cell lysis [3].

38 cases of VIT were reported from 1985 to 2020, with 24 cases (63.2%) occurring in male patients while 14 cases (36.8%) occurred in females [4]. The onset of VIT has been reported to be between 7 and 10 days after the introduction of the drug. There were only a few cases described of VIT occurring within 24 h of administration of the drug if the patient was previously sensitized [5]. In this case report, our patient was treated with intravenous vancomycin for 9 days without any adverse reaction on initial admission. After restarting IV vancomycin on day 12, she suddenly developed severe

thrombocytopenia within 12 h with a drop of platelets from 241,000/uL to 48,000/uL. Her nadir platelet count was 16,000/uL which occurred three days after the re-introduction of vancomycin.

Bleeding in the setting of VIT can range from mild petechial hemorrhage to catastrophic life-threatening bleeding. In one literature review of 29 cases of confirmed VIT, 7 patients experienced mild to moderate bleeding described as petechiae or ecchymoses while other 7 patients were noted to have severe bleeding, including one case with profound hematuria leading to hemodynamic instability [6,7].

The diagnosis of VIT poses a challenge since it requires the exclusion of other etiologies of thrombocytopenia, such as infectious or immunologic diseases and alternative drugs. Particularly in our patient, she received multiple medications, including heparin, ceftriaxone and daptomycin prior to thrombocytopenia. Since she had recent exposure to heparin during her prior admission, with an intermediate 4T score, the decision was made to stop heparin while pending HIT antibody results. Despite discontinuation of daptomycin, ceftriaxone and heparin, a perpetual decline of platelet count led to the suspicion of VIT, and IV vancomycin was discontinued immediately.

One of the key aspects in managing VIT is having high clinical acumen that vancomycin may be the culprit amongst many other factors that can cause thrombocytopenia. The average latency for suspecting vancomycin in about 50% of patients as the cause of thrombocytopenia can range between 1 and 14 days [3]. Once VIT is suspected, it should be promptly discontinued and alternatives for treatment should be sought. Drug-dependent platelet antibodies should be sent to the laboratory or a medically supervised re-challenge with vancomycin can be attempted once thrombocytopenia has resolved in order to confirm a diagnosis [8].

In addition to discontinuation of IV vancomycin, platelet transfusions should be considered if the patients have bleeding complications from thrombocytopenia. Some research has shown that platelet transfusions are only helpful if vancomycin has already been withdrawn [9]. Intravenous corticosteroids, intravenous immunoglobulin, and rituximab have also been utilized in the management of VIT once vancomycin has been stopped [4].

Some cases of thrombocytopenia can take up to 5–7.5 days to resolve after the cessation of vancomycin [3,6]. Patients who have renal insufficiency may have prolonged courses with up to 32 days of thrombocytopenia given the decreased rate of clearance. In these patients, hemodialysis can be considered if there are worsening of symptoms in order to eliminate vancomycin from the blood [10]. Once vancomycin was held on day 15 in this case, the platelet count returned to the normal range on day 18.

In conclusion, physicians should be aware that VIT is a rare but important complication of IV vancomycin therapy, and is often difficult to diagnose in critically ill patients, since there is often more than one possible cause of thrombocytopenia. Our case highlights the importance of including VIT in the differential diagnosis of thrombocytopenia in patients with current or recent use of IV vancomycin. Failure to consider VIT may have led to a delay in discontinuation of vancomycin and serious complications. Furthermore, it is equally critical to avoid administering vancomycin to these patients with previous history of VIT, because of indefinite persistence of drug sensitivity [3].

Funding

This article was funded by the authors listed in the manuscript.

Disclosure

Yu Shia Lin, Brent Boodhai, Aarti Maharaj, Carmina Aybar Rodriguez have nothing to disclose.

CRedit authorship contribution statement

All authors take full responsibility for the integrity of the work as a whole and contributed equally in writing the manuscript. All authors read and endorsed the final manuscript.

References

- [1] Levine DP. Vancomycin: a history. *Clin Infect Dis Publ Infect Dis Soc Am* 2006;42(Suppl 1):S5–12. <https://doi.org/10.1086/491709>
- [2] Marinho D, Huf G, Ferreira B, Castro H, Rodrigues C, Sousa V, et al. The study of vancomycin use and its adverse reactions associated to patients of a brazilian university hospital. *BMC Res Notes* 2011;4(1):236. <https://doi.org/10.1186/1756-0500-4-236>
- [3] Von Drygalski A, Curtis BR, Bougie DW, McFarland JG, Ahl S, Limbu I, et al. Vancomycin-induced immune thrombocytopenia. *New Engl J Med* 2007;356(9). <https://doi.org/10.1056/NEJMoa065066>
- [4] Guleng SR, Wu RH, Guo XB. Vancomycin-induced thrombocytopenia in endocarditis: a case report and review of literature. *World J Clin Cases* 2021;9(7):1696–704. <https://doi.org/10.12998/wjcc.v9.i7.1696>
- [5] Getz TM, Packer CD. Rapid-onset vancomycin-induced thrombocytopenia with reexposure. *Annu Pharm* 2019;53(12):1259–61. <https://doi.org/10.1177/1060028019867433>
- [6] Mohammadi M, Jahangard-Rafsanjani Z, Sarayani A, Hadjibabaei M, Taghizadeh-Ghehi M. Vancomycin-induced thrombocytopenia: a narrative review. *Drug Saf* 2017;40(1):49–59. <https://doi.org/10.1007/s40264-016-0469-y>
- [7] Lobo N, Ejiofor K, Thurairaja R, Khan MS. Life-threatening haematuria caused by vancomycin-induced thrombocytopenia. *Case Rep* 2015;bcr2014208192.
- [8] Arnold DM, Nazi I, Warkentin TE, Smith JW, Toltl LJ, George JN, et al. Approach to the diagnosis and management of drug-induced immune thrombocytopenia. *Transfus Med Rev* 2013;27(3). <https://doi.org/10.1016/j.tmr.2013.05.005>
- [9] Yamanouchi J, Hato T, Shiraishi S, Takeuchi K, Yakushijin Y, Yasukawa M. Vancomycin-induced immune thrombocytopenia proven by the detection of vancomycin-dependent anti-platelet antibody with flow cytometry. *Intern Med* 2016;55(20):3035–8. <https://doi.org/10.2169/internalmedicine.55.6902>
- [10] Ajit NE, Devarashetty SP, Master S. Vancomycin induced thrombocytopenia - protracted course in a hemodialysis patient. *Case Rep Oncol* 2019;12(3):749–54. <https://doi.org/10.1159/000503418>