



Received: 2016.08.09
Accepted: 2016.08.23
Published: 2017.04.04

Authors' Contribution:

- A** Study Design
- B** Data Collection
- C** Statistical Analysis
- D** Data Interpretation
- E** Manuscript Preparation
- F** Literature Search
- G** Funds Collection

Caudal Regression Syndrome: A Case Series of a Rare Congenital Anomaly

Yogesh Kumar¹✉, Nishant Gupta²✉, Kusum Hooda¹✉✉, Pranav Sharma¹✉, Salil Sharma¹✉, Puneet Kochar¹✉, Daichi Hayashi¹✉✉

¹ Department of Diagnostic Radiology, Yale New Haven Health System at Bridgeport Hospital, Bridgeport, CT, U.S.A.
² Department of Diagnostic Radiology, St. Vincent Medical Center, Bridgeport, CT, U.S.A.

Author's address: Yogesh Kumar, Clinical Assistant Provisional, Diagnostic Radiology, Yale New Haven Health System at Bridgeport Hospital, 267 Grant Street, Bridgeport, CT, U.S.A., e-mail: yogeshkumar102@gmail.com

Summary

Background:

Caudal regression syndrome is a rare, neural tube defect characterized by an abnormal development of the caudal aspect of the vertebral column and the spinal cord. It results in neurological deficits ranging from bladder and bowel involvement to severe sensory and motor deficits in the lower limbs. Maternal diabetes, genetic factors and some teratogens have been shown to be associated with its pathogenesis. Caudal regression syndrome is usually diagnosed initially by antenatal ultrasound with more definitive diagnosis made by antenatal or postnatal MRI. In this case series, we report four cases of caudal regression syndrome in different age groups including prenatal, infant and adult.

Case Report:

We are presenting multimodal imaging findings of 4 cases of caudal regression syndrome in 4 different age groups including fetus, infant, early childhood and adult. The pathogenesis, associated risk factors, complications, treatment options and prognosis of caudal regression syndrome are discussed as well.

Conclusions:

Caudal regression syndrome is a rare entity, characterized by sacroccocygeal dysgenesis with an abrupt termination of a blunt-ending spinal cord. Ultrasound and fetal MRI can be used to make a prenatal diagnosis, while MRI is the imaging modality of choice in adults. Early detection and prompt treatment is very important to decrease the risk of complications, and thus, to improve the prognosis.

MeSH Keywords:

Congenital Abnormalities • Magnetic Resonance Imaging • Spinal Cord

PDF file:

<http://www.polradiol.com/abstract/index/idArt/900971>

Background

Caudal regression syndrome is a rare congenital abnormality resulting from a developmental failure of a segment of the vertebral column and spinal cord. The function of the residual spinal cord is inversely related to the severity of the morphologic derangement. The majority of cases are sporadic, although there is evidence for a partial genetic contribution. Maternal hyperglycemia is the most important recognized teratogen. Caudal regression syndrome occurs in up to 1% of pregnancies of diabetic mothers with up to 22% of cases associated with Type I or Type II maternal diabetes mellitus (DM). Severe forms can cause early neonatal death due to cardiac, renal and respiratory

problems. Prenatal ultrasound and fetal MRI can be used for antenatal diagnosis, while radiographs and MRI of the vertebral column are imaging modalities used in children and adults.

Case Reports

Case 1

A 30-year-old woman with a long-standing history of lower extremity weakness and paresthesia as well as urinary incontinence presented with worsening back pain. The patient underwent MRI which demonstrated an abrupt termination of the spinal cord at the T12 level,

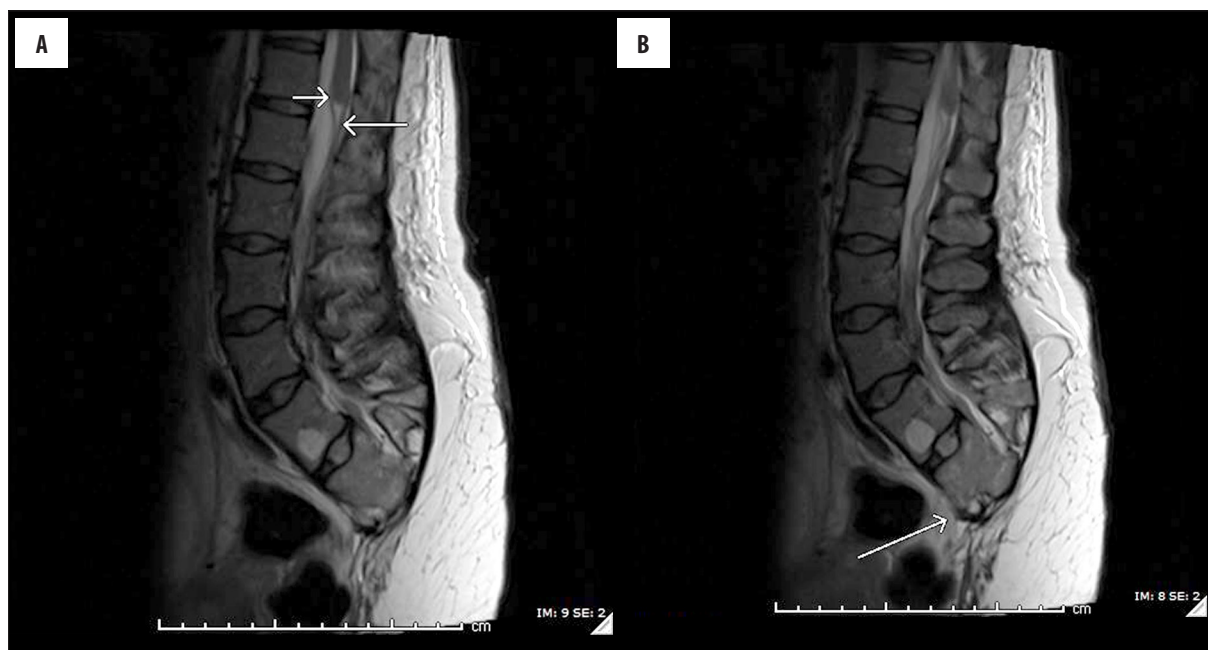


Figure 1. (A) Sagittal T2-weighted MR image in a 30-year-old woman shows a high and abrupt termination of the spinal cord with a blunt-ending conus medullaris (smaller arrow), and double-bundle arrangement of the nerve roots (larger arrow). (B) Sagittal T2-weighted MR image in a 30-year-old woman shows absent S3–5 and coccygeal segments with dysplastic S1 and S2 (arrow).

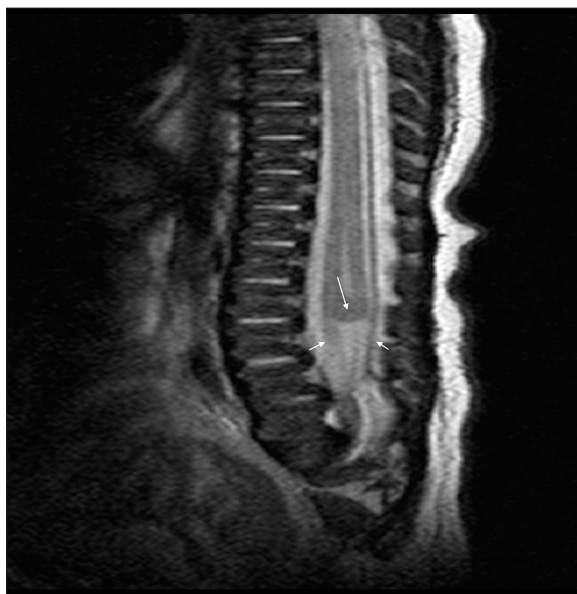

Figure 2. MRI of the lumbar vertebral column in a 10-month-old male infant revealed sacrococcygeal hypoplasia with a blunt-ending, club-shaped conus medullaris (larger arrow) with double-bundle arrangement of the nerve roots (smaller arrows)

with a blunt-ending and club-shaped conus medullaris. Cauda equina nerve roots had a double-bundle arrangement (Figure 1A). Sacrococcygeal hypoplasia, including the absent S3–5 and coccygeal segments with dysplastic S1 and S2, was also noted (Figure 1B). The visualized portion of the spinal cord was unremarkable. Based on these classic imaging findings, the diagnosis of caudal regression syndrome was made.

Case 2

A 10-month-old male infant presented with dribbling of urine since birth. A conventional radiograph of the vertebral column showed partial sacral agenesis. MRI of the vertebral column (Figure 2) revealed sacrococcygeal hypoplasia with a blunt-ending, club-shaped conus medullaris terminating at the L1 vertebral level. The caudal nerve roots were arranged in anterior and posterior bundles. No associated syrinx was seen. The imaging findings were characteristic of caudal regression syndrome.

Case 3

A 4-year-old-boy, born to a diabetic mother, presented to the neurosurgery department with urinary incontinence since birth. A plain radiograph of the lumbosacral spine revealed hypoplastic sacrococcygeal elements (Figure 3A). MRI of the lumbosacral vertebral column revealed an abruptly and high-ending conus suggestive of caudal regression syndrome (Figure 3B–3D). The associated anomalies included bilateral grade V vesicoureteric reflux and situs inversus totalis (Figure 3E, 3F). The patient is being followed conservatively with clean intermittent urinary catheterization and tap water enemas.

Case 4

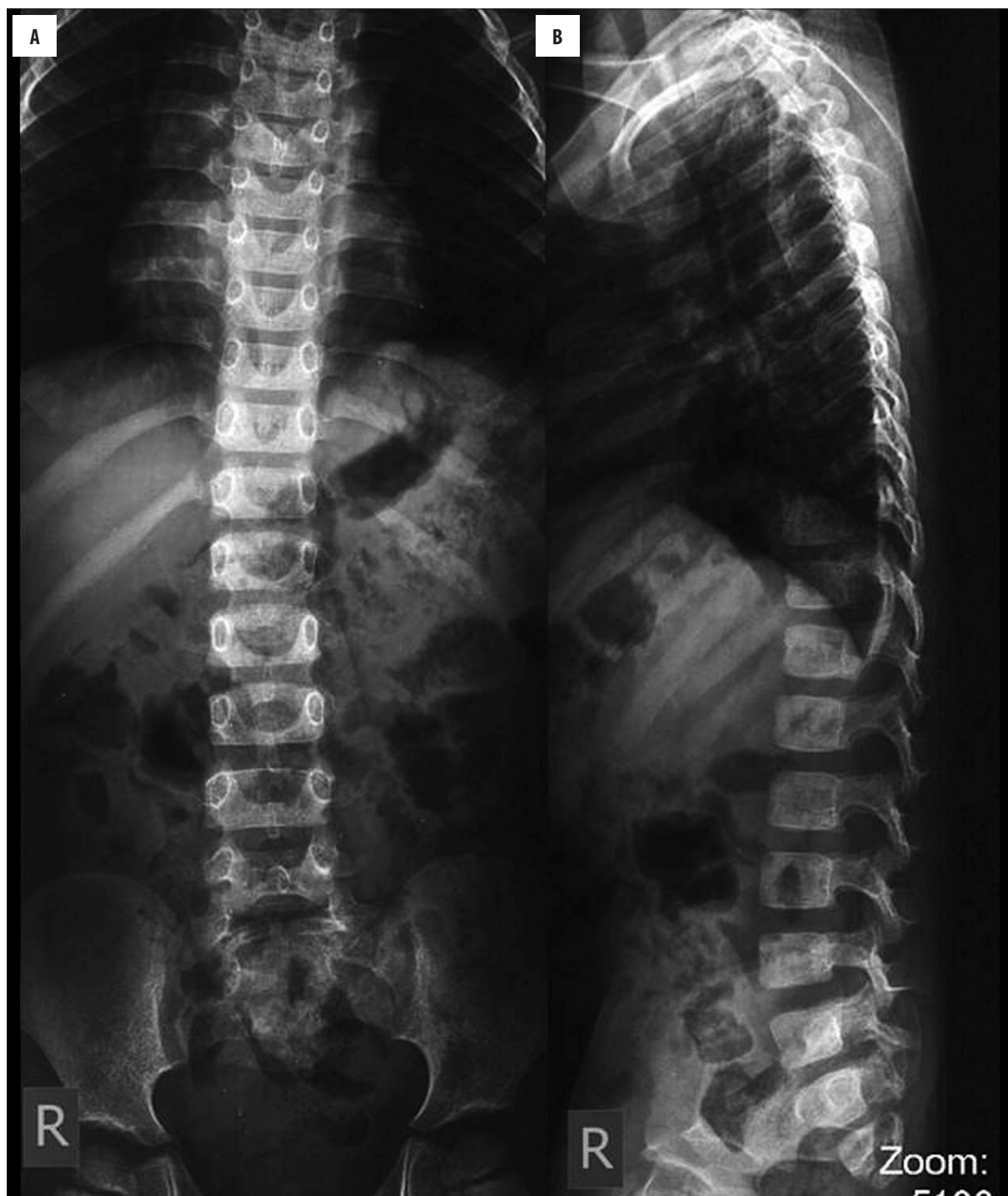A 26-year-old primigravid woman with gestational diabetes, first seen at 21 weeks of gestation, underwent an ultrasound examination which showed a singleton fetus with sacral agenesis and blunt-ending, club-shaped conus (Figure 4). MRI of the fetus, performed to look for any other abnormalities, confirmed the diagnosis of caudal regression syndrome.

Discussion

Caudal regression syndrome results from an abnormal development of the caudal aspect of the spinal cord and vertebral column. Although its precise etiology is not known, toxic, ischemic or infectious etiologies before the 4th week of gestation are thought to be associated with this syndrome [1]. The majority of cases are sporadic, although there is evidence for a partial genetic contribution. There is an association with maternal diabetes, and adequate control of diabetes before conception and during the first

few weeks of gestation is associated with decreased incidence of this syndrome [2]. Clinically, patients present with a wide spectrum of symptoms ranging from mild motor and sensory deficits in the lower extremities to neurogenic bladder, fecal incontinence and vesicoureteric reflux. Progressive neurological symptoms suggest tethering of the spinal cord located below the L1 level [3].

Diagnosis can usually be made in the 2nd or 3rd trimester with prenatal ultrasound, which demonstrates sacroccygeal dysgenesis with a high and abrupt termination of the



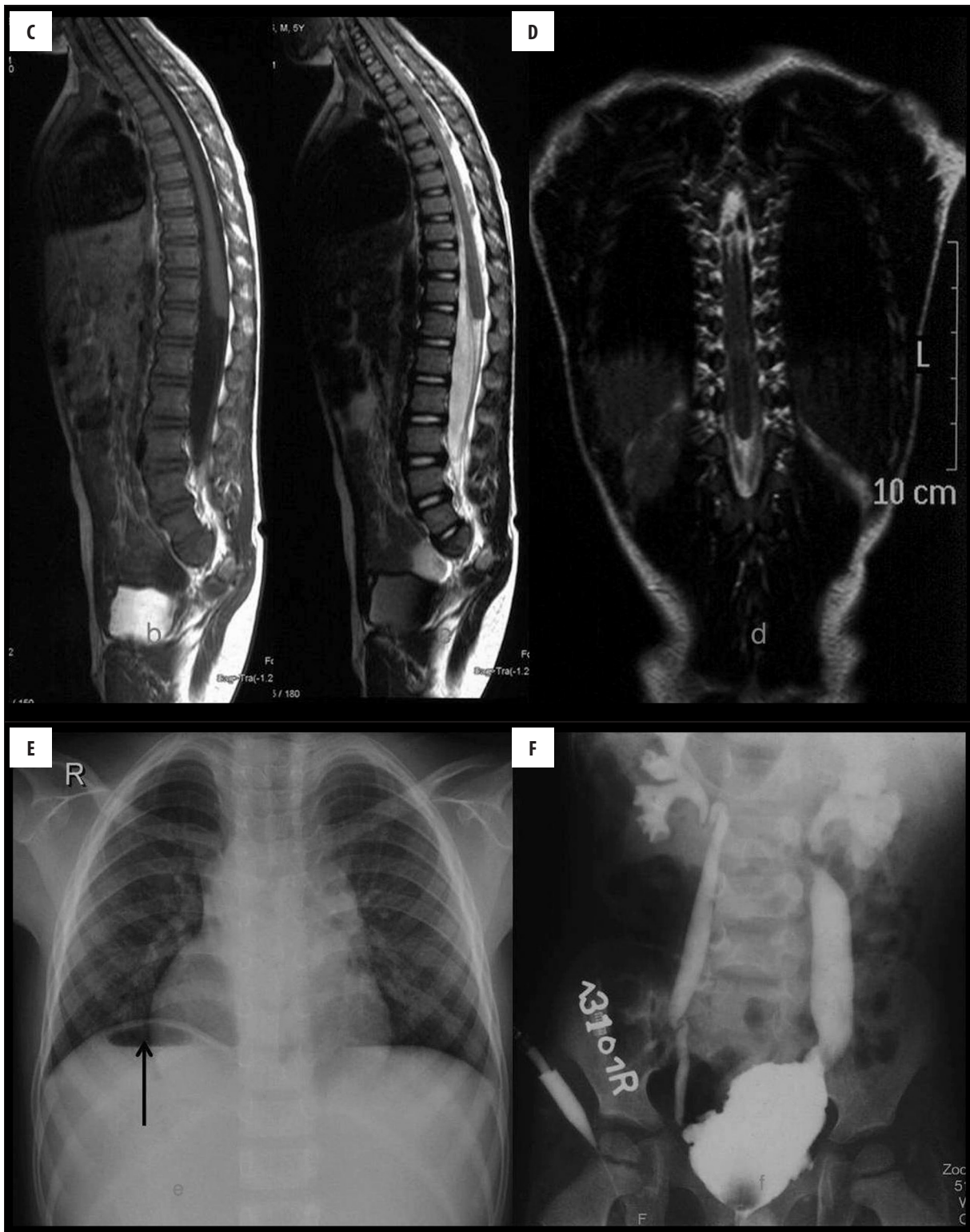


Figure 3. (A) Radiograph of the LS vertebral column of a 4-year-old boy revealed hypoplastic sacrococcygeal elements. (B) MRI of the LS vertebral column – (B, D) – T1W Sagittal and T2W coronal images showing a round conus with an abrupt and high termination (arrowhead). (C) The nerve roots can be followed caudally as a dual-bundle pattern (arrows). Note the hypoplasia of sacrum. (E) Chest radiograph showing dextrocardia with right-sided gastric air-fluid level (arrow) suggestive of situs inversus totalis. (F) Micturating cystourethrogram showing bilateral grade V VUR.

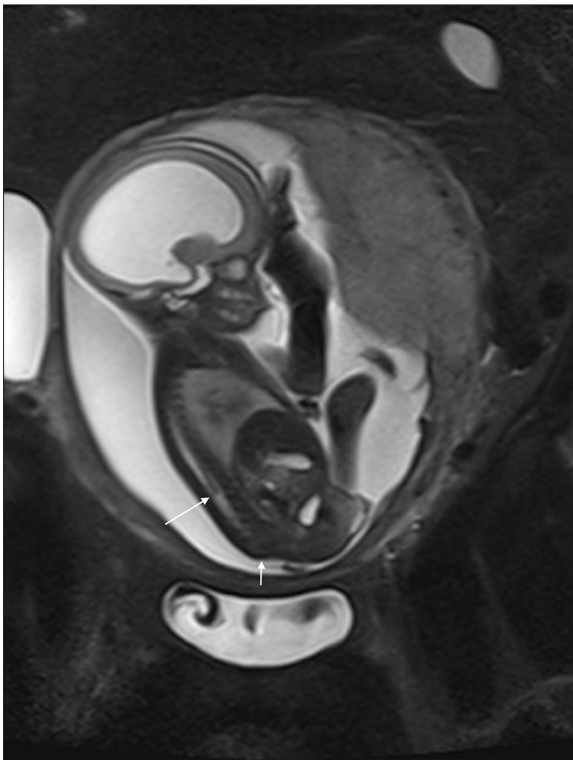


Figure 4. Fetal MRI of a 26-year-old primigravid woman with gestational diabetes shows sacral agenesis (smaller arrow) and a blunt-ending, club-shaped conus (larger arrow).

spinal cord with blunt-ending conus medullaris. Ultrasound is also helpful in evaluating other associated anomalies such as renal anomalies including agenesis, cystic dysplasia and caliectasis, and gastrointestinal anomalies such as duodenal atresia [4]. Fetal MRI can also be used to make the diagnosis in difficult cases [5]. Due to incomplete penetration of the ultrasound caused by ossified vertebrae, MRI is the imaging modality of choice for the diagnosis of any type of vertebral and spinal cord pathologies in adults [6]. This is also true for caudal regression syndrome, in which MRI demonstrates findings as described above [3]. Additionally, MRI is also helpful in demonstrating the double-bundle arrangement of nerve roots. MR neurography is a helpful tool in the evaluation of the nerve root abnormalities [7].

References:

- Adra A, Cordero D, Mejides A et al: Caudal regression syndrome: Etiopathogenesis, prenatal diagnosis, and perinatal management. *Obstet Gynecol Surv*, 1994; 49(7): 508-16
- Chen CP, Chen CY, Lin CY et al: Prenatal diagnosis of concomitant alobar holoprosencephaly and caudal regression syndrome associated with maternal diabetes. *Prenat Diagn*, 2005; 25(3): 264-66
- Tortori-Donati P, Fondelli MP, Rossi A et al: Segmental spinal dysgenesis: Neuro-radiologic findings with clinical and embryologic correlation. *Am J Neuroradiol*, 1999; 20: 445-56
- Stroustrup Smith A, Grable I, Levine D: Caudal regression syndrome in the fetus of a diabetic mother. *Radiology*, 2004; 230(1): 229-33
- Whitby E, Wright P: Non-central nervous system fetal magnetic resonance imaging. *Semin Fetal Neonatal Med*, 2015; 20(3): 130-37
- Kumar Y, Hayashi D: Role of magnetic resonance imaging in acute spinal trauma: A pictorial review. *BMC Musculoskelet Disord*, 2016; 17(1): 310
- Kumar Y, Wadhwa V, Phillips L et al: MR imaging of skeletal muscle signal alterations: Systematic approach to evaluation. *Eur J Radiol*, 2016; 85(5): 922-35
- Pierson M, Faulon M, Vigneron J, Leheup B: Genetic counseling and the caudal regression syndrome. *J Genet Hum*, 1985; 33(5): 405-18
- Moritoki Y, Kojima Y, Kamisawa H et al: Neuropathic bladder caused by caudal regression syndrome without any other neurogenic symptoms. *Case Rep Med*, 2012; 2012: 982418
- Guidera KJ, Raney E, Ogden JA et al: Caudal regression: A review of seven cases, including the mermaid syndrome. *J Pediatr Orthop*, 1991; 11(6): 743-47
- Twickler D, Budorick N, Pretorius D et al: Caudal regression versus sirenomelia: sonographic clues. *J Ultrasound Med*, 1993; 12: 323-30

Prenatal diagnosis is important so that appropriate patient counseling can be provided and postnatal interventions performed [8]. The treatment depends upon clinical symptoms, including the degree of neurological deficits. The main goals of treatment include maintaining and improving renal, cardiac, pulmonary and GI function, preventing renal infection and achieving continence. Urinary incontinence is treated with anticholinergic agents, which decreases the detrusor muscle tone, increases the bladder capacity, and thus decreases intravesicular pressure and urinary frequency [9]. Orthopedic intervention is necessary to correct the associated malformations. Physical therapy can help to prevent secondary deformities, skin ulcers and assists in improving quality of life. Surviving infants usually have normal mental function but do require extensive urologic and orthopedic assistance. Their long-term morbidity consists mostly of a neurogenic bladder dysfunction resulting in progressive renal damage and disabling neuromuscular deficits of the lower extremities [10].

The main differential diagnosis of caudal regression syndrome is sirenomelia [11]. However, sirenomelia usually is characterized by a more pronounced caudal dysgenesis with fused lower extremities. The presence of abnormally small abdominal aorta, two-vessel umbilical cord, and renal agenesis or severe dysgenesis with accompanying severe oligohydramnios and pulmonary hypoplasia in sirenomelia makes it more severe and fatal [11].

Conclusions

Caudal regression syndrome is a rare entity with a known association with maternal diabetes. It is characterized by sacrococcygeal dysgenesis with an abrupt termination of a blunt-ending spinal cord. Ultrasound and fetal MRI can be used to make prenatal diagnosis, while MRI is the imaging modality of choice in adults. Early detection and prompt treatment is very important to decrease the risk of urinary incontinence, recurrent urinary tract infections, renal impairment, and the development of a neuropathic bladder, and thus, to improve the prognosis.

Conflicts of interests

None.