



Case report

Pseudoaneurysm of brachiocephalic artery mimicking the mediastinal tumor

Skaidrius Miliauskas^{a,*}, Rimantas Benetis^b, Marius Zemaitis^a, Jurgita Zaveckiene^c,
Raimundas Sakalauskas^a

^a Department of Pulmonology and Immunology, Lithuanian University of Health Sciences, Eivieniai 2, LT-50009 Kaunas, Lithuania

^b Department of Heart, Thoracic and Vascular Surgery, Lithuanian University of Health Sciences, Eivieniai 2, LT-50009 Kaunas, Lithuania

^c Department of Radiology, Lithuanian University of Health Sciences, Eivieniai 2, LT-50009 Kaunas, Lithuania

ARTICLE INFO

Article history:

Received 14 June 2012

Accepted 1 August 2012

Keywords:

Mediastinal tumor

Pseudoaneurysm

Endobronchial ultrasound

ABSTRACT

58 year-old male admitted to the Hospital of Lithuanian University of Health Sciences due to suspicion of mediastinal tumor for diagnostic endobronchial ultrasound procedure (EBUS). The main patient's complain was progressive dyspnea. Objective investigation revealed no major findings: normal breath sounds, heart rate – 96 bpm, blood pressure – 120/80 mmHg. Chest CT scan showed the mediastinal tumor of 3.8 × 3.5 cm. During bronchoscopy smooth intratracheal nodule of 5 mm was found. Superficial biopsy showed normal airway mucosa. During EBUS procedure no clear lymph node structure or blood flow was detected. It was decided to observe the patient clinically. One month later massive hemoptysis started. Urgent bronchoscopy revealed large right-sided mass and intratracheal wall dislocation due to the possible mediastinal tumor in the same location as the polyp in the previous investigation. Repeated chest CT scan showed increasing tumor of size 4.0 × 3.2 × 4.0 cm in the mediastinum and pseudoaneurysm of brachiocephalic artery was suspected. The diagnosis was later confirmed by aortography. The patient underwent successful aneurysmectomy.

© 2012 Elsevier Ltd. All rights reserved.

1. Introduction

Aneurysm and pseudoaneurysm of brachiocephalic artery are extremely rare conditions. Traumatic injuries can be the cause of it. The symptoms are usually nonspecific. The disease must be timely and properly diagnosed and treated in order to avoid the fatal end.

2. Case report

58 year-old male admitted to the Hospital of Lithuanian University of Health Sciences due to suspicion of mediastinal tumor for diagnostic endobronchial ultrasound procedure (EBUS) in July of 2010. Mediastinal tumor of 3.8 × 3.5 cm was found during chest CT scan one year before in June of 2009. Mediastinoscopy was suggested for diagnosis but not completed due to the cardiovascular problems (low ejection fraction of the left ventricle – 10%). The patient has been suffering from dilative cardiomyopathy and chronic atrial fibrillation and has been treated with warfarin for three years. The patient used to work as sport trainer, had several

chest traumas and surgery due to punctured wound of chest wall 30 years ago.

The status of patient gradually deteriorated during one year before admission. The main patient's complain was progressive dyspnea. Objective investigation revealed no major findings: normal breath sounds, heart rate – 96 bpm, blood pressure – 120/80 mmHg.

Chest CT scan in July 2010 showed the mediastinal tumor of the same size. During bronchoscopy at the time of admission smooth intratracheal nodule of 5 mm was found (Fig. 1). Superficial biopsy of polypoid nodule was performed with subsequent answer – normal airway mucosa. EBUS procedure was done. No clear lymph node structure or blood flow was detected. Although preliminary diagnosis was mediastinal tumor, the vascular malformation couldn't be ruled out. One month later massive hemoptysis started. Urgent bronchoscopy revealed large right-sided mass and intratracheal wall dislocation due to the possible mediastinal tumor in the same location as the polyp in the first image (Fig. 2). Repeated chest CT scan (Fig. 3a–c) on August 2010 showed increasing tumor of size 4.0 × 3.2 × 4.0 cm in the mediastinum and pseudoaneurysm of brachiocephalic artery was suspected. The diagnosis was later confirmed by aortography (Fig. 4). The patient underwent successful aneurysmectomy.

* Corresponding author. Tel.: +370 37326457, +370 68627857 (mob).
E-mail address: Skaidrius.miliauskas@kaunoklinikos.lt (S. Miliauskas).

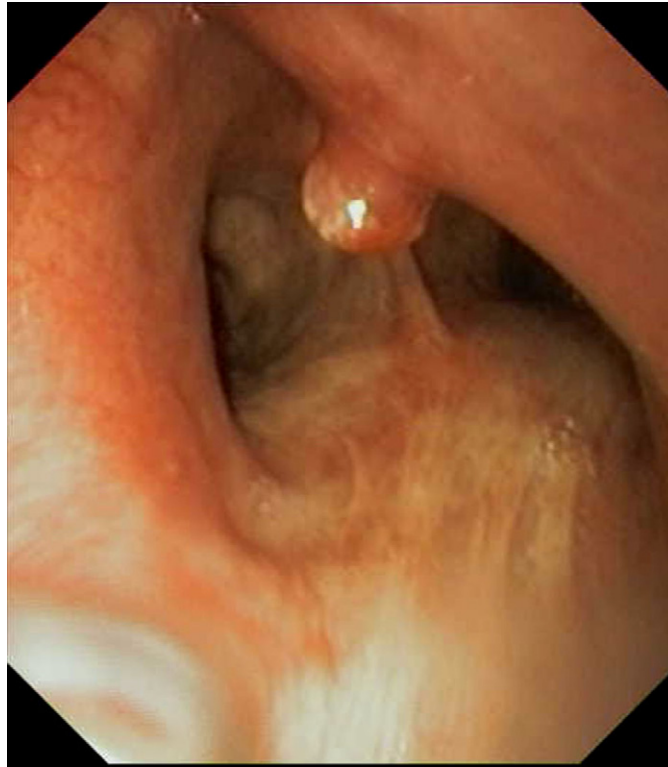


Fig. 1. Endobronchial mass (polypoid nodule) in the right wall of the trachea during primary admission.

3. Discussion

Aneurysm of brachiocephalic artery is a rare disease and could be caused by variety of diseases.^{1,4} Pseudoaneurysm of brachiocephalic artery is much more rare condition and traumatic injuries are the most frequent cause of this pathology.² Although thoracic arterial injury from blunt trauma most commonly occurs at the aortic isthmus, about 10% of these occur in the brachiocephalic artery.³ Occasionally aneurysms in this location can cause

respiratory symptoms including dyspnea and hemoptysis.⁵ Symptoms caused by this condition are nonspecific and are usually interpreted by the physicians as the result of other underlying disease. Progressive dyspnea in our presented case was always treated as the sign of progressive heart failure due to the cardiomyopathy. Old trauma was not taken in the account. Only repeated CT scan suggested final diagnosis. We think that in this case underlying pseudoaneurysm of brachiocephalic artery due to chest trauma progressed and enlarged quickly after bronchoscopic

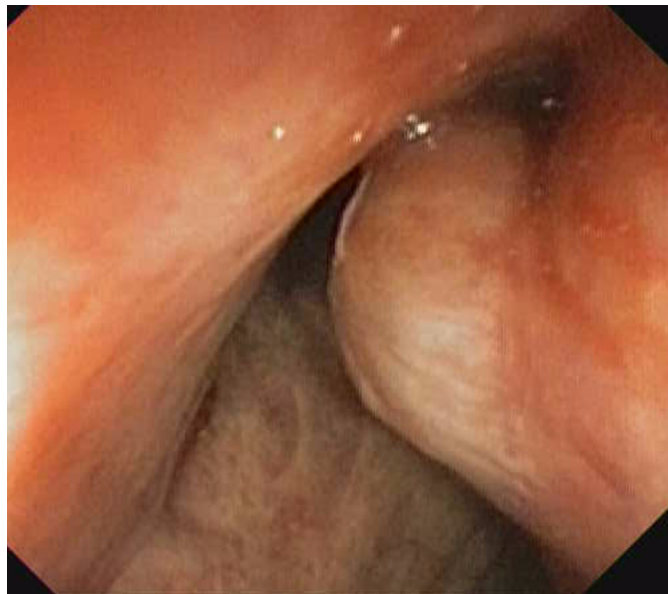


Fig. 2. Large endobronchial mass dislocating right wall of the trachea one month later.

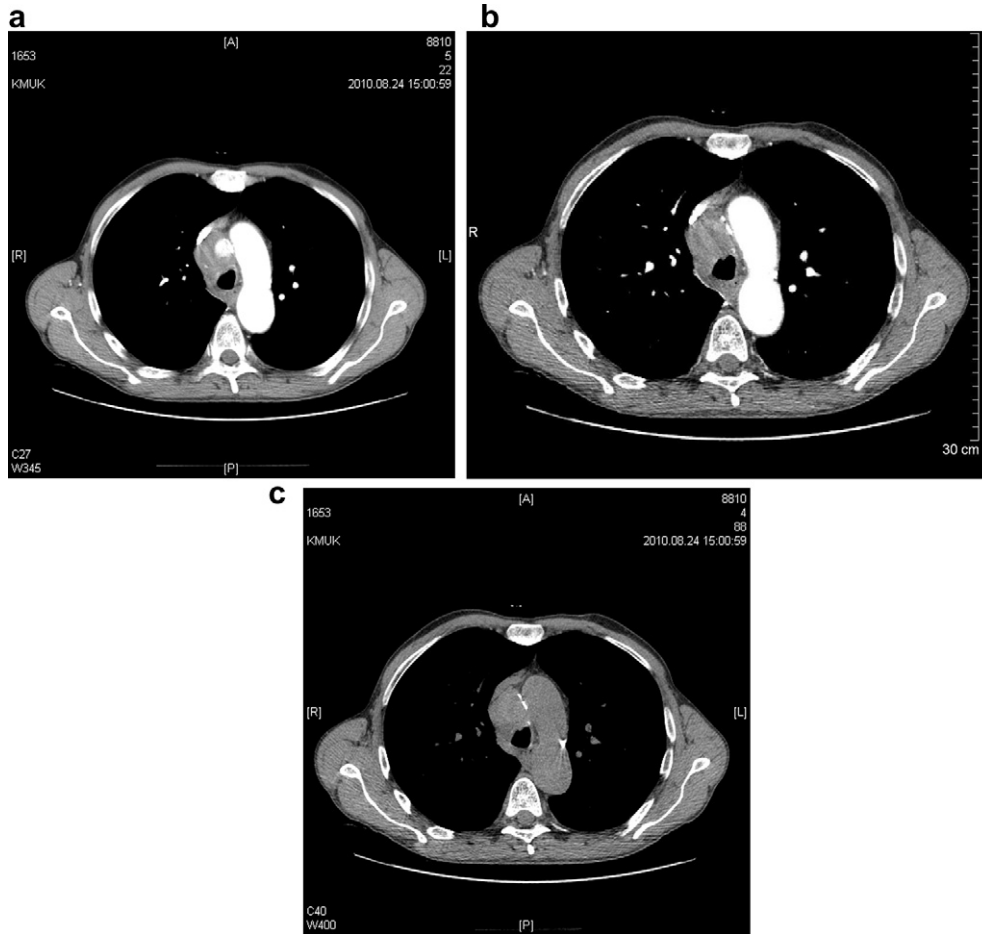


Fig. 3. (a, b, c). Computed tomography scan (a and b with contrast, c without contrast, mediastinal window) showing pseudoaneurysm of brachiocephalic artery with intratracheal mass during repeated investigation when massive hemoptysis occurred (compatible with CT scan in Fig. 2).

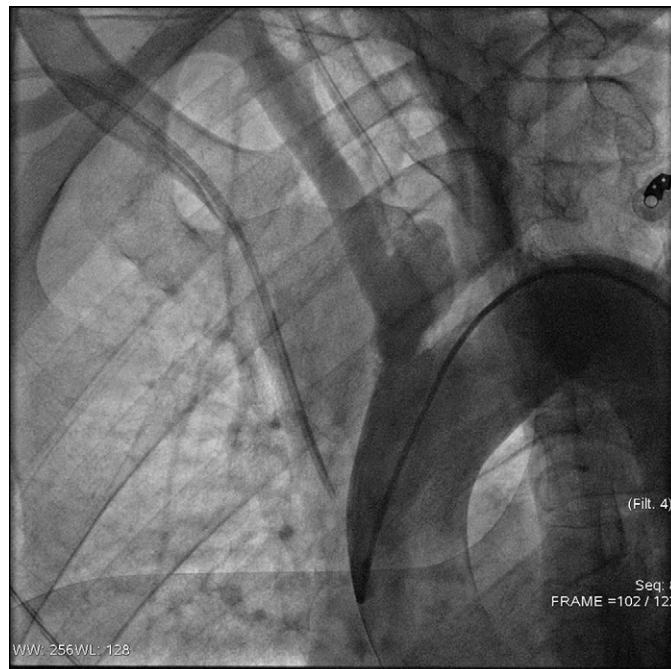


Fig. 4. Aortography showing pseudoaneurysm of brachiocephalic artery.

superficial biopsy and EBUS procedure. Careful radiological (especially CT scan) evaluation is mandatory before any diagnostic interventional procedure when chest tumor is suspected.

The authors state no conflict of interest.

References

1. Kieffer E, Chieche L, Koskas F, Bahnini A. Aneurysms of the innominate artery: surgical treatment of 27 patients. *J Vasc Surg* 2001;**34**:222–8.
2. Okubo K, Isobe J, Kitamura J, Ueno Y. Mediastinitis and pseudoaneurysm of brachiocephalic artery long after the resection of invasive thymoma and post-operative irradiation. *J Thorac Cardiovasc Surg* 2005;**130**:918–9.
3. Mattox KL, Feliciano DV, Burch J, Beall Jr AC, Jordan Jr GL, De Bakey ME. Five thousand seven hundred sixty cardiovascular injuries in 4459 patients. *Ann Surg* 1989;**209**:698–707.
4. Reddi A, Munasur M, Naidoo R, Steer D. Traumatic innominate artery aneurysm 26 years after stab injury. *Ann Thorac Surg* 2005;**79**:1034–6.
5. Sakamoto H, Hattori T, Watanabe Y, Sakakibara Y. Chronic post-traumatic pseudoaneurysm of the brachiocephalic artery with tracheal obstruction resulting in repeated pneumonia. *Ann Thorac Surg* 2006;**82**:1101–3.