

## REVIEW ARTICLE

## Examining perinatal subdural haematoma as an aetiology of extra-axial hygroma and chronic subdural haematoma

Sverre Morten Zahl<sup>1</sup>  | Knut Wester<sup>2,3</sup> | Steven Gabaeff<sup>4</sup><sup>1</sup>Department of Ear, Nose and Throat, Aalesund Hospital, Aalesund, Norway<sup>2</sup>Department of Clinical Medicine K1, University of Bergen, Bergen, Norway<sup>3</sup>Department of Neurosurgery, Haukeland University Hospital, Bergen, Norway<sup>4</sup>Clinical Forensic Medicine, Healdsburg, CA, USA**Correspondence**Sverre Morten Zahl, Department of Ear, Nose and Throat, Aalesund Hospital, N-6026 Aalesund, Norway.  
Email: sverre.zahl@gmail.com**Abstract****Aim:** Benign external hydrocephalus (BEH), hygroma and chronic subdural haematoma are extra-axial fluid collections in infants. MRI studies have shown that almost half of all new-borns have perinatal subdural blood, generally referred to as subdural haematoma (SDH) or perinatal SDH. Epidemiologically there are striking similarities between chronic SDH and BEH in infants.**Methods:** Discussion of pathophysiological mechanisms for BEH and chronic SDH, based on existing literature.**Results:** Perinatal SDH is common, and we hypothesise that this condition in some infants develop into extra-axial fluid collections, known as hygroma, BEH or chronic subdural haematoma. The mechanism seems to be an intradural bleeding that creates an obstructive layer preventing normal CSF absorption. The site where the bleeding originates from and those areas enveloped in blood from the primary damaged area are prone to later rebleeds, seen as 'acute on chronic' haematomas. With steady production of CSF and the blockage, increased intracranial pressure drives the accelerated skull growth seen in many of these children.**Conclusion:** Perinatal SDH hampers CSF absorption, possibly leading to BEH and chronic SDH, with a high risk of false accusations of abuse. Close monitoring of head circumference could prove vital in detecting children with this condition.**KEYWORDS**

subdural haematoma, infants, hygroma, child abuse, head circumference, false accusations of abuse

**1 | BACKGROUND**

Benign external hydrocephalus (BEH) is the term widely used for a neuropaediatric condition with intracranial, extra-axial fluid collections. Most often the condition is defined as a combination of a clinical macrocephaly that is increased or rapidly increasing head circumference, and typical neuroimaging findings of enlarged

subarachnoid or subdural spaces, especially over the frontal lobes, prominent interhemispheric fissure, and normal or slightly enlarged lateral ventricles.<sup>1</sup> The distinction between subarachnoid and subdural spaces may be difficult, especially on CT imaging, but often also on MRI.

Given the criterion of a clinically detected large head and/or pathologically accelerated growth, together with the neuroimaging

**Abbreviations:** BEH, benign external hydrocephalus; SDH, subdural haematoma; CSF, cerebrospinal fluid; MRI, magnetic resonance imaging.

This is an open access article under the terms of the Creative Commons Attribution-NonCommercial-NoDerivs License, which permits use and distribution in any medium, provided the original work is properly cited, the use is non-commercial and no modifications or adaptations are made.

© 2019 The Authors. *Acta Paediatrica* published by John Wiley & Sons Ltd on behalf of Foundation Acta Paediatrica.

findings, the only population-based epidemiological study indicates an incidence of extra-axial collections of about 0.4 per 1000 live births.<sup>2</sup> Such extra-axial fluid collections are probably more frequent in infants than that, especially during the first months of life<sup>3</sup>; however, if their head circumference does not reach defined abnormal values, these infants will not fit the strict criteria above and will probably remain undetected in spite of potential evolving pathology. Thus, epidemiological studies with a clinically detected large head as a prerequisite will only reveal the tip of the iceberg. Many children whose head circumference has grown more than two standard deviations of percentile growth may have significant hygroma that is never studied. If the head circumference does not reach values qualifying for macrocephaly, their condition will not even be noted as potentially pathologic. Since the era of advanced neuroimaging began (CT and MRI), several articles about this condition have been published, as reviewed elsewhere.<sup>4</sup> Quite different names have been used in the literature; a collection of the most common terms is found in Table 1.

The word 'benign' reflects the traditional and possibly misleading opinion that the condition is self-limiting and produces only temporary, mild or no symptoms and is without long-lasting problems. Recently published long-term follow-up studies, however, show that some patients have various developmental, social and cognitive problems,<sup>5-7</sup> including psychomotor delay.<sup>8</sup> Additionally, much more severe conditions have been reported in association with such subdural fluid collections, above all, epileptic seizures,<sup>9-18</sup> subdural haematoma (SDH),<sup>8,10,12-14,16,19-28</sup> increased intracranial pressure<sup>29</sup> and in others apparent life-threatening events (ALTE).<sup>30</sup> Seizures and SDH are quite often described in the same patients. In addition, MRI diffusion shows white matter changes in BEH infants,<sup>31</sup> and an association between BEH and later development of autism spectrum disorder has also been suggested.<sup>32</sup> Thus, the term 'benign' appears to be misleading.

**TABLE 1** These different names have been used in the literature for the same or similar conditions

Benign/idiopathic external hydrocephalus<sup>1,78</sup>

Benign familial macrocephaly<sup>79</sup>

Benign infantile hydrocephalus<sup>80</sup>

Benign subdural collections<sup>62</sup>

Benign extra-axial fluid/collections<sup>40,81</sup>

Benign extracerebral fluid collections<sup>82</sup>

Benign communicating hydrocephalus<sup>83</sup>

Benign enlargement of the subarachnoid spaces<sup>84</sup>

Subarachnoid fluid collections<sup>85</sup>

Chronic subdural hygromas<sup>86</sup>

Pericerebral fluid collection<sup>87</sup>

Idiopathic macrocephaly<sup>7</sup>

Chronic subdural haematomas<sup>88</sup>

Subdural effusion<sup>89</sup>

### Key notes

- A perinatal haemorrhage is very common, especially if birth is complicated.
- We hypothesise that some infants with perinatal subdural haematoma (SDH) will develop benign external hydrocephalus (BEH) or chronic SDH.
- Lack of attention to this development will likely result in false accusations of abusive head trauma.

BEH is already considered to be a risk factor for developing SDH<sup>10,20,23</sup>; the larger the subdural fluid collections, the more likely it is that it will be associated with or even cause an SDH.<sup>33</sup> BEH and SDH have both been considered a form of subdural collection, and as shown in Table 1, the terms have sometimes been used interchangeably. When apparent prior BEH is complicated with acute haemorrhage into the collections, this complex of findings is in radiology reports often referred to as 'acute on chronic SDH'; a term that may more accurately reflect the aetiology of the hygroma as related to chronic SDH.

A subdural collection containing blood elements in an infant is in itself enough to raise suspicion of child abuse, especially if the carers cannot provide what is regarded an acceptable and plausible trauma history.<sup>34</sup> If the subdural blood is caused by a spontaneous leakage of blood, see below, there is no trauma history to tell. Several authors have pointed to the risk of a spontaneously occurring SDH in an infant with BEH being misdiagnosed as abusive head trauma (AHT).<sup>12,16,35</sup> A recent article describes the legal and social consequences of such diagnostic mistakes in detail.<sup>36</sup>

SDH in infants without an acceptable history of trauma is likely to be associated with AHT/NAT (nonaccidental trauma, formerly known as shaken baby syndrome—SBS). However, without a valid scientific basis for assuming such a causal relation,<sup>37</sup> other possible causes and associations are important to explore. The aim of this article is to examine more closely the possible connection between birth-related SDH (perinatal SDH) during infancy and the development of extra-axial fluid collections, not as 'benign' collections, but as chronic SDH, as discussed by Gabaeff,<sup>38</sup> on the basis of several observations.<sup>39,40</sup> In the following, different aspects of this will be presented.

## 2 | SDH AT BIRTH—PERINATAL SDH

SDH following difficult births have been recognised for a long time.<sup>41-43</sup> For the last decade, it has been known that subdural blood is common in about half of 'normal' vaginally delivered or unscheduled caesarean sections, preceded by labour, in new-borns.<sup>39</sup>

The first hint of birth-related SDH or perinatal SDH came from Looney et al in 2007 using early MRI technology.<sup>44</sup> A follow-up MRI study in 2008 by Rooks et al,<sup>39</sup> using more up to date MRI

technology, unpredictably, astonishingly and reliably showed that 46% of 101 asymptomatic term neonates had a perinatal SDH after 'normal' deliveries. In 18% of the 101 infants, a follow-up MRI was performed at 3 months of age. All but one showed resolution of the haematomas. One of these infants had a large rebleed after 26 days in a nonabuse context, with another MRI at 5 months showing resolution of the SDH, however, with a remaining prominent subarachnoid space.<sup>39</sup> While this case cannot predict the frequency of perinatal SDH leading to chronic SDH, it does refute what we believe is the false assumption: that all birth-related bleeding (at least 1 million in 4 million births annually in the United States) resolves without complications.

Abnormal or complicated labour increases the risk of intracranial haemorrhage,<sup>45,46</sup> with SDH being the most common type of bleeding.<sup>47,48</sup> Many new-borns with subdural haemorrhages are asymptomatic<sup>49</sup> or insufficiently symptomatic to arouse medical attention.

Supporting data in another study showed 53 cases of nontraumatic death in children with mean age 9 weeks, 70% had blood or hemosiderin in orbit tissues and subdural compartments; according to the authors, it was '...likely a consequence of the birth process'.<sup>50</sup> Vinchon et al reported 16 infants with spontaneous SDH, 9 of them had a history of complicated labour and 12 children had macrocrania.<sup>35</sup> In still another report, intradural haemorrhage and SDH were found in nontraumatic cases of child death, most commonly in infants under 1 month of corrected age.<sup>51</sup> In a large, population-based study of infants with SDH, perinatal SDH (diagnosed the first week of life) was associated with obstructed labour, emergency caesarean section, assisted vaginal delivery, asphyxia, and preterm birth, amongst others.<sup>52</sup>

Even if perinatal SDH seems to resolve in some cases, the restoring rate and grade is unknown. Evidently, in many infants a haematoma will persist for weeks and months, and some, if large enough, may become permanent retracted clots infused with scar tissue and fragile with respect to rebleeding. We believe that extra-axial blood in these subdural collections and the dural capillary bed can obstruct CSF reabsorption, thereby maintaining the subdural collections. Once obstructed, the fluid exerts a pressure on the skull, resulting in an increasing head circumference. Both the origin of the intradural bleeding and, in extreme cases, the stretching of bridging veins beyond their tensile capacities, caused by the chronic SDH, can result in rebleeds into this persistent subdural collection (see below).

### 3 | EPIDEMIOLOGY OF SDH AND BEH

In a population-based study, the incidence of BEH was around 0.4 per 1000 live births, with a male preponderance of 86.4%.<sup>2</sup> Median age at symptom debut (usually increasing head circumference) was 3.4 months.<sup>53</sup>

Another study had similar findings with an incidence of SDH during infancy of around 0.17 per 1000 live births, and a male

preponderance of 64.7%.<sup>52</sup> Median age in this Swedish register study was 3.5 months for infants older than 1 week.

Yet another study found a similar annual incidence of 0.24 for SDH.<sup>54</sup> The gender distribution for this whole study group (0-2-year-olds) was 65% boys, and the average age at diagnosis was 17 weeks (approx. 4 months). Zaben et al performed a review of infants diagnosed with SDH following forceps-assisted delivery in that study; where gender was specified, 11 out of 14 patients were boys.<sup>46</sup>

It is clear that there is a discrepancy in incidences of SDH and BEH, compared with for example Rooks et al.<sup>39</sup> We believe it may be explained by Rooks et al describing only asymptomatic subdural blood in new-borns, whereas the other studies look at only symptomatic infants that come to medical attention because they have developed a clinical condition.

According to these population-based studies of BEH and SDH, there are striking similarities between these two conditions, both in age and gender distribution. The male preponderance was evident even in the earliest publications on SDH, as was the age distribution with a peak incidence during the first 6 months of life.<sup>43,55</sup> The similar gender distribution of BEH and SDH with a marked male preponderance has been noted before.<sup>36,56</sup> In general, boys, presumably with larger heads than girls, have a higher risk of neonatal morbidity and mortality.<sup>57</sup> A large foetal head circumference in itself is associated with complicated labour.<sup>58</sup> Historically, a thorough article by Ingraham and Matson from 1944 also contains other interesting observations, for example that SDH should be suspected in infants with an earlier 'triad', totally different from the content of the present version of the term: failure to thrive, increasing head circumference and a history of difficult labour.<sup>43</sup>

### 4 | NEUROIMAGING AND FLUID CHARACTERISTICS

As shown in Table 1, the terms BEH and SDH are sometimes used interchangeably, also in recent publications.<sup>59</sup> Some articles include fluid analyses from these subdural collections, reporting both CSF-like fluid and 'mixed density' fluid with variable protein concentration (Table 2).

With mixed density fluid, the neuroimaging appearance is often described as BEH initially. However, with similar findings in the context of acute blood, the space is then referred to as chronic SDH. In these cases, the term 'acute on chronic' appears to replace BEH and is common in radiology reports.

Furthermore, the presence of hygroma, mixed density fluid and inflammatory membranes (neomembranes) is diagnostic criteria for chronic SDH. The layering of blood and the appearance of blood on CT and during drainage can be used to estimate the frequency of rebleeding and the age of blood. This remains an ongoing issue, with researchers still trying to find a common terminology, as these age estimates remain important due to the legal aspects of suspected AHT.<sup>60</sup>

**TABLE 2** Published subdural fluid analyses. The list is not necessarily exhaustive

Authors	No of patients	Fluid appearance/characteristics
Kasinathan et al <sup>59</sup>	1	Haemorrhagic fluid with elevated proteins (2.6 g/dL) and predominant lymphocytic pleocytosis (200 cells/dL)
Briner & Bodensteiner <sup>90</sup>	2	Patient 1: Dark yellow fluid with a protein content of 2 g/dL. RBC count 7000/cu mm. Patient 2: Straw-coloured fluid, with protein content 0.4 g/dL. RBC count 700/cu mm
Chazal et al <sup>29</sup>	2	Patient 1: Protein concentration 1.2 g/dL. Markedly decreased prealbumin level (0.9%). Patient 2: Protein 1.0 g/dL
Alvarez et al <sup>1</sup>	1	Normal CSF values
Kumar <sup>91</sup>	4	Resembled CSF on biochemical and cytological examination except for cell counts. The cell counts on tap ranged from 2 to 15 per mm <sup>3</sup>
Nogueira & Zaglul <sup>92</sup>	4	1 negative. Normal CSF in small amount in 2 patients. Xanthochromic fluid in small amount in 1
Neveling & Truex <sup>93</sup>	4	Results were 'negative', probably considered similar to CSF
Roshan et al <sup>94</sup>	4	CSF was normal (whether this was spinal CSF or from the enlarged SAS is unknown)
Wilms et al <sup>95</sup>	6	Mean protein content was 1.4 ± 0.8 g/dL
Barlow <sup>61</sup>	1	'Subdural tap through the fontanelle was dry'
Ment et al <sup>84</sup>	3	'No subdural fluid was demonstrated in any of the three patients in whom the subdural space was examined'
Palmer & Albert <sup>96</sup>	6	1 patient with 'motor oil' appearance 5 patients with xanthochromic and/or CSF-like fluid
Zouros et al <sup>97</sup>	5	'Haemorrhagic fluid' was found in all patients
Aoki et al <sup>98</sup>	3	Protein concentrations of 984 mg/dL; 2800 mg/dL; and 2610 mg/dL

## 5 | PATHOPHYSIOLOGY

The pathophysiology behind BEH might roughly be summarised in the following assorted hypotheses.

The most common hypothesis is that the accumulation of fluid is caused by immature arachnoid granulations during the first months of life not being able to absorb CSF.<sup>61</sup> Why the arachnoid granulations mature so late remains unknown, but this seems to be a normal biological event.

Another hypothesis, presented by Robertson and colleagues in 1979, is that subdural fluid somehow obstructs CSF reabsorption.<sup>62</sup> They suggested that the subdural fluid, although primarily CSF, often with particulate matter seen in the fluid, acts like a mechanical block, preventing CSF from reaching the arachnoid granulations. This condition subsequently dilates the adjacent subarachnoid channels, which would be seen on CT as wide cerebral sulci and prominent interhemispheric fissures.

Prior to the maturation of the arachnoid granulations, the intradural capillary bed appears to carry the load of reabsorbing CSF.<sup>63-65</sup> Channels pass through the dural border layer and conduct CSF to venules they are in contact with in the capillary bed. As arachnoid granulations mature late, the dura appears to be more important in CSF absorption during this period, as discussed by Oi et al.<sup>66</sup>

A common hypothesis on the association between BEH and SDH is that bridging veins traversing the subdural/subarachnoid space/hygroma are stretched with enlarged extra-axial collections, increasing the risk of venous rupture, either spontaneously or following minor trauma.<sup>27</sup> Images of actual bridging veins in autopsy photos, however, call this into question (Figure 1). The phenomenon of blood

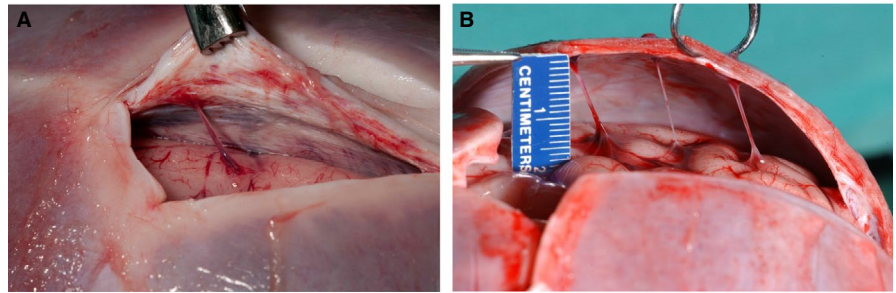
oozing from the veins' entry points is commonly observed during any craniotomy (eg by the second author); just manipulating the bridging veins at their dural entry points with a blunt instrument is enough to cause oozing of blood without the vein being torn. This blood could be leaking from the adjacent dural capillary bed.

With perinatal SDH, blood envelopes the structures within the dural capillary bed, obstructing its absorption capability. The reabsorption, which is constant and must occur to complete the CSF 'circulation', then has to operate at higher pressure. This increased pressure causes the skull bones to be pushed out and the hygroma forms as the virtually noncompressible brain continues to grow at a normal, steady rate. When the arachnoid granulations mature at 8-12 months of age, the dural capillary bed no longer performs this function, ICP decreases and accelerated head circumference growth stops. Thereafter, brain growth drives skull growth.<sup>67</sup>

Recent research further indicates that SDH can be initiated by a minor intradural bleeding, possibly originating from venous plexuses in the capillary bed. This creates a thin film of blood in the subdural space,<sup>68</sup> which, if sufficient, then overflows internally through the dural border cell layer and separates the arachnoid from the dura forming SDH between them.

Neomembranes are often seen on imaging and autopsies as a result of an inflammatory response from leaked blood.<sup>68</sup> These neomembranes are loose collections of scar tissue and capillaries that encase the prior haematoma. The SDH complications are then more susceptible to rebleeding either episodically or in small amounts, as Ito et al showed.<sup>69</sup> Clinically, we have noticed anaemia to be present, months after birth, during abuse workups and this raises suspicion about daily rebleeds of 1-2 mL/d. This may support

**FIGURE 1** Two autopsy photos showing bridging veins. In A there is some visible blood at the dural entrance. In B one may observe three bridging veins stretched extensively



perinatal SDH as the primary bleeding event, especially without a prior history or evidence of major postnatal trauma.

A unifying pathophysiologic theory may in our opinion be a birth-related bleeding that disrupts the CSF absorption in the dural capillary bed by hampering absorption of the continuously produced CSF, and that together with blood products and inflammatory debris in the hygroma, creates a subdural collection, prone to cause rebleeding. There are growth factors in old haematomas that have been shown to induce neovascularisation in the parietal haematoma membrane; these pathological vessels bleed easily,<sup>70-73</sup> and there are other factors that disturb normal coagulation or cause fibrinolysis in subdural haematomas.<sup>69,74-76</sup>

This dysfunction exists as long as the subdural capillary bed is the main absorbing route. As the arachnoid granulations gradually mature during the latter half of the first year, subdural collections and hence the head circumference gradually normalise. There is reason to believe that infants prone to a particularly difficult labour and/or instrumentation are susceptible to larger perinatal SDHs, and probably also a more complicated perinatal period. In a study of macrocephalic neonatal care survivors, hygroma evolved in about 40%, and presence of extra-axial fluid was associated with an increased risk of developmental delay.<sup>40</sup>

## 6 | SUMMARY

Perinatal SDH is a common condition in new-borns, creating a temporary dysfunction in CSF absorption in the dural capillary bed during infancy. The five main consequences of this are as follows: (a) an obstructing layer of fluid/blood creating a subdural collection; (b) neovascularisation and rebleeds from the original bleeding site intradurally and subdurally in the previously damaged area; (c) in extreme cases with wide hygromas, stretching of bridging veins that may bleed spontaneously or after minor trauma; (d) a subtle increase in ICP resulting in increased HC and temporary developmental delay; (e) a variety of apparent life-threatening events that precipitate medical intervention.

This theory on the formation of subdural collections, combined with the similar demographics of BEH/hygroma and SDH, leads us to theorise that these conditions in fact are the same. Perinatal SDH creates a subdural collection with or without visible blood (hence the terms BEH, hygroma, chronic SDH, or with acute blood, 'acute on chronic', etc). A complicated labour clearly increases the risk of

this development. Rebleeds from damaged areas that are neovascularised or new bleeds from bridging veins insertion points create acute SDHs, often seen as acute blood or mixed density collections within the hygroma.

Firstly, we propose that BEH is a form of chronic SDH. Secondly, the cascade of events following the perinatal SDH can lead to both chronic and recurrent acute SDH (often both). In infants, the finding of acute SDH leads to suspicion and accusation of child abuse. The implications of our theory may have huge legal consequences. We fear that many cases of infant SDH, with any amount of acute blood, in the context of extra-axial dural collections or not, have been misdiagnosed as abuse.

A possible first step in avoiding this could be to follow otherwise healthy children with rapidly/exceedingly increasing head circumference closely. Both incremental increases in head circumference that surpass two standard deviations after birth, and/or an absolute head circumference above the 95th percentile should be used to identify this form of neuropathology.<sup>77</sup> Especially, infants with a history of birth problems including meconium staining, latching problems, positional discomfort, instrumented deliveries, prematurity, multiple births or a significant decrease in head circumference in the week after birth followed by accelerated growth should be imaged and monitored closely by a paediatric neurologist. Clinically, vomiting, transient change in feeding or sleeping patterns, intermittent fussiness and changes in behaviour are neurologic symptoms in infants that are often misdiagnosed as gastrointestinal problems. The identification of potentially problematic, and progressive, perinatal SDH involves a high index of suspicion, facilitating early neurosurgical intervention when necessary.

Most importantly, an increased awareness about the magnitude of babies with perinatal SDH and the high risk of false accusations of abuse is the essential first step.

## CONFLICT OF INTEREST

SMZ declares no conflict of interest. KW has served as expert witness in AHT/SBS cases. SG has provided consultation in cases involving accusations of child abuse, including AHT/SBS cases and testimony, if appropriate, in other cases with medical issues relating to arguable accusations of abuse.

## ORCID

Sverre Morten Zahl  <https://orcid.org/0000-0003-3303-6977>

## REFERENCES


- Alvarez LA, Maytal J, Shinnar S. Idiopathic external hydrocephalus: natural history and relationship to benign familial macrocephaly. *Pediatrics*. 1986;77(6):901-907.
- Wiig US, Zahl SM, Egge A, Helseth E, Wester K. Epidemiology of benign external hydrocephalus in Norway—a population-based study. *Pediatr Neurol*. 2017;73:36-41.
- Gravendeel J, Rosendahl K. Cerebral biometry at birth and at 4 and 8 months of age. A prospective study using US. *Pediatr Radiol*. 2010;40(10):1651-1656.
- Zahl SM, Egge A, Helseth E, Wester K. Benign external hydrocephalus: a review, with emphasis on management. *Neurosurg Rev*. 2011;34(4):417-432.
- Mikkelsen R, Rodevand LN, Wiig US, et al. Neurocognitive and psychosocial function in children with benign external hydrocephalus (BEH)—a long-term follow-up study. *Childs Nerv Syst*. 2017;33(1):91-99.
- Zahl SM, Egge A, Helseth E, Skarbo AB, Wester K. Quality of life and physician-reported developmental, cognitive, and social problems in children with benign external hydrocephalus—long-term follow-up. *Childs Nerv Syst*. 2019;35(2):245-250.
- Muenchberger H, Assaad N, Joy P, Brunson R, Shores EA. Idiopathic macrocephaly in the infant: long-term neurological and neuropsychological outcome. *Childs Nerv Syst*. 2006;22(10):1242-1248.
- Azais M, Echenne B. Idiopathic subarachnoid space enlargement (benign external hydrocephalus) in infants. *Ann Pediatr-Paris*. 1992;39(9):550-558.
- Alper G, Ekinci G, Yilmaz Y, Arıkan C, Telyar G, Erzen C. Magnetic resonance imaging characteristics of benign macrocephaly in children. *J Child Neurol*. 1999;14(10):678-682.
- Ghosh PS, Ghosh D. Subdural hematoma in infants without accidental or nonaccidental injury: benign external hydrocephalus, a risk factor. *Clin Pediatr*. 2011;50(10):897-903.
- Govaert P, Oostra A, Matthys D, Vanhaesebrouck P, Leroy J. How idiopathic is idiopathic external hydrocephalus? *Dev Med Child Neurol*. 1991;33(3):274-276.
- Hellbusch LC. Benign extracerebral fluid collections in infancy: clinical presentation and long-term follow-up. *J Neurosurg*. 2007;107(2 Suppl):119-125.
- Laubscher B, Deonna T, Uske A, van Melle G. Primitive megalencephaly in children: natural history, medium term prognosis with special reference to external hydrocephalus. *Eur J Pediatr*. 1990;149(7):502-507.
- McNeely PD, Atkinson JD, Saigal G, O'Gorman AM, Farmer JP. Subdural hematomas in infants with benign enlargement of the subarachnoid spaces are not pathognomonic for child abuse. *Am J Neuroradiol*. 2006;27(8):1725-1728.
- Nogueira GJ, Zaglul HF. Hypodense extracerebral images on computed-tomography in children external hydrocephalus - a misnomer. *Childs Nerv Syst*. 1991;7(6):336-341.
- Piatt JH Jr. A pitfall in the diagnosis of child abuse: external hydrocephalus, subdural hematoma, and retinal hemorrhages. *Neurosurg Focus*. 1999;7(4):e4.
- Roshan K, Elizabeth C, Chacko A, Rajendra J, Gururaj A, Dilip S. External hydrocephalus - A report of 16 cases from Oman. *J Trop Pediatrics*. 1998;44(3):153-156.
- Sahar A. Pseudohydrocephalus-megalocephaly, increased intracranial-pressure and widened subarachnoid space. *Neuropadiatrie*. 1978;9(2):131-139.
- Ravid S, Maytal J. External hydrocephalus: a probable cause for subdural hematoma in infancy. *Pediatr Neurol*. 2003;28(2):139-141.
- Vinchon M. Subdural hematoma in infants: can it occur spontaneously? Data from a prospective series and critical review of the literature by Vinchon et al. Reply. *Childs Nerv Syst*. 2010;26(11):1485.
- Gout A, Gautier I, Bellaiche M, et al. Idiopathic subarachnoid space enlargement in infancy: simple anatomic variant or hemorrhagic risk factor? *Arch Pediatr*. 1997;4(10):983-987.
- Kapila A, Trice J, Spies WG, Siegel BA, Gado MH. Enlarged Cerebrospinal-Fluid Spaces in Infants with Subdural Hematomas. *Radiology*. 1982;142(3):669-672.
- Lee HC, Chong S, Lee JY, et al. Benign extracerebral fluid collection complicated by subdural hematoma and fluid collection: clinical characteristics and management. *Childs Nerv Syst*. 2018;34(2):235-245.
- McKeag H, Christian CW, Rubin D, Daymont C, Pollock AN, Wood J. Subdural hemorrhage in pediatric patients with enlargement of the subarachnoid spaces Clinical article. *J Neurosurg-Pediatr*. 2013;11(4):438-444.
- Miller D, Barnes P, Miller M. The significance of macrocephaly or enlarging head circumference in infants with the triad further evidence of mimics of shaken baby syndrome. *Am J Forensic Med Pathol*. 2015;36(2):111-120.
- Mori K, Sakamoto T, Nishimura K, Fujiwara K. Subarachnoid fluid collection in infants complicated by subdural-hematoma. *Childs Nerv Syst*. 1993;9(5):282-284.
- Papasian NC, Frim DM. A theoretical model of benign external hydrocephalus that predicts a predisposition towards extra-axial hemorrhage after minor head trauma. *Pediatr Neurosurg*. 2000;33(4):188-193.
- Pittman T. Significance of a subdural hematoma in a child with external hydrocephalus. *Pediatr Neurosurg*. 2003;39(2):57-59.
- Chazal J, Tanguy A, Irthum B, Janny P, Vanneuville G. Dilatation of the subarachnoid pericerebral space and absorption of cerebrospinal fluid in the infant. *Anat Clin*. 1985;7(1):61-66.
- Barnes PD, Galaznik J, Gardner H, Shuman M. Infant acute life-threatening event—dysphagic choking versus nonaccidental injury. *Semin Pediatr Neurol*. 2010;17(1):7-11.
- Sun M, Yuan W, Hertzler DA, Cancelliere A, Altaye M, Mangano FT. Diffusion tensor imaging findings in young children with benign external hydrocephalus differ from the normal population. *Childs Nerv Syst*. 2012;28(2):199-208.
- Shen MD, Nordahl CW, Young GS, et al. Early brain enlargement and elevated extra-axial fluid in infants who develop autism spectrum disorder. *Brain*. 2013;136(Pt 9):2825-2835.
- Tucker J, Choudhary AK, Piatt J. Macrocephaly in infancy: benign enlargement of the subarachnoid spaces and subdural collections. *J Neurosurg-Pediatr*. 2016;18(1):16-20.
- Duhaime AC, Alario AJ, Lewander WJ, et al. Head-injury in very young-children - mechanisms, injury types, and ophthalmologic findings in 100 hospitalized-patients younger than 2 years of age. *Pediatrics*. 1992;90(2):179-185.
- Vinchon M, Delestret I, DeFoort-Dhellemmes S, Desurmont M, Noule N. Subdural hematoma in infants: can it occur spontaneously? Data from a prospective series and critical review of the literature. *Childs Nerv Syst*. 2010;26(9):1195-1205.
- Wester K. Two infant boys misdiagnosed as "shaken baby" and their twin sisters: a cautionary tale. *Pediatr Neurol*. 2019;97:3-11.
- Lynoe N, Elinder G, Hallberg B, Rosen M, Sundgren P, Eriksson A. Insufficient evidence for 'shaken baby syndrome' - a systematic review. *Acta Paediatr*. 2017;106(7):1021-1027.
- Gabaëff SC. Investigating the possibility and probability of perinatal subdural hematoma progressing to chronic subdural hematoma, with and without complications, in neonates, and its potential relationship to the misdiagnosis of abusive head trauma. *Leg Med*. 2013;15(4):177-192.
- Rooks VJ, Eaton JP, Ruess L, Petermann GW, Keck-Wherley J, Pedersen RC. Prevalence and evolution of intracranial hemorrhage in asymptomatic term infants. *AJNR Am J Neuroradiol*. 2008;29(6):1082-1089.

40. Lorch SA, D'Agostino JA, Zimmerman R, Bernbaum J. "Benign" extra-axial fluid in survivors of neonatal intensive care. *Arch Pediatr Adolesc Med.* 2004;158(2):178-182.
41. Schipke R, Riege D, Scoville WB. Acute subdural hemorrhage at birth. *Pediatrics.* 1954;14(5):468-474.
42. Hayashi T, Hashimoto T, Fukuda S, Ohshima Y, Moritaka K. Neonatal subdural hematoma secondary to birth injury. Clinical analysis of 48 survivors. *Childs Nerv Syst.* 1987;3(1):23-29.
43. Ingraham FD, Matson DD. Subdural hematoma in infancy. *J Pediatr.* 1944;24(1):1-37.
44. Looney CB, Smith JK, Merck LH, et al. Intracranial hemorrhage in asymptomatic neonates: prevalence on MR images and relationship to obstetric and neonatal risk factors. *Radiology.* 2007;242(2):535-541.
45. Towner D, Castro MA, Eby-Wilkens E, Gilbert WM. Effect of mode of delivery in nulliparous women on neonatal intracranial injury. *N Engl J Med.* 1999;341(23):1709-1714.
46. Zaben M, Manivannan S, Petralia C, Leach P. Subdural haematoma in neonates following forceps-assisted delivery: case series and review of the literature. *Childs Nerv Syst.* 2019;35(3):403-409.
47. Hong HS, Lee JY. Intracranial hemorrhage in term neonates. *Childs Nerv Syst.* 2018;34(6):1135-1143.
48. Sirgiovanni I, Avignone S, Groppo M, et al. Intracranial haemorrhage: an incidental finding at magnetic resonance imaging in a cohort of late preterm and term infants. *Pediatr Radiol.* 2014;44(3):289-296.
49. Gupta SN, Kechli AM, Kanamalla US. Intracranial hemorrhage in term newborns: management and outcomes. *Pediatr Neurol.* 2009;40(1):1-12.
50. Del Bigio MR, Phillips SM. Retroocular and subdural hemorrhage or hemosiderin deposits in pediatric autopsies. *J Neuropathol Exp Neurol.* 2017;76(4):313-322.
51. Scheimberg I, Cohen MC, Zapata Vazquez RE, et al. Nontraumatic intradural and subdural hemorrhage and hypoxic ischemic encephalopathy in fetuses, infants, and children up to three years of age: analysis of two audits of 636 cases from two referral centers in the United Kingdom. *Pediatr Dev Pathol.* 2013;16(3):149-159.
52. Hogberg U, Andersson J, Squier W, et al. Epidemiology of subdural haemorrhage during infancy: a population-based register study. *PLoS ONE.* 2018;13(10):e0206340.
53. Zahl SM, Egge A, Helseth E, Wester K. Clinical, radiological, and demographic details of benign external hydrocephalus: a population-based study. *Pediatr Neurol.* 2019;96:53-57.
54. Hobbs C, Childs AM, Wynne J, Livingston J, Seal A. Subdural haematoma and effusion in infancy: an epidemiological study. *Arch Dis Child.* 2005;90(9):952-955.
55. Guthkelch AN. Subdural effusions in infancy: 24 cases. *Br Med J.* 1953;1(4804):233-239.
56. Miller R, Miller M. Overrepresentation of males in traumatic brain injury of infancy and in infants with macrocephaly: further evidence that questions the existence of shaken baby syndrome. *Am J Forensic Med Pathol.* 2010;31(2):165-173.
57. Carlsen F, Grytten J, Eskild A. Changes in fetal and neonatal mortality during 40 years by offspring sex: a national registry-based study in Norway. *BMC Pregnancy Childbirth.* 2013;13:101.
58. Elvander C, Hogberg U, Ekeus C. The influence of fetal head circumference on labor outcome: a population-based register study. *Acta Obstet Gynecol Scand.* 2012;91(4):470-475.
59. Kasinathan A, Sankhyan N, Aggarwal A, Singhi P. Subdural hemorrhage of infancy: is it spontaneous? *Neuro India.* 2018;66(2):557-558.
60. Wittschieber D, Karger B, Pfeiffer H, Hahnemann ML. Understanding subdural collections in pediatric abusive head trauma. *AJNR Am J Neuroradiol.* 2019;40(3):388-395.
61. Barlow CF. CSF dynamics in hydrocephalus—with special attention to external hydrocephalus. *Brain Dev.* 1984;6(2):119-127.
62. Robertson WC Jr, Chun RW, Orrison WW, Sackett JF. Benign subdural collections of infancy. *J Pediatr.* 1979;94(3):382-386.
63. Mack J, Squier W, Eastman JT. Anatomy and development of the meninges: implications for subdural collections and CSF circulation. *Pediatr Radiol.* 2009;39(3):200-210.
64. Squier W, de Luca G, Lindberg E, Darby S. Dural fluid channels: new thoughts, old observations. *Neuropathol Appl Neurobiol.* 2009;35:1.
65. Squier W, Lindberg E, Mack J, Darby S. Demonstration of fluid channels in human dura and their relationship to age and intradural bleeding. *Childs Nerv Syst.* 2009;25(8):925-931.
66. Oi S, Di Rocco C. Proposal of "evolution theory in cerebrospinal fluid dynamics" and minor pathway hydrocephalus in developing immature brain. *Childs Nerv Syst.* 2006;22(7):662-669.
67. Jin SW, Sim KB, Kim SD. Development and growth of the normal cranial vault: an embryologic review. *J Korean Neurosurg Soc.* 2016;59(3):192-196.
68. Squier W, Mack J. The neuropathology of infant subdural haemorrhage. *Forensic Sci Int.* 2009;187(1-3):6-13.
69. Ito H, Yamamoto S, Komai T, Mizukoshi H. Role of local hyperfibrinolysis in the etiology of chronic subdural hematoma. *J Neurosurg.* 1976;45(1):26-31.
70. Friede RL, Schachenmayr W. Origin of subdural neomembranes. 2. Fine-structure of neomembranes. *Am J Pathol.* 1978;92(1):69-84.
71. Sato S, Suzuki J. Ultrastructural observations of capsule of chronic subdural hematoma in various clinical stages. *J Neurosurg.* 1975;43(5):569-578.
72. Weigel R, Schilling L, Schmiedek P. Specific pattern of growth factor distribution in chronic subdural hematoma (CSH): evidence for an angiogenic disease. *Acta Neurochir (Wien).* 2001;143(8):811-818.
73. Yamashita T, Yamamoto S. Clinicopathological study of acute subdural-hematoma in the chronic healing stage - clinical, histological and ultrastructural comparisons with chronic subdural-hematoma. *Neurochirurgia.* 1984;27(4):98-105.
74. Kawakami Y, Chikama M, Tamiya T, Shimamura Y. Coagulation and fibrinolysis in chronic subdural hematoma. *Neurosurgery.* 1989;25(1):25-29.
75. Murakami H, Hirose Y, Sagoh M, et al. Why do chronic subdural hematomas continue to grow slowly and not coagulate? Role of thrombomodulin in the mechanism. *J Neurosurg.* 2002;96(5):877-884.
76. Ito H, Saito K, Yamamoto S, Hasegawa T. Tissue-type plasminogen activator in the chronic subdural hematoma. *Surg Neurol.* 1988;30(3):175-179.
77. Zahl SM, Wester K. Routine measurement of head circumference as a tool for detecting intracranial expansion in infants: what is the gain? A nationwide survey. *Pediatrics.* 2008;121(3):e416-e420.
78. Cundall DB, Lamb JT, Roussounis SH. Identical twins with idiopathic external hydrocephalus. *Dev Med Child Neurol.* 1989;31(5):678-681.
79. Asch AJ, Myers GJ. Benign familial macrocephaly: report of a family and review of the literature. *Pediatrics.* 1976;57(4):535-539.
80. Amodio J, Spektor V, Pramanik B, Rivera R, Pinkney L, Fefferman N. Spontaneous development of bilateral subdural hematomas in an infant with benign infantile hydrocephalus: color Doppler assessment of vessels traversing extra-axial spaces. *Pediatr Radiol.* 2005;35(11):1113-1117.
81. Carolan PL, McLaurin RL, Towbin RB, Towbin JA, Egelhoff JC. Benign extra-axial collections of infancy. *Pediatr Neurosci.* 1985;12(3):140-144.
82. Hamza M, Bodensteiner JB, Noorani PA, Barnes PD. Benign extra-cerebral fluid collections: a cause of macrocrania in infancy. *Pediatr Neurol.* 1987;3(4):218-221.
83. Kendall B, Holland I. Benign communicating hydrocephalus in children. *Neuroradiology.* 1981;21(2):93-96.
84. Ment LR, Duncan CC, Geehr R. Benign enlargement of the sub-arachnoid spaces in the infant. *J Neurosurg.* 1981;54(4):504-508.
85. Al-Saedi SA, Lemke RP, Debooy VD, Casiro O. Subarachnoid fluid collections: a cause of macrocrania in preterm infants. *J Pediatr.* 1996;128(2):234-236.

86. Caldarelli M, Di Rocco C, Romani R. Surgical treatment of chronic subdural hygromas in infants and children. *Acta Neurochir (Wien)*. 2002;144(6): 581-588; discussion 8.
87. Chen CY, Chou TY, Zimmerman RA, Lee CC, Chen FH, Faro SH. Pericerebral fluid collection: differentiation of enlarged subarachnoid spaces from subdural collections with color Doppler US. *Radiology*. 1996;201(2):389-392.
88. Orrison WW, Robertson WC, Sackett JF. Computerized tomography in chronic subdural hematomas (effusions) of infancy. *Neuroradiology*. 1978;16:79-81.
89. Tsubokawa T, Nakamura S, Satoh K. Effect of temporary subdural-peritoneal shunt on subdural effusion with subarachnoid effusion. *Childs Brain*. 1984;11(1):47-59.
90. Briner S, Bodensteiner J. Benign subdural collections of infancy. *Pediatrics*. 1981;67(6):802-804.
91. Kumar R. External hydrocephalus in small children. *Childs Nerv Syst*. 2006;22(10):1237-1241.
92. Nogueira GJ, Zaglul HF. Hypodense extracerebral images on computed tomography in children. "External hydrocephalus": a misnomer? *Childs Nerv Syst*. 1991;7(6):336-341.
93. Neveling EA, Truex RC Jr. External obstructive hydrocephalus: a study of clinical and developmental aspects in ten children. *J Neurosurg Nurs*. 1983;15(4):255-260.
94. Roshan K, Elizabeth C, Chacko A, Rajendra J, Gururaj A, Dilip S. External hydrocephalus—a report of 16 cases from Oman. *J Trop Pediatr*. 1998;44(3):153-156.
95. Wilms G, Vanderschueren G, Demaerel PH, et al. CT and MR in infants with pericerebral collections and macrocephaly: benign enlargement of the subarachnoid spaces versus subdural collections. *AJNR Am J Neuroradiol*. 1993;14(4):855-860.
96. Palmer AW, Albert GW. Minicraniotomy with a subgaleal pocket for the treatment of subdural fluid collections in infants. *J Neurosurg Pediatr*. 2019;23(4):480-485.
97. Zouros A, Bhargava R, Hoskinson M, Aronyk KE. Further characterization of traumatic subdural collections of infancy. Report of five cases. *J Neurosurg*. 2004;100(5):512-518.
98. Aoki N, Mizutani H, Masuzawa H. Unilateral subdural-peritoneal shunting for bilateral chronic subdural hematomas in infancy. Report of three cases. *J Neurosurg*. 1985;63(1):134-137.



Sverre Morten Zahl



Knut Wester



Steven Gabaeff

**How to cite this article:** Zahl SM, Wester K, Gabaeff S. Examining perinatal subdural haematoma as an aetiology of extra-axial hygroma and chronic subdural haematoma. *Acta Paediatr*. 2020;109:659-666. <https://doi.org/10.1111/apa.15072>