



# MRI findings of neuronal ceroid lipofuscinosis in a cat

Crystal White<sup>1</sup>, Jeremy Mortier<sup>1</sup>, Ranieri Verin<sup>1</sup>,  
 Thomas Maddox<sup>1</sup>, Rita Goncalves<sup>1</sup> and  
 Daniel Sanchez-Masian<sup>1</sup>

*Journal of Feline Medicine and Surgery Open Reports*  
 1–6

© The Author(s) 2018

Reprints and permissions:

sagepub.co.uk/journalsPermissions.nav

DOI: 10.1177/2055116918757330

journals.sagepub.com/home/jfmsopenreports

This paper was handled and processed

by the European Editorial Office (ISFM)

for publication in *JFMS Open Reports*



## Abstract

**Case summary** A 2-year-old male domestic shorthair cat presented to the University of Liverpool Small Animal Teaching Hospital with a 2 week history of altered mentation, blindness and focal epileptic seizures. MRI examination revealed generalised cerebral and cerebellar atrophy, diffuse T2-weighted hyperintensity of the white matter and meningeal thickening. Neuronal ceroid lipofuscinosis was confirmed on post-mortem examination.

**Relevance and novel information** This is the first report of the MRI findings of neuronal ceroid lipofuscinosis in a cat.

**Accepted:** 12 January 2018

## Case description

A 2-year-old, 3.4 kg male neutered domestic shorthair cat presented to the University of Liverpool Small Animal Teaching Hospital with a 2 week history of progressive weight loss, altered mentation, blindness and suspected focal epileptic seizures. Relevant history included a single visit to the referring veterinary surgeon 6 months prior to presentation for non-specific behavioural changes. On neurological examination, the cat's mentation was obtunded and disorientated. The menace response was markedly reduced bilaterally with intact pupillary light reflexes. Jaw clattering and hypersalivation were demonstrated intermittently, consistent with focal epileptic seizure activity. Stimulus resulted in hyper-reactivity and hypertonicity of all limbs, thus hindering a comprehensive neurological examination, including ophthalmological and visual assessment. Gait analysis was not possible owing to the cat's obtunded status and hyper-reactivity. The remaining general examination was unremarkable. Based on the clinical signs and limited neurological examination, a diffuse forebrain neurolocalisation was suspected. The main differential diagnoses for a 2-year-old cat with diffuse forebrain neurolocalisation included metabolic disease (lysosomal storage disease, thiamine deficiency, hepatic encephalopathy), infectious causes (feline

infectious peritonitis, toxoplasmosis, bacterial meningitis), immune-mediated disease (meningoencephalitis of unknown origin), developmental disease (lissencephaly, microencephaly) and degenerative disease (neuroaxonal dystrophy and leukoencephalomyelopathy). Biochemistry, including fasting ammonia and preprandial bile acids, and haematology were within normal limits. Serological testing for feline leukaemia virus, feline immunodeficiency virus, feline coronavirus and toxoplasmosis were negative. Cerebrospinal fluid analysis, including total protein, total nucleated cell count and cytology, was unremarkable.

MRI of the brain was performed using a 1.5 T magnet (Philips Ingenia CX). All slices were 3 mm thick with a 0.3 mm slice gap. Sagittal, dorsal and transverse T2-weighted (T2W) images were acquired. Transverse images for fluid-attenuated inversion recovery (FLAIR), T2\*W, T1-weighted before and after intravenous administration of contrast medium (gadobutrol 0.1 mmol/kg bodyweight [Gadovist];

<sup>1</sup>Leahurst Small Animal Teaching Hospital, University of Liverpool, Merseyside, UK

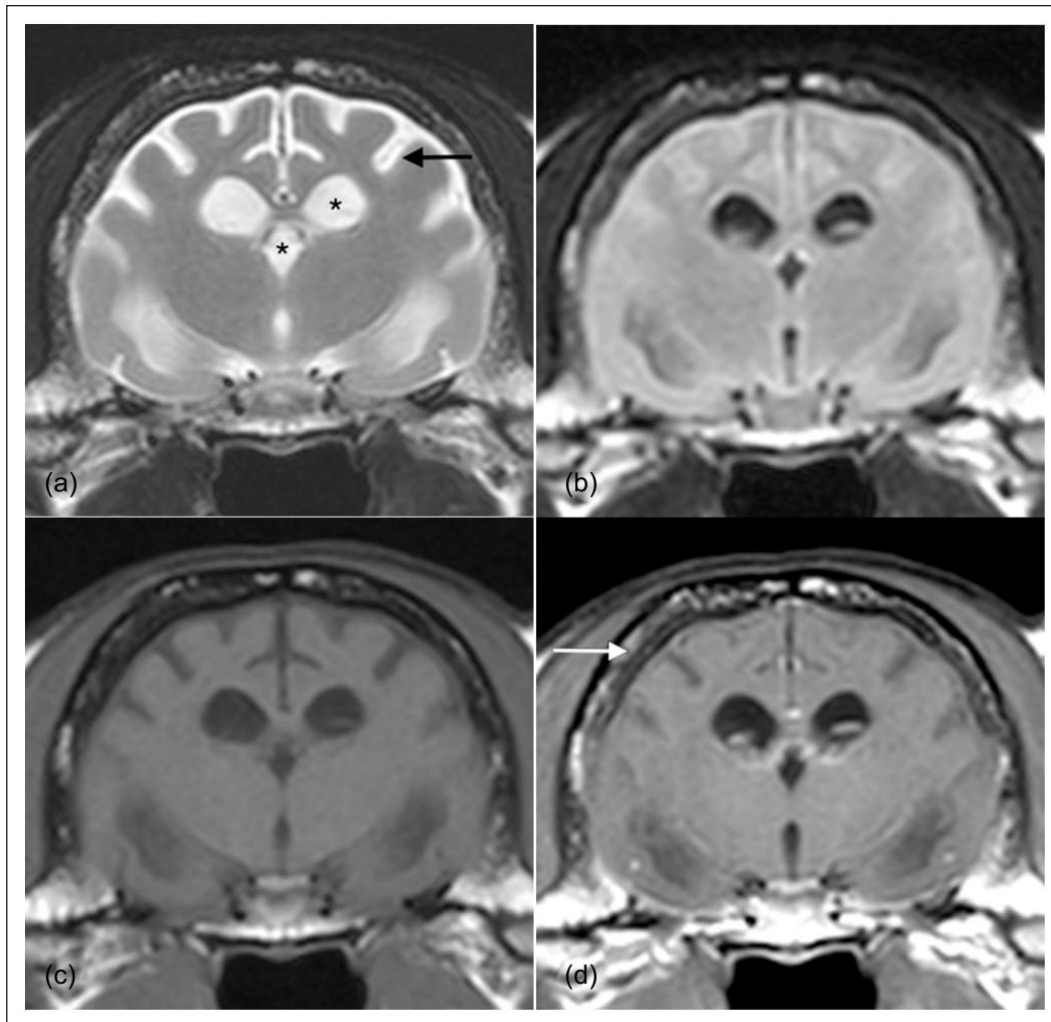
### Corresponding author:

Crystal White, Chestergates Veterinary Specialists, Chester, UK  
 Email: crwhite@alumni.rvc.ac.uk



Creative Commons Non Commercial CC BY-NC: This article is distributed under the terms of the Creative Commons

Attribution-NonCommercial 4.0 License (<http://www.creativecommons.org/licenses/by-nc/4.0/>) which permits non-commercial use, reproduction and distribution of the work without further permission provided the original work is attributed as specified on the SAGE and Open Access pages (<https://us.sagepub.com/en-us/nam/open-access-at-sage>).



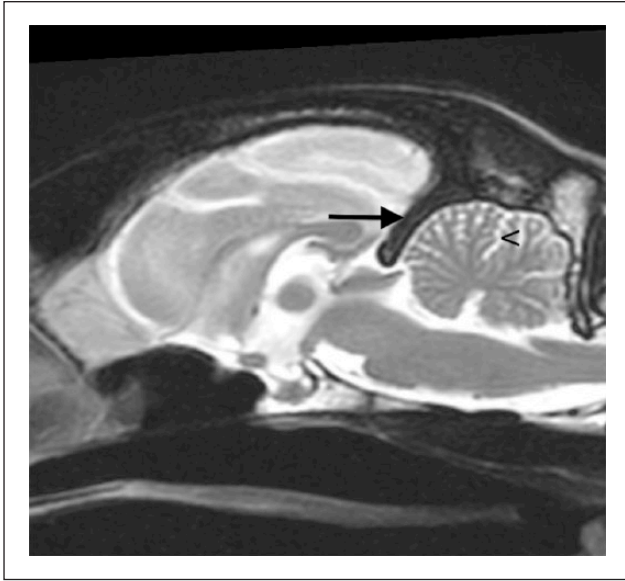
**Figure 1** (a) T2-weighted (T2W), (b) fluid-attenuated inversion recovery, (c) T1-weighted (T1W) and (d) T1W post-contrast transverse images of the brain at the level of the third ventricle. The cat's left is on the right. Symmetric ventriculomegaly is apparent (\*). There is poor white matter/grey matter distinction owing to diffuse hyperintensity of the white matter on T2W sequence. Marked cortical atrophy and widening of the cerebral sulci are visible (black arrow). Generalised, even calvarial hyperostosis is noted (white arrow)

Bayer]) and proton-density weighted sequences were obtained.

On all sequences there was thinning of the cerebral and cerebellar cortices with widening of the corresponding sulci, demonstrating diffuse cortical atrophy. The corpus callosum was markedly thin and only partially visualised with absence of a visible rostrum, genu and body. Moderate, generalised symmetrical dilation of the ventricular system was present, with complete suppression of contents on FLAIR, indicating that the cerebrospinal fluid was not markedly abnormal. Mild, generalised, symmetrical and homogeneous increased T2W signal intensity of the cerebral white matter was visible, with consequent decrease in the distinction between the white and grey matter (Figure 1). The pachymeninges were mildly and diffusely thickened.

There were no regions of abnormal contrast enhancement. Generalised and marked thickening of the calvarium and osseous tentorium cerebelli was visible (calvarial hyperostosis) with reduction of the fat signal of the diploe (Figure 2). The remaining bones of the skull were normal. Given the MRI findings and the signalment of the cat the presumptive diagnosis was an inherited neurodegenerative disorder, most likely neuronal ceroid lipofuscinosis or other lysosomal storage disease.

Following the presumptive diagnosis of neurodegenerative lysosomal storage disease and worsening of clinical signs the cat was euthanased on humane grounds and underwent a full post-mortem examination. Grossly, the meninges were diffusely moderately thickened and the brain showed moderate diffuse and bilateral cortical atrophy with narrowing of gyri and widening of sulci



**Figure 2** T2-weighted sagittal image of the brain. Moderate dilation of the third and fourth ventricles is apparent. Hyperostosis of the osseous tentorium cerebelli and calvarium is visible (black arrow). There is mild widening of the cerebellar sulci (<) due to cerebellar atrophy

(Figure 3a). Subjectively, a mild dilation of the ventricular system was observed. Sections of meninges and relevant areas of the brain and cerebellum, including motor, somatosensory, limbic, vestibular and visual system, were sampled for histopathology and transmission electron microscopy (TEM). Samples of the spinal cord at the level of the cervical and lumbosacral intumescences (C5–T1 and L3–L6, respectively) were also obtained for histopathology.

Meninges showed diffuse moderate thickening due to deposition of pale eosinophilic mature collagen interpreted as fibrosis and confirmed with Masson's trichrome stain. All cerebral areas examined showed mild-to-moderate gliosis and moderate loss of neurons (more severe in cortical areas) with numerous neurons distended and enlarged by botryoid, pale acidophilic to glassy cytoplasmic inclusions (Figure 3b), with frequent marginalisation of nuclei. Intracytoplasmic vacuoles resulted markedly positive to Luxol fast blue stain (Figure 3c), moderately positive to periodic acid–Schiff (Figure 3d) and stained red with Masson's trichrome (Figure 3e). When observed under a fluorescent microscope (excitation 465–495 nm) the cytoplasmic material showed green autofluorescence (Figure 3f). The cerebellum and the spinal cord were the least affected areas with well-represented neuronal cells showing few (very rare in the spinal cord) intracytoplasmic inclusions. Ultrastructural examination of the intracytoplasmic neuronal deposits in the occipital cortex showed electron-dense, membrane-bound material (Figure 3g) composed

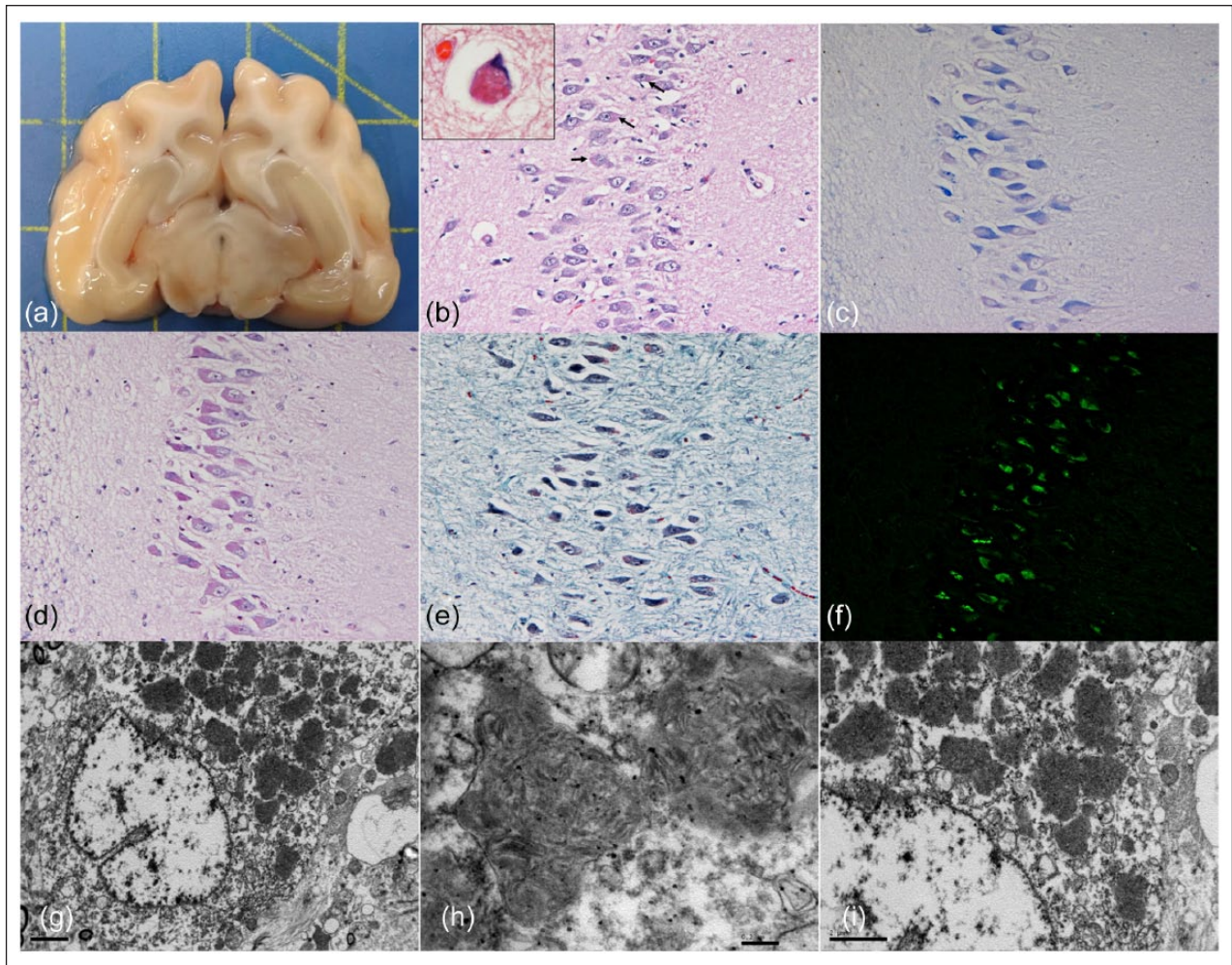
of small curvilinear lamellar stacks (Figure 3h) and electron-dense, variably sized granular material (Figure 3i), consistent morphologically with previously described intra-neuronal lipofuscins in cats.<sup>1–4</sup> No further gross and histopathological changes were observed in the main thoracic and abdominal organs, including autonomic ganglia. Furthermore, both eyes were thoroughly examined to rule out the presence of retinal neuronal inclusions and to confirm the suspect of central blindness. Neither eye showed histopathological changes.

## Discussion

To our knowledge this is the first report of MRI findings in a cat with confirmed neuronal ceroid lipofuscinosis. The neuronal ceroid lipofuscinoses represent a heterogeneous group of genetically determined neurodegenerative lysosomal storage diseases. The disease is characterised by abnormal accumulation of autofluorescent lipopigments within the neuronal and extraneuronal tissue.<sup>5</sup> Neuronal ceroid lipofuscinosis has been described in several domestic species, including dogs, cats, cattle, sheep, goats, monkeys and mice.<sup>6–13</sup> Clinical signs are similar in all species, including humans, and involve progressive cognitive decline, motor dysfunction, vision deficits and epileptic seizures, ultimately resulting in death or euthanasia. Symptomatic management is generally the mainstay of treatment.<sup>14</sup> Encouraging results have, however, been seen using enzyme-replacement therapy and gene therapy.<sup>15</sup> Carnitine is a breakdown product of subunit c protein, a major component of the storage material that accumulates in a number of neuronal ceroid lipofuscinoses. Delays in cognitive dysfunction have been reported in English Springer Spaniels supplemented long term with carnitine.<sup>15</sup> However, despite these therapeutic advances, neuronal ceroid lipofuscinoses remain an incurable group of diseases.

The cat in this case demonstrated generalised and symmetrical brain cortical atrophy and secondary dilation of the ventricular system and intracranial subarachnoid space (hydrocephalus ex vacuo). These MRI findings have been consistently described in humans and dogs and are considered cardinal signs for neuronal ceroid lipofuscinosis.<sup>10,16–19</sup> The cat in this report also showed moderate meningeal thickening. This finding, not described in the human form of the disease, was also reported in three Chihuahuas and a Dachshund with neuronal ceroid lipofuscinosis.<sup>9,20</sup> An autoimmune cause of meningeal thickening has been alluded to; however, in the case of the Dachshund, a subdural haematoma was also identified and the findings of thickened meninges could represent reactive meningitis. In our case, the moderate meningeal thickening was due to the diffuse moderate hypertrophy and fibrosis, and could be interpreted as an adaptive change due to brain atrophy.





**Figure 3** (a) Gross appearance of fresh cross section of the brain at the level of the hippocampus showing moderate atrophy with widening of sulci. (b) Hippocampus, cornu ammonis with pyramidal neurons (arrows) showing intracytoplasmic botryoid deposits of eosinophilic glassy material often associated with marginalisation of nuclei (inset). (c–e) Intracytoplasmic deposits are markedly positive to (c) Luxol fast blue, (d) moderately positive to periodic acid–Schiff stain and (e) red stained with Masson's trichrome stain. (f) Pyramidal neurons show green autofluorescence when observed under the fluorescent microscope (excitation 465–495 nm). (g–i) Transmission electron microscopy of occipital cortical neurons showing (g) membrane-bound material composed of (h) small curvilinear lamellar stacks and (i) electron-dense variably sized granular material morphologically consistent with lipofuscins

Diffuse T2W white matter hyperintensity with reduction in the white/grey matter distinction has not been previously described in the veterinary literature. A possible explanation for this could be that animals previously reported were scanned with lower field strength MRI magnets. Better contrast resolution of higher field magnets and newer MRI systems could account for this new finding. In humans, periventricular white matter T2W hyperintensity is a common finding in neuronal ceroid lipofuscinosis, confirmed as gliosis and demyelination on histology. In one study, the authors also described a diffuse increase in T2W signal intensity of the white matter.<sup>21</sup> Our patient showed a thinned and partially visualised corpus callosum, which, in this case, likely resulted from the generalised brain atrophy. Atrophy of the

corpus callosum has also been described in dogs and humans with neuronal ceroid lipofuscinosis.<sup>18,22</sup> The cat in our report had generalised calvarial hyperostosis. No skeletal abnormality has been previously described in the human or animal form of the disease. We believe calvarial hyperostosis developed in response to the chronic ex vacuo negative pressure induced by the brain cortical atrophy. Gross and histopathological findings were consistent with previous cases of neuronal ceroid lipofuscinosis in cats,<sup>1–4</sup> and confirmed the presence of lysosomal storage neuronal disease with autofluorescent material. TEM showed the presence of characteristic small curvilinear lamellar stacks and electron-dense granular material, consistent morphologically with previously described intra-neuronal lipofuscins in cats, making the diagnosis

of neuronal ceroid lipofuscinosis highly likely in this case. Ultrastructural intraneuronal deposits consistent with lipofuscins in cats have been described as granular osmophilic deposits (electron-dense granules), curved lamellar stacks and fingerprint profiles, although this latter, ultrastructural organisation was not observed in our case.

The cat in this case, and those reported in previous studies,<sup>1,2,11</sup> presented with neurological features in common with neuronal ceroid lipofuscinosis seen in other species, including humans. Initial manifestations of neuronal ceroid lipofuscinosis in humans occur typically between birth and young adulthood. This is mirrored in dogs and cats, with most reported cases presenting under 2 years of age, as seen in this cat. A case series of feline neuronal ceroid lipofuscinosis in three cats reported disorientation, focal (facial twitching) and generalised epileptic seizures, tactile hyperaesthesia and blindness; signs seen in this cat.<sup>4</sup> Similar signs are seen in humans, with a combination of retinopathy, dementia and epilepsy almost always being present.<sup>23</sup> In this case no lesions were observed bilaterally in the retina and therefore the blindness reported in this cat was likely central in origin.

To date, 14 different genes have been implemented in the development of the human form of neuronal ceroid lipofuscinosis (*CLN1–CLN14*). Traditionally and still commonly encountered in the literature, nomenclature was based on the age of clinical presentation, for example infantile/juvenile/adult. The storage material, along with its ultrastructure, is variable for each neuronal ceroid lipofuscinosis type, and, although similar, the clinical course is slightly altered for each one. Molecular analysis has identified the genetic loci for the neuronal ceroid lipofuscinosis types in humans, with the exception of the *CLN9* gene, which remains elusive.<sup>23</sup> The differences in the mutations account for the variable phenotypes between the types.<sup>24</sup> Mutations in nine different genes have been identified in dogs, eight of which are orthologues to the human causative mutations.<sup>23,25–28</sup> Sequencing of the exons of *CLN1*, *CLN3*, *CLN5*, *CLN8* and *CLN10* in a confirmed case of feline neuronal ceroid lipofuscinosis failed to identify the molecular cause in that patient.<sup>4</sup> The genes involved in the development of feline neuronal ceroid lipofuscinosis remain unidentified.

In humans and dogs, neuronal ceroid lipofuscinosis has been shown to be a recessively inherited disease with the progeny of two carrier parents having a one in four chance of developing the disease.<sup>14</sup> A second cat, from the same litter as the cat in this case, developed similar clinical signs 4 weeks after its littermate and was euthanased owing to severity of clinical signs. Histopathology and TEM confirmed neuronal ceroid lipofuscinosis in this second cat with central nervous system morphological changes similar to the cat

described in this case. MRI was not performed in this second case, but pathological findings and the relationship between the two littermates reinforce the hypothesis of an inherited mutation in cats.<sup>3</sup>

## Conclusions

Without knowledge of the causative genes involved in feline neuronal ceroid lipofuscinosis, definitive diagnosis is based on necropsy and histopathology results alone. MRI findings, combined with clinical signs, are the mainstay of the ante-mortem presumptive diagnosis. To support the use of this imaging modality in the ante-mortem diagnosis of feline neuronal ceroid lipofuscinosis, recruitment of more feline subjects with confirmed disease into similar descriptive studies is essential in identifying distinct MRI findings within this population. Owing to the similarities in the MRI findings in this cat and those seen in humans and dogs it could be assumed that the imaging features would be the same or similar in other cases of feline neuronal ceroid lipofuscinosis. It would seem prudent, therefore, to consider neuronal ceroid lipofuscinosis within the list of differentials when faced with a cat showing similar neurological signs as our case, with evidence of generalised cerebral and cerebellar atrophy and diffuse T2W hyperintensity of the white matter on MRI.

**Conflict of interest** The authors declared no potential conflicts of interest with respect to the research, authorship, and/or publication of this article.

**Funding** The authors received no financial support for the research, authorship, and/or publication of this article.

## References

- 1 Weissenbeck H and Rossel C. **Neuronal ceroid-lipofuscinosis in a domestic cat: clinical, morphological and immunohistochemical findings.** *J Comp Pathol* 1997; 117: 17–24.
- 2 Kuwamura M, Nakagawa M, Nabe M, et al. **Neuronal ceroid-lipofuscinosis in a Japanese domestic shorthair cat.** *J Vet Med Sci* 2009; 71: 665–667.
- 3 Furusawa Y, Mizukami K, Yabuki A, et al. **Mutational analysis of the feline *CLN3* gene and an ultrastructural evaluation of lysosomal storage material in a cat with neuronal ceroid lipofuscinosis: an investigation into the molecular basis of the disease.** *Vet J* 2012; 194: 425–428.
- 4 Chalkley MD, Armien AG, Gilliam DH, et al. **Characterization of neuronal ceroid-lipofuscinosis in 3 cats.** *Vet Pathol* 2014; 51: 796–804.
- 5 Kohlschutter A and Schulz A. **Towards understanding the neuronal ceroid lipofuscinoses.** *Brain Dev* 2009; 31: 499–502.
- 6 Tammen I, Houweling PJ, Frugier T, et al. **A missense mutation (c. 184C>T) in ovine *CLN6* causes neuronal ceroid lipofuscinosis in Merino sheep whereas affected South Hampshire sheep have reduced levels of *CLN6* mRNA.** *Acta Biochim Biophys* 2006; 1762: 898–905.
- 7 Fiske RA and Storts RW. **Neuronal ceroid-lipofuscinosis in Nubian goats.** *Vet Pathol* 1988; 25: 173–174.

- 8 Harper PA, Walker KH, Healy PJ, et al. **Neurovisceral ceroid lipofuscinosis in blind Devon cattle.** *Acta Neuropathol* 1988; 75: 632–636.
- 9 Nakamoto Y, Yamato O, Uchida K, et al. **Neuronal ceroid-lipofuscinosis in longhaired Chihuahuas: clinical, pathological, and MRI findings.** *J Am Anim Hosp Assoc* 2011; 47: 4.
- 10 O'Brien DP and Katz ML. **Neuronal ceroid lipofuscinosis in 3 Australian shepherd littermates.** *J Vet Intern Med* 2008; 22: 472–475.
- 11 Bildfell R, Matwichuk C, Mitchell S, et al. **Neuronal ceroid-lipofuscinosis in a cat.** *Vet Pathol* 1995; 32: 485–488.
- 12 Bronson RT, Lake BD, Cook S, et al. **Motor neuron degeneration of mice is a model of neuronal ceroid lipofuscinosis (Battens's disease).** *Ann Neurol* 1993; 33: 381–385.
- 13 Jasty V, Kowalski RL, Fonseca EH, et al. **An unusual case of generalized ceroid-lipofuscinosis in a *Cynomolgus* monkey.** *Vet Pathol* 1984; 21: 46–50.
- 14 Bennett M and Rakheja D. **The neuronal ceroid-lipofuscinoses.** *Dev Disabil Res Rev* 2013; 17: 254–259.
- 15 Katza ML, Rustad E, Robinson GO, et al. **Canine neuronal ceroid lipofuscinosis: a promising model for preclinical testing of therapeutic interventions.** *Neurobiol Dis* 2017; 108: 277–287.
- 16 Jarvela I, Autti T, Lamminranta S, et al. **Clinical and magnetic resonance imaging findings in Batten disease: analysis of the major mutation (1.02-kb deletion).** *Ann Neurol* 1997; 42: 799–802.
- 17 D'Incerti L. **MRI in neuronal ceroid lipofuscinosis.** *Neurol Sci* 2000; 21: S71–S73.
- 18 Autti T, Ranininko R, Vanhanen SL, et al. **MRI of neuronal ceroid lipofuscinosis.** *Neuroradiol* 1996; 38: 476–482.
- 19 Koie H, Shibuya H, Sato T, et al. **Magnetic resonance of neuronal ceroid lipofuscinosis in a Border collie.** *J Vet Med Sci* 2004; 66: 1453–1456.
- 20 Asakawa M, G, Mackillop E, Olby NJ, et al. **Neuronal ceroid lipofuscinosis with a chronic subdural hematoma.** *Vet Radiol Ultrasound* 2010; 51: 155–158.
- 21 Rieger D, Auerbach S, Robinson P, et al. **Neuroimaging of lipid storage disorders.** *Dev Disabil Res Rev* 2013; 17: 269–282.
- 22 Hasegawa D, Tamura S, Nakamoto Y, et al. **Magnetic resonance findings of the corpus callosum in canine and feline lysosomal storage diseases.** *PLoS One* 2013; 8: 12.
- 23 Nita DA, Mole SE and Minassian BA. **Neuronal ceroid lipofuscinoses.** *Epileptic Disord* 2016; 18 Suppl 2: S73–S88.
- 24 Mole SE, Williams RE and Goebel HH. **Correlations between genotype, ultrastructural morphology and clinical phenotype in neuronal ceroid lipofuscinoses.** *Neurogenetics* 2005; 6: 107–126.
- 25 Sanders DN, Farias FH, Johnson GS, et al. **A mutation in canine PPT1 causes early onset neuronal ceroid lipofuscinosis in a Dachshund.** *Mol Genet Metab* 2010; 100: 349–356.
- 26 Melville SA, Wilson CL, Chiang CS, et al. **A mutation in canine CLN5 causes neuronal ceroid lipofuscinosis in Border collie dogs.** *Genomics* 2005; 86: 287–294.
- 27 Katz ML, Khan S, Awano T, et al. **A mutation in the CLN8 gene in English Setter dogs with neuronal ceroid lipofuscinosis.** *Biochem Biophys Res Commun* 2005; 327: 541–547.
- 28 Wohlke A, Philipp U, Bock P, et al. **A one base pair deletion in the canine ATP13A2 gene causes exon skipping and late-onset neuronal ceroid lipofuscinosis in the Tibetan terrier.** *PLoS One* 2001; 7: 10.