

Cervicofacial Emphysema and Pneumomediastinum Following Dental Extraction: Case Report

Nargess Afzali ¹, MD; Abdolreza Malek*², MD, and Amir Hossein Hashemi Attar¹, MD

1. Department of Radiology, Faculty of Medicine, Islamic Azad University of Mashhad Branch, Mashhad, Iran
2. Department of Pediatrics, Faculty of Medicine, Islamic Azad University of Mashhad Branch, Mashhad, Iran

Received: Feb 09, 2010; Final Revision: Jun 17, 2010; Accepted: Jul 23, 2010

Abstract

Background: Pneumomediastinum is commonly caused by iatrogenic injury such as surgery on the cervical planes and chest or by tracheostomy. It is also well known that emphysema may occur after dental treatments using an air turbine drill, but there have been few cases of emphysema which extended to the mediastinum.

Case Presentation: A 16-year-old boy is presented with subcutaneous emphysema and pneumomediastinum which developed 24 hours after surgery for extraction of an inferior second molar. We first describe history, clinical presentation and radiologic appearance of our patient and then review the literature about oral surgery causing pneumomediastinum.

Conclusion: Surgical procedures in oral cavity can lead to the development of emphysema and pneumomediastinum when air turbine dental drills are used. To avoid these complications, air turbine high speed drills should be used only in necessary cases.

Iranian Journal of Pediatrics, Volume 21 (Number 2), June 2011, Pages: 253-255

Key Words: Pneumomediastinum; Subcutaneous Emphysema; Dental Extraction; Oral Surgery

Introduction

Pneumomediastinum is an uncommon event that occurs when air leaks from any part of the lung or airways into the mediastinum^[1]. The condition can be caused by a traumatic injury or by increased pressure within the lungs or airways such as excessive coughing, vomiting, or repeated bearing down to increase abdominal pressure during delivery or severe constipation^[1]. Spontaneous pneumomediastinum may also complicate

obstructive airway processes such as asthma or foreign bodies^[2]. Subsequently, air along the connective tissue planes and vascular sheaths rises up to the communicating cervical spaces, producing subcutaneous cervical emphysema in 70 to 90% of cases^[3]. In 31% of cases, it has no known precipitating cause^[3].

Pneumomediastinum following cervicofacial emphysema is rare^[4,5]. It has been reported in the literature that after dental extractions, head and neck surgery, or trauma, the air passes from the

* Corresponding Author;

Address: Department of Pediatrics, 22Bahman Hospital, Fajr freeway, Mashhad, Iran

E-mail: armalek2005@yahoo.com

air-filled spaces of the head (oral, nasal, and pharyngeal cavities) through the neck down to the mediastinum^[6].

Case Presentation

A 16-year-old boy is presented complaining of sudden cervicofacial swelling, fever, dyspnea and chest pain one day after dental surgery for an inferior left second molar. During physical examination crepitation and swelling were found in periorbital, cervical and thoracic regions due to subcutaneous emphysema. The patient had no previous heart or lung problems.

There was no evidence of airway obstruction or respiratory distress. At the time of admission vital signs were normal and O₂ saturation was 98%. White blood cell count revealed leukocytosis and neutrophilia (21000 cells and 84% neutrophils). Chest x-ray showed subcutaneous emphysema in the cervicofacial, thoracic, and axillary regions with no evidence of rib fracture. Pneumomediastinum is seen as a small amount of air adjacent to the aortic arc (Fig. 1a, 1b). Thoracic CT scan revealed air in the subcutaneous and cervical spaces extending to the mediastinum. Conservative treatment consisted of intravenous antibiotic therapy with Clindamycin, Ceftriaxone and bed rest but no oral feeding. In the next days

the swelling resolved and control CXR showed a decrease in surgical emphysema and resolution of pneumomediastinum. After five days the patient was discharged. Two days after being discharged, physical examination and chest x-ray were normal. For the next 3 weeks, the patient was examined weekly and no problems were found.

Discussion

Spontaneous pneumomediastinum is usually seen in healthy young men or parturient women resulting from the rupture of peripheral pulmonary alveoli due to sudden increase of intra-alveolar pressure after exaggerated Valsalva maneuver^[1,7]. Pneumomediastinum following cervicofacial emphysema is very rare and has been reported after dental surgical procedures, head and neck surgery, or orofacial trauma ^[8-10]. Air compression during a dental extraction can cause air to be forced down to the mediastinum ^[5]. Arai et al in 2009 presented a rare case in which subcutaneous emphysema and pneumomediastinum developed probably due to extraction of a mandibular third molar, and were found incidentally on the day after the dental procedure ^[11]. Sekine and co-workers in 2000 reported a case of bilateral pneumothorax with extensive subcutaneous emphysema in a 45-year-old man

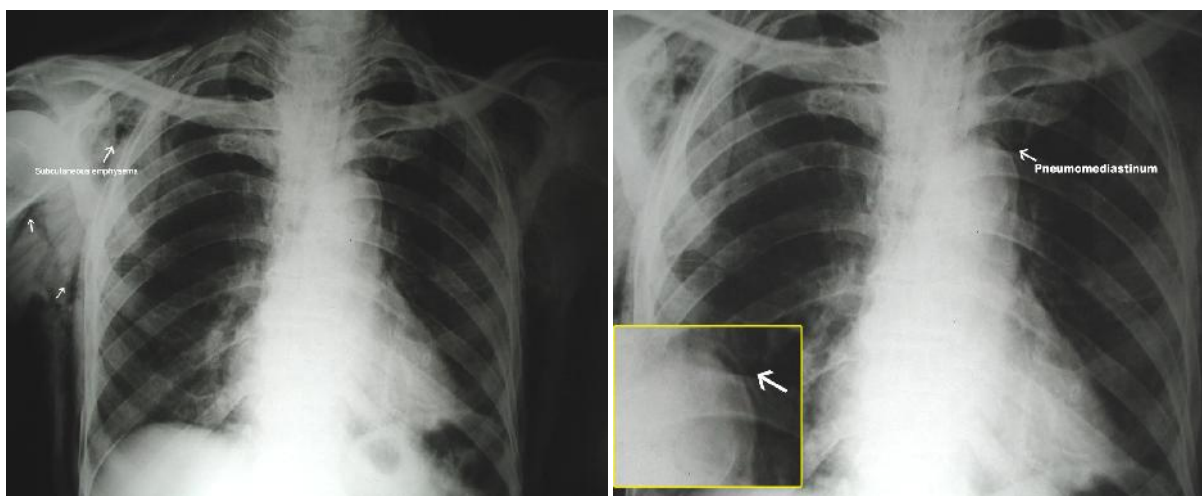


Fig. 1: Subcutaneous emphysema in the cervicofacial, thoracic, and axillary regions with no evidence of rib fracture (**Left**) and Pneumomediastinum is seen as a small amount of air adjacent to the aortic arc (**Right**)

that occurred during surgery to extract the left lower third molar^[12]. In the above mentioned cases as in our case, the inferior third molar was extracted with an air turbine dental handpiece.

Self induced injury within the oral cavity can also cause cervicofacial emphysema and pneumomediastinum^[6]. López-Peláez et al in 2001 presented four cases of subcutaneous emphysema and pneumomediastinum after self-induced punctures in the oral cavity in four young men from the same center. Two of them also had pneumothorax revealed by chest radiography and CT^[6].

The roots of the first, second, and third molars communicate directly with the sublingual and submandibular spaces^[1,7,8]. These communicate with the pterygomandibular, parapharyngeal and retropharyngeal spaces, the latter with the mediastinum^[11]. In our case, injection of air with a high speed dental drill through the soft tissue adjacent to the roots of the inferior molar seemed to cause cervicofacial emphysema leading to pneumomediastinum. Medical literature also supports this as the most probable etiology^[10-14].

Conclusion

Surgical procedures in oral cavity or extraction of lower molars especially the third inferior molar can lead to development of emphysema and pneumomediastinum when air turbine dental drills are used^[11,12,15]. To avoid these complications, air turbine drills should be used only in necessary cases.

References

1. Maunder RJ, Pierson DJ, Hudson LD. Subcutaneous and mediastinal emphysema: pathophysiology, diagnosis and management. *Arch Intern Med* 1984;144(7):1447-53.
2. Dean LM. Pneumomediastinum in an unusual location. *AJR Am J Roentgenol* 1992;159(4):900-1.
3. Vidal F, Gonzalez J, Nualart L, et al. Spontaneous pneumomediastinum in adults: presentation of 13 cases and review of the literature. *Med Clin (Barc)* 1984;82(18):797-802.
4. Horowitz I, Hirshberg A, Freedman A. Pneumomediastinum and emphysema following surgical extraction of mandibular third molars: three case reports. *Oral Surg* 1987;63(1):25-8.
5. Torres-Melero J, Arias-Díaz J, Balibrea JL. Pneumomediastinum secondary to use of high speed turbine drill during a dental extraction. *Thorax* 1996;51(3):339-40.
6. López-Peláez MF, Roldán J, Mateo S. Cervical emphysema, pneumomediastinum, and pneumothorax following self-induced oral injury. *Chest* 2001;120(1):306-9.
7. Bremner WG, Kumar CM. Delayed surgical emphysema, pneumomediastinum and bilateral pneumothoraces after postoperative vomiting. *Br J Anaesth* 1993;71(2):296-7.
8. Mather AJ, Stoykewych AA, Curran JB. Cervicofacial and mediastinal emphysema complicating a dental procedure. *J Can Dent Assoc* 2006;72(6):565-8.
9. Chung IH, Moon HJ, Suh JD, et al. Interesting case: cervicofacial emphysema and mediastinitis following restorative dental treatment -- a case report. *Br J Oral Maxillofac Surg* 2006;44(5):376.
10. Stanton DC, Balasarian E, Yepes JF. Subcutaneous cervicofacial emphysema and pneumomediastinum: a rare complication after a crown preparation. *Gen Dent* 2005;53(2):122-4.
11. Arai I, Aoki T, Yamazaki H, et al. Pneumomediastinum and subcutaneous emphysema after dental extraction detected incidentally by regular medical checkup: a case report. *Oral Surg Oral Med Oral Pathol Oral Radiol Endod.* 2009;107(4):33-8.
12. Sekine J, Irie A, Dotsu H, et al. Bilateral pneumothorax with extensive subcutaneous emphysema manifested during third molar surgery. A case report. *Int J Oral Maxillofac Surg* 2000;29(5):355-7.
13. Shackelford D, Casani JAP. Diffuse subcutaneous emphysema, pneumomediastinum and pneumothorax after dental extraction. *Ann Emerg Med* 1993;22(2):248-50.
14. Ely EW, Stump TE, Hudspeth AS, et al. Thoracic complications of dental surgical procedures: Hazards of the dental drill. *Am J Med* 1993;95(5):456-65.
15. Monsour PA, Savage NW. Cervicofacial emphysema following dental procedures. *Aus Dent J* 1989;34(5):403-6.