

Breast Pseudoaneurysm in a Woman after Core Biopsy: Intravascular Glue Embolization

Jeong Ho Kim¹, Su Joa Ahn^{1*}, Sang Yu Nam¹, Yunyeong Kim², Yong Soon Chun², Heung Kyu Park², Hye Young Choi¹

¹Department of Radiology, Gil Medical Center of Gachon University, Namdong-Gu, Incheon, Republic of Korea, ²Department of Surgery, Breast Cancer Center, Gil Medical Center of Gachon University, Namdong-Gu, Incheon, Republic of Korea

Abstract

Core needle biopsy of breast masses is a common procedure for tissue diagnosis of breast lesions. The incidence of complications is low, with pseudoaneurysm (PA) after core biopsy has been described in the literature, and the subsequent need for surgical management. Ultrasonography is the most common modality used for not only diagnosis but also treatment of a PA. Color Doppler images show a heterogeneous echoic lesion with whirling flow inside of the lesion. We describe a patient whose breast PA that developed after core needle biopsy was successfully treated with sonographically-guided intravascular glue embolization.

Keywords: Breast pseudoaneurysm, embolization, glue, ultrasound-guided Introduction

INTRODUCTION

Ultrasonography (US)-guided core needle biopsy has become an important and useful technique for the diagnosis of focal breast lesions. This procedure is highly reproducible, accurate, easily performed, and is considered an alternative to surgical biopsy.^[1] The incidence of complications is very low, and most frequent complication is hematoma. Pseudoaneurysm (PA) after core biopsy has been reported in the previous studies,^[2,3] and most patients with this condition treated with surgery. We describe a patient whose breast PA that developed after core needle biopsy was treated with intravascular glue embolization.

CASE REPORT

A 32-year-old woman visited our medical center with a small palpable nodule in the right upper outer quadrant of her breast. She had no history of previous breast surgery, familial breast cancer, underlying disease, or anticoagulation therapy. Findings on US revealed an irregular shape indistinct margin, hypoechoic nodule with increased vascularity measuring 17 mm; in her right breast at the 9-o'clock position [Figure 1a]. This lesion was classified as BI-RADS category 4C (high level of suspicion for malignancy). US-guided core needle biopsy was performed by an experienced surgeon using a 14-gauge

needle [Figure 1b]. Small bleeding was observed immediately after the procedure, but was resolved with focus compression for approximately 25 min. The histologic diagnosis was granulomatous mastitis.

Two weeks later, she visited the hospital complaining of enlarged mass, skin ecchymosis, severe pain, and tenderness in the biopsy area. US revealed a large hematoma (4 cm) with heterogeneous reflectivity and an anechoic center [Figure 2a], adjacent to the previously noted solid lesion. A color Doppler image revealed whirling flow in hematoma [Figure 2b], and iatrogenic PA was diagnosed.

First of all, the clinician performed the US-guided compression for more than an hour, but there was no reduction in size. After that percutaneous ethanol injection was implemented for treating the PA. A 0.8 mL absolute ethanol (Merck KGaA, Darmstadt, Germany) was injected within blood space using a fine needle (23 gauge) under US guidance. Although the patient was treated with focused compression and percutaneous ethanol injections, the hematoma with PA continued to increase

Address for correspondence: Dr. Su Joa Ahn,

Department of Radiology and Institute of Radiation Medicine, Gil Medical Center of Gachon University, 24 Namdong-Daero, 774-Beon-Gil, Namdong-Gu, Incheon, Republic of Korea.
E-mail: joa0827@gmail.com

Received: 12-08-2021 Revised: 16-12-2021 Accepted: 07-03-2022 Available Online: 19-07-2022

Access this article online

Quick Response Code:



Website:
<https://journals.lww.com/jmut>

DOI:
10.4103/jmu.jmu_168_21

This is an open access journal, and articles are distributed under the terms of the Creative Commons Attribution-NonCommercial-ShareAlike 4.0 License, which allows others to remix, tweak, and build upon the work non-commercially, as long as appropriate credit is given and the new creations are licensed under the identical terms.

For reprints contact: WKHLRPMedknow_reprints@wolterskluwer.com

How to cite this article: Kim JH, Ahn SJ, Nam SY, Kim Y, Chun YS, Park HK, *et al.* Breast pseudoaneurysm in a woman after core biopsy: Intravascular glue embolization. *J Med Ultrasound* 2023;31:147-9.

in size (5 cm). The surgeon and radiologist decided to try the embolization first before performing the surgery. An intervention procedure was conducted using a 5 Fr H1 (Cook, Bloomington, IN, USA) catheter inserted into the right subclavian artery, and a selective scan of the right lateral thoracic artery showed a large PA in the distal branch of this artery [Figure 3a]. The PA was successfully embolized using the 25% glue-lipiodol mixture (1:3) after superselection with microcatheter. Moreover, additional tiny contrast extravasation also noted on the right internal mammary arteriogram [Figure 3b]. Using gelfoam, embolization was performed on the lesion. The follow-up color Doppler US showed a totally thrombosed hematoma that had regressed in size. At the 2-week follow-up US, the patient has only a small hematoma left without pain [Figure 4a]. The pathologic confirmed granulomatous mastitis has been partially reduced in size after the prednisone treatment [Figure 4b].

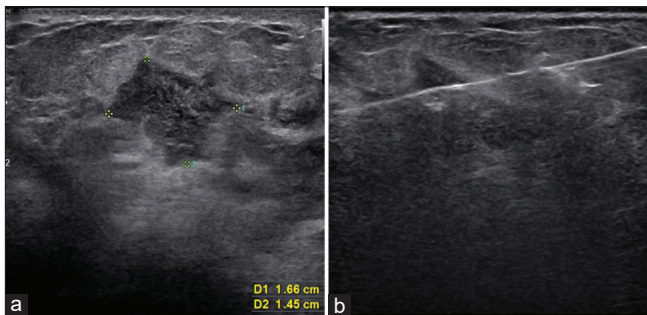


Figure 1: The initial transverse ultrasonography shows an irregular shape hypoechoic nodule with an indistinct margin in the right breast at the 9-o'clock position. (a) and ultrasonography-guided biopsy was performed with 14-gauge needle (b)

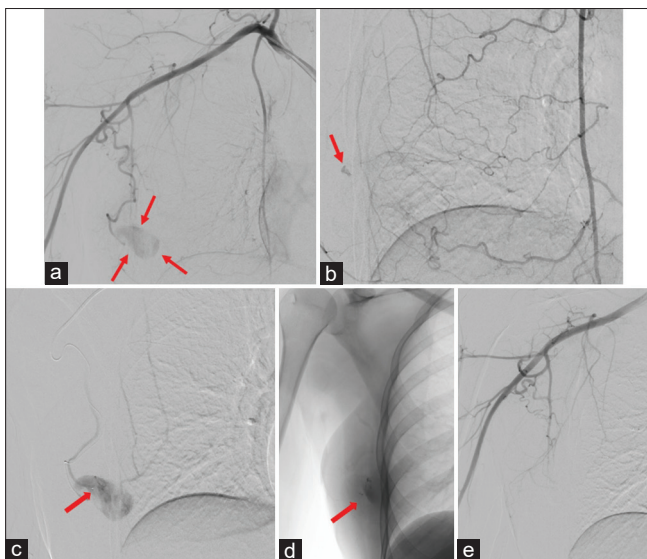


Figure 3: Digital subtraction angiogram shows a large pseudoaneurysm of the right lateral thoracic artery. (a) and additional small contrast extravasation of the right internal mammary artery. (b). We performed embolization after superselection of the right lateral thoracic artery (arrow on catheter tip). The angiogram after glue embolization, glue retention was visualized. (c,d) and disappeared of pseudoaneurysm. (e)

DISCUSSION

PA is an uncommon complication of traumatic vascular injury. It results from an injury in all three layers of an arterial vessel wall, with subsequent blood collection in adjacent tissue. It usually presents as a pulsatile, tender, and painful mass on physical examination. PA can be diagnosed by US with color Doppler imaging when arterial turbulent flow is observed within the lesion. Because PA with hematoma presents as a complex echoic lesion, gray-scale US cannot reliably differentiate PA from postprocedure hematoma. The diagnosis of PA is easily performed by color flow Doppler US, with an accuracy of more than 95%.^[4] Color Doppler US shows the presence of a whirling blood flow within the mass, which is connected with adjacent vessel tract.

The increasing use of US-guided biopsy in the evaluation of focal breast lesions may have resulted in an increased incidence of complications such as hematoma and PA. This complication can occur regardless of the experience and skills of the operator.^[5] Before performance of a core needle breast biopsy, color Doppler image of the lesion itself and around breast tissue of the lesion for the identification of vessels may be helpful for the avoidance of complications such as postprocedure bleeding, PA.^[6]

Most PAs are small in size and spontaneously thrombose that improve without clinician recognition.^[5,7] The prognosis of untreated PA is not exactly established, but surgical repair has been the standard management. However, several reports have demonstrated that treatment options of PA include US-guided focused compression, thrombin or ethanol injection, percutaneous intervention, and open surgical repair.^[2,8] More detailed advantages and disadvantages of each treatment option were summarized in Table 1.

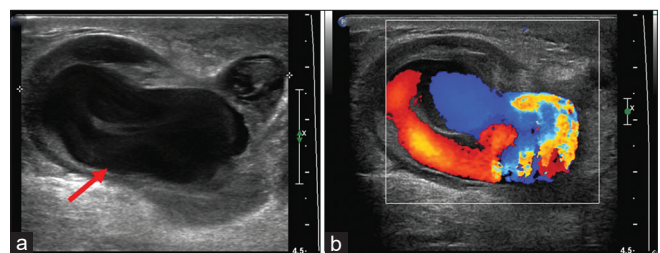


Figure 2: Follow-up transverse (a) and color Doppler (b) US after the biopsy show a complex echoic lesion with an anechoic center (arrow) and whirling blood flow in the lesion

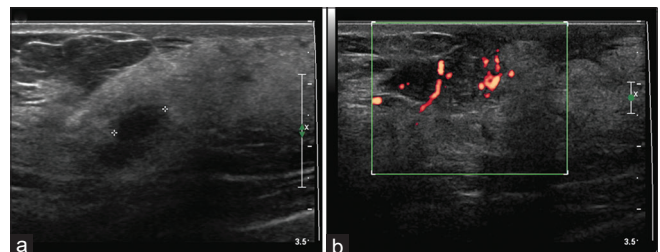


Figure 4: Follow-up transverse ultrasonography 2 weeks after the embolization shows residual small hematoma (a) with decreased size of pathologic confirmed granulomatous mastitis (b)

Table 1: Characteristics of treatment options

Treatment options	Advantages	Disadvantages
US-guided focused compression	No invasiveness Lower chance of occlusion of the native vessel No risk of the side effects associated with the systemic injection of thrombin	Not be successful if the neck is too wide Very time-consuming if multiple attempts are needed May be painful for the patient
Thrombin or ethanol injection	Less discomfort to the patient Less time compared to other methods	High recurrence rate
Endovascular coil embolization	Proceed without general anesthesia	Need for a large number of coils for complete occlusion and increased cost Possibility of PSA rupture Possibility of migration of coils peripherally, causing peripheral embolization
Endovascular glue embolization	Proceed without general anesthesia Cost-effective than coil embolization	Glue migration Catheter entrap
Open surgical repair	Last treatment option when other options fail	Increased time and cost Requirement for general anesthesia

PSA: Prostate-specific antigen, US: Ultrasonography

There were only several cases of breast PA treated with percutaneous embolization.^[9,10] Moreover, most cases involve the use of coil embolization. To our knowledge, our case is the only case used gelfoam and glue for the treatment of breast PA. The use of glue for embolization leads to less radiation, safe and lower recurrence rates than the coil embolization.^[11] Furthermore, embolization with glue is cost-effective, resulting in more than 3 times cheaper than embolization using any plug or detachable coil. Glue embolization also has widely known disadvantages such as glue migration and catheter entrap, but these complications rarely occur when the glue embolization was performed by radiologists with considerable experience in the use of tissue adhesives such as glue.

CONCLUSION

More frequent follow-up should not be recommended because PA after core needle biopsy is rare and not affected to mortality. However, there is a possibility of occurrence, which requires additional treatment or hospitalization, so sufficient explanation is essential for patients before the procedure. Moreover, a clinically evident PA must be treated because its evolution is still unknown. Several factors, such as the size, invasiveness, and cost should be considered in choosing treatment.

Intravascular embolization is an effective treatment option that can be tried before the surgery for PA, which is large in size and not completely thrombosed by US-guided focus compression, ethanol, or thrombin injection. Glue embolization is economic, simple, without complications, and efficient, especially if radiologists have experience in the use of tissue adhesive.

Informed consent

Requirements for informed consent were waived due to the retrospective nature of the study.

Financial support and sponsorship

Nil.

Conflicts of interest

There are no conflicts of interest.

REFERENCES

- Parker SH, Burbank F, Jackman RJ, Aucreman CJ, Cardenosa G, Cink TM, *et al.* Percutaneous large-core breast biopsy: A multi-institutional study. *Radiology* 1994;193:359-64.
- Bazzocchi M, Francescutti GE, Zuiani C, Del Frate C, Londero V. Breast pseudoaneurysm in a woman after core biopsy: Percutaneous treatment with alcohol. *AJR Am J Roentgenol* 2002;179:696-8.
- McNamara MP Jr., Boden T. Pseudoaneurysm of the breast related to 18-gauge core biopsy: Successful repair using sonographically guided thrombin injection. *AJR Am J Roentgenol* 2002;179:924-6.
- Daunt N. An intramammary pseudoaneurysm presenting as a breast mass. *Australas Radiol* 1995;39:71-2.
- Sasada S, Namoto-Matsubayashi R, Yokoyama G, Takahashi H, Sakai M, Koike K, *et al.* Case report of pseudoaneurysm caused by core needle biopsy of the breast. *Breast Cancer* 2010;17:75-8.
- Lee KH, Ko EY, Han BK, Shin JH, Kang SS, Hahn SY. Thrombosed pseudoaneurysm of the breast after blunt trauma. *J Ultrasound Med* 2009;28:233-8.
- El Khoury M, Mesurolle B, Kao E, Mujoomdar A, Tremblay F. Spontaneous thrombosis of pseudoaneurysm of the breast related to core biopsy. *AJR Am J Roentgenol* 2007;189:W309-11.
- Adler K, Samreen N, Glazebrook KN, Bhatt AA. Imaging features and treatment options for breast pseudoaneurysms after biopsy: A case-based pictorial review. *J Ultrasound Med* 2020;39:181-90.
- Binh NT, Duc NM, Tra My TT, Dung LV, Luu DT, Linh LT. Emergency embolization for breast pseudoaneurysm following vacuum-assisted biopsy: A case report. *Pan Afr Med J* 2021;38:135.
- Ingram AD, Mahoney MC. An overview of breast emergencies and guide to management by interventional radiologists. *Tech Vasc Interv Radiol* 2014;17:55-63.
- Favard N, Moulin M, Fauque P, Bertaut A, Favelier S, Estivalet L, *et al.* Comparison of three different embolic materials for varicocele embolization: Retrospective study of tolerance, radiation and recurrence rate. *Quant Imaging Med Surg* 2015;5:806-14.