



Trauma and Reconstruction

Open Vesicocalicostomy for the Management of Transplant Ureteral Stricture

Margaret M. Higgins^{a,*}, Jonathan P. Walker^a, Michael F. Daily^b, Shubham Gupta^a^a University of Kentucky, Department of Urology, 800 Rose Street, MS283, Lexington, KY 40536-0298, USA^b University of Kentucky, Department of Transplant Surgery, 800 Rose Street, C453, Lexington, KY 40536-0298, USA

ARTICLE INFO

Article history:

Received 17 March 2017

Accepted 23 March 2017

Keywords:

Vesicocalicostomy
Ureteral stricture
Renal transplant
Urological complications
Reconstruction

ABSTRACT

A 59-year-old male developed a proximal stricture of his transplant ureter ten years after a living donor renal transplant. Endoscopic management was unsuccessful, and the patient was temporized with percutaneous nephrostomy tubes for months. Eventually, it became clear he would require surgical revision. Intraoperatively, complete fibrosis of the renal hilum, and intrarenal location of the pelvis precluded the planned pyelovesicostomy. A successful open vesicocalicostomy was performed, anastomosing a bladder flap to a lower pole calix. The patient remains recurrence free after 6 months of follow-up.

© 2017 The Authors. Published by Elsevier Inc. This is an open access article under the CC BY-NC-ND license (<http://creativecommons.org/licenses/by-nc-nd/4.0/>).

Introduction

Urological complications following renal transplant represent a significant area of morbidity for recipients. Ureteric stricture is the most common of these, accounting for up to 50% of urologic complications.¹ The overall incidence of stricture among transplant recipients is estimated between 0.6% and 12.5%.²

Multiple techniques for repairing strictures have been described. Initial approach is usually endoscopic, including retrograde ureteral stent placement, balloon dilation, or percutaneous nephrostomy with stenting.² Commonly described open repairs consist of ureteroneocystostomy or pyelovesicostomy with or without the use of a bladder flap, or ureteroureterostomy with anastomosis of the ipsilateral native ureter to the transplant ureter or pelvis.³

When the traditional avenues of open repair are nonviable, few remaining options have been described in the literature. In the following case report, we describe a successful vesicocalicostomy performed in lieu of the planned pyelovesicostomy.

Case presentation

Our patient is a 59-year-old male with a history of end-stage renal disease secondary to bilateral renal artery stenosis. In 1995, the patient underwent a living donor renal transplant. He did well

for many years. At the end of 2015, the patient was admitted from a transplant clinic follow-up with elevated creatinine of 3.84 mg/dL from his baseline of 1.9 mg/dL. VCUg confirmed reflux into only the distal portion of the transplant ureter. Renal scan was consistent with obstruction. A nephrostomy tube was placed in the transplant kidney and an antegrade nephrostogram was performed and suggestive of a proximal ureteral stricture.

Subsequently, the patient underwent endoscopic evaluation of his transplant ureter, which confirmed a 2 cm proximal ureteral stricture. UroMax™ balloon dilation was performed and an 8.5Fr × 22 cm double J stent was left in place and his nephrostomy tube capped.

Five weeks after dilation, the patient was readmitted with severe AKI, malaise and decreased urine output. His nephrostomy tube was uncapped with resultant high volume output consistent with postobstructive diuresis. His serum creatinine eventually leveled to approximately 2.0 mg/dL. Having now failed endoscopic management of his stricture, the stent was removed and his nephrostomy tube left to gravity drain. Almost 2 months later, a follow-up antegrade nephrostogram was performed in clinic which failed to opacify the bladder or transplant ureter (Fig. 1).

A combined case involving transplant surgery and urology was planned and the patient was taken to the operating room for a planned open pyelovesicostomy. Cystoscopy revealed a normal bladder, but a completely obliterated ureteral opening. The team was unable to cannulate the fibrosed transplant ureter. An infraumbilical midline incision was made. The transplant ureter

* Corresponding author.

E-mail address: margaret.higgins@uky.edu (M.M. Higgins).

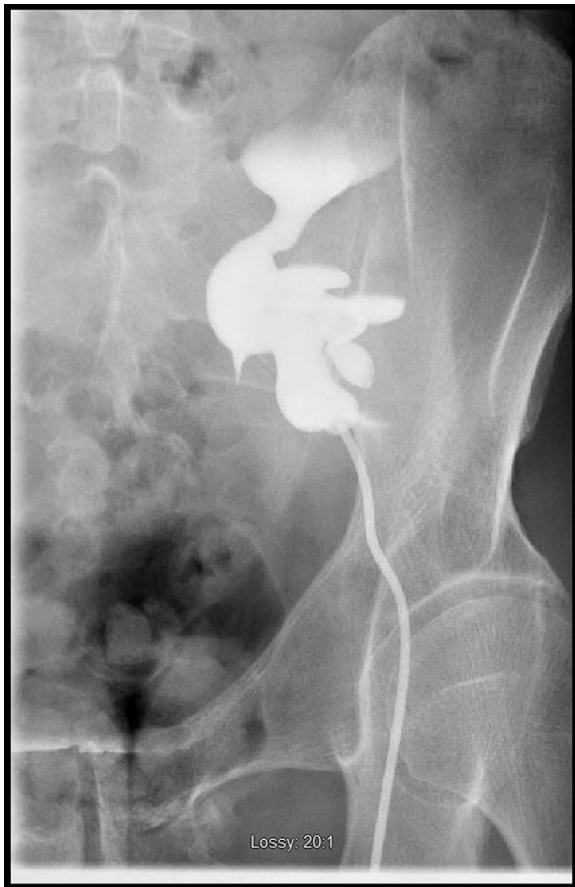

Figure 1. Preoperative antegrade nephrostogram showing complete occlusion of ureter.

was identified and found to have a significant fibrotic rind. Ureterolysis was performed until we had circumferential control of several centimeters of the transplant ureter from just distal to the iliac vessels to the renal pelvis. The ureter itself was partially transected, but no identifiable mucosal lumen was identified. The transplant kidney renal pelvis was found to be predominantly intrarenal. The renal hilum was encased in severe fibrosis, precluding further dissection without placing the vasculature at risk. Given these findings of an inaccessible renal pelvis, consideration was given to vesicocalicostomy.

Intraoperative ultrasound was performed to identify the largest, most dependent renal calyx of the transplant kidney. The bladder was fully mobilized. Bladder elongation flap was created on the anterior bladder wall. A 1 cm circular portion of the lower pole renal cortex was excised. The collecting system was entered with location confirmed with methylene blue injected through the nephrostomy tube. The vesicocalicostomy was then performed by first completing the posterior anastomosis between the lower pole calix mucosa and the mucosa of the bladder elongation flap using interrupted 5-0 polyglactin 910 sutures. Prior to completion of the anterior anastomosis, a ureteral stent was placed. The anterior anastomosis was then completed. The remaining bladder flap and cystostomy were then tubularized in a two-layer running fashion with 4-0 polyglactin 910. A peritoneal flap was harvested and sutured over our anastomosis for additional reinforcement.

The immediate postoperative course was uncomplicated. Cystogram at 4-weeks postop confirmed a freely refluxing anastomosis

and well healed cystorrhaphy. His ureteral stent was removed after 6 weeks and an antegrade nephrostogram at 8 weeks postop demonstrated a patent vesicocalicostomy without recurrent stricture or significant hydronephrosis (Fig. 2). At his 6 month follow-up, the patient was voiding well pleased and with his urinary quality of life. His serum creatinine was 2.2 mg/dL. Renal ultrasound was normal, showing stable pelvocaliectasis.

Discussion

Ureteral strictures represent a significant urological complication in renal transplant patients. When stenting fails to treat these ureteral strictures, open or laparoscopic techniques are employed. The most commonly described repairs are ureteroneovesicostomy directly to bladder or with flap, ureteroureterostomy with allograft or native ureter, or vesicopyelostomy. Repair of native ureteral strictures has even been described using appendicovesicostomy, but never in a transplant kidney.⁵

There is a paucity of literature on using vesicocalicostomy to treat ureteral strictures in transplant recipients. One case report from 1986 describes a successful vesicocalicostomy in a young woman who had severe hydronephrosis due to ureteral stricture early after transplant.⁴ After two unsuccessful attempts at surgical repair, an anastomosis between bladder and lower pole calix was created. At 23-months postop, the patient remained infection free and with only minimal dilation of the pyelocaliceal system.

A second case report from 2013 described a successful laparoscopic-assisted vesicocalicostomy in a native kidney for severe ureteral stricture disease.⁵ Intraoperative ultrasound was employed to identify the lower pole calyx. At 2-year follow-up, the patient was asymptomatic.

Our case study demonstrates a viable option for treatment of transplant ureteral stricture. It highlights the intraoperative flexibility that is necessary for urological reconstruction. Though he is only 6-months postop at this time, the patient is doing well and currently shows no sign of complication.

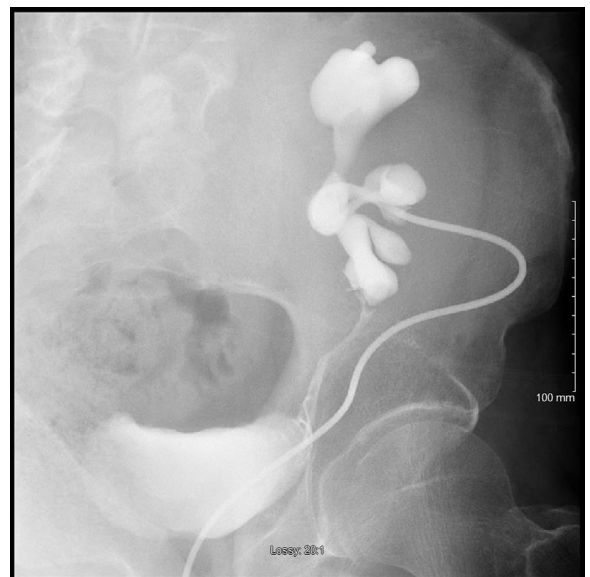


Figure 2. Two-month postoperative antegrade nephrostogram showing patent ureter and appropriate filling of the bladder with contrast.

Conclusion

Vesicocalicostomy is a rarely described option for transplant kidney ureteral stricture. It is appropriate when other standard repairs are not feasible. This should be included in the armamentarium of transplant surgeons and urologists managing kidney transplant complications.

Consent

Verbal consent was obtained from the patient for this case study.

Conflicts of interest

The authors have no conflicts of interest to disclose.

References

1. Krajewski W, Dembowski J, Kolodziej A, et al. Urological complications after renal transplantation – a single centre experience. *Cent Eur J Urol.* 2016;69(3): 306–311.
2. Zavos G, Pappas P, Karatzas T, et al. Urological complications: Analysis and management of 1525 consecutive renal transplantations. *Transpl Proc.* 2008;40(5):1386–1390.
3. Krocak T, Koulack J, McGregor T. Management of complicated ureteric strictures after renal transplantation: case series of pyelovesicostomy with Boari flap. *Transpl Proc.* 2015;47(6):1850–1853.
4. van Son WJ, Hooykaas JA, Slooff MJ, Tegzess AM. Vesicocalicostomy as ultimate solution for recurrent urological complications after cadaveric renal transplantation in a patient with poor bladder function. *J Urol.* 1986;136(4): 889–891.
5. Diaz EC, Susan S, Patel NS, et al. Laparoscopic-assisted vesicocalicostomy for severe pelvi-ureteral stricture disease. *JSLs.* 2013;17(3):468–470.