

Diaphragmatic Rupture Secondary to Blunt Thoracic Trauma

Alexander J. Scumpia, DO, MSc*

Daniel A. Aronovich, DO*

Loredana Roman, BS[†]

Vanitha Vasudevan, MD[‡]

Ryan M. Shadis, MD[‡]

Mauricio Lynn, MD[‡]

*Mount Sinai Medical Center, Department of Emergency Medicine, Miami, Florida

[†]Victor Babes University of Medicine and Pharmacy, Department of Medicine, Timisoara, Romania

[‡]Ryder Trauma Center, Department of Surgery, Jackson Memorial Health System, Miami, Florida

Supervising Section Editor: Sean Henderson, MD

Submission history: Submitted January 6, 2013; Revision received January 28, 2013; Accepted April 22, 2013

Full text available through open access at http://escholarship.org/uc/uciem_westjem

DOI: 10.5811/westjem.2013.4.15826

[West J Emerg Med. 2013;14(5):435–436.]

We present a case of a 71-year-old male that was involved in a high-speed motor vehicle collision, as an unrestrained back seat passenger. On primary survey, decreased breath sounds and bowel sounds were auscultated in the left thorax. Secondary survey was positive for left anterior chest wall tenderness. Chest radiograph demonstrated multiple rib fractures, hemothorax, and diaphragmatic rupture with herniation of bowel loops into the chest cavity (Figure 1). Upon insertion of a nasogastric tube, repeat radiograph demonstrated the nasogastric tube to be in the left upper abdomen (Figure 2). The patient underwent emergency laparotomy for repair of his injury. Incidentally, a splenic laceration was identified intraoperatively. Successful repair of the diaphragmatic injury as well as splenectomy was achieved.

DISCUSSION

Diaphragmatic rupture is a relatively rare injury with a reported incidence of 1 to 7% of all patients following significant blunt trauma.¹ In a review of 1589 patients, Asensio et al² reported that 75% had left sided injuries, 23% had right-sided injuries, and 2% had bilateral injuries. This preponderance for left-sided injuries is thought to be related to the protective effect of the bare area of the liver in contact with the diaphragm in the right thorax.³ The pathophysiology in blunt trauma is due to the abrupt change in intraabdominal pressure that is thought to cause the majority of injuries, although shearing and/or avulsion can also occur especially following lateral trauma.⁴ The differential includes: pneumothorax, hemothorax, liver injury, bowel injury, rib fractures, splenic injury and kidney injury. Radiographically, the diagnosis is made via chest radiograph demonstrating: nasogastric tube in the chest, herniated loops of bowel within the chest, with or without focal constriction of the viscus.⁴ The gold standard of treatment is emergent laparotomy.² The prompt and accurate diagnosis of diaphragmatic rupture is paramount for optimal patient outcome.

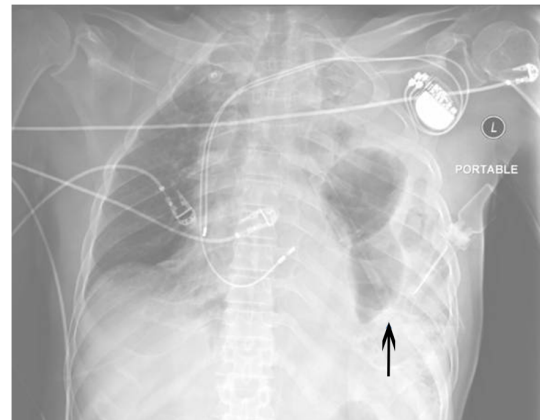


Figure 1. Portable anteroposterior chest x-ray demonstrating left rib fractures, hemothorax and left diaphragmatic rupture (arrow). Biventricular pacer is also noted.

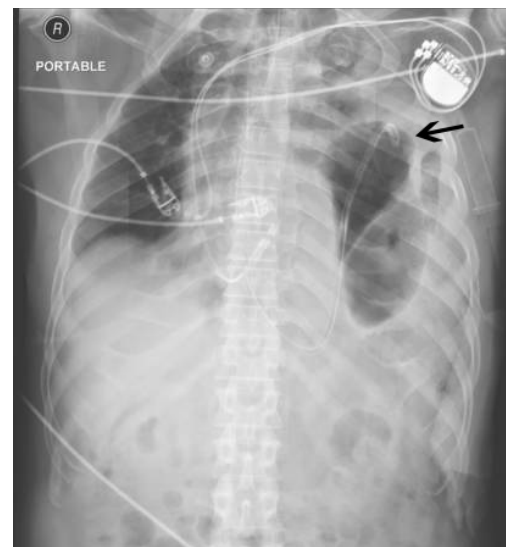

Figure 2. Portable anteroposterior chest x-ray demonstrating successful nasogastric tube insertion with tip extending above ruptured diaphragm into thorax (arrow).

Address for Correspondence: Alexander J Scumpia, DO, MSc, Mount Sinai Medical Center, Department of Emergency Medicine, 4300 Alton Rd, Miami Beach, Florida, 33140. Email: ascumpia@yahoo.com

Conflicts of Interest: By the *WestJEM* article submission agreement, all authors are required to disclose all affiliations, funding sources and financial or management relationships that could be perceived as potential sources of bias. The authors disclosed none.

REFERENCES

1. Scharff JR, Naunheim KS. Traumatic diaphragmatic injuries. *Thorac Surg Clin.* 2007;17:81-85
2. Asensio JA, Petrone P: Diaphragmatic injury. In: Cameron JL, editor. *Current Surgical Therapy*, 8th ed. Philadelphia: Elsevier Mosby Co: 2004. P.946-955.
3. Sangster G, Ventura V, Carbo A, et al. Diaphragmatic rupture: a frequently missed injury in blunt thoracoabdominal trauma patients. *Emerg Radiol.* 2007;13:225-230
4. Lochum S, Ludig T, Walter F, et al. Imaging of diaphragmatic injury: a diagnostic challenge? *Radiographics.* 2002;22:103-108