

# Horizontal alteration of anterior alveolar ridge after immediate implant placement: A retrospective cone beam computed tomography analysis

Young Keun Hyun<sup>1a</sup>, Chung Yun Lee<sup>2a</sup>, Subramanian Keerthana<sup>2</sup>, Selvaponpriya Ramasamy<sup>2</sup>, So-Yeon Song<sup>3</sup>, Ji Suk Shim<sup>3\*</sup>, Jae Jun Ryu<sup>4\*</sup>

<sup>1</sup>Periodontal Dental Clinic, Seoul, Republic of Korea

<sup>2</sup>Korea University Graduate School, Clinical Dentistry, Seoul, Republic of Korea

<sup>3</sup>Department of Dentistry, Korea University Guro Hospital, Seoul, Republic of Korea

<sup>4</sup>Department of Dentistry, Korea University Anam Hospital, Seoul, Republic of Korea

## ORCID

Young Keun Hyun

<https://orcid.org/0000-0002-8079-4159>

Chung Yun Lee

<https://orcid.org/0000-0002-9289-1802>

Subramanian Keerthana

<https://orcid.org/0000-0003-0305-8585>

Selvaponpriya Ramasamy

<https://orcid.org/0000-0002-2294-6740>

So-Yeon Song

<https://orcid.org/0000-0002-7738-5370>

Ji Suk Shim

<https://orcid.org/0000-0002-4112-6051>

Jae Jun Ryu

<https://orcid.org/0000-0002-2093-6389>

## Corresponding author

Ji Suk Shim

Department of Prosthodontics,  
Korea University Guro Hospital,  
#148, Gurodong-ro, Guro-gu, Seoul  
08308, Republic of Korea

Tel +82226262489

E-mail [shoss@hanmail.net](mailto:shoss@hanmail.net)

Jae Jun Ryu

Department of Advanced Prosthodontics,  
Korea University Anam Hospital,  
#73, Goryeodae-ro, Seongbuk-gu,  
Seoul 02841, Republic of Korea

Tel +8229205423

E-mail [koprosth@unitel.co.kr](mailto:koprosth@unitel.co.kr)

Received March 17, 2021 /

Last Revision April 20, 2021 /

Accepted April 23, 2021

<sup>a</sup> These authors contributed equally to this work.

This research was supported by National Research Foundation of Korea (NRF) grant funded by the Korea government (MSIT) (No. 2020R1A2C1014211).

**PURPOSE.** The aim of this study was to evaluate the labio-lingual alterations of the alveolar bone where the implant was placed immediately after tooth extraction.

**MATERIALS AND METHODS.** Implants were placed immediately after tooth extraction on anterior alveolar ridges in the maxilla and mandible. The pin-guide system was used to help determine the location and path of implants during the surgical process. The horizontal distance from implants to the outer border of alveolar bone was measured at the rim and middle of the implants in the cone beam computed tomography images. The alteration of alveolar bone was evaluated comparing the horizontal distances measured immediately after surgery and 3 months after surgery. **RESULTS.** The results show that more resorption occurred towards the labial bone than the lingual bone in the maxilla. A similar amount of labial and lingual bone resorption was observed in the mandible. **CONCLUSION.** Considering the horizontal alteration of alveolar bone, labio-lingual positioning of the implant towards the lingual bone in the maxilla and at the center of the alveolar ridge in the mandible is recommended when it is placed immediately after tooth extraction. [J Adv Prosthodont 2021;13:117-25]

## KEYWORDS

Dental implant; Alveolar ridge; Alveolar resorption; Tooth extraction; Cone-beam computed tomography

## INTRODUCTION

Bone resorption is correlated with catabolic changes in the alveolar bone after tooth extraction.<sup>1</sup> Tooth extraction leads to the disruption of the blood supply and the significant increase in osteoclastic activity.<sup>2</sup> As the blood sup-

© 2021 The Korean Academy of Prosthodontics

© This is an Open Access article distributed under the terms of the Creative Commons Attribution Non-Commercial License (<http://creativecommons.org/licenses/by-nc/4.0>) which permits unrestricted non-commercial use, distribution, and reproduction in any medium, provided the original work is properly cited.

ply varies for different anatomic structures in the oral cavity, the bone alteration after extraction is determined by factors including bone wall thickness, tooth angulation, and tooth shape.<sup>3</sup> Therefore, the alveolar bone alteration after tooth extraction is different between the anterior and posterior bone, between labial and palatal bone, and between maxillary and mandibular bone.<sup>4</sup>

The catabolic changes related to bone resorption are initiated by the disruption of blood supply to the labial bundle bone from the periodontal ligaments (PDL), which subsequently causes significant enhancement of the osteoclast activity.<sup>2</sup> Therefore, the central area of the socket shows more marginal bone changes than the proximal area because the proximal area is less affected by the disruption of blood supply following tooth extraction due to the additional support from the PDL of the neighboring teeth.<sup>5</sup> The labial bone in the maxilla shows more dimensional changes than the palatal bone because the labial bone has walls of limited thickness in comparison to that of the palatal bone.<sup>2</sup>

The outcome of implant placement into tooth sockets immediately after tooth extraction has been reported to be as predictable in esthetic and functional aspects.<sup>6</sup> However, there is still controversy over the statement that immediate implant placement after tooth extraction prevents alveolar bone resorption at the extracted site.<sup>7</sup> Therefore, clinicians should predict bone resorption for successful implant treatment when the implant is placed immediately after tooth extraction.<sup>8</sup> Moreover, in the anterior zone, preserved bone volume around implants after healing is critical to prevent the esthetic shortcomings including gingival discoloration, gingival recession, and reduced labial tissue volume.<sup>8</sup>

The implant position in the labio-lingual plane is critical for both biological and restorative complications.<sup>9,10</sup> The placement of an implant too far labially causes further reduction of alveolar bone, increasing the risk of soft tissue recession.<sup>11</sup> In addition, the implant in a one-sided position cannot achieve appropriate emergency profile without ridge lap.<sup>12,13</sup> The severe difference in the long axis between fixture and restoration causes difficulty in fabricating restorations.<sup>14</sup> To determine the accurate location for im-

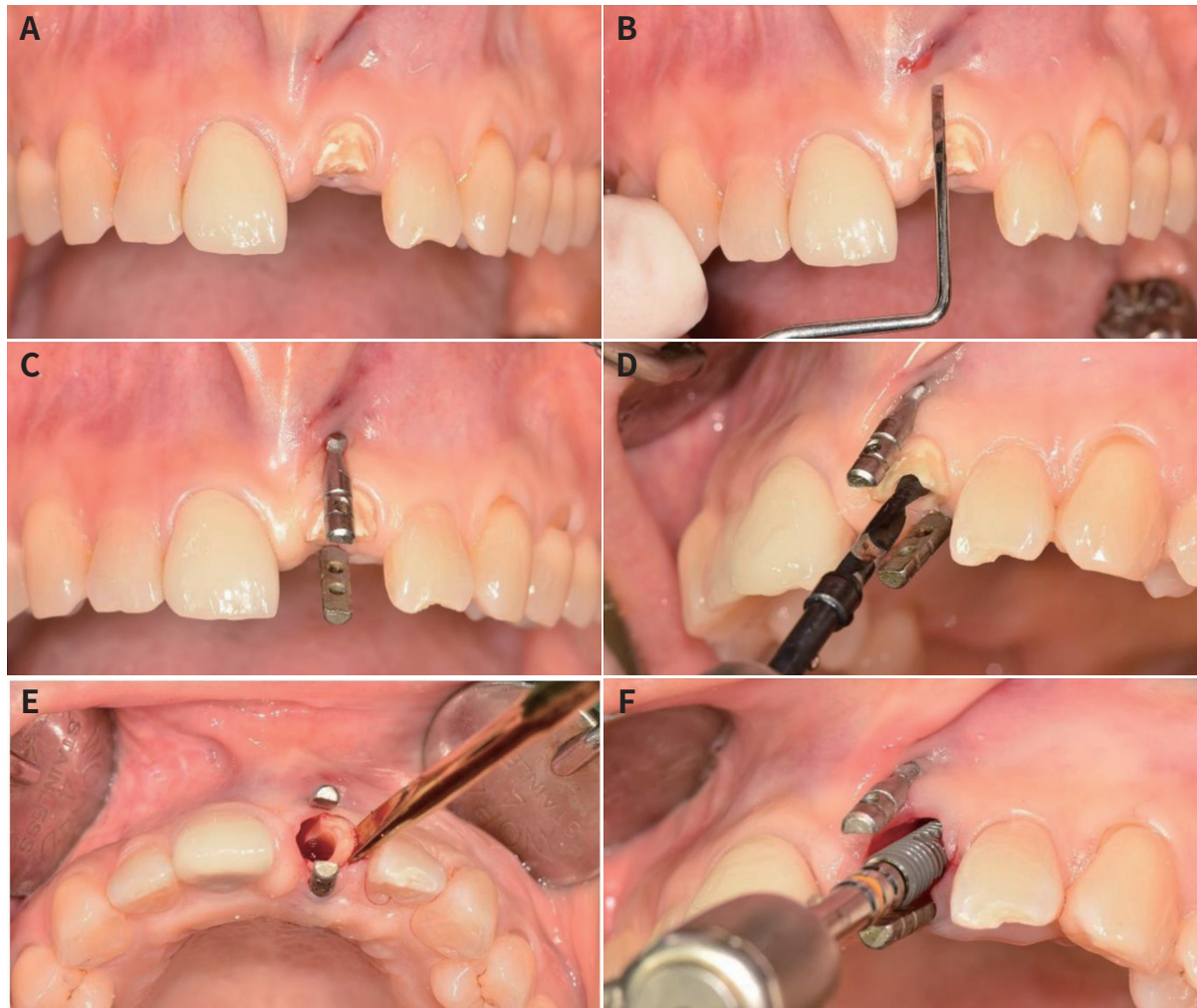
plant placement, various tools have been used. In this study, for the first time, we used a pin-guide system as a new method to assist in determining the appropriate location for implant placement.

The aim of this study was to evaluate the horizontal alteration of the alveolar bone around the implant placed in the freshly extracted socket. Implants were placed immediately after anterior tooth extraction in the maxilla and mandible, and the distance between the implant and the outer border of the alveolar bone was measured using CT images.

## MATERIALS AND METHODS

Forty consecutive patients who underwent implant treatment in the maxillary or mandibular anterior region, from 2017 to 2020, were included in this study. All implants were placed by a specialist who had majored in oral and maxillofacial surgery. The method of this study was approved by the local Medical Ethics Board (IRB no. 2019AS0083). The inclusion criteria were as follows: 1) age > 18 years, 2) presence of hopeless teeth in the anterior area, and 3) presence of healthy natural teeth adjacent to the teeth being replaced. The exclusion criteria were as follows: 1) heavy smokers (more than 10 cigarettes per day), 2) patients with severe concavity of the labial bone which requires additional guided tissue graft, or 3) patients with any wall defect after tooth extraction. The shape of alveolar bone was confirmed using cone beam computed tomography (CBCT) image acquired before the surgery. A pair of guiding pins was used to provide the reference for labial and lingual bone; the location and angulation of the implants was determined by the information from the guiding pins.

All implants were placed in the maxillary or mandibular anterior area (canine to canine) with a flapless approach (Fig. 1A). Following local anesthesia, the location for placing guiding pins was indicated on the muco-gingival junction (Fig. 1B). A pair of guiding pins was placed on the labial and lingual sides parallel to the long axis of the adjacent tooth (Fig. 1C). Pilot and subsequent drilling were performed on the retained root. Based on the angulation and distance between the pins, the position and path of drilling were determined (Fig. 1D). After finishing the drilling

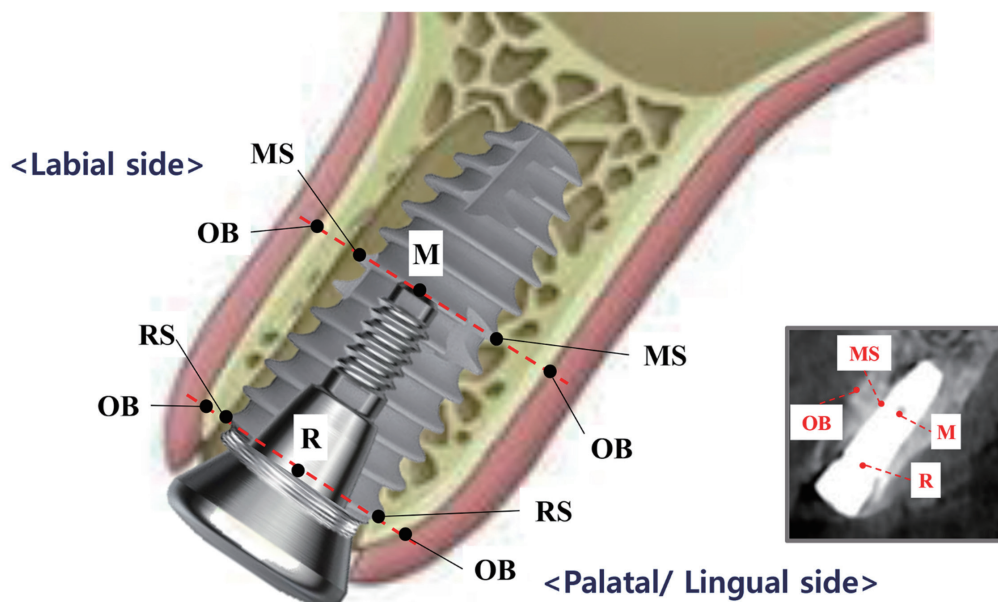


**Fig. 1.** (A) Preoperative view of maxillary left central incisal, fractured by secondary caries. (B) Indentation for the placement of guiding pin on the muco-gingival junction. (C) A pair of guiding pins were placed parallel to the long axis of adjacent tooth. (D) From the angulation and distance between pins, the position and path of drilling was determined. (E) After finishing the drilling procedure, the remaining root was extracted. (F) A cylindrical screw-type implant was placed in the extracted socket.

procedure, the remaining root was extracted (Fig. 1E). A cylindrical screw-type implant was placed in the extracted socket (Fig. 1F). Bone graft was not applied to all patients. A healing abutment was connected to the implant. Three months after the surgical intervention, a definitive ceramic implant crown was provided. The patients wore temporary denture until the delivery of the definite prosthesis. Customized abutments were provided so that the labial restorative margin was located 0.5mm below the gingiva. Computed tomography radiographs were taken before treatment, after surgery, and 3 months after surgery.

In order to describe the alteration in the alveolar bone, the landmarks were defined (Fig. 2). Changes in the alveolar bone were measured using CBCT imag-

es. The landmarks used to describe the alterations in the alveolar bone were as follows: the rim of the implant (R), the middle of the implant (M), the surface of the implant at the rim of the implant (RS), the surface of the implant at the middle of the implant (MS), and the outer border of the bone crest (OB). The rim of the implant can be determined by finding the border between implant fixture and healing abutment. The middle of the implant can be constantly designated by finding the tip of the abutment screw. The following parameters were estimated: (1) RS to OB, the horizontal distance between the implant surface and the outer border of the alveolar bone at the implant rim level, and (2) MS to OB, the horizontal distance between the implant surface at the middle of the im-



**Fig. 2.** Landmarks used to describe the alterations in the alveolar bone. Rim of implant (R), middle of implant (M), surface of the implant corresponding to the rim of the implant (RS), surface of the implant corresponding to the the middle of the implant (MS), and outer border of the bone crest (OB).

plant. The parameters were estimated for the labial and lingual side of the implant. The measurements were calibrated by two trained examiners. The first examiner measured the CBCT data repeating twice, and the second examiner double-checked the measurement from the capture image showing parameters on CBCT. The intra-examiner reliability was calculated by Pearson’s correlation coefficient ( $P < .001$ ). The intraclass correlation coefficient was 0.87.

The results are expressed as mean  $\pm$  standard deviation (SD). Data were evaluated for homogeneity of variance based on Levene’s tests ( $\alpha = .05$ ). We used a paired t-test to compare the amount of alveolar bone alteration as the anatomic location of implants (labial side and palatal side, maxilla and mandible, and rim and middle). A  $P$  value of  $< .05$  was considered statistically significant. All statistical analyses were performed using SAS software version 9.4 (SAS Institute Inc., Cary, NC, USA).

## RESULTS

This retrospective study included 40 patients, including 15 men and 25 women. Their ages ranged between 24 and 68 years with an average age of 49.3.

Among the extracted teeth, 18, 12, and 10 were extracted because of caries, periodontitis, and trauma, respectively. Implants replaced the maxillary and mandibular anterior teeth, including the central incisor, lateral incisor, and canine. The same number of implants was placed in the maxilla and mandible. The majority of the implants were 10 mm in length and 3.5 mm in diameter (Table 1).

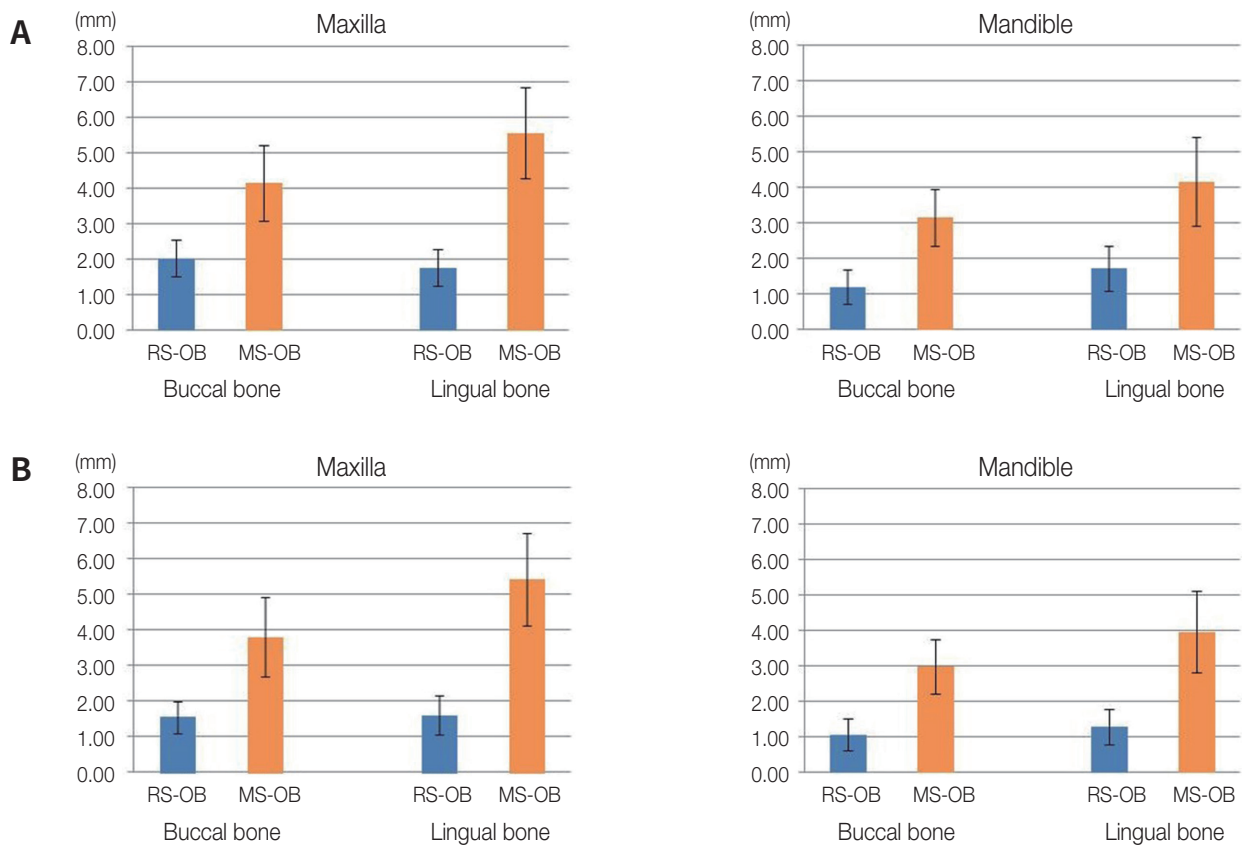
**Table 1.** Characteristics of the study group

		N
Number of patients		40
Number of implants		40
Male / female		15 / 25
Age (average)		49.3
Implant location	Maxilla	20
	Mandible	20
Reason for extraction	Trauma	10
	Caries	18
	Periodontitis	12
Implant length (mm)	8.5 / 10 / 13	7 / 32 / 1
Implant diameter (mm)	3.5 / 4.0 / 4.5	17 / 16 / 7

\* N = number

Figure 3 shows the parameters estimated immediately after surgery and 3 months later. Table 2 shows the horizontal distance between the implant surface and outer border of the alveolar bone after implant placement, which indicates the labio-lingual position of the implants. In the maxilla, the differences between the labial and lingual bones were 0.42 and 1.4 mm at the implant rim and implant middle, respectively. In the mandible, the differences between the labial and lingual bones were 0.3 and 1.01 mm at the implant rim level and implant middle, respectively.

Table 3 shows the comparison of the alveolar bone alteration between the labial and lingual bone. In the maxilla, labial bone changes were significantly greater than palatal bone changes, both at the rim of the implant ( $P < .05$ ) and the middle of the implant ( $P < .05$ ). In the mandible, there were no statistical differences in the horizontal alteration between the labial and lingual bone, both at the rim of the implant and the middle of the implant ( $P > .05$ ). Table 4 shows the comparison of the alveolar bone alteration between the maxilla and mandible. At the rim of the implant,



**Fig. 3.** The results of the study. (A) the horizontal distance between implant surface and the outer border of alveolar bone after surgery, (B) the horizontal distance between implant surface and the outer border of alveolar bone after 3 months.

**Table 2.** The horizontal distance between implant surface and outer border of alveolar bone after implant placement

		Labial bone	Lingual bone	Differences
Maxilla	Rim (RS-OB)	2.18 (0.57)	1.76 (0.52)	0.42
	Middle (MS-OB)	4.15 (1.08)	5.55 (1.27)	1.40
Mandible	Rim (RS-OB)	1.20 (0.47)	1.50 (0.58)	0.30
	Middle (MS-OB)	3.14 (0.80)	4.15 (1.24)	1.01

**Table 3.** Comparison of the amount of alveolar bone alteration (RS-OB<sub>after surgery</sub> - RS-OB<sub>after 3 months</sub> or MS-OB<sub>after surgery</sub> - MS-OB<sub>after 3 months</sub>) between labial and lingual bone

		Labial bone	Lingual bone	P value
Maxilla	Rim (RS-OB <sub>after surgery</sub> - RS-OB <sub>after 3 months</sub> )	0.50 (0.28)	0.16 (0.13)	< .05
	Middle (MS-OB <sub>after surgery</sub> - MS-OB <sub>after 3 months</sub> )	0.35 (0.27)	0.19 (0.20)	< .05
Mandible	Rim (RS-OB <sub>after surgery</sub> - RS-OB <sub>after 3 months</sub> )	0.22 (0.46)	0.45 (0.58)	.104
	Middle (MS-OB <sub>after surgery</sub> - MS-OB <sub>after 3 months</sub> )	0.24 (0.28)	0.21 (0.37)	.734

**Table 4.** Comparison of the amount of alveolar bone alteration (RS-OB<sub>after surgery</sub> - RS-OB<sub>after 3 months</sub> or MS-OB<sub>after surgery</sub> - MS-OB<sub>after 3 months</sub>) between maxilla and mandibular bone

		Maxilla	Mandible	P value
Rim (RS-OB <sub>after surgery</sub> - RS-OB <sub>after 3 months</sub> )	Labial bone	0.50 (0.28)	0.22 (0.46)	< .05
	Lingual bone	0.16 (0.13)	0.45 (0.58)	< .05
Middle (MS-OB <sub>after surgery</sub> - MS-OB <sub>after 3 months</sub> )	Labial bone	0.35 (0.27)	0.24 (0.28)	.140
	Lingual bone	0.19 (0.20)	0.21 (0.37)	.279

**Table 5.** Comparison of the amount of alveolar bone alteration (RS-OB<sub>after surgery</sub> - RS-OB<sub>after 3 months</sub> or MS-OB<sub>after surgery</sub> - MS-OB<sub>after 3 months</sub>) between the implant rim and the middle of implant

		Rim (RS-OB <sub>after surgery</sub> - RS-OB <sub>after 3 months</sub> )	Middle (MS-OB <sub>after surgery</sub> - MS-OB <sub>after 3 months</sub> )	P value
Maxilla	Labial bone	0.50 (0.28)	0.35 (0.27)	.108
	Lingual bone	0.16 (0.13)	0.19 (0.20)	.984
Mandible	Labial bone	0.22 (0.46)	0.24 (0.28)	.255
	Lingual bone	0.45 (0.58)	0.21 (0.37)	.247

more labial bone alteration was observed in the maxilla than in the mandible, and more lingual bone alteration was observed in the mandible than in the maxilla with statistical significance ( $P < .05$ ). At the middle of the implant, there was no statistical difference in labial or lingual bone alteration between the maxilla and mandible ( $P > .05$ ). Table 5 shows the comparison of alveolar bone alteration between the implant rim and the middle of the implant. There was no statistical difference in the alveolar bone alteration at the implant rim and at the implant middle ( $P > .05$ ).

## DISCUSSION

The greatest amount of alveolar bone alteration occurs in horizontal dimension.<sup>15,16</sup> To ensure sufficient bone volume around the implant after immediate implant placement, the clinician should take into consideration the changes in alveolar bone around the implant.<sup>8</sup> In this study, the horizontal alteration of alveolar bone after implant placement was evaluated by placing implants in the center of the alveolar ridge using a pin-guide system. Implants were placed on the anterior alveolar ridges in the maxilla and mandible.

ble, and the alteration of bone volume was measured at the rim and middle of the implants. The results show that more resorption occurred towards the labial bone than the lingual bone in the maxilla, whereas a similar amount of resorption occurred at labial and lingual bone in the mandible.

Alveolar bone changes after tooth extraction vary with the associated local factors, including alveolar bone and bone mass at skeletal sites.<sup>17</sup> Bone resorption following tooth loss also varies between the maxilla and mandible because anatomical features are different between the maxilla and the mandible.<sup>18</sup> The outer cortex is thin in the maxilla and thick in the mandible continuously till the basal bone,<sup>18</sup> and the mandible shows higher alveolar bone density than the maxilla.<sup>19</sup> Similar to previous studies, in this study, there was greater absorption of the labial bone than the lingual bone in the maxilla, but labial and lingual bones were similarly altered in the mandible.<sup>18,20,21</sup> Interestingly, these aspects were observed both at the rim and middle of the implants. The results highlight that clinicians should be cautious in maintaining sufficient distance between the implant and the outer border of the alveolar bone at the middle level as well as the rim of the implant. A previous study that reported the dehiscence in the apical 1/3 part of the implant immediately placed after tooth extraction supports the suggestion.<sup>22</sup>

Horizontal alteration of the alveolar ridge after tooth extraction should be considered for labial-lingual positioning of implants when they are immediately placed. In the anterior maxilla, placing implants toward the lingual bone rather than the center of the extracted socket is recommended, as the resorption of the labial bone plate is more pronounced than that of the lingual bone plate both at the rim and middle of the implants. On the other hand, in the anterior mandible, placing implants at the center of the extracted socket is recommended, as the bone resorption at the rim and middle of the implants was similar between the labial and lingual bone plate. In addition, the implant width should be determined considering the total amount of horizontal resorption on the labial and lingual sides. For the maxilla, the alveolar bone was horizontally altered by about 4 mm at the rim and 3 mm at the rim of the implant. In other

words, for the mandible, the horizontal alveolar bone resorption was approximately 3 mm at the rim and 7 mm at the rim of the implant.

The dimensional reduction of the alveolar ridge is related to the position of the implant in the socket, thickness of the socket wall, and patient-related factors.<sup>23</sup> As the position of the implant placed into the extraction socket can affect the alteration of the alveolar ridge, for the exact evaluation of alveolar ridge alteration, consistent constant positioning of implants is essential. In this study, a pin-guide system was used as the tool for adequate positioning of implants. A pair of guiding pins provided information on the distance between the labial and lingual outer border and the angulation of the alveolar ridge. The horizontal distances between the implant surface and the outer border of the alveolar bone were similar at the labial and lingual bone, showing that the implants were positioned without the perforation of alveolar bone which causes adverse effect of alveolar bone alteration. However, the other factors that affect to the alveolar resorption, including the distance between implant surface and alveolar bone, the vertical position of implant, and the thickness of alveolar bone, may be considered in the future studies.

As the physiological changes in the alveolar bone following tooth extraction occur within the first 3 months of socket healing,<sup>24</sup> the alveolar ridge changes were observed 3 months after tooth extraction. However, observation for longer periods may be necessary to evaluate the alteration in the alveolar bone around implants. For the repetitive measurement at the same point of the implant, distinguishable points were selected in the CBCT images. The rim of the implant can be distinguished by finding the border between the implants and abutments. The middle of the implant was defined as the tip of the screw hole, which is also easily picked out as the radiolucent point of the implants. Although the point may not be exactly middle of implant, it indicates the point at a constant distance from the rim of implant.

## CONCLUSION

Within the limits of this study, a greater amount of resorption was observed on the labial bone than at the

lingual bone in the maxilla. A similar amount of alteration in the labial and lingual bone was observed in the mandible. The results suggest labio-lingual positioning of the implant towards the lingual bone in the maxilla and at the center of the socket in the mandible, when placed immediately after tooth extraction.

## REFERENCES

- Chappuis V, Araújo MG, Buser D. Clinical relevance of dimensional bone and soft tissue alterations post-extraction in esthetic sites. *Periodontol 2000* 2017;73:73-83.
- Araújo MG, Lindhe J. Dimensional ridge alterations following tooth extraction. An experimental study in the dog. *J Clin Periodontol* 2005;32:212-8.
- Misawa M, Lindhe J, Araújo MG. The alveolar process following single-tooth extraction: a study of maxillary incisor and premolar sites in man. *Clin Oral Implants Res* 2016;27:884-9.
- Tylman SD. Theory and practice of crown and bridge prosthodontics. 5th ed. St. Louis: Mosby; 1965.
- Chen ST, Buser D. Clinical and esthetic outcomes of implants placed in postextraction sites. *Int J Oral Maxillofac Implants*. 2009;24:186-217.
- Schwartz-Arad D, Chaushu G. The ways and wherefores of immediate placement of implants into fresh extraction sites: a literature review. *J Periodontol* 1997;68:915-23.
- Botticelli D, Berglundh T, Lindhe J. Hard-tissue alterations following immediate implant placement in extraction sites. *J Clin Periodontol* 2004;31:820-8.
- Araújo MG, Silva CO, Souza AB, Sukekava F. Socket healing with and without immediate implant placement. *Periodontol 2000* 2019;79:168-77.
- Ferrus J, Cecchinato D, Pjetursson EB, Lang NP, Sanz M, Lindhe J. Factors influencing ridge alterations following immediate implant placement into extraction sockets. *Clin Oral Implants Res* 2010;21:22-9.
- Block MS, Emery RW, Cullum DR, Sheikh A. Implant placement is more accurate using dynamic navigation. *J Oral Maxillofac Surg* 2017;75:1377-86.
- Nisapakultorn K, Suphanantachai S, Silkosessak O, Rattanamongkolgul S. Factors affecting soft tissue level around anterior maxillary single-tooth implants. *Clin Oral Implants Res* 2010;21:662-70.
- Belser UC, Buser D, Hess D, Schmid B, Bernard JP, Lang NP. Aesthetic implant restorations in partially edentulous patients—a critical appraisal. *Periodontol 2000* 1998;17:132-50.
- Belser UC, Bernard JP, Buser D. Implant-supported restorations in the anterior region: prosthetic considerations. *Pract Periodontics Aesthet Dent* 1996;8:875-83; quiz 884.
- Buser D, Martin W, Belser UC. Optimizing esthetics for implant restorations in the anterior maxilla: anatomic and surgical considerations. *Int J Oral Maxillofac Implants* 2004;19:43-61.
- Van der Weijden F, Dell'Acqua F, Slot DE. Alveolar bone dimensional changes of post-extraction sockets in humans: a systematic review. *J Clin Periodontol* 2009;36:1048-58.
- Lam RV. Contour changes of the alveolar processes following extractions. *J Prosthet Dent* 1960;10:25-32.
- Bodic F, Hamel L, Lerouxel E, Baslé MF, Chappard D. Bone loss and teeth. *Joint Bone Spine* 2005;72:215-21.
- Malone WFP, Tylman SD, Koth DL. Tylman's theory and practice of fixed prosthodontics. 8th ed. St. Louis: Ishiyaku Euro-America; 1989.
- Devlin H, Horner K, Ledgerton D. A comparison of maxillary and mandibular bone mineral densities. *J Prosthet Dent* 1998;79:323-7.
- Lekovic V, Kenney EB, Weinlaender M, Han T, Klokkevold P, Nedic M, Orsini M. A bone regenerative approach to alveolar ridge maintenance following tooth extraction. Report of 10 cases. *J Periodontol* 1997;68:563-70.
- Lekovic V, Camargo PM, Klokkevold PR, Weinlaender M, Kenney EB, Dimitrijevic B, Nedic M. Preservation of alveolar bone in extraction sockets using bioabsorbable membranes. *J Periodontol* 1998;69:1044-9.
- Lin CY, Pan WL, Wang HL. Facial fenestration and dehiscence defects associated with immediate implant placement without flap elevation in anterior maxillary ridge: a preliminary cone beam computed tomography study. *Int J Oral Maxillofac Implants* 2018;33:1112-8.
- Tomasi C, Sanz M, Cecchinato D, Pjetursson B, Ferrus J, Lang NP, Lindhe J. Bone dimensional variations at implants placed in fresh extraction sockets: a multilevel multivariate analysis. *Clin Oral Implants Res*



2010;21:30-6.

24. Schropp L, Wenzel A, Kostopoulos L, Karring T. Bone healing and soft tissue contour changes following single-tooth extraction: a clinical and radiographic 12-month prospective study. *Int J Periodont Restor Dent* 2003;23:313-23.