

# Secondary Vulvar Reconstruction Using Bilateral Gluteal Fold Flaps after Radical Vulvectomy with Direct Closure

Solji Roh, MD  
Shimpei Miyamoto, MD  
Yutaro Kitamura, MD  
Daisuke Mito, MD  
Mutsumi Okazaki, MD

**Summary:** Although primary vulvovaginal reconstruction after vulvectomy has high potential to improve patients' outcomes, flap reconstruction is not an established part of the current standard treatment for vulvar cancer. We report a patient with successful secondary vulvar reconstruction 3 years after radical vulvectomy with direct wound closure. A 69-year-old woman presented with chronic, burning vulvar pain 3 years after radical vulvectomy without reconstruction for stage IB vulvar cancer. Her urethral orifice had everted because of the direct wound closure, which resulted in severe pain on contact. We performed secondary vulvar reconstruction using bilateral 14 × 5 cm<sup>2</sup> gluteal fold flaps. Postoperative pain management and overall aesthetic outcomes were satisfactory. Secondary vulvar reconstruction with gluteal fold flaps can avoid the sequelae resulting from inadequate direct wound closure after radical vulvectomy. Thus, we strongly advocate immediate vulvar reconstruction to prevent such situations. (*Plast Reconstr Surg Glob Open* 2021;9:e3550; doi: [10.1097/GOX.0000000000003550](https://doi.org/10.1097/GOX.0000000000003550); Published online 20 April 2021.)

Vulvar cancer is rare, accounting for 3%–5% of all cancers in the female genital tract.<sup>1–3</sup> Despite a trend shift in gynecologic surgery toward minimally invasive procedures and totally individualized treatments, radical vulvectomy is still the standard of care for vulvar cancer stage IB–IVA.<sup>4</sup> Although radical vulvectomy guarantees effective local control, it causes serious anatomic distortion and/or genitalia disfigurement, which significantly impairs the cosmetic and functional outcomes in terms of micturition, defecation, and/or sexual activity.<sup>5</sup> To minimize these sequelae after vulvectomy, various flap reconstruction methods have been reported, although such reconstruction is not yet accepted as part of the current standard treatment for vulvar cancer.<sup>5,6</sup> As some gynecologists are not aware of the current state of vulvar reconstruction, it is possible that they are also unaware that inappropriate direct wound closure can impair their patients' postoperative quality-of-life.<sup>5</sup> We report a representative case in which secondary vulvar reconstruction

using bilateral gluteal fold flaps was required after radical vulvectomy with inadequate primary closure.

## CASE REPORT

A 69-year-old woman was admitted to our hospital because of burning pain in her urethral meatus consequent to direct wound closure after radical vulvectomy for stage IB vulvar cancer 3 years previously. One year after the primary surgery, she noticed a pimple-like bump in her vulva, which continued to enlarge and become painful. The worsening pain made it uncomfortable to sit or walk for long periods, and she could not wear trousers. Eventually, she developed serious itching and had to wear a sanitary pad because of brownish discharge from the enlarging lesion.

Physical examination revealed bilateral loss of the labia majora and minora and eversion of the urethral orifice. Additionally, there was a 2-cm polypoid, hyperemic mass with a central dimple that was actively bleeding with some clots nearby (Fig. 1). Exposure of this mass to external stimuli was the main cause of her symptoms. We proposed secondary vulvar reconstruction with bilateral gluteal fold flaps, to which she agreed.

With the patient under general anesthesia in the lithotomy position, a circumferential incision was made along the scar tissue around the urethral orifice and vagina. The ring of scar tissue was carefully dissected, and

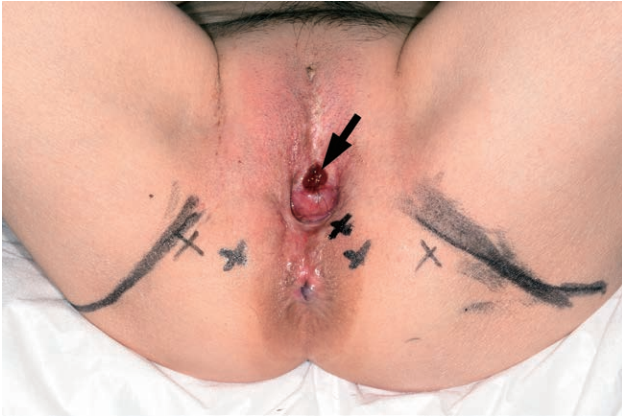From the Department of Plastic and Reconstructive Surgery, The University of Tokyo, Tokyo, Japan.

Received for publication November 2, 2020; accepted March 2, 2021.

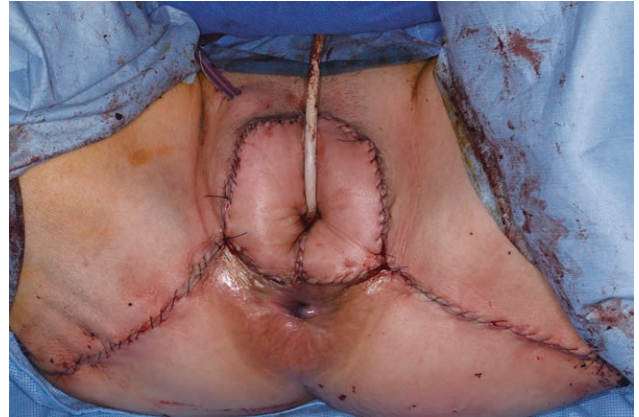
Copyright © 2021 The Authors. Published by Wolters Kluwer Health, Inc. on behalf of The American Society of Plastic Surgeons. This is an open-access article distributed under the terms of the [Creative Commons Attribution-Non Commercial-No Derivatives License 4.0 \(CCBY-NC-ND\)](https://creativecommons.org/licenses/by-nc-nd/4.0/), where it is permissible to download and share the work provided it is properly cited. The work cannot be changed in any way or used commercially without permission from the journal.

DOI: [10.1097/GOX.0000000000003550](https://doi.org/10.1097/GOX.0000000000003550)

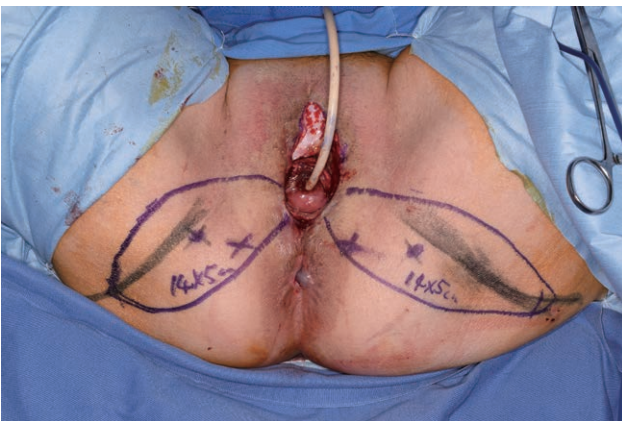
**Disclosure:** All the authors have no financial interest in relation to content of this article. No funding was received for this study.



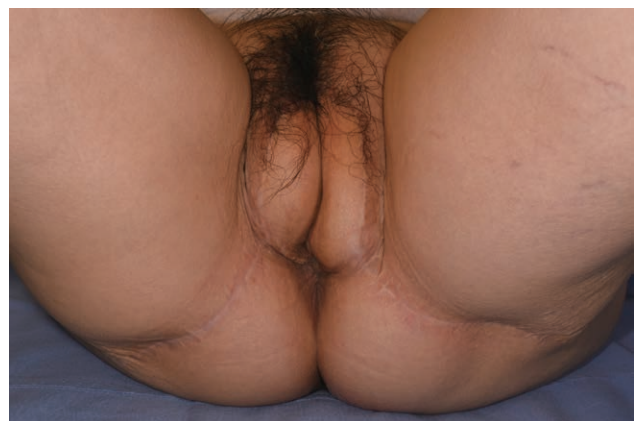**Fig. 1.** Preoperative vulvoperineal appearance of the patient. A 2-cm hyperemic mass (arrow) was observed at the urethral orifice.



**Fig. 3.** Appearance immediately after the operation with the gluteal fold flaps in place.



**Fig. 2.** Intraoperative appearance after releasing the contracture. Donor sites of the gluteal fold flaps are encircled in black.



**Fig. 4.** Vulvoperineal appearance of the patient at 18 months postoperatively.

the urethral orifice and vaginal stump were restored to their original positions (Fig. 2). Bilateral  $14 \times 5 \text{ cm}^2$  gluteal fold flaps were elevated and transposed to the defects, and the medial skin edges were sutured to the vaginal introitus (Fig. 3). We did not isolate or identify individual perforators, and the degree of flap transposition was approximately 120 degrees. Indocyanine green angiography confirmed good perfusion of the flaps. We used the whole widths of the flaps to deepen and protect the vaginal introitus. The flaps' donor sites were closed primarily. The painful polypoid tissue in the urethral orifice was also excised. Histopathologic evaluation confirmed it was inflammatory granulation of urethral tissue.

Postoperatively, a minor surgical-site infection was treated conservatively. There was no flap necrosis or wound dehiscence. The patient was discharged on postoperative day 16. Eighteen months later, she was free from pain, had normal micturition (Fig. 4), and the discharge had stopped completely.

## DISCUSSION

Historically, problems after vulvectomy have included wound infection, wound breakdown, urinary incontinence, vaginal prolapse, vaginal introital stenosis, and

sexual dysfunction. Several previous studies revealed that immediate vulvar reconstruction using skin flaps can avoid these problems and improve patients' quality-of-life. Flap reconstruction, however, has not yet been accepted as part of the standard treatment of vulvar cancer.<sup>5,6</sup> Furthermore, indications for flap reconstruction after vulvectomy have not been established in the field of gynecologic oncology.

Wide local excision with direct wound closure for defects at the introitus may lead to introital stenosis or distortion.<sup>7</sup> Although disturbed micturition has been reported as a possible sequela after direct wound closure, we could find no reports of eversion of the urethral orifice, as in our case.<sup>5</sup> In the present patient, the everted urethral orifice was exposed to external stress without having the labia majora or minora to protect it, which resulted in severe pain during contact.

Based on our belief that this patient should have undergone immediate vulvar reconstruction after vulvectomy instead of direct closure, we undertook a secondary vulvar reconstruction with bilateral gluteal fold flaps to ease her symptoms. The gluteal fold flap was first described as a variation of the lotus petal flaps by Yii and Niranjani in 1996. With the gluteal tissue mainly supplied by the direct cutaneous perforators from the internal pudendal artery,

it is now the flap of choice for vulvar reconstruction.<sup>7</sup> The locations of the perforators from the internal pudendal artery are very near the defect, and the flap can be easily transposed to the defect as a local propeller flap without positional change.<sup>8</sup> Its donor site is well concealed in the gluteal crease—away from the pathway of vulvar carcinoma spread. Moreover, the flap can be easily thinned to avoid bulkiness. For bilateral vulvar reconstruction, 2 flaps of the same size can be used to achieve symmetry.<sup>8,9</sup> In addition, the sensation of the gluteal fold flap can be maintained after transfer with innervation from the posterior labial nerve and the perineal branches of the posterior cutaneous nerve of the thigh.<sup>10</sup> We released the contracture of the vulva and restored the external urethral orifice to its original position. The transposed gluteal fold flaps, substituting for the labia, now protect the urethral and vaginal openings from external stimuli.

In the previous reports, various flaps other than the gluteal fold flap have been used for perineal reconstruction. The pudendal thigh flap is elevated based on the posterior labial artery, the terminal branch of the internal pudendal artery.<sup>11</sup> This flap is commonly used for vaginal reconstruction; however, it is not suitable for reconstruction after vulvectomy because closure of the donor site interferes with closure of the recipient site. The gracilis musculocutaneous flap can be the second line of choice for vulvar reconstruction; however, bulkiness resulting from the muscle component and unstable blood circulation of the distal area are the disadvantages.<sup>12</sup> The anterolateral thigh flap and the deep inferior epigastric artery perforator flap have also been used for perineal reconstruction; however, they should be indicated for more extensive defects.<sup>13,14</sup>

The clinical course of this patient raised concerns about the possibility that a certain number of patients who undergo direct closure after vulvectomy may suffer sequelae because the closure was inadequate or faulty. Our experience showed that secondary vulvar reconstruction with gluteal fold flaps can mitigate or prevent such sequelae. Gynecologists should be aware that, with proper indications, immediate flap reconstruction after vulvectomy is warranted to prevent such sequelae—not to mention the avoidance of secondary surgery.

### CONCLUSIONS

Direct wound closure after vulvectomy can result in eversion of the urethral orifice, which causes severe contact pain. Secondary vulvar reconstruction using bilateral gluteal fold flaps can improve this sequela.

*Shimpei Miyamoto, MD*

Department of Plastic and Reconstructive Surgery  
Graduate School of Medicine  
The University of Tokyo  
7-3-1, Hongo, Bunkyo-ku  
Tokyo 113-8655  
Japan  
E-mail: miyamos-ky@umin.ac.jp

### REFERENCES

1. Di Donato V, Bracchi C, Cigna E, et al. Vulvo-vaginal reconstruction after radical excision for treatment of vulvar cancer: Evaluation of feasibility and morbidity of different surgical techniques. *Surg Oncol*. 2017;26:511–521.
2. Wills A, Obermair A. A review of complications associated with the surgical treatment of vulvar cancer. *Gynecol Oncol*. 2013;131:467–479.
3. Sznurkowski JJ. Vulvar cancer: initial management and systematic review of literature on currently applied treatment approaches. *Eur J Cancer Care (Engl)*. 2016;25:638–646.
4. Woelber L, Kock L, Gieseck F, et al. Clinical management of primary vulvar cancer. *Eur J Cancer*. 2011;47:2315–2321.
5. Höckel M, Dornhöfer N. Vulvovaginal reconstruction for neoplastic disease. *Lancet Oncol*. 2008;9:559–568.
6. Salgarello M, Farallo E, Barone-Adesi L, et al. Flap algorithm in vulvar reconstruction after radical, extensive vulvectomy. *Ann Plast Surg*. 2005;54:184–190.
7. Yii NW, Niranjan NS. Lotus petal flaps in vulvo-vaginal reconstruction. *Br J Plast Surg*. 1996;49:547–554.
8. Hashimoto I, Abe Y, Nakanishi H. The internal pudendal artery perforator flap: free-style pedicle perforator flaps for vulva, vagina, and buttock reconstruction. *Plast Reconstr Surg*. 2014;133:924–933.
9. Hashimoto I, Nakanishi H, Nagae H, et al. The gluteal-fold flap for vulvar and buttock reconstruction: anatomic study and adjustment of flap volume. *Plast Reconstr Surg*. 2001;108:1998–2005.
10. Coltro PS, Ferreira MC, Busnardo FF, et al. Evaluation of cutaneous sensibility of the internal pudendal artery perforator (IPAP) flap after perineal reconstructions. *J Plast Reconstr Aesthet Surg*. 2015;68:252–261.
11. Tham NL, Pan WR, Rozen WM, et al. The pudendal thigh flap for vaginal reconstruction: optimising flap survival. *J Plast Reconstr Aesthet Surg*. 2010;63:826–831.
12. Chen SH, Hentz VR, Wei FC, et al. Short gracilis myocutaneous flaps for vulvoperineal and inguinal reconstruction. *Plast Reconstr Surg*. 1995;95:372–377.
13. Santanelli F, Paolini G, Renzi L, et al. Preliminary experience in reconstruction of the vulva using the pedicled vertical deep inferior epigastric perforator flap. *Plast Reconstr Surg*. 2007;120:182–186.
14. Zeng A, Qiao Q, Zhao R, et al. Anterolateral thigh flap-based reconstruction for oncologic vulvar defects. *Plast Reconstr Surg*. 2011;127:1939–1945.