

The Influence of Anterior Cruciate Ligament Remnant on Postoperative Clinical Results in Patients with Remnant Preserving Anterior Cruciate Ligament Reconstruction

Alan Andonovski¹, Sonja Topuzovska², Milan Samardziski¹, Zoran Bozinovski¹, Biljana Andonovska¹, Zlatko Temelkovski¹

¹University Clinic for Orthopedic Surgery, Traumatology, Anesthesiology and Intensive Care, Ss Cyril and Methodius University of Skopje, Skopje, Republic of Macedonia; ²Institute of Medical and Experimental Biochemistry, Faculty of Medicine, Ss Cyril and Methodius University of Skopje, Skopje, Republic of Macedonia

Abstract

Citation: Andonovski A, Topuzovska S, Samardziski M, Bozinovski Z, Andonovska B, Temelkovski Z. The Influence of Anterior Cruciate Ligament Remnant on Postoperative Clinical Results in Patients with Remnant Preserving Anterior Cruciate Ligament Reconstruction. Open Access Maced J Med Sci. 2017 Aug 15; 5(5):624-629. https://doi.org/10.3889/oamjms.2017.096

Keywords: Anterior cruciate ligament rupture; Remnant preserving ACL reconstruction; Single bundle ACL reconstruction; Clinical results.

***Correspondence:** Alan Andonovski, University Clinic for Orthopedic Surgery, Traumatology, Anesthesiology and Intensive Care, Ss Cyril and Methodius University of Skopje, Skopje, Republic of Macedonia. E-mail: alanandonovski@t.mk

Received: 07-Feb-2017; Revised: 06-Mar-2017; Accepted: 20-May-2017; Online first: 20-Jul-2017

Copyright: © 2017 Alan Andonovski, Sonja Topuzovska, Milan Samardziski, Zoran Bozinovski, Biljana Andonovska, Zlatko Temelkovski. This is an open-access article distributed under the terms of the Creative Commons Attribution-NonCommercial 4.0 International License (CC BY-NC 4.0).

Funding: This research did not receive any financial support.

Competing Interests: The authors have declared that no competing interests exist.

Abbreviations: ACL – Anterior Cruciate Ligament; PCL – Posterior Cruciate Ligament; PL bundle – Posterolateral bundle; AM bundle – Anteromedial bundle.

BACKGROUND: Anterior Cruciate Ligament (ACL) remnants have important biomechanical, vascular and proprioceptive function.

AIM: To determine the influence of the ACL residual remnants after partial and complete ACL ruptures on postoperative clinical results in patients with remnant preserving ACL reconstruction.

PATIENTS AND METHODS: The study included 66 patients divided into two groups. In patients from the *investigation* group remnant preserving ACL reconstruction was performed, in patients from the *control* group single bundle ACL reconstruction was performed. The results were assessed by Rolimeter measurements, Lysholm and Tegner scores and proprioception evaluation.

RESULTS: The mean side-to-side difference of anterior tibia displacement (mm) was improved from 4.4 ± 1.06 to 0.4 ± 0.7 in the *investigation* group, and from 4.6 ± 0.68 to 1.9 ± 0.64 in the *control* group ($p < 0.001$). Difference in the angles in which the knee was placed by the device and the patient has improved from $1.5 \pm 0.96^\circ$ to $0.5 \pm 0.53^\circ$ in the *investigation* group and from $1.8 \pm 0.78^\circ$ to $1.3 \pm 0.97^\circ$ in the *control* group ($p < 0.05$). Tegner and Lysholm scores showed no difference between the groups.

CONCLUSION: Preservation of the ACL residual bundle provides a better knee stability and proprioceptive function.

Introduction

Arthroscopic reconstruction of the anterior cruciate ligament (ACL) is one of the most commonly performed procedures in orthopedic surgery. Although there is an improvement in surgical techniques there is still graft failure rate of 3% to 12% of the cases [1]. The main factors which have influence on the results after ACL reconstructions can be separated into two groups: biomechanical and biological [2].

According to the studies [3] in 50 % of the patients with ACL injury, arthroscopic examination

carried out prior to ACL reconstruction reveals the presence of ACL residual remnants. In patients with complete ACL rupture these remnants have non anatomic femoral insertion on the intercondylar notch or posterior cruciate ligament (PCL). Sometimes a partial rupture of the anteromedial (AM) or posterolateral (PL) bundle of the ACL can be observed. In their article [4] Kazusa et al. gave the most detailed classification of the ACL residual remnants. Recently, the importance of the ACL remnant has been recognized in terms of its biomechanical, vascular and proprioceptive functions. The ACL remnants attached to the lateral wall of the intercondylar notch contribute to anteroposterior knee

stability up to 1 year after the ACL injury [5]. ACL remnant preservation means partial preservation of the ACL periligamentous and endoligamentous vessels which induce more rapid revascularization of the graft from the ACL remnant [6]. Nerve fibers from the preserved ACL remnant may influence the proprioceptive function of the knee and regenerate mechanoreceptors around the augmented graft restoring the preinjury proprioceptive function [7].

Recent studies show that ACL residual remnant stimulates the graft healing process and improves postoperative knee stability, proprioceptive function and functional knee scores after remnant preserving ACL reconstructive techniques [8-10]. Unfortunately, only patients with residual remnants after partial ACL ruptures were included in these studies. The only study that presents the postoperative clinical results in patients with residual remnants after complete ACL ruptures and non anatomical remnant healing is the study by Ann et al [11], where proprioceptive function investigation is not obtained. The purpose of this study is to determine the influence of the ACL residual remnants after partial and complete ACL ruptures on postoperative clinical results in patients with remnant preserving ACL reconstruction.

Patients and Methods

Patient's selection

The study included 66 patients (58 men and 8 women), mean age 28 years (from 16 to 50 years) diagnosed with rupture of the anterior cruciate ligament of the knee and arthroscopic confirmed presence of residual remnant from the torn ACL in which there is continuity of ligament fibers down to the tibia and above to the wall of the intercondylar notch or to the posterior cruciate ligament, and a diameter greater than 1/3 of that of normal ACL. Patients with the following disorders were excluded from this study: present infection of the knee, significant degenerative changes in the cartilage of the knee, previous operations of the knee (ACL reconstructions, removing large osteochondral fragments of the knee), associated lesions of other ligaments in the knee (posterior cruciate ligament), and those patients with malignant, autoimmune, immune proliferative, renal (creatinine > 150), systemic connective tissue, endocrine (diabetes) and hematologic (thrombocytopenia) diseases. Pregnant women were also excluded from the study. All patients preoperatively voluntarily signed a document for informational consent. Patients in this study were divided into 2 groups: group I (control group) - composed of 33 patients where after the removal of the residual bundle of ACL a standard single bundle

reconstruction of ACL was made and group II (investigation group) - composed of 33 patients where remnant preserving ACL reconstruction was made. All patients were operated in the period from January 2015 to March 2016 by the same orthopedic surgeon (A.A.) and the same postoperative rehabilitation protocol was implemented in all of them by the same physiotherapist. All measurements of the anterior-posterior knee stability, proprioception measurements, and determination of functional scores were made by the same physiatrist. The research was *prospective, randomized and double-blinded*.

Surgical technique

Operative interventions were performed in the regional (spinal) anesthesia using esmarch placed in the upper thigh. Each intervention started with arthroscopic revision of the knee joint, treatment of associated injuries of the other knee structures (meniscal lesions, cartilage injuries), as well as measurement of the ACL residual remnant diameter. Tendons of hamstring muscles were used as a graft in all patients. Fixation of grafts was done by Endobutton on the femoral part and titanium interference screw in the tibia tunnel. Operative intervention was done using 3 arthroscopic portals: high anterolateral (AL) portal, anteromedial (AM), and accessory anteromedial (AAM) portal. The placement of the femoral tunnel was done with or without a special femoral guide, by using the transportal technique of drilling via AM or AAM portal in order to obtain anatomical more horizontally (9.30 to 10.30) placed femoral tunnel. Taking into account that in cases of ACL partial rupture the remaining residual bundles are not completely intact and there is some reduction in their biomechanical function and strenght, and that graft is shifting towards down along his application, the femoral channels were placed slightly above to cover the lateral intercondylar ridge and with one part (about 1/4 the size of the channel) to pass on the other side of bifurcation ridge (Fig. 1).

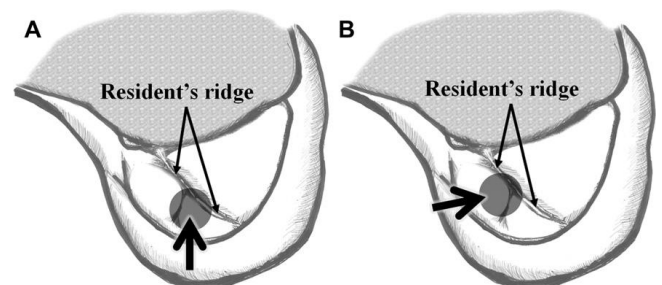


Figure 1: Placement of posterolateral (A) and anteromedial (B) femoral tunnel in remnant preserving ACL reconstruction.

In complete rupture of ACL with the existence of 2a, 2b, and 2C types of residual remnants the femoral tunnel was placed in a position as in reconstruction of AM bundle of ACL, and that position

has been used in patients with standard single bundle ACL reconstruction. Drilling of femoral tunnels was done at 110 to 120 degrees flexion of the knee. When making tibial tunnels special tibial guide has been used. Its top has been placed in the anteromedial or posterolateral part of the tibial attachment of the residual bundle (Fig. 2) in patients from the investigation group. In patients from the control group this was done in the middle part of the tibial attachment of the residual bundle. Rehabilitation of the patients was in accordance with the postoperative rehabilitation protocol applied at the Clinic for Orthopedic Surgery.

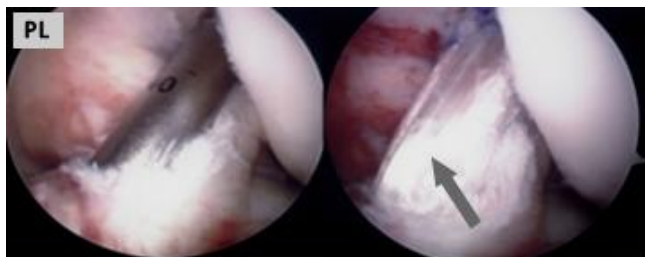


Figure 2: Graft placement in remnant preserving ACL reconstruction with preservation of the posterolateral residual bundle

Evaluation

The anterior displacement was measured by Rolimeter (Aircast Europa, Neubeuern, Germany), with the knee at 20° and 90° of knee flexion, applying an anterior force to the tibia. Both the injured and healthy knees were assessed, and the side-to-side difference in the measurement of anterior displacement was calculated before and 6 months after ACL reconstruction. In patients with ACL lesion the sensitivity of the Rolimeter to measure ACL insufficiency is up to 95% [12, 13].

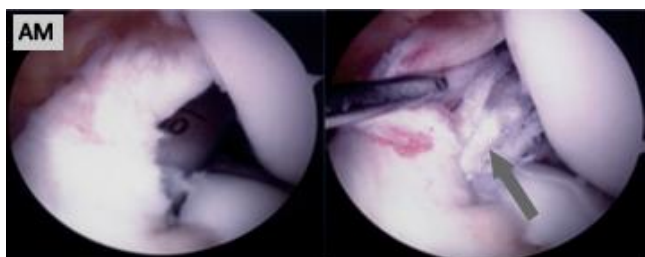


Figure 3: Graft placement in remnant preserving ACL reconstruction with preservation of the anteromedial residual bundle.

We used the joint position sense test (JPST) for evaluation of the proprioceptive function measuring with isokinetic dynamometer type *Biodex System 4 pro* (Biodex Medical Systems, Inc.). With this test we determined the ability of the patient to reproduce the angle in which the knee was positioned before it was returned back in the starting position [7, 14]. First, the patients kept their knees in the 90° flexed position as a starting position and then the injured or healthy knee was extended to a certain angle determined by an examiner. The patient was asked to remember the

angle. After returning the knee to the 90° flexed position, the patient was asked to restore the knee to the established angle. The difference between the established and set angle was measured as inaccuracy. The measurements were repeated 3 times on both legs and then the average inaccuracy was calculated. Finally, inaccuracy was calculated as the values of the involved knee minus the normal knee. We made the measurements before and 6 months after ACL reconstruction. Tegner and Lysholm knee scores were used for evaluation of the knee function.

Statistical analyses

All data were expressed as mean ± standard deviation and analyzed by SPSS 12.0 software. Group comparison was performed with t test (*student*) and P < 0.05 was considered statistically significant.

Results

All the patients were followed up for a mean period of 7 months (6 to 8 months). According to the associated injuries, 28 patients had medial meniscus lesions, 11 had lateral meniscus lesions, and 4 had lesions to both menisci. Measuring with Rolimeter the results showed greater postoperative improvement in the measured anterior tibial translation in the group with remnant preserving ACL reconstruction than in the group with standard single bundle ACL reconstruction (Table 1).

Table 1: The side-to-side difference (mm) of anterior tibia displacement in the investigation and control group, before and after surgery

	Investigation Group N = 33	Control Group N = 33	Significance (p)
Before surgery	4.4 ± 1.06	4.6 ± 0.68	
After surgery	0.4 ± 0.7	1.9 ± 0.64	(p < 0.0001)

Determining the proprioceptive function, measuring the difference in the angles in which the knee was placed by the device and the patient the postoperative measurements showed greater postoperative improvement in the investigation group than in the control group (Table 2).

Table 2: The difference in the angles (degrees) in which the knee was placed by the device and the patient in the investigation and control group, before and after surgery

	Investigation Group N = 33	Control Group N = 33	Significance (p)
Before surgery	1.5 ± 0.96	1.8 ± 0.78	
After surgery	0.5 ± 0.53	1.3 ± 0.97	(p < 0.05)

Considering the results of the functional scores (Tegner, Lysholm) there was no difference between the patients in the group where remnant preserving ACL reconstruction was made and the one

with standard single bundle ACL reconstruction. The median Lysholm knee scores significantly improved from 69 points preoperatively to 95 points 6 months postoperatively. In both groups, according to Tegner questionnaire, the mean level of sports activity before surgery it was 4, and 6 months after surgery it was 6.

Discussion

Besides the improvements in the reconstructive ACL procedures, the percentage of graft ruptures remains to range from 3% to 12% of the cases. The reasons are more sought in the disordered biological integration of the tendon graft and less in the biomechanical reasons since the initial tension and fixation of the graft could be the cause for the early graft failure, but these cannot explain the late ruptures of the graft, which would certainly be the result of the poor biological integration of the same [15]. According to Shelbourne [16] and Salmon [17], these ruptures were the result of the strenuous physical activity and weakness of the graft. All this led to a need of a surgical procedure to reconstruct the ACL, which would enable solid biological integration of the graft and rapid postoperative rehabilitation of the patient. So, the technique of surgical reinforcement (augmentation) of ACL was innovated, and represents a reconstruction of the anterior cruciate ligament preserving the residual bundle from the same, in order to use the influence of the residual bundle on the healing of the graft.

To provide mechanical stability of the knee is of an essential importance either in the early postoperative period, when the graft has not healed and when its strength depends only on its primary fixation with screws, buttons, pins and other fixation materials or in the phase of ligamentization when it is possible the elongation of the same to happen. Residual bundles have great biomechanical role in preventing the anterior tibial translation which is mostly protected in the first year of the injury and is the least expressed in the residual bundles healed to the posterior cruciate ligament as it is described in the studies of Crain et al. [18] and Nakamae et al. [5].

Revascularization of the graft is the basic condition in order to have healing and biological incorporation of the same. Consequently, it is important to preserve the ACL residual bundle during reconstruction of the same, because in that way it is possible to partially preserve the vascular network of the normal ACL and to enable the blood vessels to revascularize the graft. This effect was confirmed in the experimental studies by Arnoczky [6], Wu [19], Li [20], and Mifune [21] through the faster formation of vascular network in those experimental animals where remnant preserving ACL reconstruction was done.

Revascularization of the graft in patients after performed reconstruction of ACL was studied only indirectly by means of magnetic resonance imaging in the studies by Gohil et al. [22] and Ahn et al. [23]. According to Gohil et al. revascularization of the graft was faster in the group where the residual bundle of ACL was preserved, and according to Ahn in the group where the residual bundle of ACL was preserved, the magnetic resonance showed greater graft.

The preservation of proprioception is of great importance for patients with ACL injuries either in the period immediately after the ACL injury or in the postoperative period after its reconstruction. In certain patients the poor postoperative results could be explained with impaired proprioception, where despite the solid anatomic ACL reconstruction with good tension of the graft and stable knee in clinical testing, the patients still complains of a sense of instability in the operated knee. Therefore the residual bundle of ACL is important, since its preservation during the operational intervention means preservation of a number of mechanoreceptors located in the bundle that are important for the preservation of proprioception. The presence of mechanoreceptors in residual bundle of ACL is described in several studies [24-27], according to which most receptors are present in the residual bundles tied to the posterior cruciate ligament and their number decreases with the increasing period of injury. In the study of Adachi et al. [28] the effect of the number of mechanoreceptors in the residual bundle of ACL was examined in respect to the proprioceptive function using the joint position sense test. The results have shown one positive correlation between the number of mechanoreceptors and proprioceptive function. If it is considered that after the reconstruction of ACL the graft reinnervates and that in the residual bundles of ACL there are mechanoreceptors, then it is very probable that these residual mechanoreceptors play a major role in the reinnervation of the graft. The reinnervation itself implies return of the normal number of mechanoreceptors in the graft, as well as return of the lost proprioceptive function.

Although remnant preserving ACL reconstruction is for the first time mentioned in the paper by Mot, its importance becomes essential after the publication of the results by Adachi et al. [8]. Comparing the antero posterior stability and terminal strength of the knee as well as the proprioception determined by the joint position sense test (JPST) before and after surgery, the authors concluded that the remnant preserving ACL reconstruction gives better results than the standard single bundle reconstruction of the ACL. Buda et al. [10], in their prospective study, found good and excellent results in 95.7% of the cases with remnant preserving ACL reconstruction, making analysis by using functional scores (IKDC, Tegner activity scale) and measurements by using an arthrometer. Initially, the

remnant preserving ACL reconstruction was understood as reconstruction of one of the two ACL bundles with preservation of the intact bundle, which means that remnant preserving ACL reconstruction has been used only in patients with partial rupture of the AM or PL bundle of ACL. With the discovery of the significance of the residual remnant of the torn anterior cruciate ligament, remnant preserving ACL reconstruction started to be used in cases where there is a complete rupture of the ACL with healing of the residual bundle on the posterior cruciate ligament or nonanatomic position on the intercondylar notch. Making clinical investigation in patients with this type of remnant preserving ACL reconstruction Ann et al. concluded that this type of reconstruction provides significantly improved knee stability and functionality [11].

From the upper stated it is concluded that it is important to know the residual remnants of ACL. If this residual remnant corresponds to the AM or PL bundle in relation to the femoral insertion, and the other bundle is torn then it is a *partial rupture* of the ACL. If the residual remnant has no anatomic femoral insertion and binds to the posterior cruciate ligament (LCP), high on the roof of the intercondylar notch or to the medial wall of the lateral femoral condyle in a nonanatomic position usually more to the front and down, then it is a *complete rupture* of ACL with healing of the femoral attachment to a nonanatomic position. According to Crain et al. [18], the residual bundles of a torn anterior cruciate ligament can be classified into 4 groups: (1) Residual bundle healed to a PCL; (2) Residual bundle healed to the roof of the intercondylar notch; (3) Residual bundle healed to the lateral wall of the intercondylar notch or to the medial wall of the lateral femoral condyle; and (4) Residual bundle without having ligament tissue in it. The most detailed classification of residual bundles of ACL is the one given by Kazusa et al. [4]. According to it, the residual bundles are classified into 7 groups: (1a) Partial rupture of the PL bundle of ACL with residual bundle that matches the AM bundle; (1b) Partial rupture of the AM bundle with residual bundle that matches the PL bundle of ACL; (1c) Partial rupture of ACL with residual remnant which cannot be described neither as AM nor as PL bundle; (2a) Complete rupture of ACL with residual bundle healed on the PCL; (2b) Complete rupture of ACL with residual bundle healed on the roof of the intercondylar notch; (2c) Complete rupture of ACL with residual bundle attached to the lateral wall of the intercondylar notch on nonanatomic front set position; and (2d) Complete rupture of ACL without having a residual bundle.

In our study remnant preserving ACL reconstruction was performed in the cases with partial as well as in the cases with complete rupture of the ACL. In databases we have not managed to find another study like ours, which includes all types of ACL residual remnants described in the classification of Kazusa et al. [4]. The results showed greater

postoperative improvement in the measured anterior tibial translation ($p < 0.0001$) and proprioceptive function ($p < 0.05$) in the group with remnant preserving ACL reconstruction than in the group with standard single bundle reconstruction. Certainly, the fact that remnant preserving ACL reconstruction is a technically more demanding operative procedure should not be set aside. The visualization of insertion sites of the graft is more difficult, especially the femoral attachment of the AM bundle and the tibial attachment of the PL bundle. There is a need of a perfect control in the bony tunnels drilling process in order to prevent damage of the residual bundle. The necessity of good placement of the graft as well as the overall management of the intercondylar notch space to avoid graft impingement with cyclops lesion, tearing of the graft, and restricted movements of the knee is another reason which makes this procedure technically more complicated.

In conclusion, based on the results the conclusion would be that preservation of the residual bundle in remnant preserving ACL reconstruction is justified since it provides a better antero posterior knee stability and a better proprioceptive function than the cases where a standard single bundle ACL reconstruction is made by sacrificing the residual remnant. More studies of this kind which would include a greater number of patients in the research process are necessary in order to obtain more precise results.

References

1. Shelbourne KD, Gray T, Haro M. Incidence of subsequent injury to either knee within 5 years after anterior cruciate ligament reconstruction with patellar tendon autograft. *Am J Sports Med.* 2009;37:246–51. <https://doi.org/10.1177/0363546508325665> PMID:19109531
2. Salmon L, Russell V, Musgrove T, Pinczewski L, Refshauge K. Incidence and risk factors for graft rupture and contralateral rupture after anterior cruciate ligament reconstruction. *Arthroscopy.* 2005; 21:948–57. <https://doi.org/10.1016/j.arthro.2005.04.110> PMID:16084292
3. Durafour H, Panisset JC. Anatomic analysis of ACL tears and laxity. Presented at the Congrès annuel de la Société Française d'Arthroscopie, December 2007.
4. Kazusa H, Nakamae A, Ochi M. Augmentation Technique for Anterior Cruciate Ligament Injury. *Clin Sports Med.* 2013; 32:127–140. <https://doi.org/10.1016/j.csm.2012.08.012> PMID:23177467
5. Nakamae A, Ochi M, Deie M, et al. Biomechanical function of anterior cruciate ligament remnants: how long do they contribute to knee stability after injury in patients with complete tears? *Arthroscopy.* 2010;26:1577–85. <https://doi.org/10.1016/j.arthro.2010.04.076> PMID:20888171
6. Arnoczky SP, Tarvin GB, Marshall JL. Anterior cruciate ligament replacement using patellar tendon. An evaluation of graft revascularization in the dog. *J Bone Joint Surg Am.* 1982;64(2):217–24. <https://doi.org/10.2106/00004623-198264020-00011> PMID:7056776
7. Fremerey W.R, Lobenhoffer P, Zeichen J, Skutek M, Bosch U, Tschorne H. Proprioception after rehabilitation and reconstruction

- in knees with deficiency of the anterior cruciate ligament. *J Bone Joint Surg [Br]*. 2000;82-B:801-6. <https://doi.org/10.1302/0301-620X.82B6.10306>
8. Adachi N, Ochi M, Uchio Y, Sumen Y. Anterior cruciate ligament augmentation under arthroscopy. A minimum 2-year follow-up in 40 patients. *Arch Orthop Trauma Surg*. 2000;120:128–33. <https://doi.org/10.1007/s004020050028> PMID:10738868
9. Ochi M, Adachi N, Uchio Y, Deie M, Kumahashi N, Ishikawa Y. A minimum 2- year follow-up after selective anteromedial or posterolateral bundle anterior cruciate ligament reconstruction. *Arthroscopy*. 2009;25:117–22. <https://doi.org/10.1016/j.arthro.2008.10.011> PMID:19171269
10. Buda R, Ferruzzi A, Vannini F, Zambelli L, Di Caprio F. Augmentation technique with semitendinosus and gracilis tendons in chronic partial lesions of the ACL: clinical and arthrometric analysis. *Knee Surg Sports Traumatol Arthrosc*. 2006;14:1101–7. <https://doi.org/10.1007/s00167-006-0117-7> PMID:16799826
11. Ahn JH, Wang JH, Lee YS et al. Anterior cruciate ligament reconstruction using remnant preservation and a femoral tensioning technique: clinical and magnetic resonance imaging results. *Arthroscopy*. 2011;27:1079–1089. <https://doi.org/10.1016/j.arthro.2011.03.002> PMID:21704468
12. Muellner T, Bugge W, Johansen S, Holtan C, Engebretsen L. Inter- and intratester comparison of the Rolimeter knee tester: effect of tester's experience and the examination technique. *Knee Surg Sports Traumatol Arthrosc*. 2001;9:302-306. <https://doi.org/10.1007/s001670100225> PMID:11685363
13. Ganko A, Engebretsen L, Ozer H. The rolimeter: a new arthrometer compared with the KT-1000. *Knee Surg Sports Traumatol Arthrosc*. 2000;8:36-39. <https://doi.org/10.1007/s001670050008> PMID:10663318
14. Corrigan J, Cashman W, Brady M. Proprioception in the cruciate deficient knee. *J Bone Joint Surg*. 1992; 74-B:247-50.
15. C. Löcherbacha, R. Zaynib, P. Chambath, B. Sonnery-Cottet. Biologically enhanced ACL reconstruction. *Orthopaedics & Traumatology: Surgery & Research*. 2010; 96, 810–815. <https://doi.org/10.1016/j.otsr.2010.06.007> PMID:20934932
16. Shelbourne KD, Gray T, Haro M. Incidence of subsequent injury to either knee within 5 years after anterior cruciate ligament reconstruction with patellar tendon autograft. *Am J Sports Med*. 2009;37:246–51. <https://doi.org/10.1177/0363546508325665> PMID:19109531
17. Salmon L, Russell V, Musgrove T, Pinczewski L, Refshauge K. Incidence and risk factors for graft rupture and contralateral rupture after anterior cruciate ligament reconstruction. *Arthroscopy*. 2005;21:948–57. <https://doi.org/10.1016/j.arthro.2005.04.110> PMID:16084292
18. Crain EH, Fithian DC, Paxton EW, et al. Variation in anterior cruciate ligament scar pattern: does the scar pattern affect anterior laxity in anterior cruciate ligament deficient knees? *Arthroscopy*. 2005;21:19–24. <https://doi.org/10.1016/j.arthro.2004.09.015> PMID:15650662
19. Wu B, Zhao Z, Li S, Sun L. Preservation of remnant attachment improves graft healing in a rabbit model of anterior cruciate ligament reconstruction. *Arthroscopy*. 2013;29(8):1362-71. <https://doi.org/10.1016/j.arthro.2013.05.010> PMID:23906275
20. Li Z, Liu Y, Shi B, Wu X, Zhu J, Wang Z, Li Z. [An experimental study on anterior cruciate ligament reconstruction with remnants and remaining bundle preservation]. *Zhongguo Xiu Fu Chong Jian Wai Ke Za Zhi*. 2009;23(3):282-6. PMID:19366134
21. Mifune Y, Ota S, Takayama K, Hoshino Y, Matsumoto T, Kuroda R, Kurosaka M, Fu FH, Huard J. Therapeutic advantage in selective ligament augmentation for partial tears of the anterior cruciate ligament: results in an animal model. *Am J Sports Med*. 2013;41(2):365-73. <https://doi.org/10.1177/0363546512471614> PMID:23299851
22. Gohil S, Annear P.O, Bredahl W. Anterior cruciate ligament reconstruction using autologous double hamstrings: a comparison of standard versus minimal debridement techniques using MRI to assess revascularisation. *J Bone Joint Surg*. 2007;89-B:1165-71. <https://doi.org/10.1302/0301-620X.89B9.19339> PMID:17905952
23. Ahn JH, Lee SH, Choi SH, Lim TK. Magnetic resonance imaging evaluation of anterior cruciate ligament reconstruction using quadrupled hamstring tendon autografts: comparison of remnant bundle preservation and standard technique. *Am J Sports Med*. 2010;38(9):1768-77. <https://doi.org/10.1177/0363546510368132> PMID:20805412
24. Denti M, Monteleone M, Berardi A, Panni AS. Anterior Cruciate Ligament Mechanoreceptors: Histologic Studies on Lesions and Reconstruction. *Clin Orthop*. 1994;308:29-32. <https://doi.org/10.1097/00003086-199411000-00005>
25. Ochi M, Iwasa J, Uchio Y et al. The regeneration of sensory neurons in the reconstruction of the anterior cruciate ligament. *J Bone Joint Surg Br*. 1999;1:902-906. <https://doi.org/10.1302/0301-620X.81B5.9202>
26. Georgoulis AD, Pappa L, Moebius U et al. The presence of proprioceptive mechanoreceptors in the remnants of ruptured ACL as possible source of re-innervation of ACL autograft. *J Knee Surg Sports Traumatol Arthrosc*. 2001;9: 364-368. <https://doi.org/10.1007/s001670100240> PMID:11734875
27. Lee BI, Min KD, Choi HS, Kwon SW, Chun DI, Yun ES, Lee DW, Jin SY, Yoo JH. Immunohistochemical study of mechanoreceptors in the tibial remnant of the ruptured anterior cruciate ligament in human knees. *Knee Surg Sports Traumatol Arthrosc*. 2009;17(9):1095-1101. <https://doi.org/10.1007/s00167-009-0831-z> PMID:19533097
28. Adachi N, Ochi M, Uchio Y et al. Mechanoreceptors in the anterior cruciate ligament contribute to the joint position sense. *Acta Orthop Scand*. 2002;73:330–4. <https://doi.org/10.1080/000164702320155356> PMID:12143983
29. Ahn JH, Lee YS, Ha HC. Anterior cruciate ligament reconstruction with preservation of remnant bundle using hamstring autograft: technical note. *Arch Orthop Trauma Surg*. 2009;129:1011-1015. <https://doi.org/10.1007/s00402-008-0597-7> PMID:18299859