

# Chondrosarcoma of bone in children and adolescents

Yoichi Kaneuchi  
Tomohiro Fujiwara  
Yusuke Tsuda  
Shinichirou Yoshida  
Jonathan D. Stevenson  
Adesegun Abudu

## Abstract

**Purpose** Chondrosarcomas typically present in adults during the fifth to seventh decades and are rare in young patients. The biological behaviour and oncological outcomes may be different in children and adolescents.

**Methods** We retrospectively evaluated the outcomes of all patients with chondrosarcoma of bone who were younger than 18 years of age at the time of diagnosis and were treated at our centre between 1995 and 2018.

**Results** The 15 consecutive patients studied included nine male and six female cases, with a mean age at diagnosis of 13 years (7 to 17). The median follow-up was 117 months (30 to 277). The tumours were primary and secondary in ten and five patients, respectively. The tumours were central in 13 and surface in two patients. The tumour locations were the humerus in five, digits in five, femur in three, radius in one and pelvis in one patient. The histological grades were grade I in seven, grade II in seven and grade III in one patient. The surgical treatments were limb salvage in ten patients and ray amputation in five patients. The surgical margins were wide in eight, marginal in two and intralesional in five patients. All the patients were alive and continuously free of disease at the time of the last follow-up. No patient developed metastases or local recurrence.

**Conclusion** Chondrosarcoma of bone in children and adolescent patients has a very good prognosis and is less aggressive compared with published outcomes in older patients.

**Level of evidence:** IV

Cite this article: Kaneuchi Y, Fujiwara T, Tsuda Y, Yoshida S, Stevenson JD, Abudu A. Chondrosarcoma of bone in children and adolescents. *J Child Orthop* 2020;14:330-334. DOI: 10.1302/1863-2548.14.200046

Royal Orthopaedic Hospital NHS Foundation Trust, Birmingham, UK

Correspondence should be sent to Yoichi Kaneuchi, Oncology Department, The Royal Orthopaedic Hospital NHS Foundation Trust, The Woodlands, Bristol Road South, Birmingham, B31 2AP, UK.  
E-mail: kaneuchi@fmu.ac.jp

**Keywords:** chondrosarcoma of bone; children; adolescents; survival

## Introduction

Chondrosarcoma is a cartilage-forming malignant bone tumour. It is the second most common primary malignant bone tumour following osteosarcoma. It often occurs in middle to old age, with a peak incidence in the fifth to seventh decades of life.<sup>1,2</sup>

Due to the rarity of chondrosarcoma in children and adolescents, there is a scarcity of studies that have described the outcome of this tumour in children.<sup>3-8</sup> Thus, the biological behaviour of chondrosarcomas in young patients is unclear. In some of these studies, the survival rates of paediatric chondrosarcoma were reportedly worse than in adults;<sup>3</sup> in contrast, other studies have reported equivalent survival<sup>4,5</sup> and improved survival in young patients compared with adults.<sup>6</sup> However, none of these studies have concentrated on the outcome of chondrosarcoma in young patients with open and growing physis.

We hypothesized that chondrosarcomas occurring in young patients with open and growing physis may have different characteristics and may have a less biologically aggressive course compared with those occurring after closure of growth plates, i.e. skeletal maturity. The present study was, therefore, aimed at reporting the clinical outcome of conventional chondrosarcoma of bone in patients younger than 18 years old at the time of diagnosis.

## Patients and methods

A retrospective review was conducted of all patients who had been diagnosed with chondrosarcoma between 1st January 1995 and 31st December 2018 at a single tertiary sarcoma centre. We identified 15 patients younger than 18 years of age at the time of diagnosis with a histologically confirmed diagnosis of conventional chondrosarcoma. We excluded patients with variants of chondrosarcoma such as mesenchymal chondrosarcoma and extraskeletal lesions and also excluded patients with chondrosarcomas of the skull, facial bones, and head and neck regions. The patients presented either with pain or enlargement of a previously observed incidental lesion. Surgeries were conducted only when the lesions showed high-grade malignancy by biopsy or low-grade malignancy with rapid progression with or without pain in a few months. In contrast, the unchanged lesions in terms of size which showed

some cellular atypia were considered as a non-malignant lesion such as enchondroma and the lesions were carefully followed up and not considered chondrosarcoma. This study was approved by our institutional review board and all data were collected from the clinical records and imaging systems as part of routine patient follow-up.

The demographic information reviewed included age, gender, predisposition to secondary chondrosarcoma, tumour locations, histological grades, biopsy types, surgical treatment types, surgical margins and tumour stages. The diagnosis of chondrosarcoma in this study was made based on comprehensive review of the clinical, radiological and histopathological findings, not histology alone, by a specialist supra-regional sarcoma multidisciplinary board. The biopsy results, treatment plans and definite diagnosis of surgical specimens were made at the sarcoma multidisciplinary meetings with participating paediatric oncologists, radiologists, bone sarcoma pathologists and oncological orthopaedic surgeons. Tumour staging was determined with the use of the Enneking surgical staging system for bone sarcomas.<sup>9</sup>

Histological grades were divided into three groups (grades I, II and III).<sup>2</sup> The histological grades assigned to the tumours were the highest grades seen on the histology, even when the higher-grade cells comprised a focal region or a small number of cells.

The survival analyses were performed according to the Kaplan-Meier method and log-rank test using SPSS version 26.0 (IBM, Armonk, New York). Event-free survival was defined as lasting from the date of the initial surgery to the date of the surgery for a subsequent chondrosarcoma. Overall survival was defined as lasting from the date of the surgery to the date of the last follow-up. The difference between the survival curves was evaluated by Cox proportional hazard modelling.

## Results

In all, 15 consecutive patients with conventional chondrosarcomas were studied, including nine male and six female cases (Table 1). The mean age at the time of diagnosis was 13 years (7 to 17). Primary and secondary chondrosarcomas occurred in ten (67%) and five (33%) patients, respectively. Secondary chondrosarcomas arose from Ollier's disease in four patients and Maffucci's syndrome in one patient. The tumours were central in 13 (87%) and surface in two patients (13%). The tumour location was in the humerus in five (33%), digits in five (one metacarpal and four phalangeal bone; 33%), femur in three (20%), radius in one (7%) and pelvis in one patient (7%).

All the patients had histological diagnoses of conventional chondrosarcomas. Preoperative biopsy was performed in ten patients, including open biopsy in four and needle biopsy in six. Histological diagnoses were made in three patients after curettage and digital amputations in two patients with radiologically suspected chondrosarcomas (one had Ollier's and the other had Maffucci's syndrome).

The surgical treatment involved limb salvage in ten patients and ray amputation in five patients. In patients who underwent limb salvage, tumours were treated with curettage in five patients, including four patients with grade I and one patient with grade II chondrosarcoma; excision alone in two patients with grade I and III chondrosarcoma; and excision followed by endoprosthetic reconstruction in three patients with grade II chondrosarcoma. In the ten patients who underwent *en bloc* excisions or ray amputations, wide and marginal margins were obtained in eight patients (53%) and two patients (13%), respectively. None of the patients received chemotherapy or radiotherapy. The final histological grades of the surgical

**Table 1** Patient details

	Age/Sex	Site	Diagnosis	Primary/secondary	Surgical treatment/margin	Tumour stage	Follow-up (mths)
1	12/M	Femur	Central grade I CS	Primary	Curettage / I	1A	NED (275)
2	16/M	Humerus	Surface grade I CS	Primary	Excision / W	1B	NED (209)
3	17/M	Radius	Central grade I CS	Primary	Curettage / I	1A	NED (183)
4	17/F	Ilium	Surface grade III CS	Primary	Excision / W	2B	NED (154)
5	17/M	Femur	Central grade I CS	Primary	Curettage / I	1A	NED (117)
6	11/F	Finger	Central grade II CS	Primary	Ray amputation / W	2A	NED (68)
7	10/F	Humerus	Central grade II CS	Primary	Curettage / I	2B	NED (60)
8	10/F	Femur	Central grade I CS	Primary	Curettage + fixation / I	1B	NED (70)
9	17/M	Humerus	Central grade II CS	Primary	Excision + EPR*** / W	2B	NED (30)
10	15/F	Humerus	Central grade II CS	Primary	Excision + EPR**** / M	2B	NED (163)
11	10/M	Humerus	Central grade II CS	Secondary*	Excision + EPR*** / M	2B	NED (102)
12	12/M	Finger	Central grade II CS	Secondary*	Ray amputation / W	2A	NED (277)
13	17/F	Finger	Central grade I CS	Secondary**	Ray amputation / W	1A	NED (252)
14	7/M	Finger	Central grade I CS	Secondary*	Ray amputation / W	1A	NED (62)
15	9/M	Finger	Central grade II CS	Secondary*	Ray amputation / W	2A	NED (96)

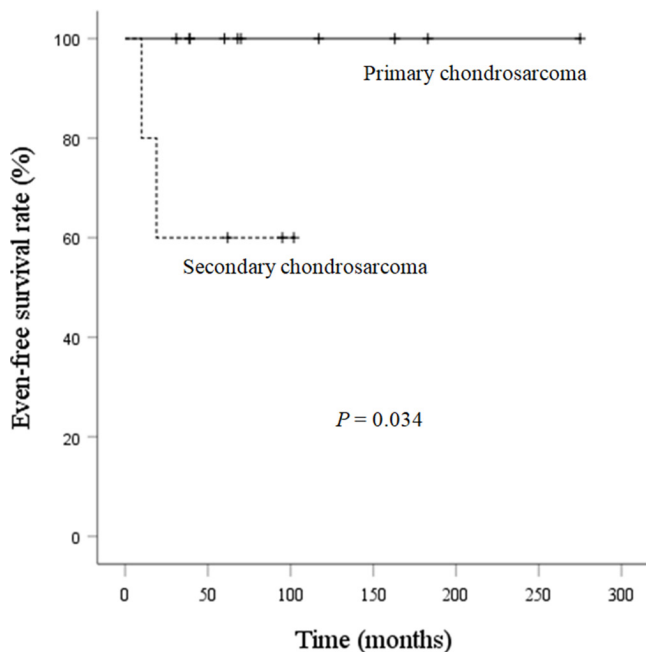
CS, chondrosarcoma; I, intralesional; W, wide; M, marginal; EPR, endoprosthetic replacement; NED, no evidence of disease

\*Ollier's disease

\*\*Maffucci's syndrome

\*\*\*total humeral EPR

\*\*\*\*proximal humeral EPR



**Fig. 1** Kaplan-Meier curve for event-free survival.

specimens were grade I in seven (47%), grade II in seven (47%) and grade III in one (7%) patient.

Event-free survival at five years was 100% in primary chondrosarcoma and 60% in secondary chondrosarcoma due to the development of further chondrosarcoma at other sites in patients with Ollier’s disease or Maffucci’s syndrome (Fig. 1). Patient with Ollier’s disease encountered a subsequent chondrosarcoma at another finger ten months after the initial operation, and another patient with Maffucci’s syndrome developed a subsequent chondrosarcoma at distal radius and below elbow amputation was performed at 19 months after the initial surgery.

Although one patient was lost to follow-up after 30 months, 14 patients were followed up for more than five years with a median follow-up of 117 months (30 to 277). All the patients were alive and continuously free of disease at the time of the last follow-up. No patient developed metastases or local recurrence.

## Discussion

Chondrosarcoma is a disease often associated with middle-aged and older patients.<sup>1,10</sup> It is extremely rare in young patients, with < 7% of all chondrosarcomas occurring in patients younger than 21 years of age at the time of diagnosis.<sup>1,4,5,11</sup> In addition, chondrosarcomas are even more rare in children, with a reported incidence of only 0.9% to 1.6% of chondrosarcomas occurring in patients younger than 18 years of age.<sup>4,5</sup> The 15 patients studied in this series represent only 2.5% of 598 patients treated for chondrosarcoma at our centre over the period of the study. Therefore, there is a paucity of literature on the biological behaviour and prognosis of this tumour in children, with only a few papers having been published.<sup>3-8</sup>

Several of the published papers extend over many decades, over which the diagnosis of bone tumours has significantly evolved, or have included several variants of chondrosarcomas and/or have also included extra-skeletal or head and neck chondrosarcomas, which may have a different pattern of behaviour and prognosis. For example, Aprin et al<sup>7</sup> retrospectively reviewed 12 paediatric and adolescent chondrosarcoma patients (aged from six to 20 years) who were treated at the Children’s Hospital Medical Center in Boston from 1957 to 1980, while Huvos and Marcove<sup>3</sup> described 79 patients with chondrosarcoma under 21 years of age who were diagnosed and treated at the Memorial Hospital for Cancer and Allied Diseases in New York over a period of 54 years, but Huvos’s study was not directly comparable as it included several histological variants (20 mesenchymal chondrosarcomas, eight myxoid chondrosarcomas, five spindle cell chondrosarcomas and one clear cell chondrosarcoma) and two extra-skeletal lesions. Similarly, Wu et al<sup>6</sup> reported a large series of patients with chondrosarcomas who were aged from 0 to 18 years, but most of the tumours were extra-skeletal or head and neck chondrosarcomas.

There are three recent and comparable studies (Table 2).<sup>4,5,8</sup> In the series of the Mayo clinic and their consultation files, Young et al<sup>8</sup> retrospectively reviewed 47 patients with conventional chondrosarcoma less than 17 years of age. In a report from the Rizzoli Institute, Gambarotti et al<sup>4</sup> retrospectively reviewed 17 patients with

**Table 2** Previous reports of children and adolescent chondrosarcoma

Reference	Period (yrs)	Age, yrs (range)	Number of patients (%)	Percentage secondary ChS (%)	Patients per site (%)	Prognosis
Young et al (1990) <sup>8</sup>	N/A	< 17 (3 to 16)	47 (N/A)	26	Humerus 16 (34), femur 11 (23), tibia 5 (11)	N/A
Gambarotti et al (2016) <sup>4</sup>	1981 to 2014	< 18 (13 to 17)	17 (0.9)	35	Femur 7 (41), tibia 4 (24), pelvis 3 (18), humerus 2 (12)	OS 93% (5 to 339 mths)
Puri et al (2019) <sup>5</sup>	2006 to 2016	≤ 21 (14 to 21)	11 (4.4)	55	Pelvis 4 (36), humerus 3 (27)	5-yr OS: 89%
Present study	1995 to 2019	< 18 (7 to 17)	15 (2.5)	33	Humerus 5 (33), digit 5 (33), femur 3 (20), ilium and radius 1 (7)	5-yr OS: 100% 10-yr OS: 100%

N/A, not available, ChS: chondrosarcoma; OS, overall survival

chondrosarcoma under 18 years of age from 1981 to 2014, while Puri et al<sup>5</sup> reported 11 adolescent chondrosarcoma cases (aged from 14 to 21 years) who were operated on at the Tata Memorial Hospital from January 2006 to December 2016.

Secondary chondrosarcomas make up a larger proportion of all chondrosarcomas in children and adolescents compared with adults.<sup>3-5,7,8</sup> Patients with hereditary multiple exostosis, Ollier's disease and Maffucci's syndrome have a higher incidence of secondary chondrosarcomas, and these secondary chondrosarcomas generally present at a younger age than do those in the general population, as confirmed in our series.<sup>12</sup> In our series, five of 15 cases (33%) arose from pre-existing enchondroma lesions (Ollier's disease in four and Maffucci's syndrome in one case).

In general, the pelvis is the most common site of chondrosarcoma, followed by the femur and shoulder girdle.<sup>11-15</sup> The pattern of skeletal distribution in paediatric chondrosarcoma patients, however, might be different than in adults.<sup>4,6,8</sup> In our series, only one case (7%) occurred in the pelvis, and the most common sites were the humerus (33%) and digits (33%). This is similar to the series of Young et al<sup>8</sup> (humerus (34%), femur (23%) and tibia (11%)) and that of Gambarotti et al<sup>4</sup> (pelvic lesion (18%), femur (41%) and tibia (24%)). This discrepancy in tumour location might be one of the reasons for better oncological outcomes in paediatrics than those of adults.

Histological grade has been shown to be a significant predictor of both patient survival and the risk of local recurrence.<sup>16,17</sup> Accurate pathological evaluation in grading is, therefore, crucial. Histopathological grading, however, remains difficult, with the possibility of misdiagnosis.<sup>14,18</sup> Previous studies have described a relatively high discrepancy in grading (43% to 59%) between biopsy specimens and surgically excised specimens.<sup>19,20</sup> This is similar in our series, with a discrepancy between grades noted on biopsy and excised specimens in 42% of patients.

Since chondrosarcomas are generally resistant to both chemotherapy and radiotherapy, surgery remains the mainstay for treatment.<sup>10,17</sup> The recommended treatment for intermediate- and high-grade chondrosarcomas is *en bloc* excision with wide margins followed by reconstruction if limb salvage is undertaken.<sup>10,21</sup> Low-grade central chondrosarcoma in the extremity long bones may be treated with curettage with or without local adjuvant treatment.<sup>10,21</sup> In our series, the five patients treated with curettage included four with grade I and one with grade II tumours with no local recurrence observed in any of these patients.

Huvos and Marcove<sup>3</sup> reported worse survival in paediatric chondrosarcoma than in adult chondrosarcoma. This could be attributed to the study design, which included high-grade chondrosarcoma variants such as mesenchymal

chondrosarcoma. Mesenchymal chondrosarcoma is a highly malignant lesion with a poorer prognosis than conventional chondrosarcoma.<sup>22,23</sup> In addition, Young et al<sup>8</sup> found that chondroblastic osteosarcoma might have been included as chondrosarcoma in Huvos and Marcove's series. Several authors, therefore, disagreed with Huvos and Marcove's conclusion.<sup>4-6,8</sup> In a series of 27 paediatric patients with chondrosarcoma, Young et al<sup>8</sup> reported that five of the eight patients (63%) who underwent curettage and two of the seven patients (29%) who received local excision experienced recurrence but 12 chondrosarcoma patients resected with adequate margins showed no recurrence. Gambarotti et al<sup>4</sup> and Puri et al<sup>5</sup> also showed that grade II chondrosarcoma cases with involved margins had no recurrence more than six years after the surgery. None of the patients in our series with intralesional, marginal or wide margins have developed local recurrence. These data may indicate that paediatric chondrosarcoma has better outcomes than adult chondrosarcoma.

Puri et al<sup>5</sup> reported 89% overall survival and disease-free survival at five years for all patients with chondrosarcomas who were 21 years of age or younger. In our series, both the five-year and ten-year overall survival rates for all patients were 100%; event-free survival at five years was 100% in primary chondrosarcoma and 60% in secondary chondrosarcoma.

Despite the limited number of patients in this and other studies, our study indicates that the prognosis of young patients who develop chondrosarcoma is far better than that of adults.

There are some limitations to this study. First, this is a retrospective and single institutional study. Second, the sample size is small for the purpose of statistical analysis. We did not include other chondrosarcoma variants, such as mesenchymal and dedifferentiated chondrosarcoma or adult patients older than 18 years of age in this study. This study aimed purely to investigate chondrosarcoma in children and adolescent patients.

In conclusion, chondrosarcoma in young patients is rare and has different tumour location characteristics compared with chondrosarcoma in adult patients. Also, chondrosarcomas of the bone in children and adolescent patients has a good prognosis compared with adult chondrosarcomas.

Received 9 March 2020; accepted after revision 17 May 2020.

## COMPLIANCE WITH ETHICAL STANDARDS

### FUNDING STATEMENT

No benefits in any form have been received or will be received from a commercial party related directly or indirectly to the subject of this article.

### OA LICENCE TEXT

This article is distributed under the terms of the Creative Commons Attribution-Non Commercial 4.0 International (CC BY-NC 4.0) licence (<https://creativecommons.org/licenses/by-nc/4.0/>) which permits non-commercial use, reproduction and distribution of the work without further permission provided the original work is attributed.

### ETHICAL STATEMENT

**Ethical approval:** All procedures performed in studies involving human participants were in accordance with the ethical standards of the institutional and/or national research committee and with the 1964 Helsinki declaration and its later amendments or comparable ethical standards.

**Informed consent:** All subjects were given informed consent and agreed to participate in the project.

### ICMJE CONFLICT OF INTEREST STATEMENT

None declared.

### AUTHOR CONTRIBUTION

**YK:** Conception and design, Acquisition of the data, Analysis and interpretation of the data, Drafting of the article, Collection and assembly of data.

**TF:** Conception and design, Acquisition of the data, Analysis and interpretation of the data, Drafting of the article, Critical revision of the article for important intellectual content, Final approval of the article.

**YT:** Conception and design, Acquisition of the data, Analysis and interpretation of the data, Drafting of the article, Final approval of the article.

**SY:** Conception and design, Acquisition of the data, Analysis and interpretation of the data, Drafting of the article, Final approval of the article.

**JDS:** Conception and design, Drafting of the article, Critical revision of the article for important intellectual content, Final approval of the article.

**AA:** Conception and design, Analysis and interpretation of the data, Drafting of the article, Critical revision of the article for important intellectual content, Final approval of the article.

### REFERENCES

1. **Unni KK, Inwards CY.** Chondrosarcoma (primary, secondary, dedifferentiated, and clear cell). In *Dahlin's bone tumors: general aspects and data on 10,165 cases*. 6th ed. Philadelphia, PA: Lippincott Williams & Wilkins, 2010:60–91.
2. **Hogendoorn PCW, Bovée JVMG, Nielsen GP.** Chondrosarcoma (grades I–III), including primary and secondary variants and periosteal chondrosarcoma. In: Fletcher CDM, Bridge JA, Hogendoorn PCW, Mertens F, eds. *World Health Organization classification of tumours. Pathology and genetics of tumours of soft tissue and bone*. Lyon: IARC Press, 2013:264–268.
3. **Huvos AG, Marcove RC.** Chondrosarcoma in the young. A clinicopathologic analysis of 79 patients younger than 21 years of age. *Am J Surg Pathol* 1987;11:930–942.
4. **Gambarotti M, Righi A, Picci P, et al.** Paediatric chondrosarcomas: a retrospective review of 17 cases. *Histopathology* 2016;68:1073–1078.
5. **Puri A, Gulia A, Kurisunkal VJ, Sukumar V, Rekhi B.** Chondrosarcomas in adolescents: are they different? *J Pediatr Orthop B* 2019 July 11. (Epub ahead of print)

6. **Wu AM, Li G, Zheng JW, et al.** Chondrosarcoma in a paediatric population: a study of 247 cases. *J Child Orthop* 2019;13:89–99.
7. **Aprin H, Riseborough EJ, Hall JE.** Chondrosarcoma in children and adolescents. *Clin Orthop Relat Res* 1982;166:226–232.
8. **Young CL, Sim FH, Unni KK, McLeod RA.** Chondrosarcoma of bone in children. *Cancer* 1990;66:1641–1648.
9. **Enneking WF, Spanier SS, Goodman MA.** A system for the surgical staging of musculoskeletal sarcoma. *Clin Orthop Relat Res* 1980;153:106–120.
10. **Gelderblom H, Hogendoorn PC, Dijkstra SD, et al.** The clinical approach towards chondrosarcoma. *Oncologist* 2008;13:320–329.
11. **Lee FY, Mankin HJ, Fondren G, et al.** Chondrosarcoma of bone: an assessment of outcome. *J Bone Joint Surg [Am]* 1999;81-A:326–338.
12. **Soldatos T, McCarthy EF, Attar S, Carrino JA, Fayad LM.** Imaging features of chondrosarcoma. *J Comput Assist Tomogr* 2011;35:504–511.
13. **Fiorenza F, Abudu A, Grimer RJ, et al.** Risk factors for survival and local control in chondrosarcoma of bone. *J Bone Joint Surg [Br]* 2002;84-B:93–99.
14. **Stevenson JD, Laitinen MK, Parry MC, et al.** The role of surgical margins in chondrosarcoma. *Eur J Surg Oncol* 2018;44:1412–1418.
15. **Björnsson J, McLeod RA, Unni KK, Ilstrup DM, Pritchard DJ.** Primary chondrosarcoma of long bones and limb girdles. *Cancer* 1998;83:2105–2119.
16. **Bus MPA, Campanacci DA, Albergio JI, et al.** Conventional primary central chondrosarcoma of the pelvis: prognostic factors and outcome of surgical treatment in 162 patients. *J Bone Joint Surg [Am]* 2018;100:316–325.
17. **Giuffrida AY, Burgueno JE, Koniaris LG, et al.** Chondrosarcoma in the United States (1973 to 2003): an analysis of 2890 cases from the SEER database. *J Bone Joint Surg [Am]* 2009;91-A:1063–1072.
18. **Flanagan AM, Lindsay D.** A diagnostic approach to bone tumours. *Pathology* 2017;49:675–687.
19. **Roitman PD, Farfalli GL, Ayerza MA, et al.** Is needle biopsy clinically useful in preoperative grading of central chondrosarcoma of the pelvis and long bones? *Clin Orthop Relat Res* 2017;475:808–814.
20. **Laitinen MK, Stevenson JD, Parry MC, et al.** The role of grade in local recurrence and the disease-specific survival in chondrosarcomas. *Bone Joint J* 2018;100-B:662–666.
21. **Gerrand C, Athanasou N, Brennan B, et al.** UK guidelines for the management of bone sarcomas. *Clin Sarcoma Res* 2016;6:7.
22. **Tsuda Y, Ogura K, Hakozaki M, et al.** Mesenchymal chondrosarcoma: A Japanese Musculoskeletal Oncology Group (JMOG) study on 57 patients. *J Surg Oncol* 2017;115:760–767.
23. **Frezza AM, Cesari M, Baumhoer D, et al.** Mesenchymal chondrosarcoma: prognostic factors and outcome in 113 patients. A European Musculoskeletal Oncology Society study. *Eur J Cancer* 2015;51:374–381.