

Received: 2022.01.19

Accepted: 2022.04.15

Available online: 2022.04.28

Published: 2022.06.03

The Triad of Legionnaires' Disease, Rhabdomyolysis, and Acute Kidney Injury: A Case Report

Authors' Contribution:

Study Design A
Data Collection B
Statistical Analysis C
Data Interpretation D
Manuscript Preparation E
Literature Search F
Funds Collection G

EF 1 **Andrew S. Kao**
E 2 **Chandima J. Herath**
EF 2 **Rana Ismail**
E 2 **Malitha E. Hettiarachchi**

1 Department of Internal Medicine, Wayne State University School of Medicine, Detroit, MI, USA
2 Department of Internal Medicine, Detroit Medical Center Sinai Grace Hospital, Detroit, MI, USA

Corresponding Author: Andrew S. Kao, e-mail: andrew.kao@med.wayne.edu
Financial support: None declared
Conflict of interest: None declared

Patient: Female, 62-year-old
Final Diagnosis: Legionnaires' disease
Symptoms: Acute kidney injury • rhabdomyolysis
Medication: —
Clinical Procedure: —
Specialty: General and Internal Medicine

Objective: Unusual clinical course
Background: *Legionella* infection is a common cause of atypical pneumonia, known as Legionnaires' disease when infection extends to extrapulmonary involvement, which often leads to hospitalization. The triad of *Legionella* pneumonia, rhabdomyolysis, and renal failure displays a rare yet fatal complication without prompt management.
Case Report: Our patient was a 62-year-old man with no significant medical history who developed Legionnaires' disease with severely elevated creatinine phosphokinase (CPK) of 9614 mcg/L, consistent with rhabdomyolysis. He experienced severe headache, anorexia, and hematuria, which prompted him to seek medical care. Pertinent social history included recent flooding in his neighborhood, which surrounded the outer perimeter of his home. His clinical manifestations and laboratory findings were consistent with *Legionella* infection, with concomitant acute kidney injury. A chest X-ray revealed hazy left perihilar opacities concerning for atypical pneumonia. Immediate interventions of hydration and antigen-directed azithromycin were initiated to prevent rapid decompensation. His clinical symptoms resolved without further complications, and he was not transferred to the Intensive Care Unit (ICU).
Conclusions: *Legionella*-induced rhabdomyolysis is an uncommon association that can lead to acute kidney failure and rapid clinical deterioration. Early and aggressive management with fluid repletion and appropriate antibiotics can improve clinical manifestations and hospital length of stay. Our patient's reduction in CPK levels and clinical improvement confirmed that extrapulmonary involvement in *Legionella* infection can lead to rhabdomyolysis. It is important for healthcare providers to recognize the clinical triad of *Legionella* pneumonia, rhabdomyolysis, and renal failure as prompt and timely management to reduce associated morbidity.


Keywords: Acute Kidney Injury • Legionnaires' Disease • Rhabdomyolysis

Full-text PDF: <https://www.amjcaserep.com/abstract/index/idArt/936264>

 1285

 —

 3

 14


Background

Legionella is a gram-negative, intracellular bacterium that invades and replicates in alveolar macrophages, causing pneumonia as the primary manifestation. Outbreaks are associated with inhalation of contaminated aerosolized water droplets from swimming pools, air conditioners, cooling towers, hot tubs, humidifiers, medication nebulizers, or potting soil [1]. *Legionella* accounts for 2-15% of community-acquired pneumonia and is the second most common cause of severe pneumonia requiring admission into the ICU [2]. The mortality rate associated with community-acquired and nosocomial sources are 42% and 79%, respectively [3]. Although the disease mainly manifests in the lungs, its extrapulmonary involvement in other organs includes the integumentary (eg, skin and soft tissue infection), musculoskeletal (eg, septic arthritis, osteomyelitis, or rhabdomyolysis), cardiovascular (eg, myocarditis or pericarditis), gastrointestinal (eg, peritonitis), renal or urinary (eg, pyelonephritis), and neurological (eg, meningitis or brain abscess) systems [4]. Here, we present a case of an uncommon association of Legionnaires' disease with rhabdomyolysis leading to acute kidney injury.

Case Report

A 62-year-old previously healthy man presented to the hospital with a 4-day history of worsening fever and fatigue, not alleviated by ibuprofen. The patient experienced headache, anorexia, knee pain, and hematuria but denied cough, dyspnea, sputum production, chest pain, abdominal pain, nausea, vomiting, constipation, or diarrhea. He had no recent travel or exposure to sick contacts. The patient had received his primary series vaccines for COVID-19. He described himself as a social drinker, non-smoker, and nonuser of illicit or recreational substances. He noted a recent flood on his street due to heavy rain, with the flooding confined to the household surroundings.

On admission, the patient was febrile at 39.5°C and tachycardic at 120 beats per minute, fulfilling 2 of the Systemic Inflammatory Response Syndrome (SIRS) criteria. On physical examination, he was shivering and lung crackles were detected in the left middle and lower lobe on auscultation. His basic metabolic panel showed CPK at 9614 mcg/L (reference: 30-223 mcg/L), ALT at 83 U/L (reference: 7-52 U/L), AST at 255 U/L (reference: 13-39 U/L), creatinine at 1.41 mg/dL (reference: 0.7-1.3 mg/dL), hyponatremia at 129 mEq/L (reference: 136-145 mEq/L), and hypophosphatemia 1.8 mg/dL (reference 2.5-4.5 mg/dL). Potassium was 3.6 mEq/L (3.5-5.1 mEq/L) and BUN was 22 mg/dL (reference: 7-25 mg/dL). His WBC count was within normal limits at 6.2 K/mm³ (reference: 3.5-10.6 K/mm³). Urinalysis detected hematuria, proteinuria, and nitrites. A chest X-ray showed hazy left perihilar opacities, suggestive

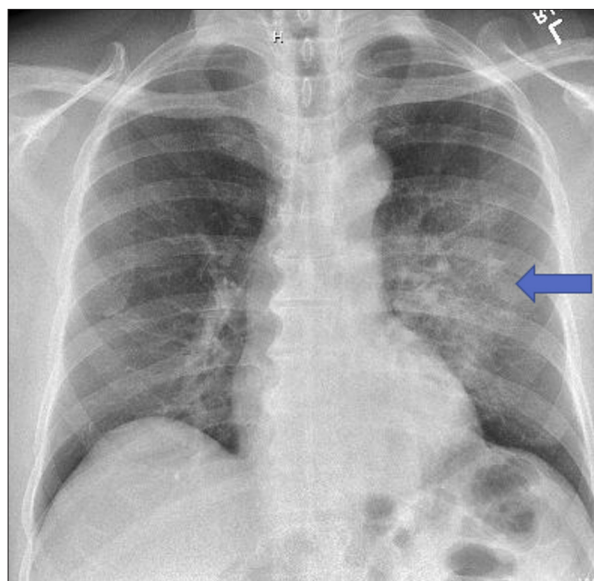


Figure 1. Chest X-ray on initial presentation. Hazy left perihilar opacities indicated a likely diagnosis of atypical bacterial pneumonia.

of pneumonia (**Figure 1**). He was started on i.v. 0.9% NaCl isotonic fluid, azithromycin, and cephalexin.

Differential diagnoses at the time were sepsis secondary to *Legionella* pneumonia, *Streptococcus pneumoniae*, or SARS-CoV-2 (the virus that causes COVID-19) infection. Cephalexin was discontinued upon urine antigen test result only positive to *Legionella pneumophila* and not *Streptococcus pneumoniae*. His SARS-CoV-2 test result was negative. He was continued on daily i.v. azithromycin 500 mg for the recommended 7-day treatment. Renal biopsy, abdominal ultrasonography, and additional biochemical tests were not further performed, as his rhabdomyolysis, acute kidney injury, hematuria, and hyponatremia were resolved without residual symptoms. Upon discharge, he was hemodynamically stable with CPK 4976 mcg/L, ALT 80 U/L, and AST 146 U/L; creatinine, sodium and phosphorus levels were normalized to 0.75 mg/dL, 136 mEq/L, and 2.5 mg/dL, respectively.

Discussion

The case report highlights the need to recognize possible environmental exposures to pathogens implicated in disease causation, as this patient's exposure to sewage-contaminated pluvial floods near his house predisposed him to infection by *Legionella* strains, especially *L. pneumophila* [5]. The pathophysiology of *Legionella*-induced rhabdomyolysis remains unclear. One theory postulated a mechanism of a direct bacterial infection into myocytes, similar to that of influenza virus [6]. Another theory suggested the release of bacterial endotoxin into the bloodstream, causing a vasoconstrictive effect and

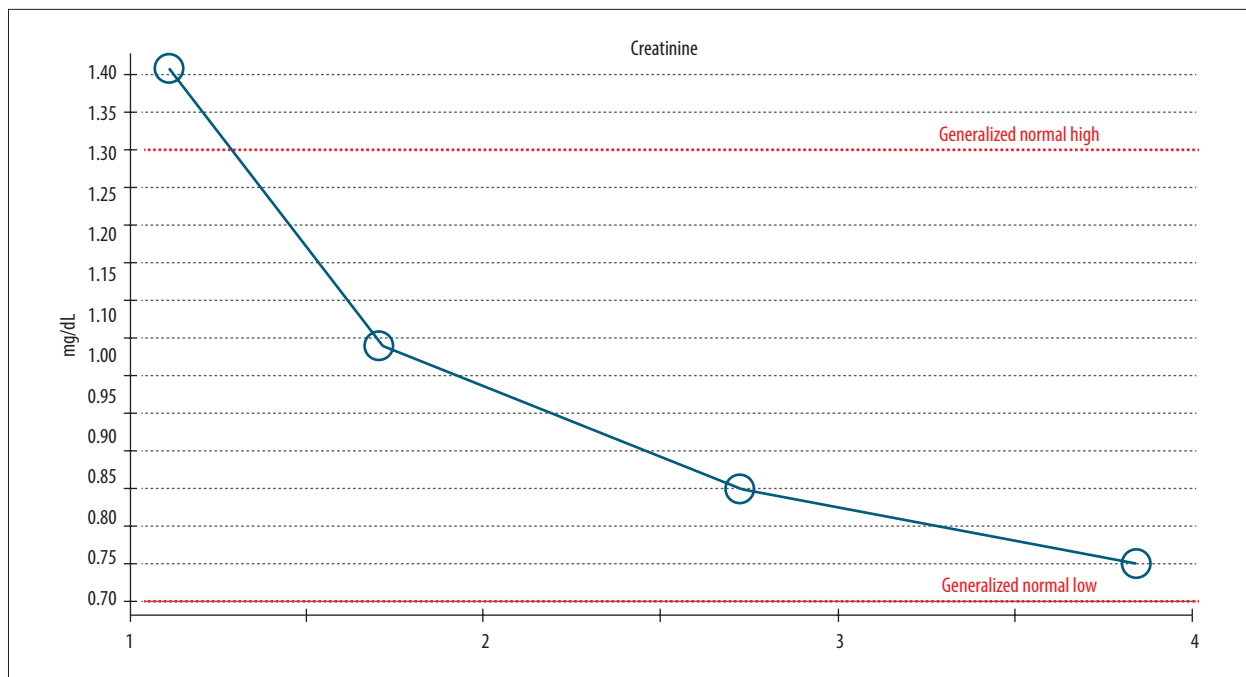


Figure 2. Creatinine trend during hospital stay. Creatinine level was elevated at 1.41 mg/dL on admission and gradually stabilized to a baseline of 0.75 mg/dL by discharge.

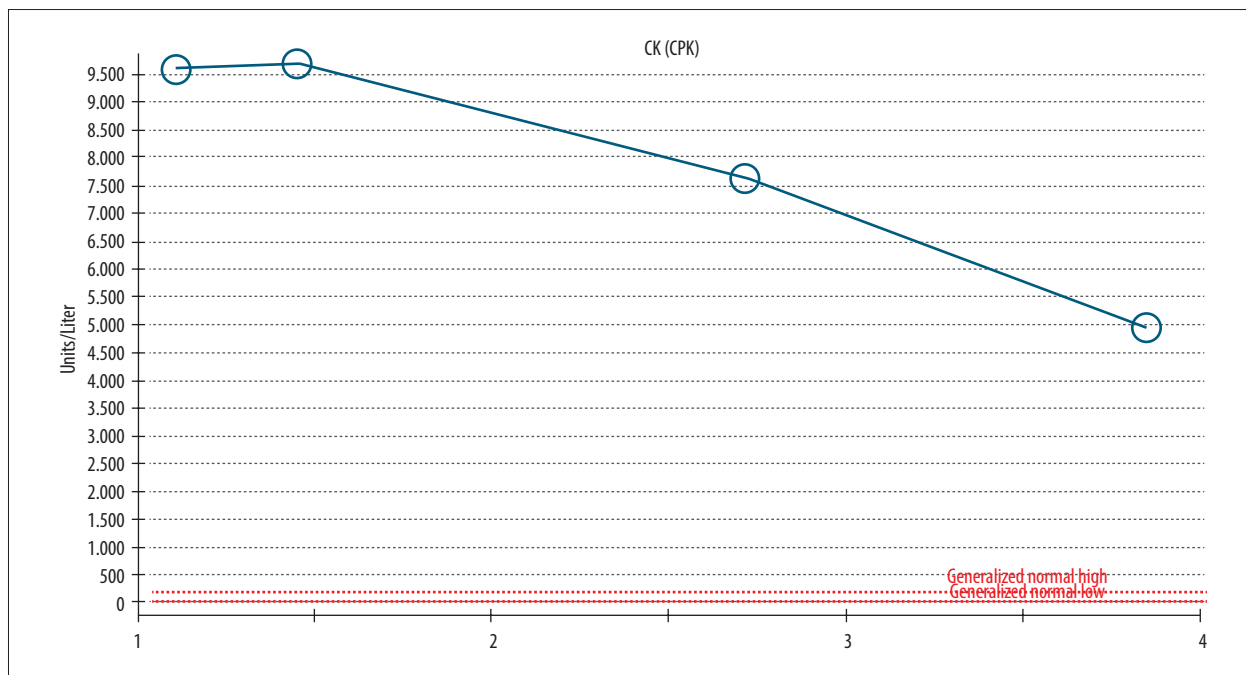


Figure 3. Creatinine phosphokinase (CPK) trend during the hospital stay. CPK level was elevated at 9614 mcg/L on admission, peaked at 9710 mcg/L on repeat blood draw, and trended down to 4976 mcg/L by discharge.

local ischemic damage to myocytes [7,8]. *Legionella*-induced rhabdomyolysis is a rare association, with few published cases in the literature since 1980 [9,10]. Except for 2 patients, all survived with proper antibiotics and aggressive intravenous rehydration or dialysis. Rhabdomyolysis caused by infectious

agents is a peculiar phenomenon, with *Legionella* remaining the most common causative agent, followed by *Streptococcus* species. Other infectious agents include *Plasmodium* or *Candida* species, while viral agents include influenza A and B, HIV, Epstein-Barr virus, herpes simplex, and cytomegalovirus [9].

Rhabdomyolysis caused by bacteria is associated with high mortality and morbidity, with 57% of cases leading to acute renal failure and 38% of cases leading to death [11].

Legionnaires' disease is a severe manifestation of *Legionella* pneumonia with lung involvement and concomitant dissemination to other organ systems. The typical clinical presentation includes headache, shortness of breath, and fever that precede cough after exposure to contaminated soil or water source. Lung examination can reveal parenchymal consolidation with pronounced fremitus and crackles confirmed by radiographic findings of patchy unilobar infiltrates. Distinct clinical signs of Legionnaires' disease include hyponatremia, hematuria, proteinuria, and gastrointestinal symptoms of nausea, vomiting, and diarrhea. Life-threatening complications requiring immediate medical attention are septic shock, respiratory failure, and acute kidney failure [12]. Our patient met 2 systemic inflammatory response syndrome criteria on admission – fever and tachycardia – but he remained hemodynamically stable. Interestingly, his leukocyte count was within normal limits on initial presentation and throughout the hospital stay. His laboratory findings were consistent with acute kidney injury: elevated creatinine 1.41 mg/dL, hematuria, and proteinuria on urinalysis. The elevated serum creatinine phosphokinase (CPK) of 9614 IU/L was indicative of rhabdomyolysis, depicting intrarenal kidney injury and mostly intact renal filtration function. On discharge, his creatinine level was normalized (Figure 2); CPK remained elevated but had decreased significantly (Figure 3). In addition to chest X-ray showing right diaphragmatic eventration (Figure 1), his elevated transaminase levels only showed a moderate decrease with AST higher than ALT, suggestive of possible underlying fatty liver disease secondary to chronic alcohol use. However, extrapulmonary involvement of gastrointestinal tracts with concomitant rhabdomyolysis has been documented in the literature [13].

Management of the rhabdomyolysis with acute kidney injury is aggressive isotonic fluid administration, which resolved our patient's electrolyte and metabolic abnormalities. The first-line treatment of Legionnaires' disease is empiric therapy with fluoroquinolones or macrolide monotherapy, or in combination with beta-lactam after ruling out *Streptococcus* species

by bacterial culture. In our case, subsequent renal biopsy to confirm *Legionella*-induced acute kidney injury was not performed, as the patient exhibited rapid clinical improvement to standard management of fluids and azithromycin. A biopsy result was unlikely to alter the treatment course. Antibiotic selection varies with infection severity and involvement of extrapulmonary sites. The minimum duration of therapy is 5 to 7 days for clinically stable patients, whereas severe infections require 7 to 10 days of therapy. Patients with extrapulmonary involvement such as cellulitis, endocarditis, myocarditis, or septic arthritis are often treated with fluoroquinolone [14]. Possible complications such as empyema or lung abscess can arise in recalcitrant cases.

Conclusions

The literature on *Legionella*-induced rhabdomyolysis is scant, as it is an uncommon association that can lead to acute kidney failure and rapid clinical deterioration. This case report demonstrates the value of collecting detailed social history to assess the potential for the living environment to contribute to disease development. A high index of suspicion is needed to initiate early and aggressive management to reduce disease severity and hospital length of stay. In this case, the patient's subsequent reduction in CPK levels and clinical improvement confirmed extrapulmonary involvement of the kidneys due to *Legionella* infection. It is important for providers to recognize this clinical triad of *Legionella* pneumonia, rhabdomyolysis, and renal failure, as timely management can reduce disease-associated morbidity and mortality.

Department and Institution Where Work Was Completed

Department of Internal Medicine, Detroit Medical Center Sinai Grace Hospital, Detroit, MI, USA.

Declaration of Figures' Authenticity

All figures submitted have been created by the authors who confirm that the images are original with no duplication and have not been previously published in whole or in part.

References:

1. McConkey J, Obeisi M, Valentini J, et al. *Legionella* pneumonia presenting with rhabdomyolysis and acute renal failure: A case report. *J Emerg Med*. 2006;30(4):389-92
2. Koufakis T, Gabranis I, Chatzopoulou M, et al. Severe Legionnaires' disease complicated by rhabdomyolysis and clinically resistant to moxifloxacin in a splenectomised patient: too much of a coincidence? *Case Rep Infect Dis*. 2015;2015:793786
3. Straus WL, Plouffe JF, File TM Jr, et al. Risk factors for domestic acquisition of legionnaires disease. Ohio legionnaires Disease Group. *Arch Intern Med*. 1996;156(15):1685-92
4. Patel H, Shelley P, Hatoum H. Hypertriglyceridemia and massive rhabdomyolysis in a patient with disseminated *legionella*. *Respir Med Case Rep*. 2020;32:101321
5. Schalk JA, Docters van Leeuwen AE, Lodder WJ, et al. Isolation of *Legionella pneumophila* from pluvial floods by amoebal coculture. *Appl Environ Microbiol*. 2012;78(12):4519-21
6. Parikh M, Dolson G, Ramanathan V, et al. Novel H1N1-associated rhabdomyolysis leading to acute renal failure. *Clin Microbiol Infect*. 2010;16:330-32
7. Kaufman D, Weber K, Gradon JD. *Legionella* pneumonia: An unusual cause of rhabdomyolysis and acute renal failure. *South Med J*. 2002;95:660

8. Williams ME, Watanakunakorn C, Baird IM, et al. Legionnaires' disease with acute renal failure. *Am J Med Sci.* 1980;279(3):177-83
9. Soni AJ, Peter A. Established association of *legionella* with rhabdomyolysis and renal failure: A review of the literature. *Respir Med Case Rep.* 2019;28:100962
10. Sutarjono B, Alexis J, Sachidanandam JC. *Legionella* pneumonia complicated by rhabdomyolysis. *BMJ Case Rep.* 2019;12(6):e229243
11. Singh U, Scheld WM. Infectious etiologies of rhabdomyolysis: Three case reports and review. *Clin Infect Dis.* 1996;22(4):642-49
12. Solanki J, Roberts A. Legionnaires' disease: A fatal form of community-acquired pneumonia. *Chest Journal.* 2021;160(4S):A297
13. Laivier C, Bleuze MO, Hantson P, Devos J. Extreme rhabdomyolysis, acute renal failure, and protracted ileus in a case of *legionella* pneumonia. *Case Rep Crit Care.* 2019;2019:3472627
14. Lowry PW, Tompkins LS. Nosocomial legionellosis: A review of pulmonary and extrapulmonary syndromes. *Am J Infect Control.* 1993;21(1):21-27