

CASE REPORT

Management of a Mobile Floating Carotid Plaque Responsible for Calcified Cerebral Emboli: A Double Sword of Damocles

Jean Sénémaud^{a,*}, Gaël Bounkong^a, Lilia Seddik^b, Asma Jaziri^a, Joseph Touma^a

^a Department of Vascular Surgery, Henri Mondor University Hospital, Créteil, France

^b Department of Neurology, Henri Mondor University Hospital, Créteil, France

Introduction: The management of a rare case of calcified cerebral emboli associated with a mobile carotid plaque (MCP) is reported and discussed.

Report: A 76 year old patient presented with sudden weakness of the left lower limb one month ago, which resolved spontaneously. A cerebral magnetic resonance imaging showed recent multiple infarcts in the right middle cerebral artery (MCA) territory. Computed tomography cerebral angiogram (CTA) revealed calcified cerebral emboli (CCE) in the right MCA territory and an isolated calcified embolus in the M3 segment of the right MCA. No calcification was observed in the aorta. The echocardiogram findings were normal. Trans-oesophageal echocardiography did not show aortic or mitral valve calcifications. A cervical duplex ultrasound (DUS) was performed and demonstrated a highly mobile carotid plaque located in the right carotid bifurcation, contrasting with static CTA imaging showing a common calcified plaque, probably because the plaque appeared against the carotid wall during image acquisition. Antiplatelet and anticoagulation therapy were initiated, and carotid endarterectomy was performed on day two to prevent further embolisation. One month follow up including carotid DUS was satisfactory.

Discussion: A case of mobile carotid plaque responsible for CCE which was diagnosed with DUS dynamic imaging is described, emphasizing the importance of multimodal imaging in such settings. Though the treatment of MCP remains controversial because of the paucity of published cases, carotid endarterectomy was considered to be the safest option to prevent recurrent stroke. Additional clinical data including large series and controlled trials are required to determine the best management of mobile carotid plaques with less than 50% diameter carotid stenosis.

© 2019 The Authors. Published by Elsevier Ltd on behalf of European Society for Vascular Surgery. This is an open access article under the CC BY-NC-ND license (<http://creativecommons.org/licenses/by-nc-nd/4.0/>).

Article history: Received 20 September 2019, Revised 18 November 2019, Accepted 26 November 2019

Keywords: Calcified cerebral emboli, Endarterectomy, Mobile carotid plaque, Stroke, Ultrasonography

CASE REPORT

A 76 year old patient presented to his primary care physician (PCP) with pain in the left ankle. His medical history included tobacco use and overweight. After careful examination, the patient also described an episode of sudden weakness of the left lower limb which lasted a couple of minutes and spontaneously resolved one month ago. The PCP requested urgent cerebral magnetic resonance imaging (MRI) which showed recent multiple infarcts in the right middle cerebral artery (MCA) territory (Fig. 1). The patient was then referred to a tertiary hospital. On admission, the patient's National Institutes of Health Stroke Scale was 0.

No carotid bruit was noted during physical examination. Echocardiogram findings were normal. A computed tomography cerebral angiogram (CTA) revealed calcified cerebral emboli (CCE) in the right MCA territory (Fig. 2A) and an isolated calcified embolus in the M3 segment of the right MCA (Fig. 2B) which were not observed on the cerebral MRI. The CTA also showed a calcified right carotid bifurcation plaque without significant stenosis (Fig. 2C and D). No calcification was observed in the aorta. Transoesophageal echocardiography showed normal ventricular volume and wall thickness along with an ejection fraction of 58%. No aortic or mitral valve calcifications were reported. Though the cervical CTA only revealed an ordinary calcified plaque in the anterior wall of the right carotid bifurcation, a cervical duplex ultrasound (DUS, Toshiba Aplio 500) was still performed. It demonstrated a typical "jelly fish sign" (i.e. a floating hyperechogenic plaque, mobile with the cardiac cycle) of a mobile carotid plaque (MCP) located in the right carotid bifurcation. The MCP produced a stenosis of less than 50% using the North American Symptomatic Carotid

* Corresponding author. Department of Vascular Surgery, Henri Mondor University Hospital 51 avenue du Maréchal de Lattre de Tassigny, 94010 Créteil, France. (Jean Sénémaud).

E-mail address: jeannicolas.senemaud@aphp.fr (Jean Sénémaud).

2666-688X/© 2019 The Authors. Published by Elsevier Ltd on behalf of European Society for Vascular Surgery. This is an open access article under the CC BY-NC-ND license (<http://creativecommons.org/licenses/by-nc-nd/4.0/>).

<https://doi.org/10.1016/j.ejvssr.2019.11.004>

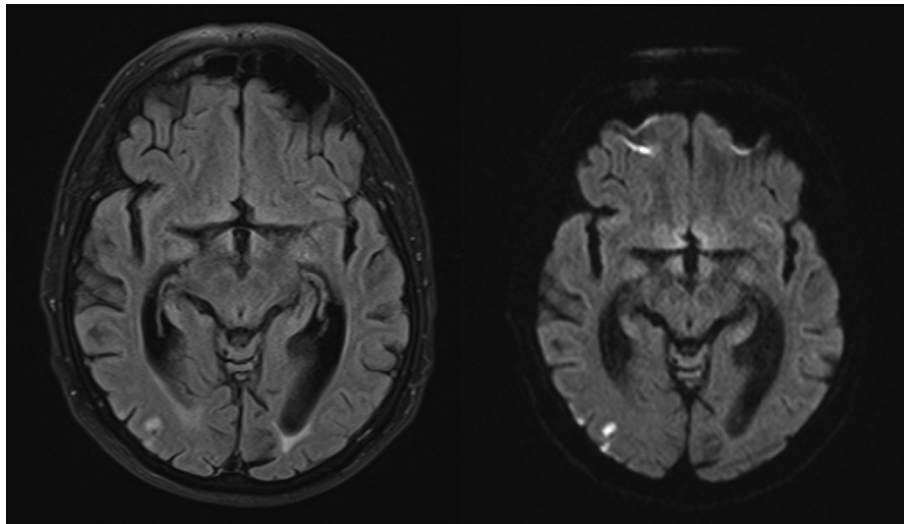


Figure 1. Axial fluid attenuated inversion recovery (left) and diffusion weighted imaging (right) showing multiple areas of hypersignal and restricted diffusion consistent with multifocal recent ischaemia in the right middle cerebral artery territory.

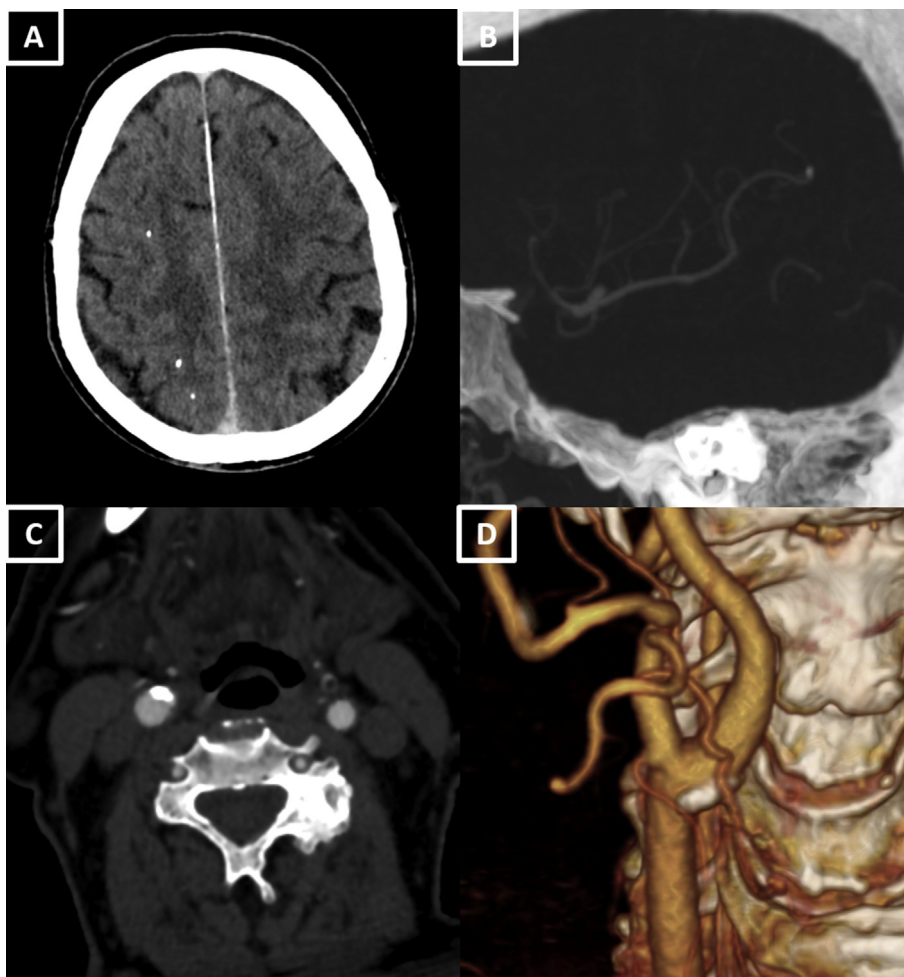


Figure 2. (A) Axial contrast enhanced cerebral computed tomography cerebral angiogram (CTA) showing multiple calcified cerebral emboli in the right middle cerebral artery (B) Calcified embolus in the M3 segment of the right middle cerebral artery seen in multiplanar reconstruction (C) Axial cervical CTA showing a calcified right carotid plaque without significant stenosis (D) Three dimensional CTA reconstruction of the right carotid bifurcation.

Endarterectomy Trial (NASCET) method (Fig. 3, Supplemental Video). Antiplatelet and anticoagulation therapy were initiated in order to prevent the formation of

thrombus. A high dose of statin (atorvastatin, 80mg daily) was also given. Right carotid endarterectomy was performed on day two to prevent further migration. The

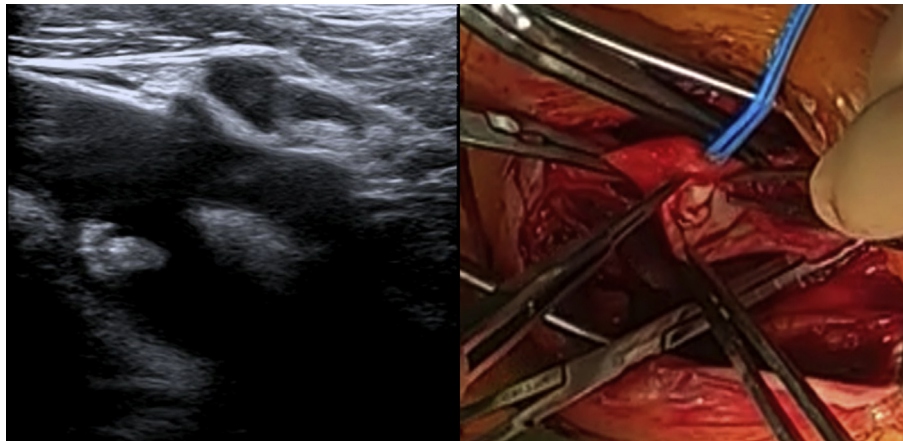


Figure 3. Cervical duplex ultrasound showing a mobile, ruptured internal carotid plaque (left). Per-operative findings showing the floating plaque through the carotid arteriotomy (right).

procedure took place under general anaesthesia. An ulcerated atherosclerotic plaque located in the right carotid bifurcation (Fig. 3) was found. Histopathological findings confirmed the diagnosis of ulcerated, ruptured plaque, showing intraplaque haemorrhage and calcifications. The post-operative course was uneventful and the patient was discharged home eight days post-operatively after obtaining stable blood pressure control. The anticoagulation therapy was stopped immediately after surgery. The one month DUS showed a satisfactory surgical result.

Supplementary video related to this article can be found at <https://doi.org/10.1016/j.ejvssr.2019.11.004>.

The following is/are the supplementary data related to this article: Video11

DISCUSSION

A case of calcified cerebral emboli secondary to a mobile carotid plaque embolism is reported. Calcified cerebral emboli were previously considered a rare entity but a recent study suggested a 5.9% prevalence among patients presenting with acute ischaemic stroke.¹ The main sources of CCE include calcified aortic stenosis (up to 36% of cases), carotid atherosclerotic plaque (30%) and mitral annular calcifications (11%).² The stroke recurrence rate is higher in cases of CCE than in conventional thrombo-embolism, rising to 43% according to recent findings.² CCE therefore represents a “Sword of Damocles”, highlighting the urgent need to diagnose CCE as early as possible to treat its cause.

Approximately one fifth of all ischaemic strokes are thought to be secondary to carotid artery atherosclerosis.³ In this case, a ruptured, mobile carotid plaque was the cause of multiple CCE in the right MCA territory after ruling out aortic or cardiac cause when using dynamic extracranial carotid imaging. Mobile carotid plaques, also described as free floating carotid thrombi, are a poorly defined entity encompassing various presentations such as floating plaque, plaque thrombus, and intraluminal thrombus of the carotid artery. Though MCP may have different clinical

implications, they are considered as having a high short term risk of recurrent ischaemic event.⁴ Compared with atherosclerotic carotid disease, patients with MCP are younger, predominantly male and present with transient neurological symptoms.⁵ The most common aetiology is a complicated atherosclerotic carotid plaque but various medical conditions were described in the settings of MCP such as malignancy, pregnancy, inflammatory and infectious states.⁶ In this case, both DUS and histopathological examination assessed the ruptured nature of an atherosclerotic carotid plaque. Retrospective studies using DUS imaging suggest an incidence of 1/2000.⁷ but this is probably an underestimate, since the majority of studies report symptomatic cases only. Diagnosis may be allowed using standard carotid artery imaging including duplex ultrasound, computed tomography, or MRI angiography. In this case, DUS dynamic imaging was of paramount importance as it was able to diagnose the mobile nature of the carotid plaque, unlike the static CTA imaging which was first considered as normal, probably because the plaque was placed against the carotid wall during image acquisition.

In the settings of symptomatic carotid stenosis, the use of high dose statin has been proven to reduce the risk of further cardiovascular events and to stabilise the vulnerable plaques.⁸ Though the right carotid stenosis was <50%, surgical treatment by carotid endarterectomy was considered the most appropriate choice to suppress the risk of embolism for several reasons: though the antithrombotic therapy may lead to the dissolution of free floating thrombi,⁵ it is unlikely to be effective on atherosclerotic calcified floating carotid plaques as presented in this case, especially when responsible for calcified cerebral emboli. Cases of carotid artery occlusion have also been described during medical treatment alone.⁹ Moreover, the ischaemic recurrence risk was considered to be high because of the presence of both CCE and the threatening, highly mobile nature of the calcified mobile carotid plaque. And finally, carotid endarterectomy is a well established procedure associated with an acceptable post-operative stroke rate.^{5,8} The surgery was performed a month after the initial onset

of symptoms and was considered a delayed procedure, being less at risk of stroke compared with early surgery.⁶

In the literature, the use of carotid artery stenting as an alternative to CEA in the setting of MCP has been described¹⁰ but requires multiples steps (carotid catheterisation, cerebral protection device positioning, stenting itself) which might theoretically cause plaque dislodgment and cerebral embolism.

CONCLUSION

In this case, a highly mobile carotid plaque was missed on static CTA and MRI imaging, highlighting the importance of additional dynamic extracranial carotid evaluation by duplex ultrasound. Though the treatment of MCP remains controversial because of the paucity of published cases, carotid endarterectomy was considered to be the safest option to prevent recurrent stroke by eliminating the MCP. In selected cases, carotid endarterectomy should be considered even though the diameter stenosis is <50%. Additional clinical data including large series and controlled trials are required to precisely assess the role and timing of carotid endarterectomy in the setting of mobile carotid plaque.

CONFLICTS OF INTEREST

None.

FUNDING

None

ACKNOWLEDGEMENTS

The authors would like to thank the Department of Neurology of Henri Mondor University Hospital for their assistance in the management of this case.

REFERENCES

- 1 Bardon M, Hanson J, O'Brien B, Naeem A. Calcified cerebral emboli: incidence and implications. *J Med Imaging Radiat Oncol* 2018;**62**:499–503.
- 2 Walker BS, Shah LM, Osborn AG. Calcified cerebral emboli, a "do not miss" imaging diagnosis: 22 new cases and review of the literature. *AJNR Am J Neuroradiol* 2014;**35**:1515–9.
- 3 Grau AJ, Weimar C, Buggle F, Heinrich A, Goertler M, Neumaier S, et al. Risk factors, outcome, and treatment in subtypes of ischemic stroke: the German stroke data bank. *Stroke* 2001;**32**:2559–66.
- 4 Barnett HJ. Efficacy of carotid endarterectomy translates to being efficacious with appropriate surgical skill. *Arch Neurol* 2002;**59**:1866–8.
- 5 Bhatti AF, Leon Jr LR, Labropoulos N, Rubinas TL, Rodriguez H, Kalman PG, et al. Free-floating thrombus of the carotid artery: literature review and case reports. *J Vasc Surg* 2007;**45**:199–205.
- 6 Vellimana AK, Kadkhodayan Y, Rich KM, Cross 3rd DT, Moran CJ, Zazulia AR, et al. Symptomatic patients with intraluminal carotid artery thrombus: outcome with a strategy of initial anti-coagulation. *J Neurosurg* 2013;**118**:34–41.
- 7 Arning C, Herrmann HD. Floating thrombus in the internal carotid artery disclosed by B-mode ultrasonography. *J Neurol* 1988;**235**:425–7.
- 8 Marchione P, Vento C, Morreale M, Izzo C, Maugeri A, Manuppella F, et al. Atorvastatin treatment and carotid plaque morphology in first-ever atherosclerotic transient ischemic attack/stroke: a case-control study. *J Stroke Cerebrovasc Dis* 2015;**24**:138–43.
- 9 Khurana D, Saini M, Laldinpui J, Khandelwal N, Prabhakar S. Mobile plaque in the internal carotid artery: a case report and review. *Ann Indian Acad Neurol* 2009;**12**:185–7.
- 10 Chakhtoura EY, Goldstein JE, Hobson RW. Management of mobile floating carotid plaque using carotid artery stenting. *J Endovasc Ther* 2003;**10**:653–6.