


Contents lists available at [ScienceDirect](#)

Acta Orthopaedica et Traumatologica Turcica

journal homepage: <https://www.elsevier.com/locate/aott>

Kyphosis – A risk factor for positioning brachial plexopathy during spinal surgeries



Mirza Biscevic^{a,*}, Aida Sehic^b, Sejla Biscevic^c, Ismet Gavrankapetanovic^a, Barbara Smrke^d, Damir Vukomanovic^e, Ferid Krupic^f

^a Department of Orthopedics and Traumatology, General Hospital Sarajevo, Bosnia and Herzegovina

^b Department of Intraoperative Neurophysiological Monitoring, SMS, Louisville, KY, USA

^c Department of Nuclear Medicine, General Hospital Sarajevo, Bosnia and Herzegovina

^d Department of Neurosurgery, Clinical Center Ljubljana, Slovenia

^e George Washington University School of Medicine and Health Sciences, USA

^f Department of Orthopedics, Sahlgrenska Academy at University of Gothenburg, Sweden

ARTICLE INFO

Article history:

Received 12 January 2017

Received in revised form

22 December 2018

Accepted 5 February 2019

Available online 18 March 2019

Keywords:

Brachial plexopathy

Motor-evoked potentials

Spine deformity

Trunk

Kyphosis

Scoliosis

ABSTRACT

Objective: The aim of this study was to evaluate the differences in transcranial electric motor-evoked potentials – TceMEP on upper limbs and the incidences of postoperative brachial plexopathy between patients with kyphotic and scoliotic trunk shapes.

Methods: In the period of January 2011–January 2017, 61 consecutive patients (mean age: 18.4 years \pm 4.4 years (range: 10–32)) with pediatric spinal deformity underwent surgery in our Department. Eight of them had a kyphotic trunk deformity (Scheuermann kyphosis, neurofibromatosis, posterior thoracic hemivertebra), and the rest of the 53 patients had a scoliotic trunk deformity (mostly adolescent idiopathic scoliosis – AIS, lateral hemivertebra). The TceMEP recordings in all four limbs were analyzed every 30 min, or upon the surgeon's command. Upper limb TceMEP recordings were used as a control of systemic and anesthetic related changes, and as the indicator of positioning brachial plexopathy.

Results: Four out of 8 patients (50.0%) from the kyphotic group experienced noteworthy decreases in TceMEP amplitude ($\geq 65\%$) in one or both arms, and only 2 out of 53 patients (3.8%) from the scoliotic group, confirming significant statistical difference (Chi-square 16.75, $p < 0.05$). Two out of 8 patients with decreases in TceMEP amplitude suffered from transitory postoperative brachial plexopathy, and both of them were from the kyphotic group.

Conclusion: It seems that kyphotic trunks have a higher risk for positioning-related brachial plexopathy, probably due to distribution of trunk's weight onto only four points (two iliac bones and two shoulders), compared to the scoliotic trunks that have wider weight-bearing areas. We emphasize the importance of proper patient positioning and close intraoperative neuro-monitoring of all four limbs in more than one channel per limb.

Level of Evidence: Level IV Therapeutic Study.

© 2019 Turkish Association of Orthopaedics and Traumatology. Publishing services by Elsevier B.V. This is an open access article under the CC BY-NC-ND license (<http://creativecommons.org/licenses/by-nc-nd/4.0/>).

Introduction

Since the first scoliosis surgery in 1924, patient expectations of successful spine correction have grown. Today, surgeons often meet those expectations thanks to improved spinal implants, operative and perioperative care, and safer anesthesia. However, aggressive corrections place nerve structures at higher risk from extraordinary implant mechanical forces, bony impingements, and non-physiological positioning during long-lasting surgeries. Consequently, both patient and surgeon concerns have grown regarding

* Corresponding author. Department of Orthopedics and Traumatology, General Hospital Sarajevo, Kranjceviceva 12, 71000 Sarajevo, Bosnia and Herzegovina. Tel.: +0038733285100. Fax: +0038733285370.

E-mail address: mirzabiscevic@hotmail.com (M. Biscevic).

Peer review under responsibility of Turkish Association of Orthopaedics and Traumatology.

the risk of neurologic injury. Risks include not only lower limb paraplegia from deformity correction, but also upper limb brachial plexopathy arising from patient malpositioning.

The prone patient positioning for spinal surgery is associated with complex morbidities attributed to body habitus and its contact with complex operating room table frames. The most frequent upper body injuries are to the brachial plexus and cervical spine nerves, while the most serious injury is postoperative visual loss.¹ Positioning designed to achieve optimal exposure and operating conditions may be non-physiologic, creating perioperative peripheral nerve injury – PPNI from excessive mechanical pressure and torsion. The risk for PPNI is increased during spinal deformity surgery because of such a long duration. Understanding the etiology, mechanism, and pattern of injury with each type of nerve injury is important for the prevention of PPNI.^{2,3} Transcranial electric motor-evoked potential – TceMEP recordings can detect motor-function impairment before the PPNI (plexopathy) becomes irreversible, thus allowing for the possibility of prevention.

We have assumed that despite proper patient positioning, the shape of the trunk can be a risk factor for position-related brachial plexopathy. The purpose of this study is to evaluate differences in upper arm TceMEP recordings and the incidences of postoperative brachial plexopathy between the patients with kyphotic and scoliotic trunk shapes.

Materials and methods

The study involved 68 consecutive patients with pediatric spinal deformities who underwent surgery in period of Jan. 2011–Jan. 2017. Strict inclusion criteria were as follows: posterior corrective surgery of a pediatric spine deformity performed by a single surgeon, prone positioning lasting longer than 5 h, normal preoperative neurological status, adherence to standardized anesthesia protocol (total intravenous anesthesia – TIVA, consisting of propofol 3.0–4.5 µg/ml + sufentanil 1.5–2.5 ng/ml without relaxant), and interpretable TceMEP recordings. Five patients were excluded due to accompanying disease or conditions that were deemed to influence the final result (three patients with neuromuscular scoliosis, and two brachial plexus palsy), and two more patients were excluded due to uncompleted data. Although there are many subtypes of spinal deformities, we have divided our patients in two groups, kyphotic and scoliotic, to reach the goals of our study. Eight out of 61 eligible patients had a kyphotic type of deformity, such as Scheuermann kyphosis, neurofibromatosis, or posterior thoracic hemivertebra, and the rest of the 53 patients had a scoliotic type of deformity, mostly adolescent idiopathic scoliosis – AIS or lateral hemivertebra, [Table 1](#).

Preoperative protocol, patient positioning, surgical equipment and technique, system of drainage, wound closure, and post-operative care were identical for all our patients, with minor technical exceptions related to the specificity of each patient. Patients were in the prone position with their arms resting in “90-

90°” position (90° shoulder abduction, 90° elbow flexion, pronated arm) and their lower legs with free feet position supported by a pillow. Patient trunks were leaned onto four pillows (both anterior superior iliac spines, and both shoulders), leaving the abdomen and breasts freely hanging at maximum.

TceMEP was generated using electrical stimulating pulses applied through a needle or corkscrew electrodes inserted into the cranial scalp. These electrodes were typically placed over the motor cortex regions approximately 1 cm anterior to C1–C2. The stimulus intensity was 150–400 V with durations of 50 µsec in a train of 2–4 pulses with an inter-stimulus interval of 1–5 msec. These parameters were varied to elicit the highest quality baseline waveforms.

Distal recordings were acquired through needle electrodes inserted bilaterally into upper extremity muscles (i.e. abductor digiti minimi) and lower extremity muscles (i.e. vastus lateralis, anterior tibialis, gastrocnemius medialis). The greater number of channels on the lower extremities provided a more reliable picture in the case of developing change that does not necessarily affect all recording channels with same degree.⁴ Many times, channels from the vastus lateralis presented low responses due to their deep positioning.

Reliable baseline recordings were obtained prior to positioning, with slight adjustments in the recording parameters when needed for the post-positioning and pre-incision period. Post-incision recordings were obtained in relation to the specific surgical act (i.e. muscle dissection, screw insertion, distraction, osteotomy, correcting maneuver, wound closure) at least once every 30 min, or upon the surgeon's command. The device, NIM-eclipse[®], and its SD-MEP mod (Medtronic, Somafor Danek, USA) were used in this study. The MEP “alert” would involve a unilateral or bilateral 65–75% reproducible decrease in TceMEP amplitude from the post-induction pre-positioning baseline. After eliminating technical (i.e. electrodes, positioning, etc.) and anesthesia (i.e. inhalation agents, hypotension, hypoxia, hypothermia) related changes, there are two levels of warning to the surgeon. The first report is done at a 50% loss of response, marked as an “alert”, and the second report is done at 75–80%, marked as an “alarm.” Considering that MEP responses are elicited after a single stimulus, it is sufficient to have 2–3 repeats for intervention and then subsequently at every step of correction until a signal returns at the baseline.^{5–7}

Upper limb TceMEP recordings were used as a control of systemic and anesthetic related changes, and as the indicator of positioning brachial plexopathy. This prospective cohort study was done in accordance with all of the required ethical standards (institutional and national). Informed consent was obtained from all individual participants included in this study, and there were no acknowledgements, conflict of interests, or financial support for this research.

Results

Age, blood loss, number of fused vertebrae, and duration of prone positioning are noted in [Table 2](#). The duration of the prone

Table 1
Indications for surgery.

Diagnosis	Scoliotic/kyphotic type of deformity	Pts.	%
adolescent idiopathic scoliosis - AIS	S	43	70.5
Scheuermann kyphosis	K	6	9.8
posterior revision surgeries	S	4	6.6
lordoscoliosis patients (marfanoid pts.)	S	3	4.9
neurofibromatosis	K	1	1.6
posterior thoracic hemivertebra	K	1	1.6
lateral hemivertebra	S	1	1.6
other types of spine deformities	S	2	3.3

Table 2
Age, blood loss, number of fused vertebrae, and duration of prone positioning.

	average	SD	min.	max.
age (years)	18.7	4.4	10	32
blood loss (l)	1.3	0.5	0.4	2.3
number of fused vertebrae	11.9	1.9	10	18
duration of prone position (hours)	6.1	1.4	5.0	9.1

position for patients with a kyphotic deformity was, on average, shorter when compared to the subgroup of patients with a scoliotic type of deformity (5.6:6.2), but statistically insignificant (Mann–Whitney test, Z-Score - 0.49736, $p = 0.61708$).

Upper limb TceMEPs were stable during the vast majority of surgeries. However, six out of 61 patients (9.8%) experienced noteworthy decreases in TceMEP amplitudes ($\geq 65\%$) on one or both arms. In the kyphotic group, 4 out of 8 patients experienced TceMEP changes (50.0%) while only 2 out of 53 patients in the scoliotic group (3.8%), confirming significant statistical difference (Chi-square - 16.748, $p = 0.00004$).

Those TceMEP changes were gradual and oscillating. Simple arm repositioning led to TceMEP recovery, sometimes TceMEPs were decreased again. Postoperatively, all patients had a normal motor

function, except two of them, both from the kyphotic group, who suffered from transient postoperative brachial plexopathy. It has additionally supported our hypothesis that kyphotic trunks possess a higher risk for positioning-related brachial plexopathy.

The first patient was a 17-year-old female, 175 cm tall, with a mid-thoracic Scheuermann kyphosis of 75° . During the surgery, amplitude of TceMEP intermittently declined in the right arm. Those changes were judged to be unconvincing, Fig. 1.

Nevertheless, clinically the patient had complete axillary and radial nerve palsy with median and ulnar nerve paresis post-operatively (inability to abduct the arm, extend the wrist and fingers, and moderate weakness of finger flexion and grasp), without clinically notable sensory loss. The median and ulnar nerve paresis recovered within a week, the radial nerve palsy persisted for a month, and the axillar nerve palsy for almost four months. Physiotherapy and shoulder sling immobilization led to a full clinical and EMG recovery. The second patient was a 19-year-old male, 201 cm tall, with an angular thoracolumbar Scheuermann kyphosis that affects sagittal alignment and indicates surgery.⁸ This patient had an identical situation with the MEP decreasing and postoperative neurological status and recovery, but in a milder form.

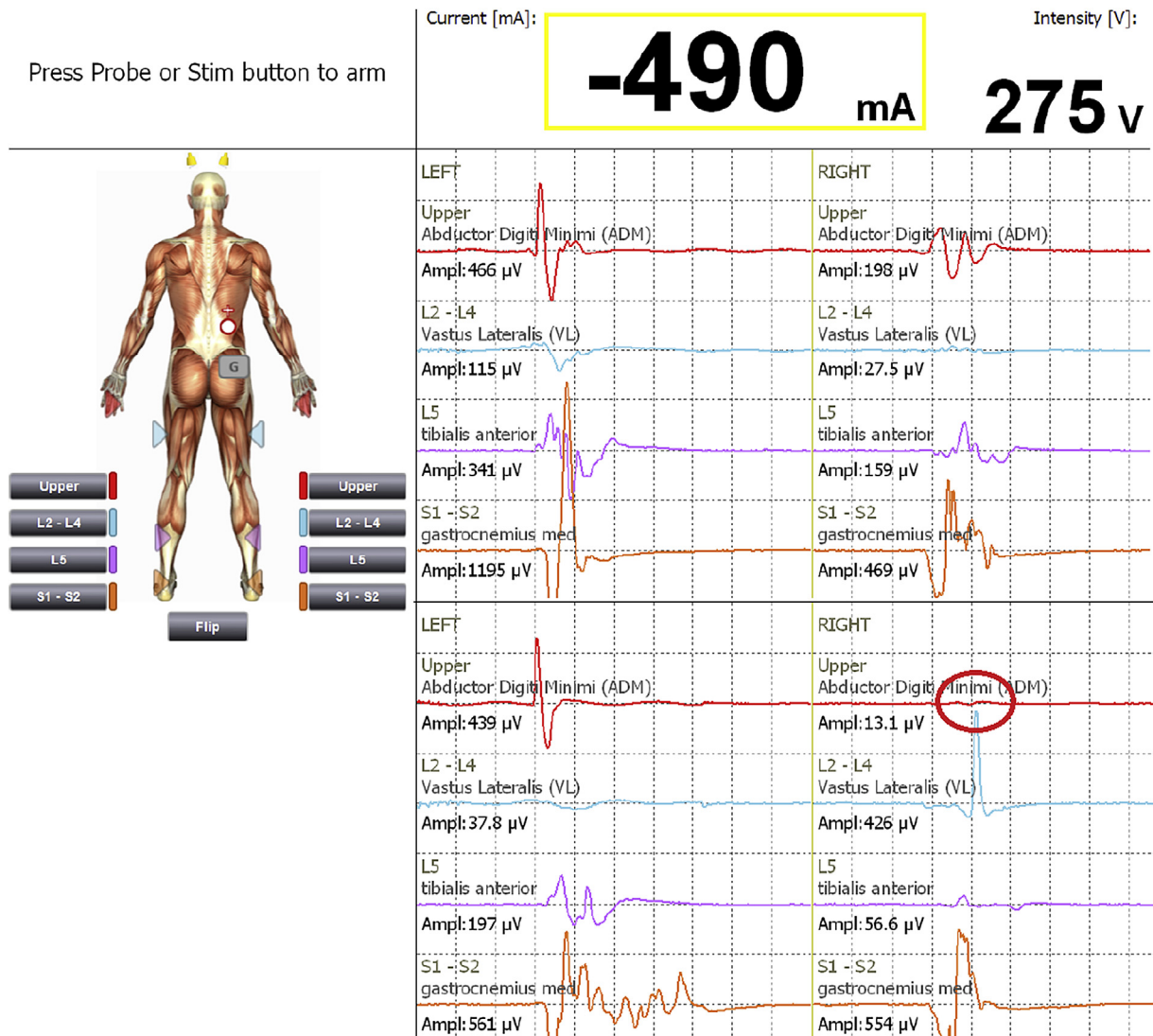


Fig. 1. TceMEPs recordings at the beginning of surgery (upper part of Fig. 1.); losing of right arm MEP later, intraoperatively (lower part of the Fig. 1).

Discussion

Extensive surgeries, such as corrections of pediatric spinal deformities, are risky procedures of which numerous complications might appear. The most fearsome complication is a motor deficit of the lower limbs with an incidence of 0.4–1.9%.^{9,10} Motor deficits of the upper limbs, such as brachial plexopathy, are fortunately transient in the vast majority of patients. These are related to the prone-positioning of a patient and not to the surgical maneuvers, unlike deficits of lower limbs, because the spinal deformity surgeries are performed below the level of T2.

After extensive database searching, we have not found a study with same design or criteria as our study. The most similar studies for comparison were Labrom's, Schwartz's and Chung's studies. In Labrom and colleagues' retrospective longitudinal study of 434 consecutive pediatric patients undergoing surgical correction of scoliosis with monitoring of somatosensory evoked potentials – SSEP – the risk of positioning brachial plexopathy was 6.2%.¹¹ In a similar study by Schwartz and colleagues, the risk for brachial plexopathy involving the ulnar nerve was 3.6%.¹² Ulnar neuropathy was noted by SSEP neuromonitoring at 5.2% in 230 patients who had a lumbosacral surgery in Chung and coworker's study.¹³ Repositioning the arm(s) or shoulders resulted in nearly an immediate improvement of SSEP amplitude, and all patients awoke without signs of brachial plexopathy.^{11–13} Additionally, there are some other studies describing the problem of positioning on brachial plexopathy during spinal surgeries, as well as the general importance of proper patient positioning.^{14–16}

In our study, the incidence of TceMEP reduction in the upper limbs due to arm malposition was 9.8%. Arm malposition-related change was very easily differentiated from surgical, systemic, and technical related issues by simultaneously recording all four limb TceMEPs. Technical and systemic related changes would affect both upper and lower limb TceMEPs. Since all the procedures we did were below the T2 level, the upper limb TceMEPs could be affected only by arm malpositioning. Simple repositioning of that limb would lead to a gradual return of the lost potential, thus preventing long term position-related plexopathy. In spite of the arm/shoulder repositioning, we noted postoperative brachial plexopathy in 3.3% of patients. This could be explained by the existence of only one monitoring channel on the arms, intermittent instead of continuous monitoring, and inadequate arm repositioning. Although TceMEP changes on the arms were often false positive, there were no false negative results. In other words, each postoperative brachial plexopathy has been announced by significant intraoperative MEP changes. In comparison to the mentioned studies, our study had a higher incidence of positive neuro-monitoring events, probably due to a higher TceMEP sensitivity to hypotension, hypothermia, and general anesthesia, especially inhaled anesthetics then SSEP monitoring.¹⁷

The duration of surgery was not identified as a reason for the malpositioning brachial plexopathy in this study; rather, it was the kyphotic posture with a thirteen times greater incidence of TceMEP changes in the kyphotic group compared to the scoliotic group. Both of the postoperative brachial plexopathies were noted in the kyphotic group, thus supporting our hypothesis that kyphotic patients are prone to position-related brachial plexopathy. The four-point weight-bearing spots of the kyphotic trunk (two iliac bones and two shoulders) is a less favorable situation for patient positioning compared to the wider weight-bearing areas that characterize scoliotic trunks. To avoid this complication, we once again emphasize the importance of proper patient positioning and close intraoperative monitoring of all four limb TceMEPs in more than one channel per limb.

Limitations of this study might include qualitative outcome measures, like significant/insignificant reduction of amplitude and presence/absence of different types of neurological deficits, relatively small sample size, lack of elaborating TceMEP recordings in relation to specific arm manipulation, employment of the only one MEP channel, and absence of simultaneous SSEP recordings. Still, the PubMed database contains only studies about positioning brachial plexopathies that are based on SSEP intraoperative neuromonitorisation. There is no study that analyze incidence of postoperative brachial plexopathy in relation to MEP changes or trunk shape.

Conclusion

Prone patient positioning with excessive pressure/torsion on the upper limbs and neck might cause postoperative brachial plexopathy. It seems that kyphotic trunks have a higher risk, probably due to narrower weight-bearing areas compared to the scoliotic trunks.

This complication is preventable if intraoperative MEP changes are identified on time and followed by prompt shoulder/arm reposition.

A higher number of channels on the upper extremities and combined MEP/SSEP monitoring provide a superior tool in detection of brachial plexopathy.

References

- Salkind EM. A novel approach to improving the safety of patients undergoing lumbar laminectomy. *AANA J.* 2013;81(5):389–393.
- Hazarika A, Rath GP. Modified prone positioning for dorsal spine surgery in a patient with postural deformity due to spasticity of lower limbs. *J Clin Anesth.* 2014;26(7):582–584.
- Kamel I, Barnette R. Positioning patients for spine surgery: avoiding uncommon position-related complications. *World J Orthop.* 2014;5(4):425–443.
- Biscevic M, Biscevic S, Ljuca F, et al. Motor evoked potentials in 43 high risk spine deformities. *Med Arh.* 2014;68(5):345–349.
- Calancie B. Intraoperative neuromonitoring and alarm criteria for judging MEP responses to transcranial electric stimulation: the threshold-level method. *J Clin Neurophysiol.* 2017;34(1):12–21.
- Langeloo DD, Lelivelt A, Louis Journée H, et al. Transcranial electrical motor-evoked potential monitoring during surgery for spinal deformity: a study of 145 patients. *Spine.* 2003;28(10):1043–1050.
- Berends HI, Journée HL. Influence of the montage of stimulation electrodes for intraoperative neuromonitoring during orthopedic spine surgery. *J Clin Neurophysiol.* 2018;35(5):419–425.
- Vialle LR. The incidence and management of acute neurologic complications following complex adult spinal deformity surgery. In: *AO Spine Masters Series – Adult Spinal Deformities.* vol. 4. New York: Thieme Medical Publishers; 2015: 68–77.
- Qiu Y, Wang S, Wang B, et al. Incidence and risk factors of neurological deficits of surgical correction for scoliosis: analysis of 1373 cases at one Chinese institution. *Spine.* 2008;33(5):519–526.
- MacEwen GD, Bunnell WP, Sriram K. Acute neurological complications in the treatment of scoliosis. A report of the Scoliosis Research Society. *J Bone Joint Surg Am.* 1975;57(3):404–408.
- Labrom RD, Hoskins M, Reilly CW, et al. Clinical usefulness of somatosensory evoked potentials for detection of brachial plexopathy secondary to malpositioning in scoliosis surgery. *Spine.* 2005;30(18):2089–2093.
- Schwartz DM, Drummond DS, Hahn M, et al. Prevention of positional brachial plexopathy during surgical correction of scoliosis. *J Spinal Disord.* 2000;13(2): 178–182.
- Chung I, Glow JA, Dimopoulos V, et al. Upper-limb somatosensory evoked potential monitoring in lumbosacral spine surgery: a prognostic marker for position-related ulnar nerve injury. *Spine J.* 2009;9(4):287–295.
- Uribe JS, Kolla J, Omar H, et al. Brachial plexus injury following spinal surgery. *J Neurosurg Spine.* 2010;13(4):552–558.
- Duffy BJ, Tubog TD. The prevention and recognition of ulnar nerve and brachial plexus injuries. *J Perianesth Nurs.* 2017;32(6):636–649.
- Ying T, Wang X, Sun H, et al. Clinical usefulness of somatosensory evoked potentials for detection of peripheral nerve and brachial plexus injury secondary to malpositioning in microvascular decompression. *J Clin Neurophysiol.* 2015;32(6):512–517.
- Bjerke BT, Zuchelli DM, Nemani MV, et al. Prognosis of significant intraoperative neurophysiologic monitoring events in severe spinal deformity surgery. *Spine Deform.* 2017;5(2):117–123.