

## Full Length Article

## Autoimmune psychosis in Taiwan: A case report and review of literature

Ta-Wei Guu<sup>a,b,\*</sup>, Sheng-Ta Tsai<sup>c</sup>, Kuan-Pin Su<sup>a,d,e</sup><sup>a</sup> Department of Psychiatry and Mind-Body Interface Laboratory (MBI-Lab), China Medical University Hospital, Taichung, Taiwan<sup>b</sup> Division of Psychiatry, Department of Internal Medicine, China Medical University Beigang Hospital, Yunlin, Taiwan<sup>c</sup> Department of Neurology, China Medical University Hospital, Taichung, Taiwan<sup>d</sup> Tainan Municipal An-Nan Hospital, China Medical University, Tainan, Taiwan<sup>e</sup> College of Medicine, China Medical University, Taichung, Taiwan

## ARTICLE INFO

## Keywords:

Autoimmune psychosis

N-Methyl D-Aspartate (NMDA)

Immune therapy

Garcinia cambogia

## 1. Background

Autoimmune psychosis, especially those involving anti-N-methyl-D-aspartate receptor (anti-NMDAR) antibodies, has been drawing clinical attentions. In 2020, a group of experts has published a consensus paper regarding the diagnosis and management of autoimmune psychosis (Pollak et al., 2020) according to clinical experience from Western countries. In Asia, more evidence from case studies are needed. Here we presented a case of definite autoimmune psychosis and compared the clinical differences of such patients based on current literature.

## 2. Case report

Miss W was 20 years old when she presented psychosis for the first time. She was over-weighted (68 Kilogram/1.63 Meter, body mass index: 25.6) and had early onset type 2 diabetes treated with metformin for 6 years. She suffered from acute conscious disturbance 10 days before visiting emergency department (ED) of the hospital in November 2012, and was requested to take medical leaves by the convenience store she worked. However, she further presented with drowsiness, poor attention, slow responses, fluctuating agitation, visual and auditory hallucination, accompanied by intermittent dystonic tremor at left arm. She had upper respiratory tract infection symptoms with prolonged course of fever noted three weeks ago, but no specific travel history nor family history of mental illness.

At ED, comprehensive substance screen, brain contrast MRI, biochemistry profile and hemogram were arranged. Except for mild

leucocytosis, hyperglycaemia, and mildly elevated aspartate amino-transferase and alanine amino-transferase, no other abnormality was disclosed. Of note, she used Garcinia Cambogia extract for weight reduction one week before the medical leaves, and her family and colleagues reported her poor attention and slow responses had transient improvement for two days before further deteriorating.

She was first admitted to psychiatric ward under the impression of psychotic disorder due to other medical conditions. Due to prominent adverse effects such as worsening of tremor and rigidity under antipsychotics, and persistent disorientation, measures of peripheral inflammation, including blood high sensitivity CRP, E.S.R., procalcitonin and white cell counts, as well as brain MRI were repeated, which all showed negative findings, but cerebrospinal fluid (CSF) study showed markedly elevated IgG index (1.03). Her conditions kept progressing that agitation, dysautonomia, and fluctuation of consciousness level were noted alternatively, so she was transferred to the neurology ward in one week. Antiviral agent with dexamethasone were empirically prescribed under the impression of immune mediated encephalopathy, and autoimmune profile was surveyed, where weak positive result of anti-NMDAR antibody, but not other auto antibodies, was found in both serum and CSF under immunofluorescence microscopy, and intra-abdominal tumor was not identified in CT scan (shown in Fig. 1-3). Five sessions of plasmapheresis were immediately arranged, and her consciousness and psychosis significantly improved (shown in Table 1). She was discharged one week after the last plasmapheresis. She regularly followed up afterwards in the outpatient department or with phone calls, and there has been no recurrent episode so far. She was married, and successfully delivered a

\* Corresponding author. Division of Psychiatry, Department of Internal Medicine, China Medical University Beigang Hospital, Yunlin, Taiwan.

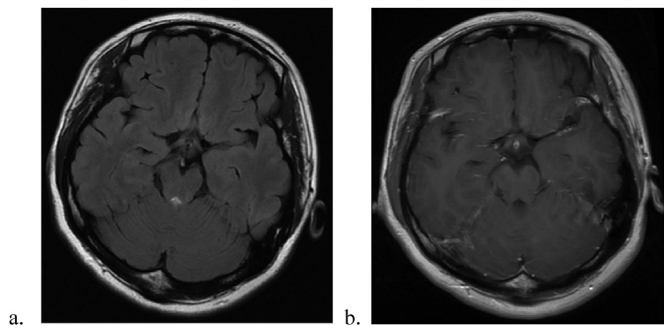
E-mail address: [da20vid@gmail.com](mailto:da20vid@gmail.com) (T.-W. Guu).

<https://doi.org/10.1016/j.bbih.2020.100055>

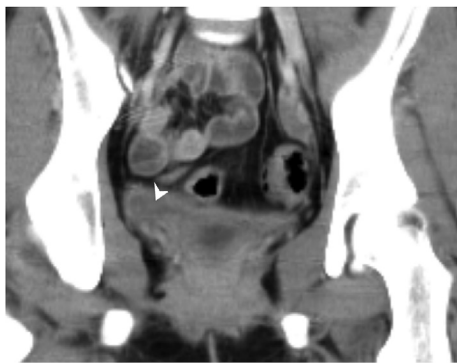
Received 13 February 2020; Received in revised form 21 February 2020; Accepted 21 February 2020

Available online 25 February 2020

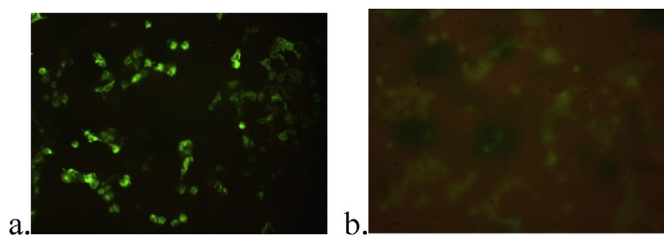
2666-3546/© 2020 Published by Elsevier Inc. This is an open access article under the CC BY-NC-ND license (<http://creativecommons.org/licenses/by-nc-nd/4.0/>).



**Fig. 1.** We did the brain MRI with contrast twice for this patient during admission (with 7 days interval). The two times of brain MRI didn't find organic lesions. Specifically for her acute psychosis, we emphasized on the bilateral anterior temporal lobes. Both the T2 FLAIR (a) series and T1 FLAIR (b) with contrast didn't find inflammatory or space-occupying lesions.



**Fig. 2.** For this anti-NMDAR encephalitis patient, we checked her abdominal CT to find ovarian teratoma. But the image didn't find visible ovarian teratoma. In the coronal section of abdominal CT with contrast, the arrowhead showed the normal right ovary.



**Fig. 3.** Positive findings of anti-NMDAR antibodies under immunofluorescence microscopy in both CSF (a) and serum (b) samples of the patient.

baby without complication six years after the disturbing psychotic experience.

### 3. Discussion

Psychoses associated with positive neuronal surface autoantibodies has becoming a unique disease entity for more than a decade. With the integration of evidence, a criteria system to diagnose possible, probable, and definite autoimmune psychoses, and recommendations for treatment strategies had been proposed in a consensus paper published in 2020 (Pollak et al., 2020). A recent review article characterizing the clinical features, mechanism, treatment and outcomes of different antibody-mediated encephalitis reported annual incidence of all types of encephalitis with neuronal autoantibodies is at least 5 per 100,000 persons, and more than 1500 patients with positive anti-NMDAR antibodies

**Table 1**

The clinical and laboratory presentation before and after the treatments. The patient's improvement in consciousness and positive psychotic symptoms after steroid pulse therapy and plasma exchange, which were not directly reflected by blood tests and CSF data, suggestive of the need of direct measurement of specific antibodies and prompt immune therapy. n/a: not applied.

	Pre-treatment	After dexamethasone pulse therapy (8 days later)	After plasma exchange (14 more days later)
<b>Clinical assessments</b>			
Glasgow coma scale	E1V1M4	E2V4M5	E4V5M6
PANSS-positive score	41	28	9
<b>Blood tests</b>			
High sensitivity CRP (c-reactive protein) (mg/L)	0.9	3.9	n/a
WBC (white blood cell) (cells/ul)	11060	12480	n/a
Neutrophilic Segment	82.9%	88.2%	n/a
Procalcitonin (PCT) (ng/mL)	0.05	0.10	n/a
E.S.R. (erythrocyte sedimentation rate) (mm/1hr)	12	13	n/a
<b>CSF data</b>			
CSF WBC (cells/ul)	7	6	n/a
CSF micro-protein (mg/dL)	23	16	n/a
CSF IgG index	1.03	n/a	n/a

had been reported worldwide (Dalmau and Graus, 2018). However, even taking together the larger, recently published case series and follow up studies (Kong et al., 2019; Saraya et al., 2013; Xu et al., 2020; Yaguchi et al., 2019), this disease entity still seems underestimated and under-reported in Asia.

In Taiwan, an article reviewing 13 female anti-NMDAR encephalitis patients from 2011 to 2018 disclosed the time to correct diagnosis ranged from 7 to 150 days, and time to hospitalization ranged from 37 to 210 days (Chiu et al., 2019). In our case, the time to diagnosis of anti-NMDAR encephalitis was around 21 days. Applying the "red flags," such as rapid progression, adverse response to antipsychotics, autonomic dysfunction and decreased consciousness that our patient had presented, was recommended to facilitate timely management, and would reduce up to 75% of time (from 40 to 10 days) from symptoms onset to diagnosis (Pollak et al., 2020).

Our patient has been followed up for around seven years without recurrence, and improved significantly without second line immune therapy. Reasons explaining the good prognosis may include the rather early diagnosis and treatment compared with the reported cases in Asia. However, exposure to *Garcinia Cambogia* extract was an intriguing factor as it seems transiently attenuating the illness. Although the clinical relevance is not clear, literature had shown anti-inflammatory property of *Garcinia Cambogia* extract in preclinical studies (dos Reis et al., 2009), in addition to anti-obesity effects (Payab et al., 2019).

In summary, although more evidence is needed in Taiwan and other Asian countries to facilitate clinical practice in the field of autoimmune psychosis, experiences from Western world could be valuable tools for psychiatrists and neurologists facing potential patients with anti-NMDAR encephalitis.

### Author contributions

TWG took care of the patient and consulted with STT and followed up the patient. TWG then drafted the manuscript, and STT reviewed all the figures and image findings. All the authors reviewed and revised the manuscripts equally.

## Role of the funding sources

All the aforementioned funding bodies had no role in the design and conduct of the study; collection, management, analysis, and interpretation of the data; preparation, writing, review, or approval of the manuscript; and decision to submit the manuscript for publication.

## Declaration of competing interest

The authors disclose no conflict of interests.

## Acknowledgements

The authors of this work were supported by the following grants: MOST 106-2314-B-039-027-MY3, 108-2320-B-039-048, 108-2813-C-039-133-B and 108-2314-B-039-016 from the Ministry of Science and Technology, Taiwan; NHRI-EX108-10528NI from the National Health Research Institutes, Taiwan; MYRG2018-00242-ICMS from University of Macau, China; CMRC-CMA-3 from Higher Education Sprout Project by the Ministry of Education (MOE), Taiwan; CMU108-SR-106 from the China Medical University, Taichung, Taiwan; and CRS-108-048, DMR-108-216 and DMR-109-102 from the China Medical University Hospital, Taichung, Taiwan.

## References

Chiu, H.C., Su, Y.C., Huang, S.C., Chiang, H.L., Huang, P.S., 2019. Anti-NMDAR encephalitis with ovarian teratomas: review of the literature and two case reports.

- Taiwan. *J. Obstet. Gynecol.* 58 (3), 313–317. <https://doi.org/10.1016/j.tjog.2019.03.004>.
- Dalmau, J., Graus, F., 2018. Antibody-mediated encephalitis. *N. Engl. J. Med.* 378 (9), 840–851. <https://doi.org/10.1056/NEJMra1708712>.
- dos Reis, S.B., de Oliveira, C.C., Acedo, S.C., Miranda, D.D., Ribeiro, M.L., Pedrazzoli Jr., J., Gambero, A., 2009. Attenuation of colitis injury in rats using *Garcinia cambogia* extract. *Phytother. Res.* 23 (3), 324–329. <https://doi.org/10.1002/ptr.2626>.
- Kong, S.S., Chen, Y.J., Su, I.C., Lin, J.J., Chou, I.J., Chou, M.L., et al., 2019. Immunotherapy for anti-NMDA receptor encephalitis: experience from a single center in Taiwan. *Pediatr. Neonatol.* 60 (4), 417–422. <https://doi.org/10.1016/j.pedneo.2018.10.006>.
- Payab, M., Hasani-Ranjbar, S., Shahbal, N., Qorbani, M., Aletaha, A., Haghi-Aminjan, H., et al., 2019. Effect of the herbal medicines in obesity and metabolic syndrome: a systematic review and meta-analysis of clinical trials. *Phytother. Res.* <https://doi.org/10.1002/ptr.6547>.
- Pollak, T.A., Lennox, B.R., Muller, S., Benros, M.E., Pruss, H., Tebartz van Elst, L., et al., 2020. Autoimmune psychosis: an international consensus on an approach to the diagnosis and management of psychosis of suspected autoimmune origin. *Lancet Psychiatr.* 7 (1), 93–108. [https://doi.org/10.1016/s2215-0366\(19\)30290-1](https://doi.org/10.1016/s2215-0366(19)30290-1).
- Saraya, A., Mahavithanont, A., Shuangshoti, S., Sittidetboripat, N., Deesudchit, T., Callahan, M., et al., 2013. Autoimmune causes of encephalitis syndrome in Thailand: prospective study of 103 patients. *BMC Neurol.* 13, 150. <https://doi.org/10.1186/1471-2377-13-150>.
- Xu, X., Lu, Q., Huang, Y., Fan, S., Zhou, L., Yuan, J., et al., 2020. Anti-NMDAR encephalitis: a single-center, longitudinal study in China. *Neurol. Neuroimmunol. Neuroinflamm.* 7 (1) <https://doi.org/10.1212/nni.0000000000000633>.
- Yaguchi, H., Tsuji, T., Yabe, I., Hirayama, E., Nomura, T., Ohashi, I., et al., 2019. Incidence of anti-NMDAR encephalitis in patients undergoing resection of ovarian teratoma in a single institution. *J. Neurol. Sci.* 409, 116608. <https://doi.org/10.1016/j.jns.2019.116608>.