

Mediastinal Single Nodal Relapse of a Nasal Nk/T cell Lymphoma

Kyoung Hoon Rhee, M.D., Seok Chan Hong, M.D., Jeong Min An, M.D.,
Jooryung Huh, M.D.², Ryu Jin Sook, M.D.³,
Jin Seong Lee, M.D.⁴ and Cheolwon Suh, M.D.

*Departments of Internal Medicine, Pathology², Nuclear Medicine³ and Radiology⁴,
Asan Medical Center, University of Ulsan College of Medicine, Seoul, Republic of Korea*

A nasal NK/T cell lymphoma is a very aggressive form of lymphoma. Patterns of relapse after treatment have not been systematically evaluated, and mediastinal nodal relapse at a primary site has never been documented. We describe here a 40-year old man who presented with a nasal obstruction caused by a protruding mass that was identified as a nasal NK/T cell lymphoma. The initial work-up, including chest and abdominopelvic computed tomography (CT) and positron emission tomography (PET), showed no regional or distant metastasis. A CT scan performed following three cycles of chemotherapy with cyclophosphamide, doxorubicin, vincristine, and prednisolone (CHOP) showed that the mass had nearly disappeared. Radiation therapy undertaken following chemotherapy was given to the primary site. However, PET performed following radiotherapy revealed a single mediastinal lymphadenopathy, with no evidence of residual tumor in the nasal cavity. A biopsy using video-assisted thoracoscopy (VATS) showed the presence of a recurrent NK/T cell lymphoma with an immunophenotype identical to that of the primary nasal lymphoma. An additional three cycles of CHOP chemotherapy were administered, and the patient remains alive, with no evidence of disease 30 months after the initial relapse. These findings indicate that early detection with PET and prompt surgical excision with the use of VATS can lead to successful treatment of a relapsed nasal NK/T cell lymphoma.

Key Words : Nasal NK/T-cell lymphoma, Relapse, Mediastinal node, Positron Emission Tomography, Video-Assisted Thoracic Surgery

INTRODUCTION

Natural killer (NK)/T-cell lymphoma is the most common subtype of primary nasal lymphoma¹. Nasal NK/T cell lymphoma is a very aggressive form of lymphoma, with over 50% of the tumors showing involvement of the adjacent alveolar bones, hard palate, orbits, nasopharynx and an association with an extensive soft-tissue mass². Relapse patterns of nasal NK/T cell lymphoma after treatment have not been systematically evaluated, and mediastinal nodal relapse at a controlled primary

site has not been previously reported. Here we report a case of mediastinal single nodal relapse of a NK/T cell lymphoma, detected by positron emission tomography (PET) and confirmed pathologically, which was removed completely with surgery using video-assisted thoracoscopy (VATS).

CASE REPORT

A previously healthy 40-year-old Korean male was admitted

• Received : August 25, 2006
• Accepted : December 19, 2006

• Correspondence to : Cheolwon Suh, M.D., Division of Oncology, Department of Internal Medicine, Asan Medical Center, University of Ulsan College of Medicine, 388-1, Pungnap-2 dong, Songpa-gu, Seoul 138-736, Korea Tel : 82-2-3010-3209, Fax : 82-2-3010-6961, E-mail : csuh@amc.seoul.kr

to Asan Medical Center, Seoul, Korea, in December 2003 with symptoms of nasal obstruction and fever. A radiological examination of the paranasal sinus disclosed a soft tissue mass in the left middle meatus and associated obstructive sinusitis in the left maxillary sinus (Figure 1). A rhinoscopic examination revealed an irregular, and partly ulcerated protruding mass occupying the nasal cavity. A punch biopsy showed the presence of extensively necrotic tissue with a few viable foci of sheets of atypical medium- to large-sized lymphocytes with irregularly shaped nuclei. Individual necrosis and apoptosis were frequent. The tumor cells were positive by immunostaining for CD3, CD 56, cytotoxic granule marker TIA-1, and UCHL-1 (CD45RO), but negative for CD20, CD79a, CD4, and CD8. *In situ* hybridization showed the presence of Epstein-Barr virus in the majority of the tumor cell nuclei. The patient was diagnosed with an extranodal CD 56+ nasal NK/T cell lymphoma.

To evaluate the disease status, computed tomography (CT), bone marrow aspiration and biopsy, and PET were performed. CT showed no abnormal findings in other areas. Fluorine-18 fluorodeoxyglucose (FDG) PET showed a focal hypermetabolic lesion with a 4.8 maximal standardized uptake value (SUV) in the left nasal cavity, but no abnormally hypermetabolic lesions in the chest or abdomen (Figure 2, Figure 3A). All of these findings were consistent with a stage IEB nasal NK/T cell lymphoma.

Hematological levels were hemoglobin 12.8 g/dL, hematocrit 36.9%, platelet count $172 \times 10^3/\text{mm}^3$, and white blood cell count $4,200/\text{mm}^3$ (66% neutrophils, 29% lymphocytes, 5% monocytes, and 0.5% eosinophils). A bone marrow biopsy showed no malignant cell infiltration. All blood chemistry findings were normal, except for a slightly elevated lactate dehydrogenase level of 379 IU/l (normal range 120–250 IU/l). A cytological examination of the cerebrospinal fluid showed no abnormalities.

The patient was treated with three cycles of chemotherapy, consisting of cyclophosphamide, doxorubicin, vincristine, and prednisolone (CHOP), followed by 28 fractions of local radiation therapy to the primary site, with a total dose of 5,040 cGy.

In April 2004, about one month after completion of the radiation therapy, FDG PET-CT revealed a newly developed focal hypermetabolic lesion with a maximal SUV of 3.6 in the aorto-pulmonic nodal station. There were no abnormal findings at other sites, except for post-radiation sinusitis and thyroiditis (Figure 3B). A biopsy using VATS was performed, and the lymph node was removed completely. Microscopically, the node showed numerous histiocytes and epithelioid granulomas and scattered medium-sized CD56-positive lymphocytes in the paracortex; the nuclei of these cells were positive for Epstein-Barr virus. The tissue specimen of the mediastinal lymph node showed histology similar to that of the nasal mass (Figure 4A–D).

The patient was treated with an additional three cycles of

CHOP chemotherapy. A follow-up chest CT and PET showed no evidence of residual tumor. Thirty-five months after the initial diagnosis and thirty months after the initial relapse, the patient is still alive, without any evidence of further relapse.

DISCUSSION

An extranodal NK/T cell lymphoma is characterized by extensive mucosal ulceration and angiocentric or angiodestructive lymphomatous infiltration. These tumors have an immunophenotype of NK/T cell neoplasms, including expression of cytoplasmic CD 3 epsilon and CD56, and many are positive for EBV^{3,4}. These NK cell lymphomas show a geographic predilection, in that they are more common in Asian regions such as Hong Kong, Japan, and Korea, and in Latin American countries including Mexico, Peru, and Guatemala⁵⁻⁷.

“Nasal” NK/T cell lymphomas are classified as lesions confined within the nasal cavity and nasopharynx, whereas “nasal-type” NK/T cell lymphomas are lesions involving sites outside the nasal cavity/nasopharynx, such as the oral cavity, palate, larynx, tonsil, skin, soft tissues, and the visceral organs^{4,8,9}. The prognosis for patients with primary non-Hodgkin’s lymphoma of the nasal cavity is poor, and the rates of distant metastasis and local relapse are high. The 5-year overall survival and disease-free survival rates for 102 patients with stage IE nasal NK/T cell lymphoma have been recently reported to be 71.7% and 60.9%, respectively¹⁰. Outcomes of 262 extranodal NK/T cell lymphomas were recently used to develop a prognostic model of these tumors, with new prognostic factors including B symptoms, stage, lactate dehydrogenase (LDH) level, and regional lymph node status¹¹. According to this model, our patient, who had B symptoms and an elevated LDH level, is in group 3 (two risk factors).

Because of the low incidence and geographic occurrence of these tumors, a systematic evaluation of the treatment for nasal NK/T cell lymphomas has not been fully performed. Therefore, the optimal therapy for nasal NK/T-cell lymphoma has not yet been established. Although a prospective randomized trial about optimal treatment has not been performed, several retrospective studies have shown radiotherapy to be superior to chemotherapy alone for stage I/II disease^{12,13}. Some studies report that the addition of chemotherapy to radiotherapy does not appear to confer any survival benefit in early stage patients^{13,14}. Consequently radiotherapy, either as the initial treatment or as part of the chemotherapy regimen, is presently the mainstay of a treatment program for early stage NK/T cell lymphoma. The patient in this case was treated with three cycles of chemotherapy, followed by in field radiation therapy as and initial treatment program.

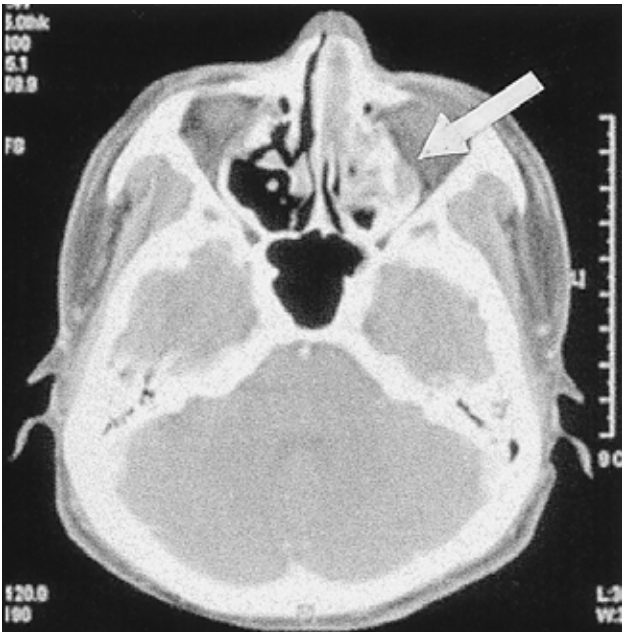


Figure 1. Computed tomography of the paranasal sinus showing a soft tissue density mass in the left middle meatus and associated obstructive sinusitis in the left maxillary sinus.

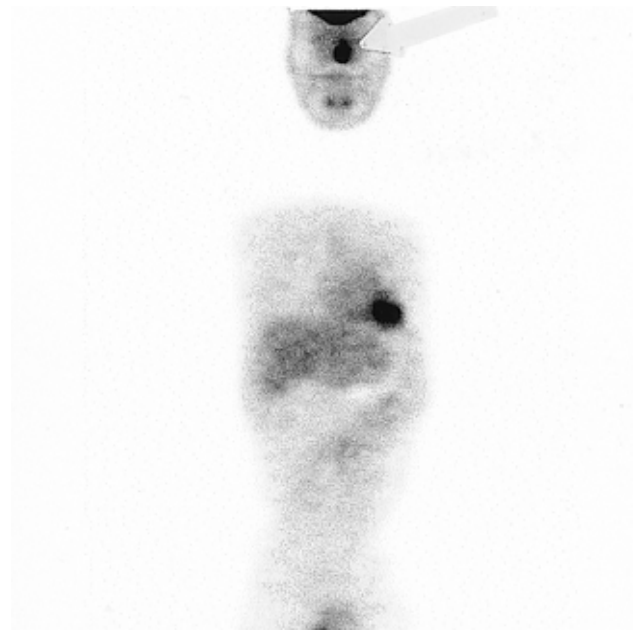

Figure 2. FDG PET of the nasal cavity at the initial diagnosis. There was a focal hypermetabolic lesion in the left nasal cavity at the initial diagnosis.

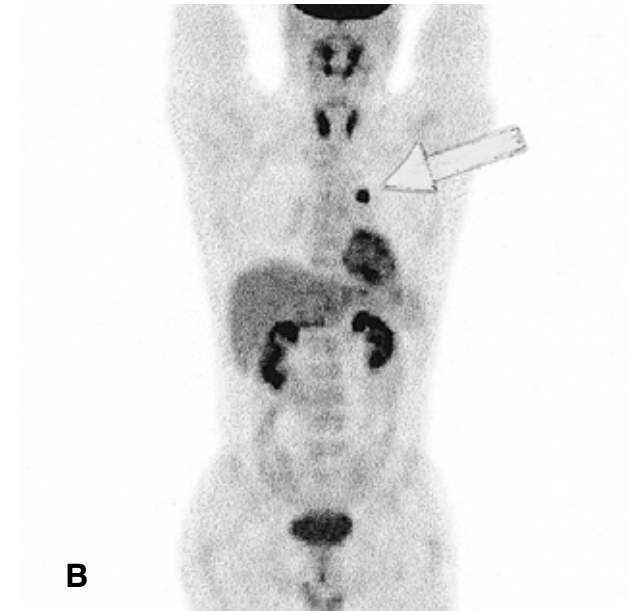
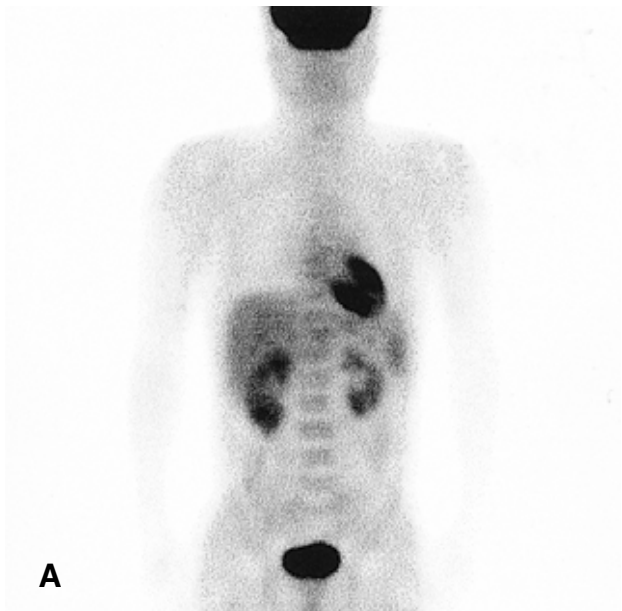


Figure 3. FDG PET of the mediastium at the initial diagnosis (A) and at relapse (B). (A) There was no abnormal hypermetabolic lesion in the chest and abdomen at the initial diagnosis. (B) There was increased metabolic activity at the mediastinal lymph node of the AP window (maximal SUV=3.6). Diffuse increased uptake was observed in both thyroid glands, indicative of thyroiditis.

Secondary lymph node involvement is rarely encountered until late in the course of disease¹⁵. In the patient described here, we diagnosed mediastinal relapse promptly using PET, a highly sensitive diagnostic tool for various cancers that can detect increased glycolytic activity of neoplasms¹⁶. PET is

usually performed to diagnose and stage tumors and to monitor response to therapy¹⁷. Although CT is frequently performed for patients with lymphoma, it is less sensitive for small tumor foci. Following treatment of a lymphoma, CT can reveal residual masses or enlarged lymph nodes, which may or may not

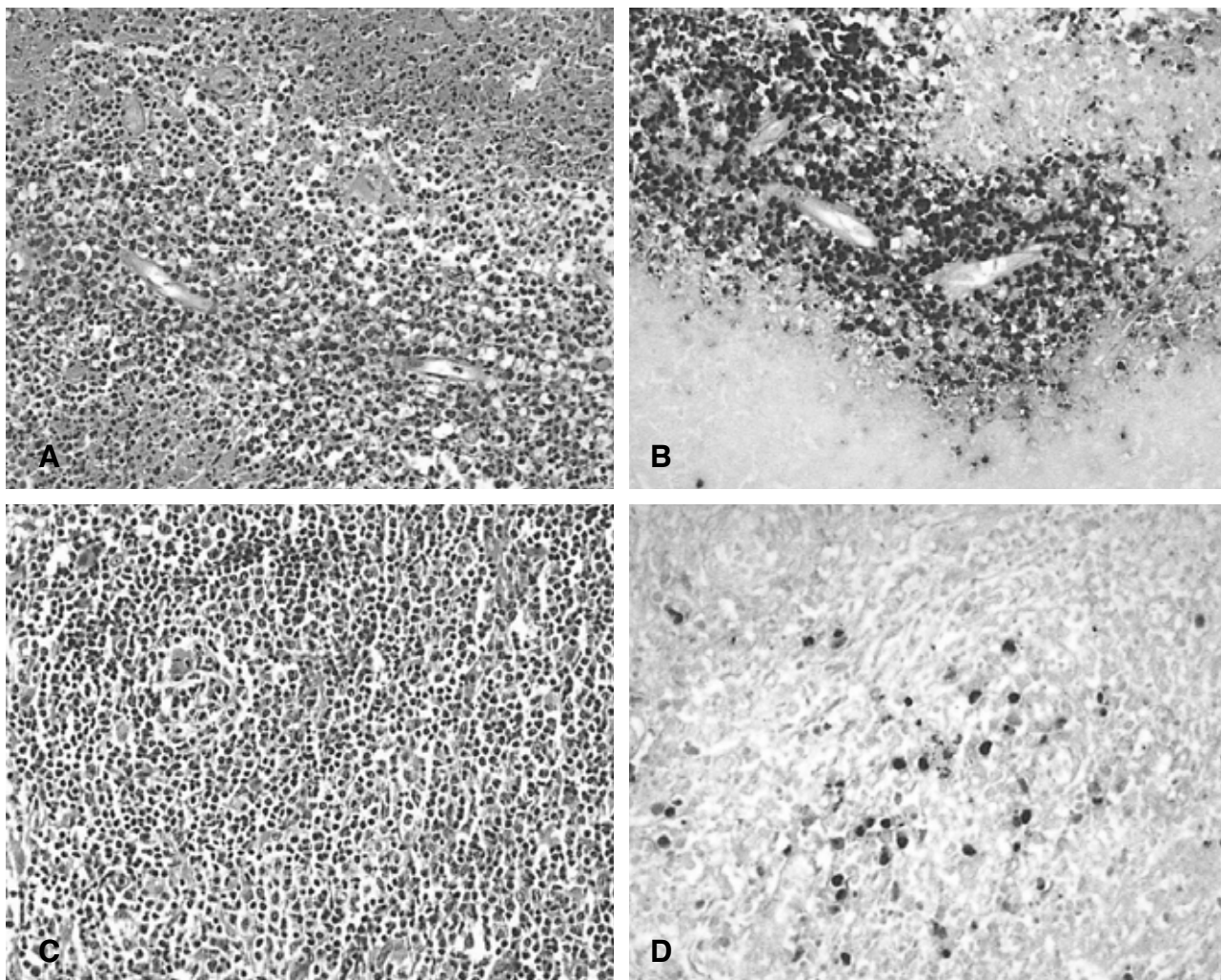


Figure 4. Initial biopsy of the nasal mass showing an extranodal NK/T-cell lymphoma (A, B) and biopsy of the mediastinal lymph node showing tumor recurrence (C, D). (A) Viable tumor cells show perivascular distribution in an extensively necrotic background containing an abundance of apoptotic bodies. Note the irregular, hyperchromatic nuclei and variable amount of clear to eosinophilic cytoplasm of the tumor cells ($\times 4000$, H and E staining). (B) In situ hybridization for Epstein-Barr virus showing signals in the tumor cell nuclei. (C) A few scattered atypical medium to large lymphocytes were admixed with small, mature, reactive lymphocytes and numerous histiocytes in the paracortex of the effaced node with hyperplastic high endothelial venules ($\times 400$, H and E staining). (D) In situ hybridization for Epstein-Barr virus showing positive signals in the tumor cell nuclei. The pathological and immunohistochemical features of the mediastinal lymph node were identical with those of the nasal mass.

contain a viable tumor^{18, 19}. Lymphoma evaluation using CT is primarily dependent on the size and morphologic criteria used to differentiate a malignant from a reactive lymph node. However, even a single small lymph node could be a lymphoma site. The patient described here had a single mediastinal lymph node of 1 cm in size. Evaluation by CT alone, without PET, would have made the diagnosis difficult and would have affected the decision in deciding whether the patient should have been further evaluated by the use of VATS.

Various techniques can be used to perform diagnostic mediastinal biopsies, the most widely used being the use of

percutaneous fine-needle aspiration, cervical mediastinoscopy, parasternal mediastinotomy, open biopsy through a thoracotomy, and more recently VATS²⁰. VATS is currently indicated not only for diagnostic procedures, but also for its versatility, permitting other surgical treatments at the same time. Mediastinoscopy is still the most widely used procedure for mediastinal lymph node biopsy, but access to the aorticopulmonary window may be difficult and is limited by the aorta and left main bronchus. However, VATS makes it possible to reach all lymph node stations, including the posterior subcarinal, paraesophageal, and prevertebral stations²⁰.

The potentially aggressive behavior of relapsed NK/T-cell lymphomas makes early and correct pathological diagnosis and prompt treatment important. The patient described here developed a single mediastinal nodal relapse one month after initial treatment of the nasal NK/T cell lymphoma, and was diagnosed and treated using PET and VATS. This patient is still alive 35 months after the initial diagnosis and 30 months after the initial relapse without any evidence of further relapse.

REFERENCES

- Cheung MM, Chan JK, Lau WH, Foo W, Chan PT, Ng CS, Ngan RK. *Primary non-Hodgkin's lymphoma of the nose and nasopharynx: clinical features, tumor immunophenotype, and treatment outcome in 113 patients. J Clin Oncol* 16:70-77, 1998
- Ooi GC, Chim CS, Liang R, Tsang KW, Kwong YL. *Nasal T-cell/natural killer cell lymphoma: CT and MR imaging features of a new clinicopathologic entity. AJR Am J Roentgenol* 174:1141-1145, 2000
- Chan JK, Jaffe ES, Ralfkiaer E. *Extranodal NK/T cell lymphoma, nasal type. In: Jaffe ES, Harris NL, Stein H, eds. Pathology and genetics tumors of hematopoietic and lymphoid tissue. p. 204-207, Lyon, IARC Press, 2001*
- Jaffe ES, Chan JK, Su IJ, Frizzera G, Mori S, Feller AC, Ho FC. *Report of the Workshop on Nasal and Related Extranodal Angiocentric T/Natural Killer Cell Lymphomas: definitions, differential diagnosis and epidemiology. Am J Surg Pathol* 20:103-111, 1996
- Ferry JA, Skar J, Zukerberg LR, Harris NL. *Nasal lymphoma: a clinicopathologic study with immunophenotypic and genotypic analysis. Am J Surg Pathol* 15:268-279, 1991
- Liang R, Todd D, Chan TK, Chiu E, Lie A, Kwong YL, Choy D, Ho FC. *Treatment outcome and prognostic factors for primary nasal lymphoma. J Clin Oncol* 13:666-670, 1995
- Kim GE, Cho JH, Yang WI, Chung EJ, Suh CO, Park KR, Hong WP, Park IY, Hahn JS, Roh JK, Kim BS. *Angiocentric lymphoma of the head and neck: patterns of systemic failure after radiation treatment. J Clin Oncol* 18:54-63, 2000
- Chim CS, Ma SY, Au WY, Choy C, Lie AK, Liang R, Yau CC, Kwong YL. *Primary nasal natural killer cell lymphoma: long-term treatment outcome and relationship with the International Prognostic Index. Blood* 103:216-221, 2004
- Ko YH, Cho EY, Kim JE, Lee SS, Huh JR, Chang HK, Yang WI, Kim CW, Kim SW, Ree HJ. *NK and NK-like T-cell lymphoma in extranasal sites: a comparative clinicopathological study according to site and EBV status. Histopathology* 44:480-489, 2004
- Yao B, Li YX, Fang H, Jin J, Liu XF, Yu ZH. *Prognostic factors of primary non-Hodgkin's lymphoma of the nasal cavity: a report of 129 cases. Ai Zheng* 25:465-470, 2006
- Lee J, Suh C, Park YH, Ko YH, Bang SM, Lee JH, Lee DH, Huh J, Oh SY, Kwon HC, Kim HJ, Lee SI, Kim JH, Park J, Oh SJ, Kim K, Jung C, Park K, Kim WS. *Extranodal natural killer T-cell lymphoma, nasal type: a prognostic model from a retrospective multicenter study. J Clin Oncol* 24:612-618, 2006
- Sobrevilla-Calvo P, Meneses A, Alfaro P, Bares JP, Amador J, Reynoso EE. *Radiotherapy compared to chemotherapy as initial treatment of angiocentric centrofacial lymphoma (polymorphic reticulosis). Acta Oncol* 32:69-72, 1993
- Li YX, Yao B, Jin J, Wang WH, Liu YP, Song YW, Wang SL, Liu XF, Zhou LQ, He XH, Lu N, Yu ZH. *Radiotherapy as primary treatment for stage IE and IIE nasal natural killer/T-cell lymphoma. J Clin Oncol* 24:181-189, 2006
- Kim K, Chie EK, Kim CW, Kim IH, Park CI. *Treatment outcome of angiocentric T-cell and NK/T-cell lymphoma, nasal type: radiotherapy versus chemoradiotherapy. J Clin Oncol* 35:1-5, 2005
- Ng WK, Lee CY, Li AS, Cheung LK. *Nodal presentation of nasal type NK/T-cell lymphoma: report of two cases with fine needle aspiration cytology findings. Acta Cytol* 47:1063-1068, 2003
- Gutte H, Hojgaard L, Kjaer A. *Early clinical experience and impact of 18F-FDG PET. Nucl Med Commun* 26:989-994, 2005
- Brix G, Nosske D, Glatting G, Minkov V, Reske SN. *A survey of PET activity in Germany during 1999. Eur J Nucl Med Mol Imaging* 29:1091-1097, 2002
- Radford JA, Cowan RA, Flanagan M, Dunn G, Crowther D, Johnson RJ, Eddleston B. *The significance of residual mediastinal abnormality on the chest radiograph following treatment for Hodgkin's disease. J Clin Oncol* 6:940-946, 1988
- Surbone A, Longo DL, DeVita VT Jr, Ihde DC, Duffey PL, Jaffe ES, Solomon D, Hubbard SM, Young RC. *Residual abdominal masses in aggressive non-Hodgkin's lymphoma after combination chemotherapy: significance and management. J Clin Oncol* 6:1832-1837, 1988
- Massone PP, Lequaglie C, Magnani B, Ferro F, Cataldo I. *The real impact and usefulness of video-assisted thoracoscopic surgery in the diagnosis and therapy of clinical lymphadenopathies of the mediastinum. Ann Surg Oncol* 10:1197-1202, 2003