

# Iatrogenic Glossopharyngeal Neuropathy in Aesthetic Practice: A Case Report

Leniza R. Mingazova, MD, PhD\*  
 Elena I. Karpova, MD, PhD†  
 Stanislav V. Murakov, MD, PhD‡  
 Olga I. Danishuk, MD, PhD‡  
 Vladimir G. Bychenko, MD, PhD\*  
 Olga R. Orlova, MD, PhD\*  
 Marina I. Soykher, MD, PhD\*  
 Vladimir N. Nikolenko, MD, PhD\*  
 Mikhail Y. Sinelnikov, MD, PhD\*

**Summary:** Iatrogenic glossopharyngeal nerve injuries are commonly associated with procedures such as a tonsillectomy, carotid endarterectomy, and endotracheal intubation. We present a previously unreported complication of a thread lift procedure in the jowl region, causing damage to the glossopharyngeal nerve through compression. The glossopharyngeal nerve belongs to the bulbar group of the cranial nerves. It is connected with the vagus and, therefore, is closely associated with the latter functionally and anatomically. Damage to the former may present with cardiovascular complications associated with the vagus nerve. The presented case demonstrates the diagnostic and treatment aspects of iatrogenic injury to the glossopharyngeal nerve. (*Plast Reconstr Surg Glob Open* 2022;10:e4166; doi: 10.1097/GOX.0000000000004166; Published online 11 March 2022.)

The wide use of thread lift rejuvenation in aesthetic medicine has led to an increase in the variety and incidence of complications.<sup>1</sup> The thread lift procedure is a blind intervention, with no direct visualization of important anatomical structures. As such, risk of damage to these structures is high. Damage to regional nerves is associated with specific and nonspecific symptoms, including sensory deficits, pain, movement impairment, and autonomic dysfunction. Damage to the peripheral branches of the trigeminal nerve is most commonly seen in facial interventions.<sup>2</sup> We describe our experience in diagnosis and treatment of injury to the glossopharyngeal nerve, brought about by compression of the nerve trunk due to a thread lift procedure.

## CASE REPORT

A 45-year-old female patient underwent facial contour correction with a thread lift (23 cm poly-L-lactic acid based Happy Lift double needle threads). A double-loop threading was used. The thread was inserted at the mastoid process base in the posterior auricular region. The vector of thread insertion was directed toward the jowls. Two loops were formed: the primary loop was shaped superior-medially; the secondary loops were inferior-lateral, with

the apex of the loop near the jowl. The procedure was performed on both sides, starting with the right side. While performing the second loop on the left side, the patient felt a sudden intense pain in the throat, root of the tongue, and left palatine tonsil, followed by a burning sensation, radiating toward the left auricle. Bradycardia (55 beats/min), a decrease in blood pressure to 80/50 mmHg, was noted. The procedure was interrupted immediately, and cryotherapy was commenced. In this condition, the patient remained hospitalized at the cosmetic clinic for 5 days.

1 month after the incident, the patient was referred to our neurological clinic. The patient complained of constant, monotonous burning pains, cutting in the throat—at the root of the tongue, palate, and tonsils on the left. The pain radiated into the auricular region. Upon evaluation, edema of the oral cavity base and auricular region were noticed, as well as sensory impairments (foreign body sensation in the left retromandibular region), sensation deficit (impaired pain and temperature sensitivity at the root of the tongue, left soft palate, oropharynx), ageusia in the posterior third of the tongue, xerostomia, persistent hypotension, and bradycardia (BP = 90/60, heart rate = 60 per minute). The evaluation findings were consistent with glossopharyngeal injury, with vagus nerve involvement (Fig. 1). An MRI was performed, which revealed thread remnants in the left parotid gland.

Due to symptom persistence and presence of a foreign body within the parotid gland, a surgical revision was planned. A periauricular incision was performed, and the parotid gland was visualized. According to intraoperative ultrasound, the thread was located and excised from the parotid gland (Fig. 2). No complications occurred.

After surgery, the patient noticed significant improvement. On examination 3 days postoperatively, it was found

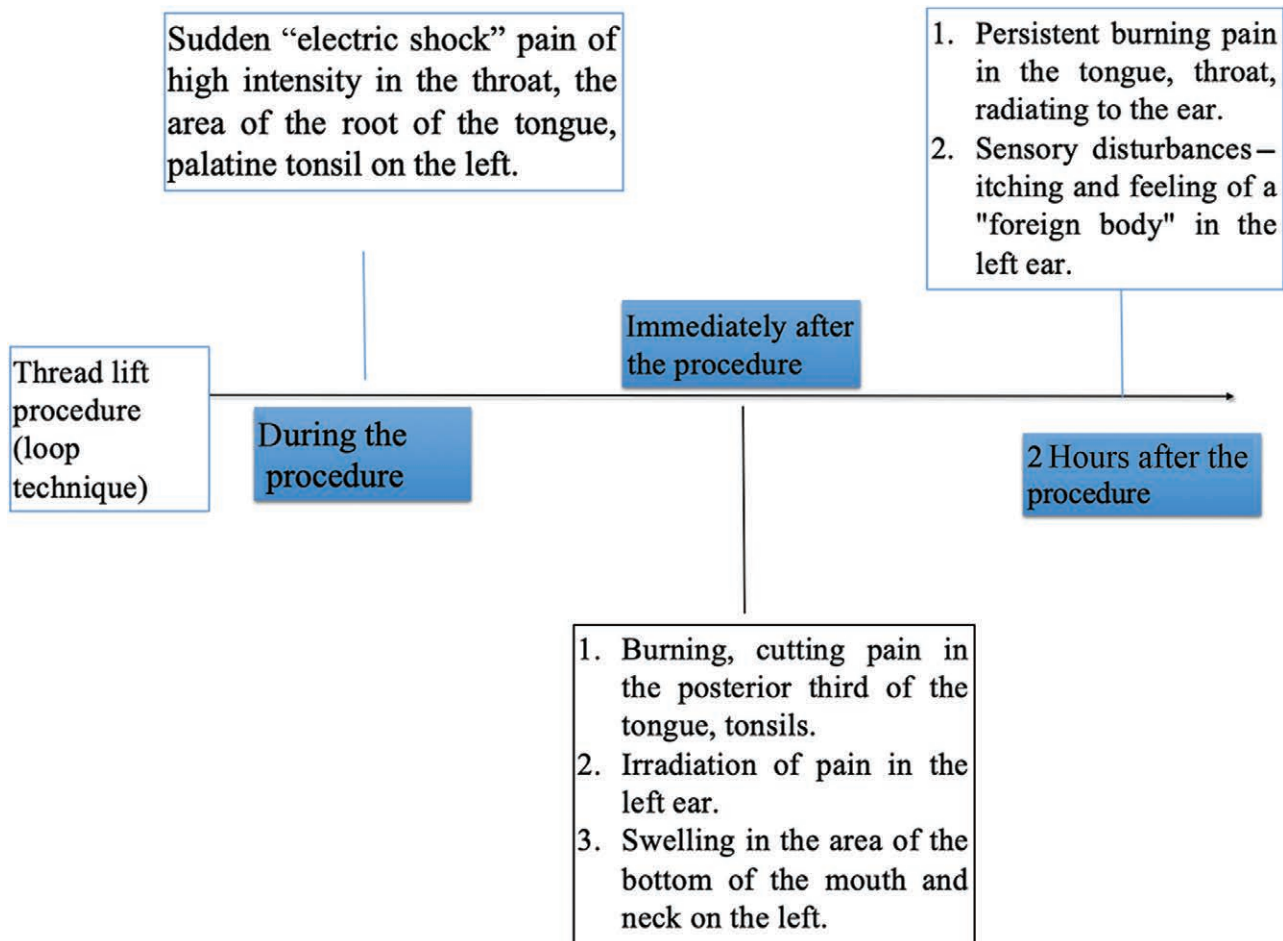
From the \*Sechenov University, Moscow, Russian Federation; †Pirogov State Medical University, Moscow, Russian Federation; and ‡Federal Medical Biological Academy, Moscow, Russian Federation.

Received for publication April 20, 2021; accepted January 6, 2022.

Copyright © 2022 The Authors. Published by Wolters Kluwer Health, Inc. on behalf of The American Society of Plastic Surgeons. This is an open-access article distributed under the terms of the Creative Commons Attribution-Non Commercial-No Derivatives License 4.0 (CCBY-NC-ND), where it is permissible to download and share the work provided it is properly cited. The work cannot be changed in any way or used commercially without permission from the journal.

DOI: 10.1097/GOX.0000000000004166

**Disclosure:** The authors have no financial interest to declare in relation to the content of this article.



**Fig. 1.** Summary of clinical manifestation at different time periods.

that the intensity of pain in the area of the tongue root was significantly reduced. Signs of weakness (drooping) of the soft palate on the left disappeared. When pronouncing the sounds “A” and “E,” the pharynx walls vibrated symmetrically on both sides. Signs of neurosensory deficiency (hypoalgesia, thermhypesthesia, ageisia) in the posterior third of the tongue persisted. Supporting therapy included Berlithion 600 mg per os daily and magnesium and vitamin B6 supplementation. Sensory disturbances, as well as signs of xerostomia and ageusia regressed at 1 month following surgery. Sensory impairments resolved completely within hours after surgery. Sensory deficit (loss of nociceptor, temperature and tactile sensitivity, subjective sensation of itching and ear congestion), xerostomia, and ageusia resolved within 1 month after surgery. Complete sensation restoration was noted 12 months after surgery. As such, a complete recovery was achieved.

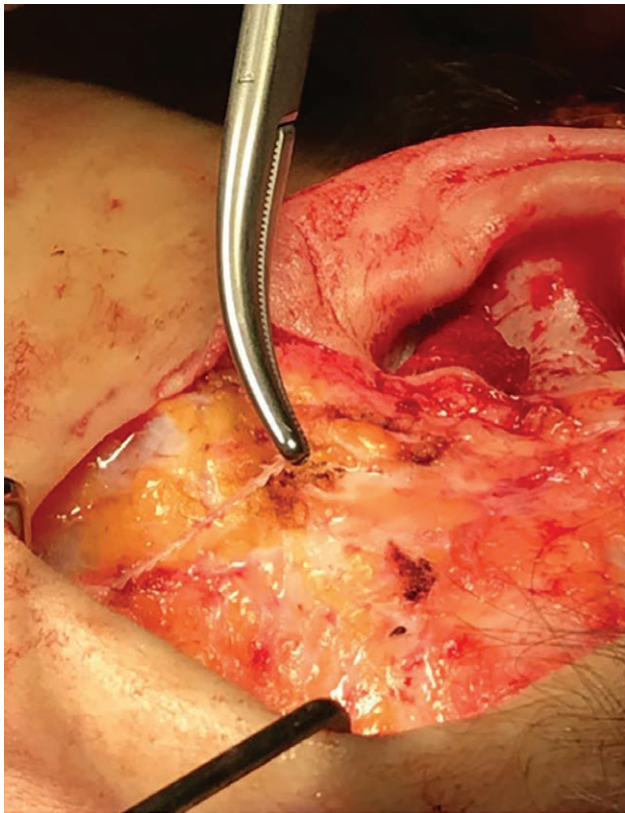
### DISCUSSION

The glossopharyngeal nerve exits in the cranial cavity through the jugular foramen and travels superficially to the internal carotid artery and deep to the jugular vein, external carotid artery, and styloid process. The main trunk of the glossopharyngeal nerve travels past the lateral border of the stylopharyngeus muscle toward the base of

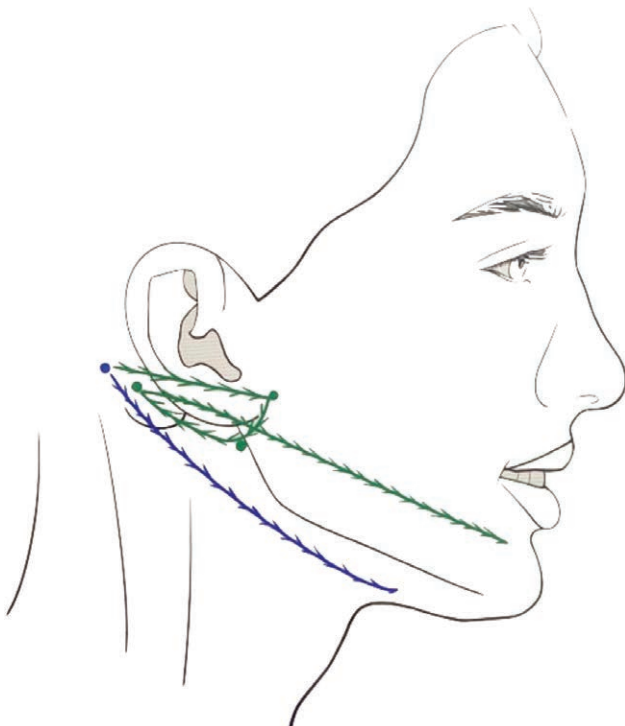
the tongue. Deep within the hyoid muscle, the main trunk of the glossopharyngeal nerve is divided into the terminal lingual and tonsillar branches. In the parapharyngeal space, the glossopharyngeal nerve branches into the tympanic nerve, the carotid sinus nerve, and the glossopharyngeal branch to the pharyngeal plexus.<sup>1</sup>

The thread lift procedure generally involves the lower and middle thirds of the face, with superficial (above SMAS) passage of the thread. Nonetheless, as seen in our report, the superficial direction of the thread cannot always be controlled.

In clinical practice, injury to the glossopharyngeal nerve is described during a tonsillectomy,<sup>3-6</sup> carotid endarterectomy,<sup>7-9</sup> and endotracheal intubation.<sup>10</sup> In our report, injury to the glossopharyngeal nerve may have been caused due to tissue compression and improper placement of the thread posterior to the mandible. Direct damage to the glossopharyngeal nerve may also be hypothesized, due to the significant clinical symptoms. The clinical presentation suggests unilateral damage and compression to the glossopharyngeal nerve, most likely the lingual branch. Fast recovery after surgery also suggests that the glossopharyngeal nerve was compressed as a result of the formation of a “loop” between the two threads (Fig. 3). After surgical removal of the thread, the “loop” tension is broken, relieving the underlying affected structures.



**Fig. 2.** Intraoperative view of needle located within the parotid gland.



**Fig. 3.** "Loop" method of aesthetic thread lift of the lower third of the face.

The clinical symptoms seen in our case report are associated with specific function of the glossopharyngeal nerve, including taste, sensation, and communicatory branches to the vagus nerve. The latter explains the presence of cardiovascular symptoms, which were brought about by vagus involvement. Xerostomia showed damage to the parasympathetic innervation of the salivary glands and direct damage to the parotid gland. Even though the exact location of injury to the glossopharyngeal nerve could not be located, the symptoms, radiology data, and thread lift protocol provide evidence supporting iatrogenic damage to the glossopharyngeal nerve.

## CONCLUSIONS

Facial rejuvenation procedures are increasingly popular, with minimally invasive procedures being favored over surgery. Nonetheless, such manipulations (including thread lift) may be more dangerous, due to inability to account for anatomical variations and directly visualize tissues, and can result in lasting tissue damage. The presented complication of a lower third thread lift (jowl lift) shows symptoms associated with glossopharyngeal damage through compression, brought about by thread tightening. A surgical revision was necessary to relieve tension. A complete recovery was achieved, with substantial improvement directly after surgical correction. Working within the superficial tissue of the face does not protect the operator from deep structure damage from compression, and this should be accounted for when planning a thread lift.

Mikhail Y. Sinelnikov, MD, PhD

Sechenov University

Moscow, Russian Federation

E-mail: mikhail.y.sinelnikov@gmail.com

## REFERENCES

1. Goodwin WJ Jr, Arnold D, Wachholz J. Surgical anatomy of the glossopharyngeal nerve. *Laryngoscope*. 1993;103(11 Pt 1):1302–1304.
2. Klazen Y, Van der Cruyssen F, Vranckx M, et al. Iatrogenic trigeminal post-traumatic neuropathy: a retrospective two-year cohort study. *Int J Oral Maxillofac Surg* 2018;789–793.
3. Uzun C, Adali MK, Karasalihoglu AR. Unusual complication of tonsillectomy: taste disturbance and the lingual branch of the glossopharyngeal nerve. *J Laryngol Otol*. 2003;117:314–317.
4. Ford LC, Cruz RM. Bilateral glossopharyngeal nerve paralysis after tonsillectomy: case report and anatomic study. *Laryngoscope*. 2004;114:2196–2199.
5. Hong SA, LaGorio L, Husain I. Post-tonsillectomy dysphagia secondary to glossopharyngeal nerve injury. *BMJ Case Rep*. 2020;13:e232657.
6. Trindade A, Philpott CM. Bilateral glossopharyngeal nerve palsy following tonsillectomy: a very rare and difficult complication of a common procedure. *J Laryngol Otol*. 2015;129:392–394.
7. AbuRahma AF, Choueiri MA. Cranial and cervical nerve injuries after repeat carotid endarterectomy. *J Vasc Surg*. 2000;32:649–654.
8. Forssell C, Kiting P, Bergqvist D. Cranial nerve injuries after carotid artery surgery. A prospective study of 663 operations. *Eur J Vasc Endovasc Surg*. 1995;10:445–449.
9. Rosenbloom M, Friedman SG, Lamparello PJ, et al. Glossopharyngeal nerve injury complicating carotid endarterectomy. *J Vasc Surg*. 1987;5:469–471.
10. Laffon M, Ferrandière M, Mercier C, et al. Transient lingual and glossopharyngeal nerve injury: a complication of cuffed oropharyngeal airway. *Anesthesiology*. 2001;94:719–720.