

## CASE REPORT

## Three cases of acute distal demyelinating neuropathy with recovery

Emilia Österlund-Tauriala<sup>1</sup>  & Juhani V. Partanen<sup>2</sup><sup>1</sup>Clinical Neurosciences, Neurology, Helsinki University Hospital, University of Helsinki, Helsinki, Finland<sup>2</sup>Clinical Neurosciences, Clinical Neurophysiology, Helsinki University Hospital, University of Helsinki, Helsinki, Finland

### Correspondence

Emilia Österlund-Tauriala, Department of Neurology, Helsinki University Central Hospital, P.O.Box 340, 00029 HUS, Finland.  
Tel: +358-9-4711; Fax: +358-9-47185942;  
E-mail: emilia.osterlund-tauriala@hus.fi

### Funding Information

Helsingin ja Uudenmaan Sairaanhoidopiiri.

Received: 26 October 2015; Revised: 23 August 2016; Accepted: 2 March 2017

*Clinical Case Reports* 2017; 5(6): 822–828

doi: 10.1002/ccr3.943

### Introduction

An acute demyelinating polyneuropathy with spontaneous recovery was observed in three patients. The main symptoms were distal symmetrical paresthesia and muscle weakness. In contrast to classical Guillain–Barré syndrome (GBS), tendon reflexes were preserved. Serial nerve conduction studies were performed to three patients. At onset, there was an increase in distal motor latencies (DML) and temporal dispersion and diminution of CMAP, while sensory conduction velocities (SCV) remained normal. At nadir, there was a massive increase in DML and temporal dispersion. Sensory responses were blocked in hands and feet. Radial and sural SCVs remained normal. No excessive A-waves were observed. H-reflexes were normal. All patients improved clinically and neurophysiologically without treatment. In one case, full recovery was confirmed with nerve conduction studies (NCS). This study suggests a rare distal variant of acute inflammatory demyelinating polyradiculoneuropathy (AIDP): an acute, monophasic, distal demyelinating neuropathy without radiculitis.

After the first report of Guillain–Barré syndrome in 1916, Guillain himself concluded in 1938 that GBS could present in different ways and proposed four topographical

### Key Clinical Message

Guillain–Barré syndrome (GBS) may present as distal acute inflammatory demyelinating polyradiculoneuropathy (AIDP), with severe distal demyelination of the peripheral nerves in the absence of radiculitis. Clinical course is benign, and prognosis seems favorable, but nerve conduction studies (NCS) findings at nadir may resemble some chronic forms of polyneuropathy, so close follow-up during recovery is needed.

### Keywords

Acute inflammatory demyelinating polyneuropathy, acute polyneuropathy, distal AIDP, electroneuromyography, Guillain–Barré syndrome.

patterns of neurological involvement [1]. In recent decades, several new distinct subtypes have been introduced. Guillain–Barré syndrome now includes AIDP, acute motor axonal neuropathy (AMAN), acute motor and sensory axonal neuropathy (AMSAN), acute sensory neuropathy, acute pandysautonomia, and Miller Fisher syndrome [2]. A recent addition to the classification is facial variant AIDP [3]. In this article, we report three cases of neurophysiologically severe but clinically relatively benign acute polyneuropathy with spontaneous recovery.

### Methods

Three previously healthy patients were referred for nerve conduction studies (NCSs) and needle electromyography (EMG) because of acute paresthesia and muscle weakness of the hands and feet. Needle EMG was performed on patients 2 and 3 as part of every evaluation, except the first recording of patient 2 because 6 days after onset was too early for fibrillations to occur. Patient 1 refused needle studies. The muscles studied included but were not limited to the dorsal interosseus I or opponens pollicis in the hand and dorsal interosseus IV in the foot.

Nerve conduction studies and needle EMG were carried out according to the description in the book *Electrodiagnostic Medicine* [4] on Keypoint Classic EMG equipment, ver. 3.21 (Medtronic Functional Diagnostics A/S, Skovlunde, Denmark) using surface electrodes (NM-420S, Nihon Kohden, Tokyo, Japan, and NF-50-K/W/12, Ambu A/S, Ballerup, Denmark). Most studies were performed unilaterally on the right side, some bilaterally to confirm symmetry. For clarity, only unilateral findings are reported in Table 1.

The temperature of the skin was  $>30^{\circ}\text{C}$  in all NCV studies, measured with Fluke 61 Infrared Thermometer (Fluke Electronics, Minneapolis, MN). Needle EMG was using disposable 0.35-mm-diameter concentric needle electrodes (Ambu Neuroline, Ambu A/S, Ballerup, Denmark).

## Results

Patient 1 was a 17-year-old woman. She developed distal numbness in the extremities, 2 weeks after an upper respiratory tract infection with fever. Five days later, she could not walk on toes or heels and her hand grip was weakened. Romberg's test was positive. Tendon reflexes in the extremities were normal.

MRI scans of head and spine were normal. Leukocyte count and protein level in the cerebrospinal fluid (CSF) were normal. Six weeks from onset, serum antiganglioside IgM and IgG (GM1) and *Borrelia* antibodies were negative. She was managed conservatively as the symptoms were mild. At 6 weeks of follow-up, the symptoms were already improving.

Seven weeks after onset, nerve conduction studies (Table 1) showed markedly prolonged distal latencies. The compound muscle potentials (CMAPs) were temporally dispersed with commensurate reduction in amplitude. Median and peroneal MCV could not be measured because the sweep duration of the equipment could not be adjusted long enough. Accordingly, F-waves were absent; at follow-up, F-wave latencies were prolonged. Median and radial SNAP amplitudes were decreased with only slightly decreased velocity. Sural SNAP and velocity remained normal. At 4 months, the patient only had some tiring of the feet when walking long distances. At 27 weeks, there was substantial improvement in all NCSs (Table 1). Five months later, the patient felt well and refused any further tests.

Patient 2 was a 31-year-old woman, who had difficulty running, paresthesia in the extremities, and numbness of the soles, a week after gastroenteritis and fever. She had mild pain in the shoulders, upper extremities, and lower back and headache especially around the eyes. She reported paresthesia on the perioral and nasal region and

experienced palpitations and difficulty breathing especially at night. Sharp and touch sensation was impaired in hands and feet, while sensation of cold and vibration as well as tendon reflexes were preserved. The patient had difficulty walking in a straight line, and Romberg's test was positive. The course of disease was progressive for 4 weeks, but the patient remained ambulatory and no immunotherapy was applied.

MRI scans of the head and neck were normal. The leukocyte count and protein level in the CSF were normal. *Borrelia* IgG and IgM and anti-MAG antibodies were negative. 4.5 months after onset, a slight elevation of voltage-gated K channel antibodies, 110 pmol/L, was detected (cutoff 85 pmol/L). Antiganglioside (GM1) IgM and IgG antibodies and *Campylobacter* antibodies were negative.

Nerve conduction studies were performed 6 days, 4 weeks, 14 weeks, 23 weeks, and 1.5 years after onset of symptoms (Table 1). Needle EMG was normal. Six days after onset, CMAP duration already showed a wide dispersion pattern, and CMAP amplitude was diminished. At nadir, distal motor latencies (DMLs) were up to five times the upper level of normal (ULN), and CMAP duration was even more widely dispersed. During recovery, DMLs and CMAP amplitudes gradually returned to normal, as seen in follow-up NCS (Table 1). Some F-responses showed increased minimum latency, but A-waves were absent. Changes in motor nerve responses are presented in Figures 1 and 2.

The median SNAP across the carpal tunnel was blocked, while the SCV in the forearm segment remained normal. During recovery, a gradual increase in SNAP amplitude and velocity was seen in the distal segment. A decreased SNAP amplitude at nadir was seen especially in the radial nerve in all patients although the SCV remained normal.

At 8 weeks, the symptoms begun to improve. The patient still had some difficulty in fine motor skills and walking long distances. After 1.5 years, the remaining symptom was mild paresthesia of the soles.

Patient 3 was a 60-year-old woman. Three weeks after a hepatitis A vaccination, she presented with extreme pain in the thoracic spine. Within a couple of days, the pain alleviated and she started to feel paresthesia on the hands and feet, nose, and upper lip. Sharp and touch sensation was impaired in the fingers and toes, while tendon reflexes were readily elicited. She reported altered sensation on the ventral side of the body. Sense of vibration in the extremities was normal. There was no distinct muscle weakness.

MRI scans of the head, neck, and thoracic spine were normal. Two months after onset, CSF protein level was elevated, 58 mg/dL (cutoff 45 mg/dL) without pleocytosis.

**Table 1.** Nerve conduction studies.

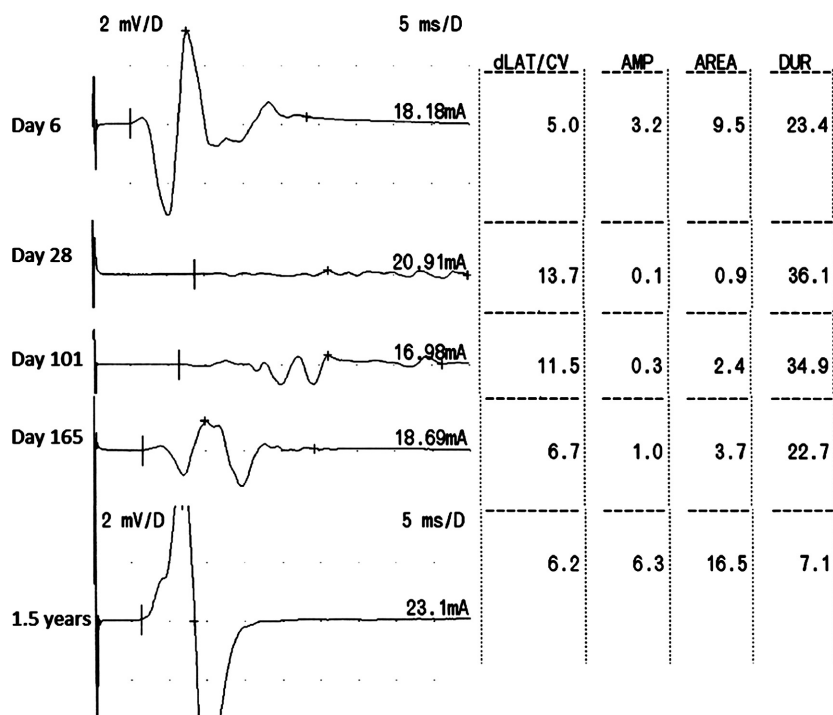
Variable	Patient 1		Patient 2					Patient 3		
	Day 50	Day 190	Day 6	Day 28	Day 101	Day 165	1.5 years	Day 51	Day 191	5 years
Median motor										
DML	19.4	5.2	6.5	19	11.7	9.4	4.3	10.9	4.5	3.9
CMAPamp	2.9	4.7	2.1	0.5	2.3	4.2	8.1	2.9	6.7	8.8
CMAPdur	9.7	5	17.3	27.3	12.6	8.6	5.7	10.5	4.2	4.1
MCV	–	51.5	54.7	51.5	53.5	50	53.5	54	55.9	59.5
FminL	–	32.8	31.3	64	40.2	36.3	27.9	–	27	27
Z score		5	3	29.9	10.3	7.1	0.3			1.5
H refl L	19	17	–	17.5	17.5	17.7	17	–	–	14.5
Z score	3.2	0.9		0.9	0.9	1.1	0.3			–0.5
Ulnar motor										
DML	4.3	3.8	3.8	10.2	7.3	5.6	2.9	2.9	2.4	3
CMAPamp	3.8	4	7.6	1.4	1.9	7.7	7.5	1.5	5.1	5.6
CMAPdur	8.3	4.6	6.6	16.5	12.4	9.5	7.0	6.3	5.6	5.2
MCV	37.2	50.4	57.7	52.8	49.2	52	59.3	52.4	56.4	59.5
FminL	NR	30.3	30.5	NR	37	33.8	28.3	28.5	25.6	25.3
Z score		1.8	1.2		6	3.6	–0.5	2.6	0.5	0.2
Deep peroneal motor										
DML	26.2	6.3	8.3	19	11.4	8.1	4.4	7.2	3.8	4.2
CMAPamp	0.3	2.4	1	0.5	1.9	2.2	2.2	1.4	3.6	2.4
CMAPdur	17.8	5.4	11.4	27.3	13.1	12	11	14.8	5.3	5.1
MCV	–	45.9	48.9	43.5	44.7	42.1	43.4	48	51.4	52.2
FminL	NR	55.8	30.5	69.6	60.3	58.5	54	50.1	44.3	43.1
Z score		4.3	1.2	10	5.5	4.7	2.6	3.6	0.9	0.9
Tibial motor										
DML	29.2	7.3	5	13.7	11.5	8.8	6.1	7.3	–	5
CMAPamp	0.1	1.8	0.5	0.1	0.3	1.1	2.8	0.6		5.1
CMAPdur	19	4.7	29.6	36.1	34.6	22.4	8.4	28.8		5.5
H refl L	31.2	30.3	31.3	32	31.5	31.7	31.5	27.7	27.3	27.2
Z score	1.7	1	1.2	1.7	1.3	1.4	1.3	0.7	0.4	0.3
Median sensory										
AntebrA	14	28	37	49	48	57	58	17	16	23
AntebrCV	69.4	70.6	60.5	63.6	63.5	62.2	63.2	67.1	67.7	70.3
3 fing A	6	27	29	NR	NR	9	27	NR	13	46
3 fing CV	20.1	40.9	48.3	NR	NR	30.4	54.8	NR	37.5	44.3
Radial sensory										
SNAP	25	43	53	22	14	15	36	24	36	45
SCV	60.6	64.1	55.9	58.6	52.6	59.9	54.6	63.3	61.7	66.7
Superficial peroneal sensory										
SNAP	1.8	4.7	6.8	NR	1.1	1.7	4.9	5	9.2	15
SCV	35.7	43.3	44.6	NR	33	35.3	45.2	41.4	48	54.3
Sural sensory										
SNAP	15	24	18	14	11	13	15	16	15	17
SCV	47.1	50	50.4	47.4	48.3	48	47.8	48	52.2	52.3

DML, distal motor latency; CMAP, compound muscle action potential; MCV, motor (nerve) conduction velocity; SCV, sensory (nerve) conduction velocity; SNAP, sensory nerve action potential; NR, no response.

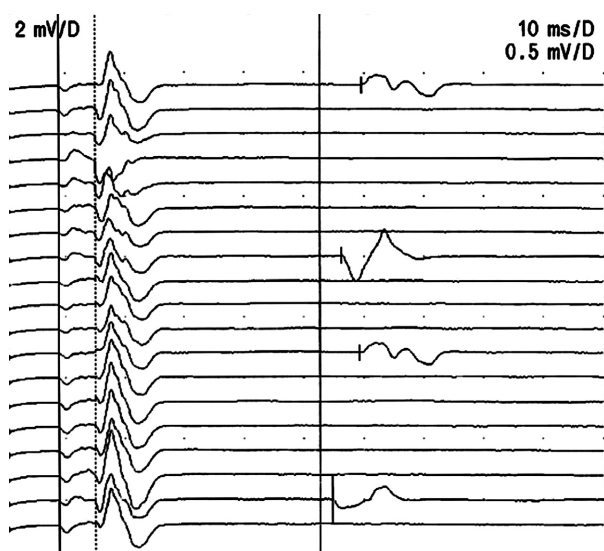
Nerve conduction studies and needle EMG were performed 7 weeks, 27 weeks, and 5 years after onset of symptoms. Needle EMG was normal. Nerve conduction studies showed prolonged DML in median, tibial, and peroneal nerves with normal MCVs. CMAP duration showed a very wide dispersion pattern, and the CMAP amplitude was diminished. Tibial H-reflex latency was

normal. SNAP amplitudes were decreased with sural sparing. Median SCV was slowed across the carpal tunnel.

Five months after onset, the patient had mild remaining symptoms and became symptomless later on. Five years later, follow-up NCS was arranged to confirm complete recovery, and nerve conduction studies were within normal range (Table 1).



**Figure 1.** Tibial CMAP: 6 days after onset; at nadir; and three times during recovery. dLAT/CV, distal motor latency (ms); AMP, amplitude of the compound muscle action potential (mV); DUR, duration of the motor response (ms).



**Figure 2.** Peroneal F-responses at onset (patient 2). The minimum latency is increased, but there are no A-waves. Note also the wide temporal dispersion and diminished amplitude of the CMAP.

## Discussion

The clinical features and NCS findings suggest a distal variant of AIDP: an acute, monophasic, distal demyelinating neuropathy without radiculitis. Nerve conduction

studies in the extremities were very abnormal, but clinical symptoms were mild, possibly owing to only distal impairment of nerve function. There were no GM1 antibodies. The prognosis for this subtype seems to be favorable, and specific immunotherapy may not be required.

## Clinical aspects

The course of the disease meets most of the criteria of GBS: It is a self-limited acute neuropathy that starts 1–3 weeks after a respiratory illness or gastroenteritis and reaches a nadir within 4 weeks, and recovery can be complete [2]. There is a plateau phase that ranges from days to several weeks or months, followed by a recovery phase of varying duration that is usually much slower [5]. Symmetry of symptoms, mild sensory symptoms, autonomic dysfunction, and pain are features that strongly support the diagnosis of GBS [6]. Patient 2 noted palpitations and breathing difficulty. Two of the patients reported pain that did not respond well to treatment.

The essential difference compared with AIDP is the absence of radiculitis: There is no flaccid paralysis or ataxia, and tendon reflexes remain intact (see also [6, 7]). A recent cohort study found decreased reflexes in paretic arms or legs initially in 91% of patients and during follow-up, in all patients [8]. Even patients with mild disease had decreased reflexes early on [9]. Some GBS-

resembling conditions were excluded from the diagnostic criteria because the number of cases missed by the current criteria was considered to be extremely low, under 1% [10].

Yuki et al. suggested in 2012 that the existing diagnostic criteria of GBS should be expanded to include patients with preserved tendon reflexes [11]. Their study demonstrated that tendon reflexes could be normal or hyperexcitable throughout the entire clinical course in 10% of patients with GBS. Most of their 32 patients had IgG antibodies to GM1, GM1b, GD1a, or GaINAc-GD1a (27/32) and were finally diagnosed with AMAN. Three patients received a final diagnosis of AIDP, but their NCS findings were not reported.

Two of our patients had symptoms of an infection 1–2 weeks before the onset of paresthesia and weakness. About two-thirds of patients with GBS have symptoms of an infection in the 3 weeks before the onset of weakness [6]. Patient 3 was vaccinated against hepatitis A 3 weeks before onset. Hepatitis vaccinations have been suggested to be associated with the occurrence of GBS [12].

The typical monophasic clinical course of the disease is an argument for the postinfectious nature of this condition [6]. Our patients recovered spontaneously, and relapses have not come to our knowledge. Serologic studies were normal in all except patient 2, who had slightly elevated voltage-gated K channel (VGKC) antibodies 4.5 months after the onset of symptoms. These were not measured in the other two patients. A recent study states that a positive VGKC complex antibody test does not indicate that the patient has an autoimmune or paraneoplastic syndrome. LGI1 or Caspr2 would be more indicative of true antibodies against the VGKC complex, but they were not tested [13].

Alternative causes, such as Lyme disease, sarcoidosis, exposure to heavy metals, biological toxins or drug intoxication, vasculitis, and lymphomatous neuropathy, were considered and excluded with appropriate tests [2]. An important differential diagnosis in the acute phase is acute-onset CIDP [14].

In GBS, CSF is taken primarily to rule out other pathologies, such as Lyme disease or lymphoma. Albuminocytologic dissociation develops over time and is observed in only 75% of cases 3 weeks after onset [15]. Patients 2 and 1 had CSF samples taken rather early in this regard, within 1 and 2 weeks after onset, respectively. Patient 3 did have elevated CSF protein without pleocytosis.

### Electrophysiological aspects

Neurophysiological studies play a very important role in diagnosis, subtype classification, and confirmation that

the disease is a peripheral neuropathy [16]. There is no consensus on neurophysiological criteria for classification of GBS. NCS in our patients fulfilled most of the neurophysiological criteria for AIDP proposed by Hughes and Cornblath in *The Lancet* in 2005 [2]. DML should be over 120% compared to the upper level of normal in at least two nerves. In our patients, all motor nerves had an increased DML up to 500% compared to the upper level of normal, except for the normal ulnar DML in patient 3. The CMAP was diminished but remained >10% compared to the lower level of normal in all motor nerve measurements, except for the tibial nerve with small or absent CMAPs at nadir. All patients had an F-response latency >120% of the upper level of normal in at least two nerves. In contrast to GBS, all MCVs remained normal [17], except for the slow ulnar MCV in patient 1.

There was slowing or block of the distal sensory responses (median, ulnar, superficial peroneal, and tibial), but preservation of more proximal sensory responses and SCVs (radial, sural, and forearm segment of median nerve). The “sural sparing” pattern is characteristic of GBS [18].

Nerve conduction studies can only assess proximal segments indirectly by measuring H-reflexes and F-wave latencies. Patient 1 had modest slowing of median nerve H-reflex latency at nadir, but all other H-reflex latencies remained normal in all patients. The increased F-wave minimum latency was attributed to the increase in DML. There was no increase in the number of A-waves, as would be typical for acute GBS [19]. Normal needle EMG throughout the disease suggests that there was no axonal damage to motor nerves.

The findings can be explained by distal demyelination of the peripheral nerves, with less affected middle and proximal parts. Focal enlargement of the peripheral nerves, visualized using high-resolution ultrasound (HRUS), has been reported in early GBS [20]. Acute enlargement of the peripheral nerve could cause impingement in the carpal and tarsal tunnels and, in turn, demyelination in the nerve passing through. Moreover, symptoms were not length dependent; two patients complained of paresthesia in the distal areas of trigeminal nerves and/or sensory disturbances in the distal areas of anterior cutaneous thoracic nerves.

A review of the literature states that a pattern of prolonged DMLs consistent with demyelination, less pronounced slowing in adjacent forearm and lower leg segments, and decreased CMAPs and SNAPs in lower limbs, consistent with axon loss, is unique to anti-MAG neuropathy [21]. Patient 2 was tested 2 months after onset, and she did not have MAG antibodies, and patients 2 and 3 had normal serum protein electrophoresis. In all patients, the clinical course proved against

anti-MAG neuropathy, which is a chronic, slowly progressing disease [22]. Possible explanations for this topographical distribution are a more permeable blood-nerve barrier or more prominent antigen expression in distal axons, which makes them more vulnerable to certain antibodies [16].

## Conclusion

Serial NCSs in three patients with an acute monophasic neuropathy demonstrate an evolving demyelinating neuropathy with distal demyelination and conduction block, which resolves over time partially or completely. Reduction and dispersion in CMAPs and prolonged F-wave latencies fulfill the neurophysiological diagnostic criteria for demyelinating neuropathy in GBS. However, there is no evidence of radiculitis: The symptoms are distal, A-waves are absent, and tendon reflexes preserved.

## Authorship

EÖT: involved in data acquisition; analysis and interpretation of data; drafting the manuscript; revising the manuscript critically for important intellectual content; approval of the version of the manuscript to be published. JVP: involved in data acquisition; analysis and interpretation of data; revising the manuscript critically for important intellectual content; approval of the version of the manuscript to be published.

## Acknowledgments

We thank Professor Pentti Tienari for valuable comments on the manuscript.

## Source of Funding

Publishing this work was funded by the Department of Neurology, Helsinki University Central Hospital.

## Conflict of Interest

None declared.

## References

- Guillain, G. 1938. Les polyradiculonevrites avec dissociation albumin-cytologique et a evolution favorable (syndrome de Guillain et Barré). *J. Belge. Neurol. Psychiatry.* 38:323–329.
- Hughes, R. A. C., and D. R. Cornblath. 2005. Guillain-Barré syndrome. *Lancet* 9497:1653–1666.
- Susuki, K., M. Koga, K. Hirata, E. Isogai, and N. Yuki. 2009. A Guillain-Barré syndrome variant with prominent facial diplegia. *J. Neurol.* 256:1899–1905.
- Dumitru, D., A. A. Amato, and M. J. Zwarts, eds. 2002. *Electrodiagnostic medicine*, 2nd ed. Pp. 159–256. Hanley & Belfus Inc., Philadelphia.
- van Doorn, P. A., L. Ruts, and B. C. Jacobs. 2008. Clinical features, pathogenesis, and treatment of Guillain-Barré syndrome. *Lancet Neurol.* 7:939–950.
- Uncini, A., and S. Kuwabara. 2012. Electrodiagnostic criteria for Guillain-Barré syndrome: a critical revision and need for an update. *Clin. Neurophysiol.* 123:1487–1495.
- Shahrizaila, N., K. J. Goh, S. Abdullah, R. Kuppasamy, and N. Yuki. 2013. Two sets of nerve conduction studies may suffice in reaching a reliable electrodiagnosis in Guillain-Barré syndrome. *Clin. Neurophysiol.* 124:1456–1459.
- Fokke, C., B. van den Berg, J. Drenthen, C. Walgaard, P. A. van Doorn, and B. C. Jacobs. 2014. Diagnosis of Guillain-Barré syndrome and validation of Brighton criteria. *Brain* 137:33–43.
- van Koningsveld, R., P. I. Schmitz, C. W. Ang, J. Groen, A. D. M. E. Osterhaus, F. G. A. Van der Meche, et al. 2002. Infections and course of disease in mild forms of Guillain-Barre syndrome. *Neurology* 58:610–614.
- Sejvar, J. J., K. S. Kohl, J. Gigudu, A. Amato, N. Bakshi, R. Baxter, et al. 2011. Guillain-Barré syndrome and Fisher syndrome: case definitions and guidelines for collection, analysis, and presentation of immunization safety data. *Vaccine* 29:599–612.
- Yuki, N., N. Kokubun, S. Kuwabara, Y. Sekiguchi, M. Ito, M. Odaka, et al. 2012. Guillain-Barré syndrome associated with normal or exaggerated tendon reflexes. *J. Neurol.* 259:1181–1190.
- Souayah, N., A. Nasar, M. F. Suri, and A. I. Qureshi. 2007. Guillain-Barre syndrome after vaccination in United States. A report from the CDC/FDA Vaccine Adverse Event Reporting System. *Vaccine* 25:5253–5255.
- van Sonderen, A., M. W. J. Schreurs, M. A. A. M. de Bruijn, S. Boukhrissi, M. M. Nagtzaam, E. S. Hulsenboom, et al. 2016. The relevance of VGKC positivity in the absence of LGI1 and Caspr2 antibodies. *Neurology* 86:1692–1699.
- Anadani, M., and B. Katirji. 2015. Acute-onset chronic inflammatory demyelinating polyneuropathy: an electrodiagnostic study. *Muscle Nerve* 52:900–905.
- Yuki, N., and H. P. Hartung. 2012. Guillain-Barré Syndrome. *N. Engl. J. Med.* 366:2294–2304.
- Franssen, H., and D. C. G. Straver. 2014. Pathophysiology of immune-mediated demyelinating neuropathies - Part II: neurology. *Muscle Nerve* 49:4–20.
- Benatar, M., J. Wu, and L. Peng. 2009. Reference data for commonly used sensory and motor nerve conduction studies. *Muscle Nerve* 40:772–794.

18. Derksen, A., C. Ritter, A. Parveen, B. C. Kieseier, P. Mancias, H. P. Hartung, et al. 2014. Sural sparing pattern discriminates Guillain-Barré syndrome from its mimics. *Muscle Nerve* 50:780–784.
19. Kornhuber, M. E., C. Bischoff, H. Mentrup, and B. Conrad. 1999. Multiple A-waves in Guillain-Barré syndrome. *Muscle Nerve* 22:394–399.
20. Décard, B. F., J. Fladt, H. Axer, D. Fischer, and A. Grimm. 2015. Nerve ultrasound in Miller-Fischer variant of Guillain-Barré syndrome. *Muscle Nerve* 52:1106–1110, Figure 1.
21. Kaku, D. A., J. D. England, and A. J. Sumner. 1994. Distal accentuation of conduction slowing in polyneuropathy associated with antibodies to myelin-associated glycoprotein and sulphated glucuronyl paragloboside. *Brain* 117:941–947.
22. Lupu, V. D., C. A. Mora, J. Dambrosia, J. Meer, M. Dalakas, and M. K. Floeter. 2007. Terminal latency index in neuropathy with antibodies against myelin-associated glycoproteins. *Muscle Nerve* 35:196–202.