


Early Identification of Chronic Mesenteric Ischemia with Endoscopic Duplex Ultrasound

Nathkai Safi ^{1,2}, Kim Vidar Ånonsen ³, Simen Tveten Berge ^{1,2}, Asle Wilhelm Medhus ³, Jon Otto Sundhagen ¹, Jonny Hisdal ^{1,2}, Syed Sajid Hussain Kazmi ^{1,2}

¹Department of Vascular Surgery, Division of Cardiovascular and Pulmonary Diseases, Oslo University Hospital, Ullevål, Oslo, Norway; ²Institute of Clinical Medicine, Faculty of Medicine, University of Oslo, Oslo, Norway; ³Department of Gastroenterology, Oslo University Hospital, Ullevål, Oslo, Norway

Correspondence: Syed Sajid Hussain Kazmi, Tel +47 92468309, Email sshkazmi@gmail.com

Introduction: Due to diagnostic delay, chronic mesenteric ischemia (CMI) is underdiagnosed. We assumed that the patients suspected of CMI of the atherosclerotic origin or median arcuate ligament syndrome (MALS) could be identified earlier with endoscopic duplex ultrasound (E-DUS).

Patients and Methods: Fifty CMI patients with CTA-verified stenosis of either $\geq 50\%$ and $\geq 70\%$ of celiac artery (CA) and superior mesenteric artery (SMA) were examined with E-DUS and transabdominal duplex ultrasound (TA-DUS). Peak systolic velocities (PSV) of $\geq 200\text{cm/s}$ and $\geq 275\text{cm/s}$ for CA and SMA, respectively, were compared with CTA. Subgroup analysis was performed for the patients with (n=21) and without (n=29) prior revascularization treatment of CMI. The diagnostic ability of E-DUS and TA-DUS was tested with crosstabulation analysis. Receiver operating characteristics (ROC) curve analysis was performed, and the area under the curve (AUC) was calculated to investigate the test accuracy.

Results: In the patients with $\geq 70\%$ stenosis, E-DUS had higher sensitivity than TA-DUS (91% vs 81% for CA and 100% vs 92% for SMA). AUC for SMA $\geq 70\%$ in E-DUS was 0.75 and with TA-DUS 0.68. The sensitivity of E-DUS for CTA-verified stenosis $\geq 70\%$ for CA was 100% in the patients without prior treatment. E-DUS demonstrated higher sensitivity than TA-DUS for both arteries with stenosis $\geq 50\%$ and $\geq 70\%$ in the treatment-naive patients.

Conclusion: E-DUS is equally valid as TA-DUS for the investigation of CMI patients and should be used as an initial diagnostic tool for patients suspected of CMI.

Keywords: chronic mesenteric ischemia, intestinal ischemia, acute mesenteric ischemia, duplex ultrasound, computed tomography angiography, MALS

Background

Chronic mesenteric ischemia (CMI) is a relatively rare disorder and, if left untreated, can progress to acute mesenteric ischemia (AMI), which is a life-threatening condition with high mortality rates (50–70%).¹ Asymptomatic CMI has 5-year mortality of up to 40%, and it may be even higher (86%) if all three mesenteric arteries are affected.² Atherosclerosis of the mesenteric arteries is the most common cause of CMI.^{3,4} Another cause of CMI, especially in a relatively younger population, is median arcuate ligament syndrome (MALS).⁵

The typical clinical presentation is abdominal pain with postprandial worsening resulting from persistent intestinal hypoperfusion due to insufficient blood supply during increased metabolic demand after eating.⁶ Changes in the eating pattern, ie, avoiding large meal portions, usually lead to undesirable weight loss in these patients. Other complaints may follow, such as diarrhea or constipation, nausea, vomiting, and in severe cases of ischemia, worsening abdominal pain even during exercise and activity.⁷ However, these symptoms are poorly related to CMI.^{8,9}

To date, no biomarker with sufficient sensitivity or specificity has been identified for routine clinical investigation of CMI.^{3,4} Catheter-based angiography as the gold standard of CMI investigation has been replaced by computed

tomography angiography (CTA), which has a sensitivity of 100% and a specificity of 95–100%.^{4,10,11} In case of contraindications to CTA, contrast-enhanced magnetic resonance angiography may be an alternative.^{4,11,12}

The CMI patients must be followed since the reported incidence of restenosis of the endoprosthesis is as high as 33%, and the mortality after acute occlusion of the stent be 50%.^{13–15} The guidelines recommend a transabdominal duplex ultrasound (TA-DUS) as an adjunct to the initial investigation of the patients with CMI as well as for the follow-up.^{3,4,16,17} Validation studies in the 1990s compared duplex ultrasound (DUS) flow velocities with digital subtraction angiography (DSA)-verified stenosis of the mesenteric arteries, and a wide range of cut-offs for velocities was reported and used in the different DUS criteria for significant mesenteric artery stenoses. DUS is operator-dependent, and the visualization of the mesenteric arteries can be challenging in some patients.^{13,14,18} Furthermore, it has been reported that the patients after revascularization and particularly after stenting of the mesenteric arteries, can still have persistently higher peak systolic velocity (PSV) beyond 335 cm/s despite asymptomatic angiographic stenosis of <20% of the stented superior mesenteric artery (SMA).¹⁹

Recently, endoscopic ultrasound (E-DUS) has been evaluated for the investigation of CMI.²⁰ This modality may have a role in the early diagnosis of patients with CMI since the endoscopic examination is frequently performed as an initial investigation procedure in patients with upper abdominal pain.²⁰ However, the diagnostic potential of E-DUS in patients with CMI has not yet been fully elucidated. In the present study, we investigate CMI patients with both E-DUS and TA-DUS to determine their diagnostic accuracy for celiac artery (CA) and SMA stenosis. We hypothesized that E-DUS is superior to TA-DUS in the early detection of CMI.

Patients and Methods

This study is a single-center study performed at the Department for Vascular Surgery at Oslo University Hospital. From December 2017 until December 2018, patients with postprandial abdominal pain, changes in food intake pattern, weight loss, and CTA-verified stenosis of the mesenteric arteries were prospectively included in the study. The patients were investigated with both TA-DUS and E-DUS. They were divided into Group A (treatment-naive; n = 29) and Group B (prior treatment, but with relapse or residual symptoms; n = 21). [Table 1](#) illustrates the patients' characteristics and the

Table 1 Baseline Characteristics and Comorbidities in Fifty Patients with Chronic Mesenteric Ischemia, Caused by Either Atherosclerosis or Median Arcuate Ligament Syndrome

Variables	n=50
Median age, years (IQR)	73 (58)
Gender (male: female)	24:26
Comorbidity	
Ischemic heart disease	23 (46%)
Atrial fibrillation	7 (14%)
Stroke	10 (20%)
Hypertension	24 (48%)
COPD	15 (30%)
Diabetes mellitus	8 (16%)
Smoking	40 (80%)
Median body mass index (IQR)	20 (23)
Hyperlipidemia	31 (62%)
Postprandial pain	50 (100%)
Gastroscopy prior to DUS examinations	48 (96%)
Median duration of symptoms before DUS examinations (years, IQR)	3.4 (2)
Median arcuate ligament syndrome	14 (28%)
Atherosclerosis of mesenteric arteries	36 (72%)

Abbreviations: COPD, chronic obstructive pulmonary disease; IQR, interquartile range; DUS, duplex ultrasound.

clinical presentation. The patients in Group B were previously treated for atherosclerotic changes in the mesenteric arteries in 16 cases and MALS in 5 patients. Despite prior endovascular or surgical treatment, the patients still had a symptom or had a relapse of symptoms of CMI. The investigations were performed 1–6 months after the revascularization procedures.

The patients with MALS had a $\geq 50\%$ stenosis of the CA on CTA. The CTA was taken in the deep expiration phase. The patients with atherosclerosis had CTA-verified stenosis or occlusion in either one or both, CA and SMA. CTA changes of IMA were also registered. Multi-sliced CTA (64 row-multidetector, Siemens Medical Systems; Forchheim, Germany) of the abdominal aorta and the mesenteric arteries was performed, and the scans were examined in multiple plans. A lumen diameter reduction of $\geq 50\%$ in the mesenteric arteries was considered a positive test. Grading of the stenosis in each artery was done with the following formula: % stenosis = $(1 - [\text{narrowest lumen diameter}/\text{diameter normal distal artery}]) \times 100$.²¹

Transabdominal Ultrasound

TA-DUS was performed with a GE Vivid E95 ultrasound scanner and a GE C1-6 curve array probe (GE Healthcare, Chicago, IL, USA) by the same experienced operator (JH). Conventional B-mode and color Doppler were performed to evaluate the vascular status, identifying stenosis and post-stenotic turbulence. Pulsed Doppler was used to measure peak systolic velocity (PSV) and end-diastolic velocity (EDV) of the mesenteric arteries in the inspiratory and expiratory phases. Harmonic imaging was utilized to minimize artifacts. Every effort was made to keep the insonation angle $< 60^\circ$. The patients were in the overnight fasting state, and the procedure was performed in the morning.

Endoscopic Ultrasound

E-DUS combines endoscopy and duplex ultrasound to obtain detailed images beyond the innermost lining of the digestive tract. The procedure was performed with a Hitachi Aloka ProSound F75 and an Olympus GF-UCT180 curved linear array ultrasonic videoscope (180° ultrasound field of view). All E-DUS examinations were performed by the same experienced endoscopist (KÅ) at the Endoscopy Laboratory of the Department of Gastroenterology, Oslo University Hospital. Standards for E-DUS procedure were followed.^{22,23} All patients were in at least 6 hours of fasting state before the examination. All procedures were performed under conscious sedation with midazolam (mean 3.35 mg) and alfentanil (mean 0.77 μg). SaO_2 was kept above 95% during the procedure. The patients were carefully monitored for any hemodynamic changes. The videoscope was placed in the upper part of the stomach along the lesser curvature and a longitudinal view of the aorta was obtained to identify the origin of the CA and SMA. None of the patients developed complications related to the endoscopy.

Definitions and Measurements

Our main aim was to investigate the two ultrasound modalities' ability to identify the patients with CTA-verified $\geq 50\%$ stenosis and $\geq 70\%$ stenosis of both CA and SMA in the study population. In addition, we aimed to determine if the diagnostic ability of either of the duplex ultrasound modalities was better in the patients in Group B than in Group A.

We used PSV criteria for CA ≥ 200 cm/s and SMA ≥ 275 cm/s as definitions of significant stenosis and compared these velocities with the CTA findings of $\geq 50\%$ and $\geq 70\%$ stenosis.^{16,24,25}

We compared EDV ≥ 55 cm/s in CA and ≥ 45 cm/s in SMA corresponding to CTA verified $\geq 50\%$ stenosis.²⁵ Occluded arteries identified with DUS were considered among the patients with $\geq 70\%$ stenosis.

The duplex ultrasound operators of TA-DUS and E-DUS were blinded to the CTA findings and each other's DUS findings. Only TA-DUS was performed during the follow-ups. All enrolled patients were followed-up at 3, 6, 12 months, and yearly after that.

Statistical Analysis

Continuous data are presented with median and interquartile range (IQR) and categorical data with numbers and percentages. Cross-tabulation was performed for calculation of sensitivity, specificity, positive predictive value (PPV), negative predictive value (NPV), and overall accuracy (OA) of E-DUS and TA-DUS. PSV velocities of ≥ 200 cm/s for

CA and ≥ 275 cm/s for SMA were used. Flow velocities were compared with CTA-verified stenosis $\geq 50\%$ and $\geq 70\%$ separately. Receiver operating characteristic curves (ROC) analysis was performed, and the area under the curve (AUC) was estimated. AUC was interpreted as 0.50–0.60, fail; 0.60–0.70, poor; 0.70–0.80, fair; 0.80–0.90, good; 0.90–1.0, excellent.²⁶ Data analysis was performed with IBM SPSS Statistics Version 27 (IBM Corp., USA).

Ethical Statement

The database for patients with chronic mesenteric ischemia was approved in 2016 by the Regional Committees for Medical and Health Research Ethics in the South-Eastern region of Norway (REK Sør-Øst B 2016/682). It is also registered in ClinicalTrials.org Protocol Registration and Results System (NCT02914912). The study was conducted per the Declaration of Helsinki. All patients gave informed, written consent prior to the study commencement.

Results

A total of 50 patients were included in the study period. The median age of included patients was 71 years (IQR 58), and 26 (52%) were females (Table 1). The median duration of symptoms was 3.4 years (IQR 2). All patients in the study were investigated with E-DUS; however, one of these patients died before TA-DUS, and in another three (6%), an acoustic window for a reliable measurement of flow velocities could not be obtained. Figure 1 illustrates the patient's flow.

CTA Findings

Based on CTA and clinical findings, 23 (46%) patients had CTA-verified atherosclerotic stenosis in all three mesenteric vessels. Fourteen (28%) patients had MALS with single artery stenosis of the CA. The remaining thirteen (26%) patients had atherosclerosis of CA and SMA. In total, 36 patients (66%) had CMI due to atherosclerosis in CA and SMA, and among these three patients (6%) also had MALS. Five patients (10%) had a total occlusion of CA, and SMA was occluded in eight patients (16%).

In five patients with prior laparoscopic decompression operation for MALS, CTA demonstrated between 50% and 70% stenoses. In three patients treated with the stent of the CA for atherosclerotic stenosis, two had $\geq 70\%$ stenosis on CTA, and one had $< 50\%$ stenosis. Nine patients had a stent in SMA, two had on CTA $\geq 70\%$ stenoses, six patients had stenosis between 50% and 70%, and one patient had $< 50\%$ stenosis. Two patients had stents in both mesenteric arteries, one of them had stenosis between 50% and 70% in both arteries, and the other had stenosis between 50% and 70% only in the CA, but $\geq 70\%$ SMA stenosis on the CTA. In one patient with an aortomesenteric bypass to SMA, CTA

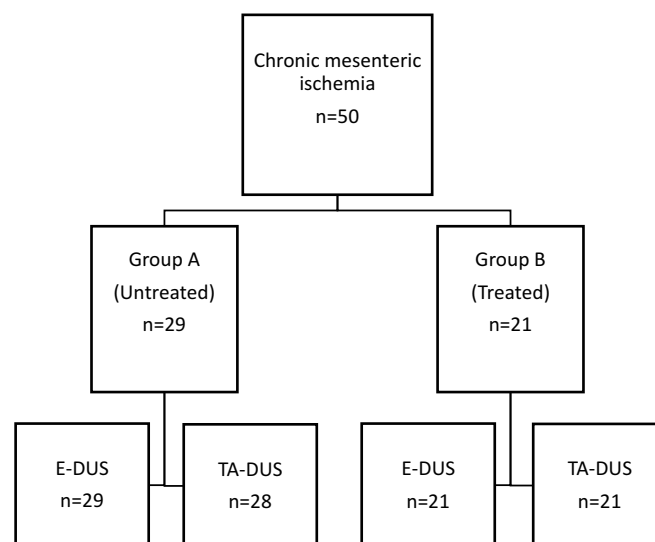


Figure 1 Patient flow in 50 patients with chronic mesenteric ischemia (CMI) investigated with transabdominal duplex ultrasound (TA-DUS), endoscopic duplex ultrasound (E-DUS) and computed tomography angiography (CTA).

Table 2 Results of the Validity Assessment of Duplex Ultrasound Determined Peak Systolic Velocities of ≥ 200 cm/s for Celiac Artery and ≥ 275 cm/s for the Superior Mesenteric Artery (SMA) for the Detection of $\geq 50\%$ and $\geq 70\%$ Computed Tomography Angiography - Verified Stenosis

		CTA $\geq 70\%$		CTA $\geq 50\%$	
		CA	SMA	CA	SMA
		PSV	PSV	PSV	PSV
		≥ 200 cm/s	≥ 275 cm/s	≥ 200 cm/s	≥ 275 cm/s
Sensitivity	E-DUS	91%	100%	78%	68%
	TA-DUS	81%	92%	57%	58%
Specificity	E-DUS	37%	75%	30%	91%
	TA-DUS	72%	88%	67%	95%
PPV	E-DUS	55%	62%	82%	90%
	TA-DUS	71%	75%	86%	93%
NPV	E-DUS	83%	100%	25%	69%
	TA-DUS	81%	97%	27%	65%
OA	E-DUS	62%	84%	68%	78%
	TA-DUS	76%	89%	57%	74%

Abbreviations: E-DUS, endoscopic duplex ultrasound; TA-DUS, transabdominal duplex ultrasound; PPV, positive predictive value; NPV, negative predictive value; CTA, computed tomography angiography; CA, celiac artery; SMA, superior mesenteric artery; PSV, peak systolic velocity; OA, overall accuracy.

demonstrated occluded SMA and $\geq 70\%$ stenosis of CA. The patient had previously unsuccessful treatment with a stent in SMA and CA before bypass operation. In another patient with bypass to the splenic artery, CTA demonstrated a stenosis grade of $\geq 70\%$ in the gastrosplenic trunk and $< 50\%$ in the SMA.

DUS Findings

The sensitivity of E-DUS for the identification of $\geq 70\%$ CTA-verified stenosis in the whole group (n=50) was higher than for TA-DUS, 91%, 95% CI 0.91 0.91 and likelihood ratio positive (LR+) 1.5 vs 81%, 95% CI 0.81 0.81 and LR+ 2.9) for CA. Sensitivity of E-DUS was 100%, 95% CI 1 1, LR+ 4.6 vs 92%, 95% CI 0.92 0.92 and LH+ 7.8 in SMA for TA-DUS.

For $\geq 50\%$ stenosis of CA, E-DUS showed a sensitivity of 78%, specificity of 30% and LH+ 1.1. Sensitivity for TA-DUS was 58%, specificity of 67% and LH+ 1.7. Whereas, for $\geq 50\%$ stenosis of SMA E-DUS had a sensitivity of 68%, specificity of 91% and LH+ 7.5. TA-DUS had sensitivity of 57%, specificity of 95% and LR+ 12. Results of cross-tabulation for the whole study population are summarized in the [Table 2](#).

E-DUS had a better NPV than TA-DUS in patients with $\geq 70\%$ stenosis for CA (83% versus 81%) and SMA (100% versus 93%) ([Table 2](#)).

In Group A, the sensitivity of E-DUS and TA-DUS for diagnosing $\geq 70\%$ stenosis of both arteries was similar ([Table 3](#)). Both ultrasound modalities had a NPV of 100% for SMA stenosis of $\geq 70\%$.

For a $\geq 50\%$ stenosis of CA, the sensitivity of E-DUS and TA-DUS was 90% and 80%, respectively. However, both modalities had similar and low specificity, NPV, and PPV values. For $\geq 50\%$ of SMA, the PPV of E-DUS and TA-DUS was 100% and 90%, respectively ([Table 3](#)).

In Group B, E-DUS had higher sensitivity than TA-DUS for both stenosis grades in both mesenteric arteries ([Table 3](#)). Also, the NPV of E-DUS was higher than for TA-DUS, particularly for a $\geq 70\%$ stenosis of SMA. NPV for both modalities were low in the patients with $\geq 50\%$ stenosis of CA ([Table 3](#)).

Selected results from the present study and similar studies are summarized in [Table 4](#). EDV did not show as high sensitivity and specificity as the PSV for identifying neither $\geq 50\%$ nor $\geq 70\%$ of the CA or SMA in both duplex ultrasound modalities.

Table 3 Results of the Validity Assessment of Peak Systolic Velocities Measured with Duplex Ultrasound (for the Detection of $\geq 50\%$ and $\geq 70\%$ CTA-Verified Stenosis in All Patients ($n=50$), Treatment-Naive Patients (Group A; $n=29$) and Patients After Treatment (Group B; $n=21$). PSV Cut-Offs: ≥ 200 cm/s for Celiac Artery and ≥ 275 cm/s for the Superior Mesenteric Artery (SMA)

		CTA $\geq 70\%$				CTA $\geq 50\%$			
		CA		SMA		CA		SMA	
		E-DUS	TA-DUS	E-DUS	TA-DUS	E-DUS	TA-DUS	E-DUS	TA-DUS
Sensitivity	Total	91%	81%	100%	92%	78%	57%	67%	56%
	Group A	100%	82%	100%	100%	90%	80%	59%	64%
	Group B	82%	80%	100%	83%	73%	64%	83%	50%
Specificity	Total	37%	72%	78%	88%	30%	67%	90%	95%
	Group A	30%	60%	86%	84%	33%	45%	100%	92%
	Group B	50%	90%	67%	93%	50%	100%	89%	100%
PPV	Total	55%	71%	62%	75%	82%	86%	90%	93%
	Group A	50%	60%	70%	70%	75%	67%	100%	90%
	Group B	64%	89%	55%	83%	79%	100%	90%	100%
NPV	Total	83%	81%	100%	97%	25%	27%	69%	65%
	Group A	100%	82%	100%	100%	60%	63%	63%	69%
	Group B	72%	82%	100%	93%	43%	55%	80%	60%
OA	Total	62%	76%	84%	89%	68%	57%	78%	74%
	Group A	59%	78%	90%	88%	72%	65%	76%	77%
	Group B	67%	85%	76%	90%	67%	75%	86%	72%

Abbreviations: E-DUS, endoscopic duplex ultrasound; TA-DUS, transabdominal duplex ultrasound; CTA, computed tomography angiography; CA, celiac artery; SMA, superior mesenteric artery; PPV, positive predictive value; NPV, negative predictive value; OA, overall accuracy.

ROC Curve Analysis

ROC curve analysis estimated AUC of 0.75 ($p = 0.001$, CI 95% 0.61 0.88) for E-DUS for a $\geq 70\%$ stenosis of the SMA, and 0.68 ($p = 0.03$, CI 95% 0.52 0.83) for TA-DUS (Figure 2A). For the PSV criterium of ≥ 275 cm/s, the sensitivity was 0.70 and the false-positive rate (1-specificity) was 0.25 for E-DUS. TA-DUS had a sensitivity of 44% and a false-positive rate of 0.23.

ROC curve analysis of E-DUS and TA-DUS for $\geq 70\%$ stenosis of the CA had an AUC of 0.79 ($p < 0.0001$, 95% CI 0.66 0.91) and 0.75 ($p = 0.001$, 95% CI 0.60 0.90), respectively (Figure 2B). For the PSV criterium of ≥ 200 cm/s with E-DUS, the sensitivity was 0.92, and the false-positive rate was 0.64. In TA-DUS, the test sensitivity was 0.72, and the false-positive rate was 0.24.

For a $\geq 50\%$ stenosis of SMA, with a PSV of ≥ 275 cm/s, ROC curve analysis of E-DUS and TA-DUS demonstrated an AUC of 0.79 ($p < 0.0001$, 95% CI 0.66 0.92) and 0.68 ($p < 0.03$, 95% CI 0.52 0.83), respectively (Figure 2C). For a PSV of 275 cm/s, E-DUS had a sensitivity of 0.65 and a false-positive rate of 0.21. In TA-DUS, AUC sensitivity was 0.44, and the false-positive rate was 0.26.

For CTA-verified $\geq 50\%$ stenosis of CA and a PSV criterium of ≥ 200 cm/s, ROC curve analysis of E-DUS and TA-DUS showed an AUC of 0.70 ($p = 0.007$, 95% CI 0.56 0.87) for the former, and 0.80 ($p < 0.0001$, 95% CI 0.64 0.97) for the latter DUS modality (Figure 2D). For E-DUS, the sensitivity was 0.80 with a false-positive rate of 0.56. In TA-DUS, AUC sensitivity was 0.52 with a false-positive rate of 0.22.

Discussion

The present study demonstrates a higher sensitivity for E-DUS than TA-DUS for identifying both $\geq 50\%$ and $\geq 70\%$ stenosis in CA and SMA. In addition, the NPV of E-DUS was better than TA-DUS in patients with $\geq 70\%$ stenosis for both CA and SMA.

Similarly, in a previous study by Noh et al, a higher E-DUS sensitivity was found for stenoses in CA or SMA than TA-DUS.²⁷ In a study by Almansa et al (2011), E-DUS had a sensitivity of 63% but a high specificity of 84% (Table 4).²⁰ In contrast to Almansa et al, our study showed a lower specificity for E-DUS than TA-DUS, particularly for CA (37% vs

Table 4 Published Results of the Validation Studies for the Peak Systolic Velocities (PSVs), End Diastolic Velocities (EDVs) and Digital Subtraction Angiography (DSA) Verified Stenosis of the Celiac Artery (CA) and the Superior Mesenteric Artery (SMA). The Results of the Validation of the Present Study in Fifty Chronic Mesenteric Ischemia Patients with CTA-Verified Stenosis of CA and SMA

		CA			SMA			CA			SMA		
		>70%	>50%	>70%	>50%	>70%	>50%	>70%	>50%	>70%	>50%	>70%	>50%
Moneta 1993		>200 cm/s		>275 cm/s									
TA-DUS	Sens	87%		92%									
	Spec	80%		96%									
	OA	82%		96%									
AbuRahma 2012		>320 cm/s	>240 cm/s	>400 cm/s	>295 cm/s	100 cm/s	40 cm/s	70 cm/s	45 cm/s				
TA-DUS	Sens	80%	87%	72%	87%	58%	84%	65%	79%				
	Spec	89%	83%	93%	89%	91%	48%	95%	79%				
Van Pettersen 2013	*	> 280 cm/s	> 268 cm/s	> 268 cm/s	> 220 cm/s	>57 cm/s	> 64 cm/s	> 101 cm/s	> 62 cm/s				
TA-DUS	Sens	66%	66%	75%	84%	83%	78%	74%	75%				
	Spec	77%	80%	86%	76%	56%	65%	96%	94%				
	§	> 272 cm/s	> 243 cm/s	> 205 cm/s	> 277 cm/s	>84 cm/s	> 83 cm/s	> 52 cm/s	> 52 cm/s				
	Sens	72%	68%	78%	68%	66%	53%	78%	76%				
	Spec	77%	71%	84%	93%	81%	81%	93%	93%				
Almansa 2011		> 200 cm/s		> 275 cm/s									
TA-DUS	Sens	80%		80%									
	Spec	78%		78%									
	NPV	97%		97%									
E-DUS	Sens	63%		63%									
	Spec	84%		84%									
	NPV	94%		94%									
Present study 2021		> 200 cm/s	> 200cm/s	> 275 cm/s	> 275 cm/s	> 55 cm/s	> 55cm/s	> 45 cm/s	> 45cm/s				
TA-DUS	Sens	81%	57%	92%	56%	65%	46%	62%	42%				
	Spec	72%	67%	88%	95%	73%	67%	85%	90%				
	NPV	81%	27%	97%	65%	73%	23%	85%	56%				
	OA	76%	57%	89%	74%	70%	50%	79%	64%				
E-DUS	Sens	91%	78%	100%	67%	55%	68%	85%	71%				
	Spec	37%	30%	78%	90%	65%	70%	51%	59%				
	NPV	83%	25%	100%	69%	56%	35%	90%	62%				
	OA	62%	68%	84%	78%	60%	68%	60%	66%				

Note: *Flow velocities during expiration; §Flow velocities during inspiration.

Abbreviations: E-DUS, endoscopic duplex ultrasound; TA-DUS, transabdominal duplex ultrasound; Sens, sensitivity; Spec, specificity; NPV, negative predictive value; OA, overall accuracy.

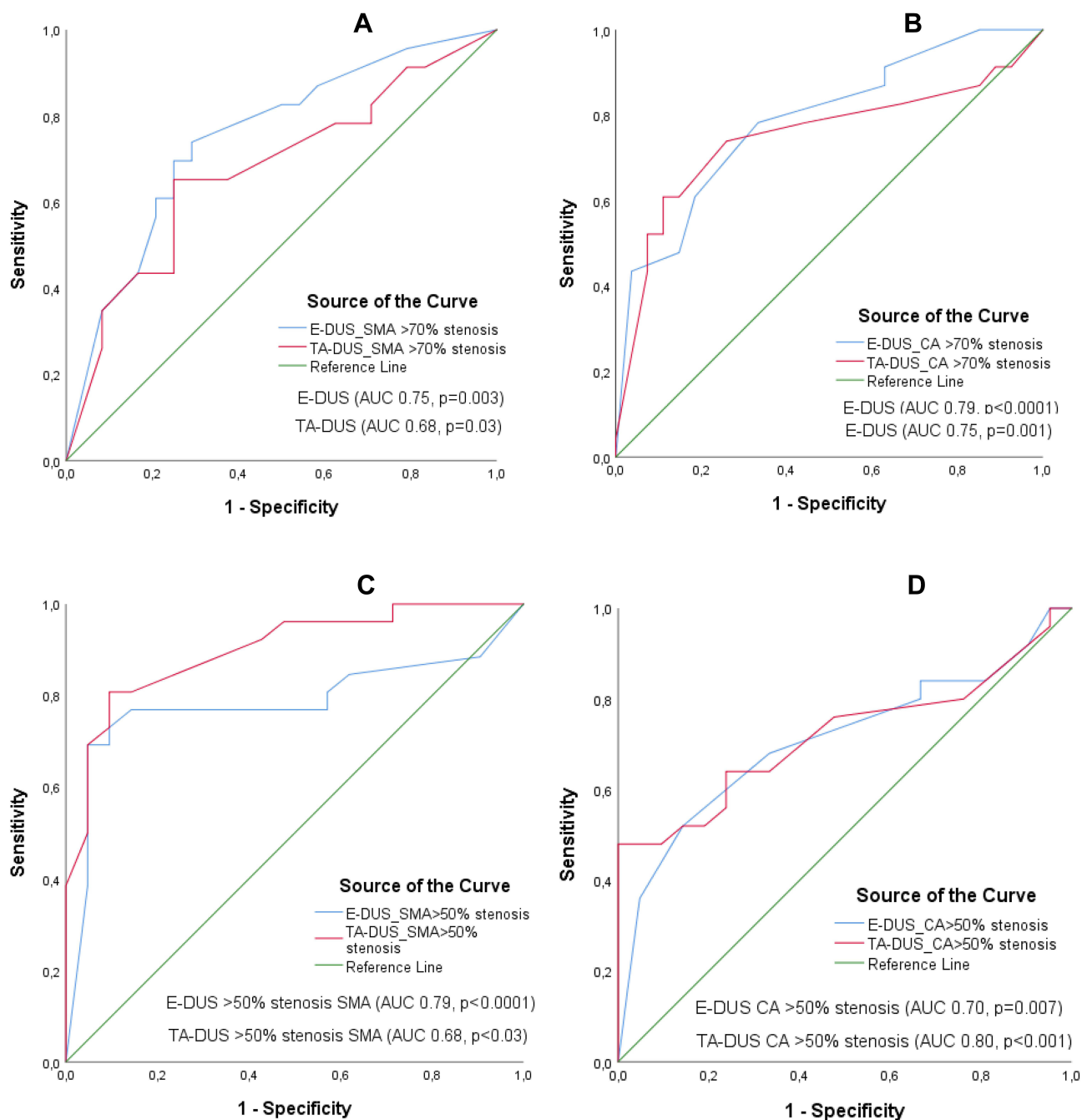


Figure 2 (A–D) ROC curve analysis of the ability of endoscopic duplex ultrasound (E-DUS) and transabdominal duplex ultrasound (TA-DUS) peak systolic velocities of ≥ 200 cm/s for celiac artery (CA) and ≥ 275 cm/s for superior mesenteric artery (SMA) to detect computed tomographic angiogram (CTA)-verified stenosis of $\geq 50\%$ and $\geq 70\%$ in fifty patients with chronic mesenteric ischemia. **(A)** Sensitivity and false-positive rate (1-specificity) in $\geq 70\%$ stenosis in SMA; **(B)** $\geq 70\%$ stenosis in CA; **(C)** $\geq 50\%$ stenosis in SMA; **(D)** $\geq 50\%$ stenosis in CA.

72%) (Table 4). However, for a CTA-verified stenosis $\geq 50\%$ for SMA, our study demonstrated excellent specificity in E-DUS and TA-DUS (90% vs 95%).

In the treatment-naïve patients (Group A) with CMI, E-DUS had excellent sensitivity (100%) and NPV (100%) for both arteries with CTA-verified stenosis $\geq 70\%$, irrespective of etiology, atherosclerosis, or MALS. Therefore, a negative E-DUS can probably exclude CMI in these patients. These findings suggest that E-DUS is an excellent initial diagnostic test for the diagnosis of CMI in patients undergoing endoscopic investigation for upper abdominal pain. Similarly, in

patients with CTA-verified $\geq 50\%$ stenosis of the CA and SMA, the sensitivity and PPV of E-DUS are better than TA-DUS.

In the patients with prior treatment (Group B), the sensitivity of E-DUS was better than for TA-DUS in both arteries and with both CTA-verified stenosis grades of $\geq 50\%$ and $\geq 70\%$. However, the specificity was insufficient (50%) for diagnosing CA stenosis of either $\geq 50\%$ or $\geq 70\%$. Although E-DUS has adequate sensitivity to diagnose the mesenteric artery stenosis in patients who underwent a prior treatment for CMI (Group B), the modality lacks specificity to exclude the healthy patients. This lack of specificity is due to type-I error and has also been observed in CMI patients after TA-DUS investigation.^{13,19} However, E-DUS has better NPV than TA-DUS exclusively in patients treated for stenosis or occlusion in the SMA.

Most CMI patients undergo gastroscopy in the initial work-up of chronic upper abdominal pain. Therefore, it may be relevant to investigate mesenteric artery stenosis with E-DUS during endoscopy in patients with CMI suspicion. Additionally, E-DUS has been presented as superior to TA-DUS in detecting other diseases of the persistent upper abdominal pain.^{28,29}

AUC of 0.79 for E-DUS was acceptable for identifying CTA-verified $\geq 50\%$ stenosis of SMA. However, in the case of TA-DUS, a lower criterion for PSV could have provided better sensitivity without increasing the false-positive rate (eg, PSV 175 cm/s, the sensitivity of 73%, and false-positive rate of 22%). E-DUS, PSV ≥ 200 cm/s, had the best combination of sensitivity and false-positive rate. In CA stenosis $\geq 50\%$, both E-DUS and TA-DUS had acceptable AUC (0.7 and 0.8, respectively), but with low specificity and high false-positive rates, particularly in E-DUS (60%).

The limitation of our study is the small size of the study population. However, compared to previously published studies on the use of E-DUS, our study population only includes patients with CTA-verified CMI. Nevertheless, the results of our study should be verified in a larger cohort of patients with CMI. In future studies, a more comprehensive range of PSVs should be investigated for their potential of correctly identifying the stenosis grades in the CA and SMA. Since CMI is an uncommon disorder, symptom debut to its diagnosis is prolonged; E-DUS can identify patients with CMI at the time of the initial endoscopic investigation.² This method can also be used to perform the transmucosal microcirculation assessment with laser Doppler flowmetry and visible light spectrometry, which may increase the probability of a correct diagnosis of CMI.⁵ Due to the limitations in the specificity of E-DUS, the patients should be further investigated with CTA for the confirmation of the CMI diagnosis.

Conclusion

E-DUS is as valid as TA-DUS for the investigation of patients with CMI. It might be of more value than TA-DUS as an initial diagnostic tool for its potential to identify CMI earlier and prevent patient suffering and even mortality.

Data Sharing Statement

Request for deidentified data sharing can be directed to the prime investigator of the study, Kazmi, SSH MD, Ph.D., syekaz@ous-hf.no.

Author Contributions

All authors made a significant contribution to the work reported, whether that is in the conception, study design, execution, acquisition of data, analysis, and interpretation, or in all these areas; took part in drafting, revising, or critically reviewing the article; gave final approval of the version to be published; have agreed on the journal to which the article has been submitted; and agreed to be accountable for all aspects of the work.

Disclosure

The authors report no conflicts of interest in this study.

References

1. Sreenarasimhaiah J. Chronic mesenteric ischemia. *Curr Treat Options Gastroenterol*. 2007;10(1):3–9. doi:10.1007/s11938-007-0051-x
2. van Bockel JH, Geelkerken RH, Wasser MN. Chronic splanchnic ischaemia. *Best Pract Res Clin Gastroenterol*. 2001;15(1):99–119. doi:10.1053/bega.2001.0158

3. Björck M, Koelmay M, Acosta S, et al. Editor's choice – management of the diseases of mesenteric arteries and veins: clinical practice guidelines of the European society of vascular surgery (esvs). *Eur J Vasc Endovasc Surg.* 2017;53(4):460–510. doi:10.1016/j.ejvs.2017.01.010
4. Terlouw LG, Moelker A, Abrahamson J, et al. European guidelines on chronic mesenteric ischaemia - joint United European gastroenterology, European Association for Gastroenterology, Endoscopy and Nutrition, European Society of Gastrointestinal and Abdominal Radiology, Netherlands association of hepatogastroenterologists, Hellenic society of gastroenterology, cardiovascular and interventional radiological society of Europe, and Dutch mesenteric ischemia study group clinical guidelines on the diagnosis and treatment of patients with chronic mesenteric ischaemia. *United Eur Gastroenterol J.* 2020;8(4):371–395. doi:10.1177/2050640620916681
5. Berge ST, Safi N, Medhus AW, et al. Gastroscopy assisted laser Doppler flowmetry and visible light spectroscopy in patients with chronic mesenteric ischemia. *Scand J Clin Lab Invest.* 2019;79(7):541–549. doi:10.1080/00365513.2019.1672084
6. Terlouw L, Verbeten M, Noord D, et al. The incidence of chronic mesenteric ischemia in the well-defined region of a Dutch mesenteric ischemia expert center. *Clin Transl Gastroenterol.* 2020;11(8):e00200. doi:10.14309/ctg.000000000000200
7. Alahdab F, Arwani R, Pasha AK, et al. A systematic review and meta-analysis of endovascular versus open surgical revascularization for chronic mesenteric ischemia. *J Vasc Surg.* 2018;67(5):1598–1605. doi:10.1016/j.jvs.2017.12.046
8. ter Steege RW, Sloterdijk HS, Geelkerken RH, Huisman AB, van der Palen J, Kolkman JJ. Splanchnic artery stenosis and abdominal complaints: clinical history is of limited value in detection of gastrointestinal ischemia. *World J Surg.* 2012;36(4):793–799. doi:10.1007/s00268-012-1485-4
9. Mensink PBF, van Petersen AS, Geelkerken RH, Otte JA, Huisman AB, Kolkman JJ. Clinical significance of splanchnic artery stenosis. *Br J Surg.* 2006;93(11):1377–1382. doi:10.1002/bjs.5481
10. Cademartiri F, Palumbo A, Maffei E, et al. Noninvasive evaluation of the celiac trunk and superior mesenteric artery with multislice ct in patients with chronic mesenteric ischaemia. *Radiol Med.* 2008;113(8):1135–1142. doi:10.1007/s11547-008-0330-1
11. Schaefer PJ, Pfarr J, Trentmann J, et al. Comparison of noninvasive imaging modalities for stenosis grading in mesenteric arteries. *Rofö.* 2013;185(07):628–634. doi:10.1055/s-0033-1335212
12. Hagspiel KD, Flors L, Hanley M, Norton PT. Computed tomography angiography and magnetic resonance angiography imaging of the mesenteric vasculature. *Tech in Vasc and Interv Radiol.* 2015;18:2–13. doi:10.1053/j.tvir.2014.12.002
13. Lundin N, Lehti L, Ekberg O, Acosta S. Validation of computed tomography angiography using mean arterial pressure gradient as a reference in stented superior mesenteric artery. *Abdom Radiol.* 2021;46(2):792–798. doi:10.1007/s00261-020-02700-6
14. Dias NV, Acosta S, Resch T, et al. Mid-term outcome of endovascular revascularization for chronic mesenteric ischaemia. *Br J Surg.* 2010;97(2):195–201. doi:10.1002/bjs.6819
15. Björnsson S, Resch T, Acosta S. Symptomatic mesenteric atherosclerotic disease—lessons learned from the diagnostic workup. *J Gastrointest Sur.* 2013;17(5):973–980. doi:10.1007/s11605-013-2139-z
16. Moneta GL, Yeager RA, Dalman R, Antonovic R, Hall LD, Porter JM. Duplex ultrasound criteria for diagnosis of splanchnic artery stenosis or occlusion. *J Vasc Surg.* 1991;14(4):511–520. doi:10.1016/0741-5214(91)90245-P
17. AbuRahma AF, Stone PA, Srivastava M, et al. Mesenteric/cealic duplex ultrasound interpretation criteria revisited. *J Vasc Surg.* 2012;55(2):428–436.e426; discussion 435–426. doi:10.1016/j.jvs.2011.08.052
18. Geelkerken RH, Delahunt TA, Schultze Kool LJ, van Baalen JM, Hermans J, van Bockel JH. Pitfalls in the diagnosis of origin stenosis of the coeliac and superior mesenteric arteries with transabdominal color duplex examination. *Ultrasound Med Biol.* 1996;22(6):695–700. doi:10.1016/0301-5629(96)00078-6
19. Soult MC, Wuamett JC, Ahanchi SS, Stout CL, Larion S, Panneton JM. Duplex ultrasound criteria for in-stent restenosis of mesenteric arteries. *J Vasc Surg.* 2016;64(5):1366–1372. doi:10.1016/j.jvs.2016.06.103
20. Almansa C, Bertani H, Noh KW, Wallace MB, Woodward TA, Raimondo M. The role of endoscopic ultrasound in the evaluation of chronic mesenteric ischaemia. *Dig Liver Dis.* 2011;43(6):470–474. doi:10.1016/j.dld.2011.01.003
21. Ota H, Takase K, Rikimaru H, et al. Quantitative vascular measurements in arterial occlusive disease. *Radiographics.* 2005;25(5):1141–1158. doi:10.1148/rg.255055014
22. Sharma M, Rai P, Mehta V, Rameshbabu C. Techniques of imaging of the aorta and its first order branches by endoscopic ultrasound (with videos). *Endosc Ultrasound.* 2015;4(2):98–108. doi:10.4103/2303-9027.156722
23. Kim JY, Shin MS, Lee S. Endoscopic features for early decision to evaluate superior mesenteric artery syndrome in children. *BMC Pediatr.* 2021;21(1):392. doi:10.1186/s12887-021-02848-0
24. Mitchell EL, Moneta GL. Mesenteric duplex scanning. *Perspect Vasc Surg Endovasc Ther.* 2006;18(2):175–183. doi:10.1177/1531003506291885
25. Zwolak RM, Fillinger MF, Walsh DB, et al. Mesenteric and celiac duplex scanning: a validation study. *J Vasc Surg.* 1998;27(6):1078–1088. doi:10.1016/S0741-5214(98)60010-0
26. Hosmer DW, Lemeshow S. Area under the ROC curve. *Appl Logist Regres.* 2000;160:164.
27. Noh KW, Pungpaong S, Wallace MB, et al. Is eus with Doppler comparable to transabdominal ultrasound as a screening test for chronic mesenteric ischemia (cmi)? *Endoscopy.* 2006;39(S 1):FR12. doi:10.1055/s-2006-947751
28. Chang KJ, Chak A, Lightdale C, et al. Endoscopic ultrasound (eus) compared with endoscopy and transabdominal ultrasound (tus) in the work-up of patients with upper abdominal pain (uap): a prospective multi-center cohort study. *Gastrointest Endosc.* 2004;59(5):P233. doi:10.1016/S0016-5107(04)01050-8
29. Thompson MB, Ramirez JC, De La Rosa LM, et al. Endoscopic ultrasound in the evaluation of chronic upper abdominal pain of unknown etiology: a retrospective chart review examining the efficacy of eus in determining a new diagnosis. *J Clin Gastroenterol.* 2015;49(2):e17–20. doi:10.1097/MCG.0000000000000174

Vascular Health and Risk Management

Dovepress

Publish your work in this journal

Vascular Health and Risk Management is an international, peer-reviewed journal of therapeutics and risk management, focusing on concise rapid reporting of clinical studies on the processes involved in the maintenance of vascular health; the monitoring, prevention and treatment of vascular disease and its sequelae; and the involvement of metabolic disorders, particularly diabetes. This journal is indexed on PubMed Central and MedLine. The manuscript management system is completely online and includes a very quick and fair peer-review system, which is all easy to use. Visit <http://www.dovepress.com/testimonials.php> to read real quotes from published authors.

Submit your manuscript here: <https://www.dovepress.com/vascular-health-and-risk-management-journal>