



Primary diagnosis of pulmonary embolism with unenhanced MRI for patients not eligible for CTPA: Clinical outcome

Koshiar Medson^{a,b,*}, Roberto Vargas-Paris^{a,c}, Anna Nordgren-Rogberg^{a,b}, Audur Sigbergdottir^d, Sven Nyrén^{b,e}, Peter Lindholm^{a,b}

^a Department of Physiology and Pharmacology, Karolinska Institutet, SE-171 77 Stockholm, Sweden

^b Thoracic radiology, Imaging and Physiology, Karolinska University Hospital, SE-171 76 Stockholm, Sweden

^c Abdominal Radiology, Imaging and Physiology, Karolinska University Hospital, SE-171 76 Stockholm, Sweden

^d Södersjukhuset, Stockholm, Sweden

^e Department of Molecular Medicine and Surgery, Karolinska Institutet, Karolinska University Hospital, Solna (L1:00), SE-171 76 Stockholm, Sweden

ARTICLE INFO

Keywords:

Pulmonary embolism
MRI
Thoracic imaging

ABSTRACT

Purpose: To follow up the clinical outcome of patients with suspected pulmonary embolism (PE), in those only imaged using unenhanced, free-breathing magnetic resonance imaging (MRI).

Methods and materials: Fifty-seven patients aged 29–99 years (mean 70, SD 18) that could not undergo Computed Tomography Pulmonary Angiography (CTPA) were offered alternative imaging diagnostics in parallel with ongoing methodological studies validating MRI vs CTPA. Contraindications included renal failure (n = 44), severe iodine contrast allergy (n = 10), pregnancy (n = 2) and radioactive iodine therapy (n = 1). The unenhanced MRI protocol was based on free-breathing, steady-state free precession with no cardiac or respiratory gating. Retrospective review of the electronic medical record (EMR) was made of 0–12 months post-imaging and was collected during 2012–2018.

Results: All 57 MRIs were of diagnostic quality and 12 pulmonary embolisms were diagnosed. Of the 57 patients, 44 were already on, or had started anticoagulation therapy due to clinical suspicion of PE. Four of the patients were put on anticoagulation after the positive MRI and 13 were taken off anticoagulation after a negative MRI report. Other diagnoses reported (considering dyspnea) were pleural effusion (n = 24), consolidation (n = 12) and pericardial effusion (n = 2). One patient had a deep vein thrombosis (DVT) within three months of our negative MRI result and then had a stroke within one year. Another patient suffered a stroke within three months of being diagnosed (by MRI) with PE and given anticoagulation as treatment.

Conclusions: Our method supported or altered clinical decision-making and treatment in this cohort. A diagnostic tool for PE without intravenous contrast agent or radiation is of great benefit for certain patients.

1. Introduction

Pulmonary embolism (PE) is a severe medical condition and one of the most common causes of death within the range of cardiovascular diseases with an incidence of 1–2 per 1000 inhabitants in Europe and USA. Due to its nonspecific signs and symptoms, it is commonly under- or misdiagnosed clinically [1–6]. The imaging method of choice for diagnosing this condition at present is computed tomography pulmonary angiography (CTPA), due to its high sensitivity and specificity, it being readily available and having a short acquisition time [3,5,7]. However, it does have drawbacks, the most important being the use of iodinated contrast material and ionizing radiation, giving contrast material allergy, renal insufficiency and pregnancy relative

contraindications [4,6,8]. It is estimated that about 25% of patients with suspected pulmonary embolism have contraindications for this diagnostic method [9].

Concerning the iodinated contrast material, there are two main issues, one being severe contrast allergy and the other and more critical, being CIN (contrast medium-induced nephropathy). There is an ongoing debate about the impact of iodinated contrast material on kidney function and the causes of CIN. Although evidence points to a multifactorial cause, the recommendations for the use of contrast medium are quite clear and based on defined risk factors and the Glomerular Filtration Rate (GFR) of the patient [10–14].

In terms of radiation, the number of CTPA and CT examinations performed in general has been increasing over the past number of years

* Corresponding author at: FO Thoraxradiologi, B5:11, Karolinska University Hospital, SE-171 76 Stockholm, Sweden.

E-mail address: koshiar.medson@ki.se (K. Medson).

<https://doi.org/10.1016/j.ejro.2019.08.004>

Received 18 July 2019; Received in revised form 15 August 2019; Accepted 16 August 2019

Available online 03 October 2019

2352-0477/© 2019 The Authors. Published by Elsevier Ltd. This is an open access article under the CC BY-NC-ND license

(<http://creativecommons.org/licenses/by-nc-nd/4.0/>).

[15]. With the increasing number of examinations, the amount of ionizing radiation that the population is exposed to has also increased and so there is concern over the amount of radiation exposure used in medical imaging, particularly in young patients [16]. We have data suggesting that the cumulative doses of about 50–60 mGy might triple the risk of leukemia and brain cancer in children [17]. There is also a concern in exposing young female patients to radiation, due to the high sensitivity of their breast tissue [16,18].

Previous studies have shown that MRI has lower efficacy than CTPA, especially regarding subsegmental emboli [6,19–22]. Advances in the technological aspects of CTPA has made it possible to see very small subsegmental emboli. This has led to a considerable increase in the number of pulmonary embolisms being diagnosed, but without a corresponding decrease in mortality due to this condition [23–26]. There are still questions to the clinical significance and benefit in finding or treating these subsegmental emboli with anticoagulation. On the one hand, we have the proposed increased risk for future VTE and development of Chronic Thromboembolic Pulmonary Hypertension (CTEPH) and on the other hand the risk of bleeding complications that is estimated to be as high as 8% [23,24,27–30]. Moreover, there is also some reader disagreement in CT angiographies, which is estimated to be at 30–37% in different studies [28].

Different MRI protocols, both with and without the use of contrast agents, have been used for diagnosis of pulmonary embolism with varying results. Oudekerk et al. showed a specificity of 95% and a sensitivity of 77% for segmental (and larger vessels) emboli. Kalb et al. showed similar results with a specificity of 100% and a sensitivity of 67% for respiratory triggered SSFP. PLOPED III demonstrated 78% sensitivity and 99% specificity on technically adequate angiographies. Our study is based on the protocol introduced by Nyren et al. and showed a specificity of 100% and sensitivity of 90–93% with the inter-reader agreement of 0.97 [36].

The purpose of this retrospective study was to determine the clinical outcome of patients with suspected pulmonary embolism (PE) that could not undergo CTPA and thereby the effectiveness of this diagnostic method that is an unenhanced, free-breathing MRI protocol.

2. Methods and materials

The study was performed according to the Declaration of Helsinki and approved by the local Ethics Committee.

We reviewed the electronic medical record (EMR) of all patients at Karolinska University Hospital between Feb 2012 and April 2018 that could not undergo CTA due to renal failure, severe contrast allergy, pregnancy or radioactive iodine therapy and that were offered an alternative at our teaching hospital in parallel with ongoing methodological studies validating MRI vs CTPA. EMR review was performed to determine the following:

- 1 Diagnostic-quality of the examination
- 2 PE
- 3 Other findings than PE
- 4 The outcome in the form of a review of EMR at three months and one-year post-imaging for any VTE (Venous Thromboembolism, DVT and PE).

There was no restriction for patient recruitment other than contraindication for MRI.

Only a few of physicians in our teaching hospital who, having been informed about this ongoing project, referred patients to us when there were no other diagnostic options available. This diagnostic method was (is) not yet a standard method and this goes some way to explain the low number of patients referred to us and included. Two attending radiologists reviewed all exams in line with our institution's standard protocol. No changes were made to preliminary result after the second read. This study did not include any additional readings of the data,

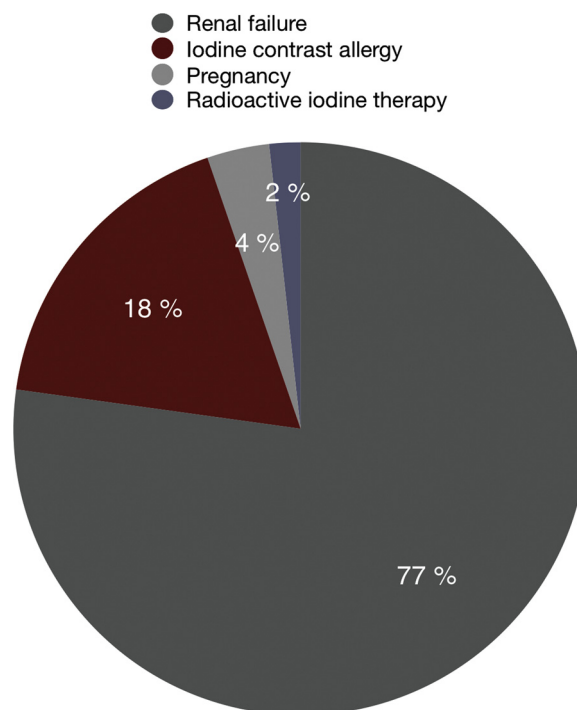


Fig. 1. Reasons for not being eligible for CTPA.

only a review of EMR. The criteria for a false negative were any occurrence of VTE (Venous Thromboembolism, DVT and PE) in the year following a negative MRI examination result [31].

The study cohort consisted of a total of 57 patients, with all having a one year follow up (100%). There were 27 females (47%) and 30 males (53%), age 29–99 years with a mean age of 70 (SD = 18). The examination was made due to renal failure in 44 cases (77%), severe iodine contrast allergy in 10 cases (17%), pregnancy in two (4%) and radioactive iodine therapy in one case (2%). (Fig. 1, Reasons for not being eligible for CTPA).

Thirty-one of our patients were already on anticoagulation due to other reasons than suspected PE. Reasons being dialysis ($n = 5$), atrial fibrillation ($n = 10$), recent surgery ($n = 4$), other reasons like NSTEMI and prior PE etc. ($n = 12$). Additionally, 13 patients were put on anticoagulation due to clinical suspicion of PE before the MRI examination. Subsequently, a total of 77 per cent (44/57) were on anticoagulation therapy at the time of MRI examination.

(Fig. 2, number of patients on anticoagulation at the time of MRI examination).

The MRI protocol used has been published previously in a study comparing the technique to CTPA by Nyren et al. [36]; “Patients were placed (supine, head-first) in a 1.5 T MRI scanner (Magnetom Aera, Siemens Medical Systems, Erlangen, Germany). A dorsal 32-element spine matrix coil integrated into the table and a ventral 18-element body matrix coil was used. The MRI protocol was based on a 2D free-breathing steady-state free precession (SSFP) sequences, without use of an intravenous contrast agent, respiratory, or electrocardiographic gating. The patients received no specific breathing instructions. Parameters: flip angle, 70°; field of view, 450 mm; matrix size, 256 × 256; voxel size, 0.9 × 0.9 × 4.5 mm; TE, 1.23–1.26 ms; TR, 2.8 ms; slice thickness, 4.5 mm; overlap, –2.7 mm (60%); acquisition time, 9 min 34 s.

Acquisition time in each plane were: axial, 3 min 50 s; sagittal and coronal, 2 min 52 s each. Five slices were obtained in each anatomical position in three orthogonal planes, generating stacks of approximately 500 images in each plane (axial, 600; sagittal, 450; and coronal, 450). The 1500 images were sorted by position, generating stacks with multiple images in various phases of the breathing and cardiac cycle.

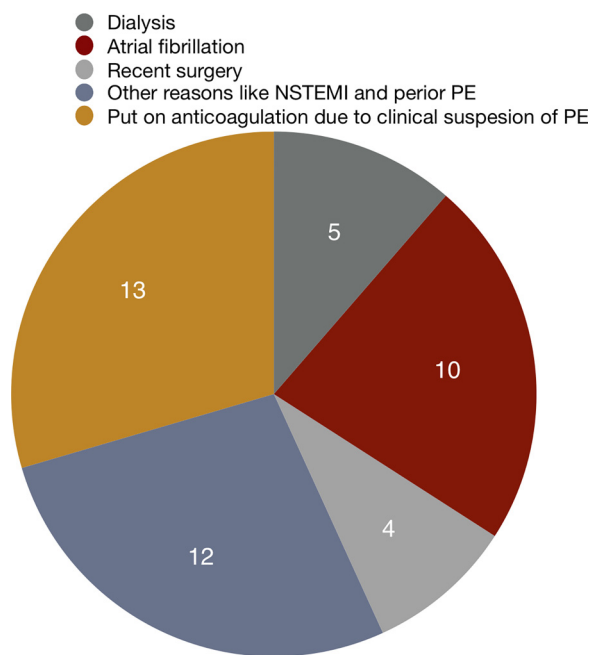


Fig. 2. Number of patients on anticoagulation at the time of MRI examination.

Pulmonary embolism was confirmed if one or more vascular signs were present: a complete filling defect, a partial filling defect and/or freely floating thromboembolic masses in the vessel. Additional findings were noted, such as signs of pleural or pericardial effusion, consolidation, malignancy.”

We used the clinical outcome of the patients to determine the effectiveness of this diagnostic method as we did not have any reference standard [31–33]. Any VTE (Venous Thromboembolism, DVT and PE) during the one-year follow-up on a negative MRI result was considered as a false negative. We considered a positive MRI result for PE to be a true positive, while a negative MRI and no VTE during the follow-up period was considered true negative. False positive cannot be distinguished since we do not have any reference standard.

All the statistical analysis was calculated with MedCalc on-line statistical software and Microsoft Excel.

3. Results

A retrospective review was done for our cohort of patients who underwent MRI instead of CTPA due to renal failure, contrast agent allergy, pregnancy or radioactive iodine therapy between 2012 and 2018 at Karolinska University Hospital in Stockholm.

All the examinations were of diagnostic quality. We had a total of 12 positive PE cases according to MRI results. Four of these cases were put on anticoagulation after a positive exam report. There were also 13 who were put on anticoagulation due to clinical suspensions which were taken off anticoagulation after a negative exam report.

(Fig. 3, Patient flow and results in our study)

A number of other diagnoses were also reported regarding dyspnea. These reports included pleural effusion ($n = 24$), consolidation ($n = 12$) and pericardial effusion ($n = 2$).

There was one DVT case within three months following a negative MRI result, and the same patient had a stroke within one year. There was also one case of stroke within three months in a patient with a positive MRI result for PE, who was put on anticoagulation after the result. Within our study population, eight patients died within three months, and six died within one year due to reasons other than VTE (Venous Thromboembolism, DVT and PE) according to EMR. Using the VTE as a possible case of false-negative etc, the above-mentioned results give the following statistical data: Sensitivity of 92.31% (95% CI,

63.97–99.81), specificity of 100% (95% CI, 91.96–100), PPV of 100%, NPV of 97.78% (95% CI, 87–99.66).

Few examples of the cases where our method supported or altered clinical decision and/or treatment. Each example contains two MP4 movies in axial and coronal planes. These clips are 20 s each and cover areas of interest.

3.1. Patient 1

71-year-old male not eligible for CTPA due to renal failure. Positive MRI for saddle emboli.

Other diagnosis reported included, a small amount of pulmonary effusion and dilatation of the pulmonary trunk (Movie 1 & 2).

3.2. Patient 2

75-year-old female not eligible for CTPA due to severe allergy.

Negative MRI for pulmonary emboli. She was put on anticoagulation due to clinical suspicion of PE. Anticoagulation was stopped after the negative MRI result.

Other diagnosis reported included a large amount of pulmonary effusion and consolidation bilaterally (Movie 3 & 4).

3.3. Patient 3

78-year-old male not eligible for CTPA due to renal failure.

Positive MRI for pulmonary emboli in the proximal left lower lobe artery.

He was put on anticoagulation due to a positive MRI result.

Other diagnosis reported included a small amount of left-sided pulmonary effusion and parenchymal changes in the right lower lobe of chronic/fibrotic character (Movie 5 & 6).

3.4. Patient 4

82-year-old female not eligible for CTPA due to renal failure.

Negative MRI for pulmonary emboli. She was put on anticoagulation due to clinical suspicion of PE. Anticoagulation was stopped after the negative MRI result.

Other diagnosis reported included right middle lobe atelectasis (Movie 7 & 8).

3.5. Patient 5

51-year-old male not eligible for CTPA due to severe contrast allergy.

Positive MRI for emboli in the lower right lobe artery. He was put on anticoagulation after the positive MRI result.

Other diagnosis reported included a small amount of bilateral pleural effusion and small pulmonary infarct in the left lower lobe (Movie 9 & 10).

4. Discussion

Magnetic resonance imaging is continuously evolving but has still not gained full validation as an alternative imaging method in patients with suspected pulmonary embolism and with relative contraindications to CTPA [34,35]. Nyrén et al. have designed a short MRI protocol (10 min) with high sensitivity and specificity. The unenhanced MRI protocol is based on free-breathing, steady-state free precession with no cardiac or respiratory gating [36]. The goal is to use MRI as a first-line imaging method in the clinical setting in the management of patients with relative contraindications to CTPA, as described earlier.

In this study, we used the clinical outcome to measure the effectiveness of the MRI examination, as we did not have any reference method of evaluation. In that regard, the results look very promising, as

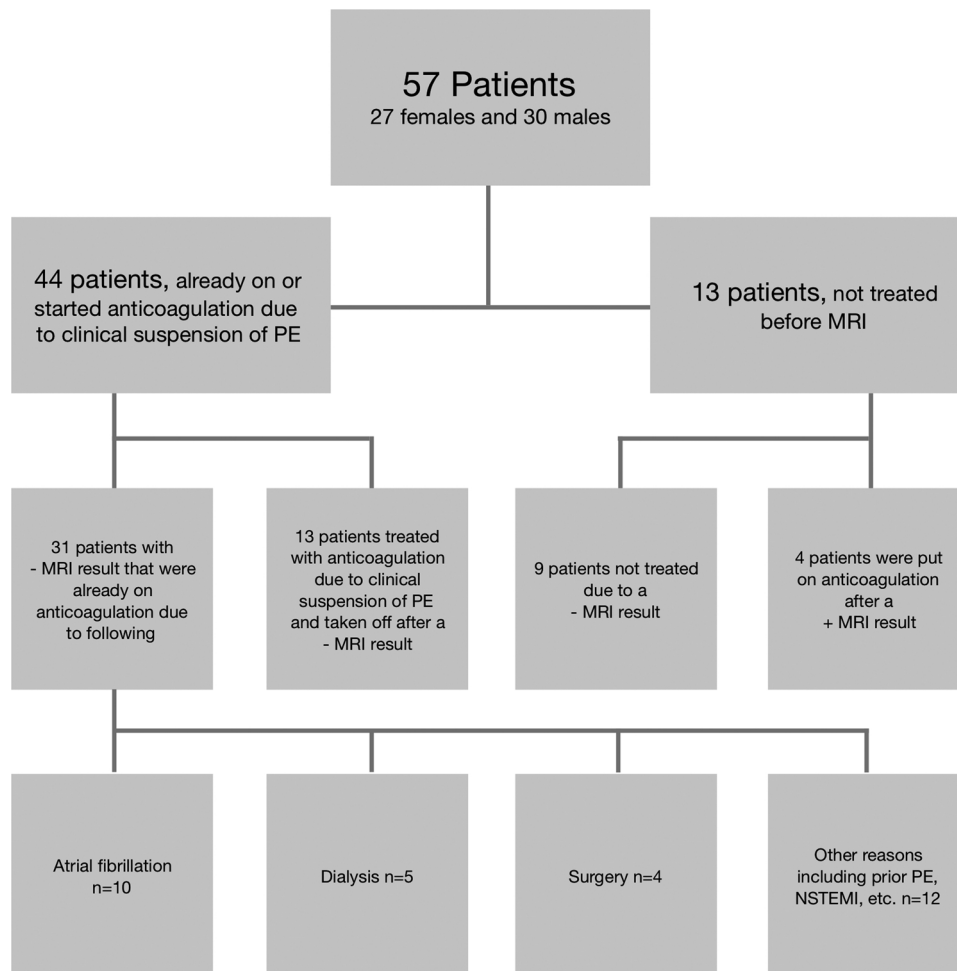


Fig. 3. Patient flow and results in our study.

only one possibly false negative was observed from a total of 57 examinations. The results also altered the course of treatment in four cases, who were put on anticoagulants due to a positive MRI result and 13 who were taken off anticoagulants due to a negative MRI result. Moreover, a total of thirty-eight other thoracic findings or diagnosis with consideration to dyspnea were also reported, where some were previously unknown, and others were supporting a previously known condition. This demonstrates that our MRI protocol can help in diagnosing PE as well as other conditions.

This has also been the case in other studies where coincidental findings such as aortic dissection and hemothorax have been diagnosed and reported [22,37]. Another advantage with MRI is that after ruling out PE, an extensive cardiac MRI or venography of the legs can be added to the examination for an extended diagnostics [34].

One of the main issues with MRI in the diagnosis of PE as shown by PIOPED III is the number of technically inadequate images, so the suggestion was that the examination should be performed only in trained centers [19]. We had no technically inadequate images in our study, nor did Nyrén et al., who used the same protocol in their preliminary study [36]. Thus, it can be concluded that our protocol is simple for the patients as no breath-holding or other instructions need to be followed, easily applied by the radiographers as no cardiac or respiratory gating is needed and also easy for readers.

Magnetic resonance imaging technology is rapidly evolving, and over the past decades has improved significantly with a faster acquisition, larger coverage and faster reconstruction. Increasingly, more studies show that MRI is a reliable imaging modality in diagnosing acute pulmonary embolism with the advantage being that there is no

ionizing radiation or use of iodinated contrast agent, not to mention that specific sequences can be performed without breath holding. Therefore, MRI may provide a safer alternative to CT angiography in diagnosing PE in patients with relative contraindications to CTPA.

Our method supported or altered clinical decision and treatment in this cohort. We conclude that our short, easily applied protocol can help in the management of patients who have difficulty with breath-holding and in particular, in those with contraindications to CT angiography; however, because of the small size of this study, further clinical validation is required.

5. Limitations

There are several limiting factors in this study where some of them are already mentioned. Here we will address only two of these that we think are the most important ones.

First, is the number of patients included in this study. Reason for this being that only a few physicians in our teaching hospital were informed about this ongoing project and the method was only used when there were no other diagnostic options available. Selection bias must also be mentioned here since most of our patients were elderly with a mean age of 70 (SD 18) and ill with multiple disorders.

Equally important is the fact that there was no other diagnostic method for comparison to the MRI results. Although using clinical outcome has been used in many studies before, having a gold standard as a reference would have made the results more robust and the statistics more reliable.

Declaration of Competing Interest

The authors declare that there is no conflict of interest.

Acknowledgements

This work was supported by the Swedish Heart and Lung Foundation, the Swedish Society of Medicine and Stockholm City Council.

Appendix A. Supplementary data

Supplementary material related to this article can be found, in the online version, at doi:<https://doi.org/10.1016/j.ejro.2019.08.004>.

References

- [1] D. Morrone, V. Morrone, Acute pulmonary embolism: focus on the clinical picture, *Korean Circ. J.* 48 (5) (2018) 365–381.
- [2] M.V. Huisman, et al., Pulmonary embolism.
- [3] S.Z. Goldhaber, H. Bounameaux, Pulmonary embolism and deep vein thrombosis, *Lancet* (London, England) 379 (9828) (2012) 1835–1846.
- [4] B. Hochegger, et al., Magnetic resonance imaging findings in acute pulmonary embolism, *Br. J. Radiol.* 84 (999) (2011) 282–287.
- [5] H. Bounameaux, A. Perrier, M. Righini, Diagnosis of venous thromboembolism: an update, *Vasc. Med. (Lond., Engl.)* 15 (5) (2010) 399–406.
- [6] B. Kalb, et al., MR imaging of pulmonary embolism: diagnostic accuracy of contrast-enhanced 3D MR pulmonary angiography, contrast-enhanced low-flip angle 3D GRE, and nonenhanced free-induction FISP sequences, *Radiology* 263 (1) (2012) 271–278.
- [7] A. Kluge, et al., Experience in 207 combined MRI examinations for acute pulmonary embolism and deep vein thrombosis, *AJR Am. J. Roentgenol.* 186 (6) (2006) 1686–1696.
- [8] M. Zhou, et al., Diagnostic performance of magnetic resonance imaging for acute pulmonary embolism: a systematic review and meta-analysis, *J. Thromb. Haemost.: JTH* 13 (9) (2015) 1623–1634.
- [9] P.D. Stein, et al., Multidetector computed tomography for acute pulmonary embolism, *N. Engl. J. Med.* 354 (22) (2006) 2317–2327.
- [10] U. Nyman, et al., Preventing contrast medium-induced acute kidney injury: side-by-side comparison of Swedish-ESUR guidelines, *Eur. Radiol.* 28 (12) (2018) 5384–5395.
- [11] P. Aspelin, et al., Nephrotoxic effects in high-risk patients undergoing angiography, *N. Engl. J. Med.* 348 (6) (2003) 491–499.
- [12] J.S. Hinson, et al., Risk of acute kidney injury after intravenous contrast media administration, *Ann. Emerg. Med.* 69 (5) (2017) p. 577–586 e4.
- [13] Swedish Society of Uroradiology, National Guidelines Iodine Contrast Media v.6.0, Available via <http://www.sfmr.se/sidor/kontrastmedelsrekommendationer/>. (Accessed 5 July 2018) (2017).
- [14] American College of Radiology, ACR Manual on Contrast Media. Version 10.3/2017, Available via <https://www.acr.org/Clinical-Resources/Contrast-Manual>. (Accessed 5 July 2018) (2017).
- [15] D.J. Brenner, E.J. Hall, Computed tomography—an increasing source of radiation exposure, *N. Engl. J. Med.* 357 (22) (2007) 2277–2284.
- [16] A.J. Einstein, M.J. Henzlova, S. Rajagopalan, Estimating risk of cancer associated with radiation exposure from 64-slice computed tomography coronary angiography, *JAMA* 298 (3) (2007) 317–323.
- [17] M.S. Pearce, et al., Radiation exposure from CT scans in childhood and subsequent risk of leukaemia and brain tumours: a retrospective cohort study, *Lancet* 380 (9840) (2012) 499–505.
- [18] X. Li, et al., Patient-specific radiation dose and cancer risk for pediatric chest CT, *Radiology* 259 (3) (2011) 862–874.
- [19] P.D. Stein, et al., Gadolinium-enhanced magnetic resonance angiography for pulmonary embolism: a multicenter prospective study (PIOPED III), *Ann. Intern. Med.* 152 (7) (2010) 434–443 W142-3.
- [20] M. Revel, et al., Diagnostic accuracy of magnetic resonance imaging for an acute pulmonary embolism: results of the ‘IRM-EP’ study, *J. Thromb. Haemost.* 10 (5) (2012) 743–750.
- [21] M. Oudkerk, et al., Comparison of contrast-enhanced magnetic resonance angiography and conventional pulmonary angiography for the diagnosis of pulmonary embolism: a prospective study, *Lancet* 359 (9318) (2002) 1643–1647.
- [22] A. Kluge, W. Luboldt, G. Bachmann, Acute pulmonary embolism to the subsegmental level: diagnostic accuracy of three MRI techniques compared with 16-MDCT, *Am. J. Roentgenol.* 187 (1) (2006) W7–W14.
- [23] R.S. Wiener, L.M. Schwartz, Steven Woloshin, Time trends in pulmonary embolism in the United States: evidence of overdiagnosis, *Arch. Intern. Med.* 171 (9) (2011) 831–837.
- [24] J.J.J. Glassroth, Imaging of pulmonary embolism: too much of a good thing? *JAMA* 298 (23) (2007) 2788–2789.
- [25] A.J. Burge, et al., Increased diagnosis of pulmonary embolism without a corresponding decline in mortality during the CT era, *Clin. Radiol.* 63 (4) (2008) 381–386.
- [26] A. Qaseem, et al., Appropriate use of screening and diagnostic tests to foster high-value, cost-conscious care, *Ann. Intern. Med.* 156 (2) (2012) 147–149.
- [27] S. Clemens, K.V. Leeper, Newer modalities for detection of pulmonary emboli, *Am. J. Med.* 120 (10 Suppl. 2) (2007) S2–12.
- [28] M. Righini, et al., Age-adjusted D-dimer cutoff levels to rule out pulmonary embolism: the ADJUST-PE study, *JAMA* 311 (11) (2014) 1117–1124.
- [29] P.D. Stein, et al., Diagnosis and management of isolated subsegmental pulmonary embolism: review and assessment of the options, *Clin. Appl. Thromb. Hemost.* 18 (1) (2012) 20–26.
- [30] E.J. van Beek, et al., The clinical course of patients with suspected pulmonary embolism, *Arch. Intern. Med.* 157 (22) (1997) 2593–2598.
- [31] M.L. Schiebler, et al., Effectiveness of MR angiography for the primary diagnosis of acute pulmonary embolism: clinical outcomes at 3 months and 1 year, *J. Magn. Reson. Imaging* 38 (4) (2013) 914–925.
- [32] P.S. Douglas, et al., Outcomes research in cardiovascular imaging: report of a workshop sponsored by the National Heart, Lung, and Blood Institute, *JACC Cardiovasc. Imaging* 2 (7) (2009) 897–907.
- [33] I. Tillie-Leblond, et al., Risk of pulmonary embolism after a negative spiral CT angiogram in patients with pulmonary disease: 1-year clinical follow-up study, *Radiology* 223 (2) (2002) 461–467.
- [34] M.P. Revel, et al., Diagnostic accuracy of unenhanced, contrast-enhanced perfusion and angiographic MRI sequences for pulmonary embolism diagnosis: results of independent sequence readings, *Eur. Radiol.* 23 (9) (2013) 2374–2382.
- [35] B.L. Davidson, M.J. Lacrampe, Why can’t magnetic resonance imaging reliably diagnose pulmonary embolism? *Ann. Intern. Med.* 152 (7) (2010) 467–468.
- [36] S. Nyren, et al., Detection of pulmonary embolism using repeated MRI acquisitions without respiratory gating: a preliminary study, *Acta Radiol.* 58 (3) (2017) 272–278.
- [37] A. Kluge, et al., Pulmonary perfusion in acute pulmonary embolism: agreement of MRI and SPECT for lobar, segmental and subsegmental perfusion defects, *Acta Radiol.* 47 (9) (2006) 933–940.