

## Amyopathic dermatomyositis with diffuse lung disease

Sumeera Bandi<sup>1</sup>, Vidushi Jain<sup>2</sup>, Ashish K. Jaiswal<sup>3</sup>

<sup>1</sup>Department of Pulmonary Medicine, HIMSR, Delhi, <sup>2</sup>Department of Dermatology, Dermalinks, Ghaziabad, Uttar Pradesh,

<sup>3</sup>Department of Pulmonary Medicine NIIMS, Greater Noida, Uttar Pradesh, India

### ABSTRACT

A 38-year-old woman presented with progressively increasing breathlessness, recurrent productive cough, and intermittent fever of 1 year duration. Examination revealed cutaneous eruptions on the dorsal aspects of the hands and on face. Histopathologic features of skin biopsy revealed acanthosis, hyperkeratosis with focal vacuolar alteration of the basal-cell layer, and perivascular inflammatory infiltrates in upper dermis. CT scan showed diffuse lung disease and pulmonary function tests showed severe restrictive lung disease. There was no muscular involvement clinically or on electromyography and magnetic resonance imaging. She was diagnosed as a case of amyopathic dermatomyositis with diffuse lung disease and managed with topical and systemic steroid and topical sunscreen with fairly good response.

**Keywords:** Cutaneous lesions, dermatomyositis, lung disease

### Introduction

Dermatomyositis (DM) is a relatively rare autoimmune connective tissue disease with distinctive cutaneous lesions and symmetric proximal inflammatory myopathy. The term polymyositis (PM) is used for cases having characteristic inflammatory myopathy in absence of cutaneous involvement. Very rarely, characteristic cutaneous lesions of DM occur without muscle disease when it is called amyopathic DM or DM sine myositis. DM can affect other organ systems including lungs. Diffuse lung disease occurs in 15–32% of patients.<sup>[1-3]</sup> Recently, we came across an interesting case of DM with characteristic skin lesions and progressively increasing lung disease without myopathy which is being reported.

### Case Summary

A 38-year-old female presented to the Pulmonology department with complaints of progressive shortness of

breath of 1 year duration. She also gave history of intermittent low grade fever and bouts of productive cough in between. For these she took treatment on several occasions with slight improvement. General physical examination revealed reddish skin rashes on face and hands. Systemic examination of chest, abdomen, cardiovascular, neurological, and musculoskeletal systems did not reveal any abnormality. For her skin rashes she was referred to dermatologist. Detailed dermatological examination revealed multiple hyperkeratotic, violaceous, flat top papules with central atrophy present on the dorsum of the interphalangeal and metacarpophalangeal joints suggestive of Gottron's papules [Figure 1]. She also had discrete heliotrope erythema in periorbital region of face [Figure 2] and periungual telangiectasia and cuticular changes on hands. Dermatological findings were strongly suggestive of DM. However, even on repeated enquiry, patient denied any history of muscle weakness or pain neither any diminished muscle power was detected objectively. Her routine investigations including hematology, biochemistry, and urinalysis were normal. Serum creatinine kinase level was elevated (290 U per liter; normal value, <190 U per liter). Other muscle enzymes like serum lactic dehydrogenase (LDH), aldolase, serum glutamic oxaloacetic transaminase (SGOT), serum glutamic

**Address for correspondence:** Dr. Ashish K. Jaiswal,  
Department of Pulmonary Medicine, NIIMS, Greater Noida,  
Uttar Pradesh, India.

E-mail: jaiswalashish11@gmail.com

**Received:** 17-01-2020

**Revised:** 13-03-2020

**Accepted:** 13-04-2020

**Published:** 30-06-2020

#### Access this article online

##### Quick Response Code:



**Website:**  
www.jfmpc.com

**DOI:**  
10.4103/jfmpc.jfmpc\_106\_20

This is an open access journal, and articles are distributed under the terms of the Creative Commons Attribution-NonCommercial-ShareAlike 4.0 License, which allows others to remix, tweak, and build upon the work non-commercially, as long as appropriate credit is given and the new creations are licensed under the identical terms.

**For reprints contact:** WKHLRPMedknow\_reprints@wolterskluwer.com

**How to cite this article:** Bandi S, Jain V, Jaiswal AK. Amyopathic dermatomyositis with diffuse lung disease. J Family Med Prim Care 2020;9:3147-50.

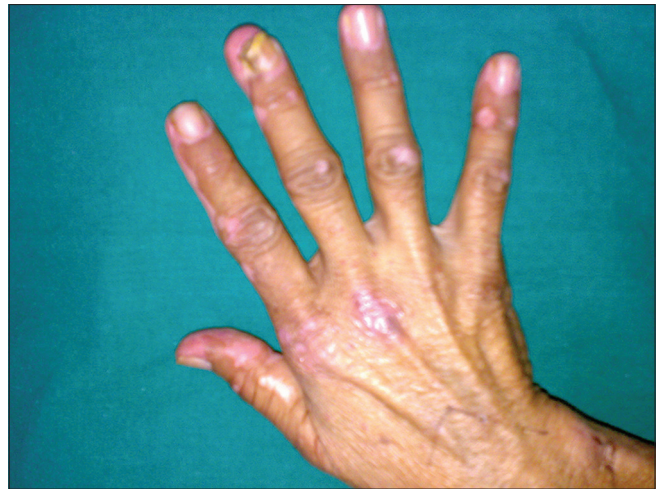pyruvate transaminase (SGPT) were normal. High-resolution computerized tomography (HRCT) scan revealed thickened interlobular septa, linear opacities, ground-glass opacification, and patchy consolidation with some evidence of traction bronchiectasis in the basal zone [Figure 3]. Pulmonary function test (PFT) was suggestive of severe restrictive lung disease with forced vital capacity (FVC) being 34% of the predicted value. 2D – ECHO was suggestive of severe pulmonary arterial hypertension (PAH) with a gradient of 70 mm Hg along pulmonary valve. Skin-biopsy showed acanthosis, hyperkeratosis with focal vacuolar alteration of the basal-cell layer, and perivascular inflammatory infiltrates in upper dermis, findings that were consistent with Gottron's papules. Electromyography (EMG) and magnetic resonance imaging (MRI) of proximal muscles were normal. Tests for serum antinuclear antibody (ANA), rheumatoid factor (RF), anti-ribonucleo protein (RNP) antibody, and Jo-1 antibody were negative. Based on above clinical, lab investigation and imaging findings, she was diagnosed as a case of DM. She was managed with prolonged course of systemic prednisolone along with topical steroid, sun screens, and other sun protective measures. She slowly responded to these treatments. At 1 year of follow-up, her heliotrope rash had resolved, Gottron's papules had regressed partially, and her respiratory complaints were stable. She continued to have no musculoskeletal abnormalities, and her muscle enzyme CPK had returned to normal level. She is still under treatment and follow-up.

## Discussion

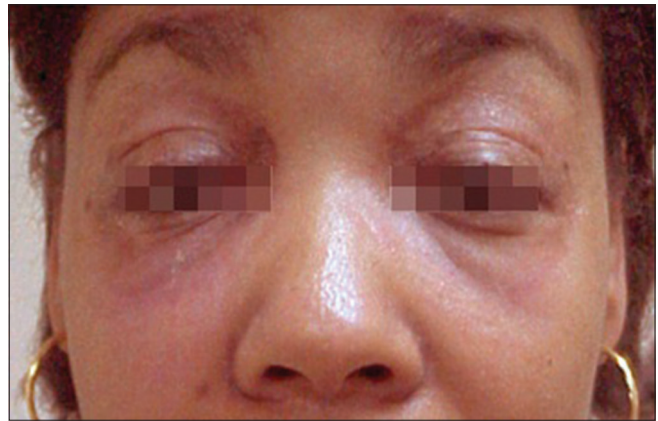
DM is a relatively rare disorder that occurs throughout the world. The incidence of DM ranges from 2 to 10 per million populations, with a female-to-male predominance of 2.5:1 and with a bimodal age distribution peaking in childhood and in the fourth to fifth decades. DM appears to have a higher expression of HLA-B8/DR3, HLA-, B14, and HLA-B40.<sup>[4]</sup> Bowen and Peter in 1975 proposed the diagnostic criteria for DM/PM,<sup>[5]</sup> which still is well accepted. These criteria include:-

1. Progressive symmetrical proximal muscle weakness.
2. Elevation of serum enzymes level of muscle origin (CPK, aldolase, SGOT, SGPT, LDH).
3. Abnormal electromyography showing characteristic myositis pattern.
4. Abnormal muscle biopsy showing inflammatory muscle injury.
5. Characteristic cutaneous manifestations.

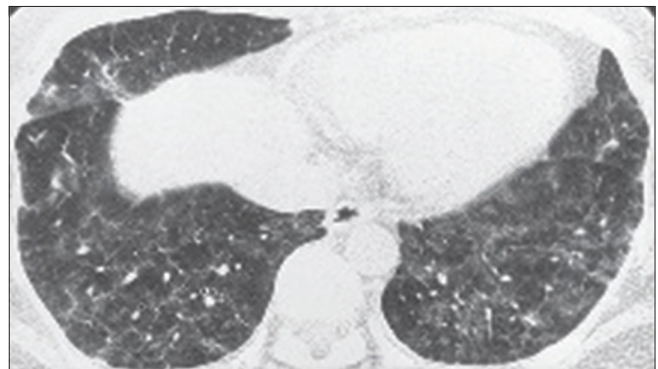
The diagnosis of DM is considered definitive in case of presence of 5<sup>th</sup> plus any three of first four criteria and probable in case of presence of 5<sup>th</sup> plus any two of first four criteria. The pathognomonic cutaneous lesions of DM are Gottron's papules and Gottron's sign. Gottron's papules consists of violaceous flat top papules over dorsal aspect of inter-phalangeal joints of hands. Gottron's sign consists of macular violaceous erythema with or without edema over



**Figure 1:** Hyperkeratotic, erythematous, flat papules with central atrophy



**Figure 2:** Discrete facial heliotrope erythema on face



**Figure 3:** HRCT findings include thickened interlobular septa, linear opacities, ground-glass opacification, and patchy consolidation with some traction bronchiectasis

inter/metacarpo phalangeal joints and bony prominences like elbows, knees, and medial malleoli. The characteristic cutaneous features of DM include heliotrope rash which consists of a violaceous-to-dusky erythematous rash with or without edema in a symmetrical distribution involving periorbital skin. Several other cutaneous features, including macular violaceous erythema in photo distribution and on

extensor surfaces of upper limb, poikiloderma (i.e. variegated hypo and hyperpigmentation, telangiectasia and atrophy of skin) and periungual and cuticular changes are characteristic of DM even though not pathognomonic. Although cutaneous lesions of DM can be quite specific, the histopathologic findings are often non-diagnostic, demonstrating evidence of non-specific chronic dermatitis. However, not infrequently, histologic changes are indistinguishable from systemic lupus erythematosus (SLE) showing epidermal atrophy, basal cell degeneration, edema of upper dermis, scattered inflammatory infiltrate, and often mucin deposition. The Gottron's papules also show basal cell degeneration but acanthosis rather than epidermal atrophy as seen in the present cases.

The most common CT findings in lung disease associated with PM/DM have been irregular linear opacities with areas of consolidation and ground-glass attenuation.<sup>[6,7]</sup> Honeycombing has not been a common finding in these patients. Mino *et al.*<sup>[8]</sup> found no honeycombing in his study on 17 cases, whereas Akira *et al.*<sup>[9]</sup> reported honeycombing in only 2 of 7 patients. Our results correlate well with these previous studies in which irregular linear opacities with bilateral and lower lung predominance were the most common finding.

In study of 70 patients by William *et al.* the impairment of pulmonary function was predominantly restrictive; with total lung capacity below 80% of the predicted value in 27 of 33 patients tested. Forced vital capacity was below 80% predicted in 31 of 38 of those tested. Our case study is accordance with the same.<sup>[10]</sup> Prior studies describing the histopathology of interstitial lung disease (ILD) in DM have recognized several patterns including diffuse alveolar damage (DAD), bronchiolitis obliterans organizing pneumonia (BOOP), cellular interstitial pneumonia (not otherwise specified), and usual interstitial pneumonia (UIP)<sup>[6,7]</sup> while in our case it was chronic interstitial pneumonitis with mild degree of alveolitis.

In the present case, muscular system was normal clinically and also on EMG and MRI. Only there was slight elevation of CPK. As there was no evidence of muscular involvement clinically and also on EMG and MRI, muscle biopsy was not done. William *et al.* in their study of DM/PM showed presence of proximal weakness, tenderness, joint swelling, Raynaud's phenomenon, and abnormal cardiopulmonary examination findings. Out of 53 patients in whom EMG was done active myopathy was seen in 49, normal findings in 3, and was indeterminate in 1. In fact, the presence of a low creatine kinase has been associated with more rapidly progressive diffuse lung disease.<sup>[10]</sup> Studies of autoantibodies have highlighted the association between the presences of antibodies to aminoacyl transfer RNA (tRNA) synthetases, inflammatory myopathies, and diffuse lung disease. These antibodies help define the clinical antisynthetase syndrome: The coexistence of myositis, diffuse lung disease, and arthritis. The most common autoantibody is Jo-1 (a cytoplasmic antihistidyl tRNA synthetase), occurring in 20–30% of patients

with inflammatory myopathy and correlating strongly with the presence of diffuse lung disease.<sup>[8-10]</sup>

Glucocorticoids are the first line therapy for DM. A slow tapering over a period of 2–3 years give best result. Other immunomodulators such as IVIg, azathioprine, methotrexate, cyclophosphamide, cyclosporine, mycophenolate mophetil, tacrolimus, sirolimus, infliximab, and rituximab may also be used, especially in setting of severe or recalcitrant disease or steroid toxicity are.<sup>[11,12]</sup> Our patient did well on oral steroid without any further exacerbation.

The present case is interesting in view progressively increasing respiratory disease, cutaneous lesions characteristic of DM clinically and histopathologically, absence of muscular involvement and fairly good response to treatment.

### Financial support and sponsorship

Nil.

### Conflicts of interest

There are no conflicts of interest.

### References

1. Krathen MS, Fiorentino D, Werth VP. Dermatomyositis. *Curr Dir Autoimmun* 2008;10:313-32.
2. Sontheimer RD. The management of dermatomyositis: Current treatment options. *Expert Opin Pharmacother* 2004;5:1083-99.
3. Shinohara T, Hidaka T, Matsuki Y, Ishizuka T, Takamizawa M, Kawakami M, *et al.* Rapidly progressive interstitial lung disease associated with dermatomyositis responding to intravenous cyclophosphamide pulse therapy. *Intern Med* 1997;36:519-23.
4. Iorizzo LJ 3<sup>rd</sup>, Jorizzo JL. The treatment and prognosis of dermatomyositis: An updated review. *J Am Acad Dermatol* 2008;59:99-112.
5. Bohan A, Peter JB. Polymyositis and dermatomyositis (second of two parts). *N Engl J Med* 1975;292:403-7.
6. Ikezoe J, Johkoh T, Kohno N, Takeuchi N, Ichikado K, Nakamura H. High-resolution CT findings of lung disease in patients with polymyositis and dermatomyositis. *J Thorac Imag* 1996;11:250-9.
7. Nicholson AG, Colby TV, DuBois RM, Wells AU. The prognostic significance of the histologic pattern of interstitial pneumonia in patients presenting with the clinical entity of cryptogenic fibrosing alveolitis. *Am J Respir Crit Care Med* 2000;162:2213-7.
8. Mino M, Noma S, Taguchi Y, Tomii K, Kohri Y, Oida K. Pulmonary involvement in polymyositis and dermatomyositis: Sequential evaluation with CT. *AJR Am J Roentgenol* 1997;169:83-7.
9. Akira M, Hara H, Sakatani M. Interstitial lung disease in association with polymyositis-dermatomyositis: Long-term follow-up CT evaluation in seven patients. *Radiology* 1999;210:333-8.
10. Douglas WW, Tazelaar HD, Hartman TE, Hartman RP, Decker PA, Schroeder DR, *et al.* Polymyositis-dermatomyositis

- associated interstitial lung disease. *Am J Respir Crit Care Med* 2001;164:1182-5.
11. Majithia V, Harisdangkul V. Mycophenolate mofetil. an alternative therapy for autoimmune inflammatory myopathy. *Rheumatology* 2005;44:386-9.
  12. Zieglschmid-Adams ME, Pandya AG, Cohen SB, Sontheimer RD. Treatment of dermatomyositis with methotrexate. *J Am Acad Dermatol* 1995;754-7.