

Accuracy of virtual 3-dimensional cephalometric images constructed with 2-dimensional cephalograms using the biplanar radiography principle

Jae-Seo Lee¹, Sang-Rok Kim², Hyeon-Shik Hwang², Kyungmin Clara Lee^{2,*}

¹Department of Oral and Maxillofacial Radiology, School of Dentistry, Chonnam National University, Gwangju, Korea

²Department of Orthodontics, School of Dentistry, Chonnam National University, Gwangju, Korea

ABSTRACT

Purpose: The purpose of this study was to evaluate the accuracy of virtual 3-dimensional (3D) cephalograms constructed using the principle of biplanar radiography by comparing them with cone-beam computed tomography (CBCT) images.

Materials and Methods: Thirty orthodontic patients were enrolled in this study. Frontal and lateral cephalograms were obtained with the use of a head posture aligner and reconstructed into 3D cephalograms using biplanar radiography software. Thirty-four measurements representing the height, width, depth, and oblique distance were computed in 3 dimensions, and compared with the measurements from the 3D images obtained by CBCT, using the paired *t*-test and Bland-Altman analysis.

Results: Comparison of height, width, depth, and oblique measurements showed no statistically significant differences between the measurements obtained from 3D cephalograms and those from CBCT images ($P > 0.05$). Bland-Altman plots also showed high agreement between the 3D cephalograms and CBCT images.

Conclusion: Accurate 3D cephalograms can be constructed using the principle of biplanar radiography if frontal and lateral cephalograms can be obtained with a head posture aligner. Three-dimensional cephalograms generated using biplanar radiography can replace CBCT images taken for diagnostic purposes. (*Imaging Sci Dent* 2021; 51: 407-12)

KEY WORDS: Dental Digital Radiography; Cone-Beam Computed Tomography; Diagnostic Imaging

Introduction

Cone-beam computed tomography (CBCT) has been used in dentistry for orthodontic diagnosis and treatment planning; however, its relatively high costs have been a burden to patients and clinicians for routine usage.¹⁻³ In order to obtain CBCT images for diagnostic purposes, including 3-dimensional (3D) analysis for skull and dentition, CBCT scanning with a large field of view (FOV) is necessary. Nonetheless, there are limitations in taking CBCT scans routinely with a large FOV for all patients because of the radiation hazard and high costs. The growing usage of

CBCT in clinical dentistry has provided more accurate and higher-quality images, but both the benefits and hazards of radiation exposure should be taken into consideration. Many clinical attempts have been made to generate 3D coordinates by reconstructing 2-dimensional (2D) radiographs such as lateral and frontal cephalograms. The biplanar radiography method⁴⁻⁹ generates a 3D cephalogram using frontal and lateral cephalograms taken at a 90° angle. This method has the advantage that clinicians can utilize conventional cephalometric landmarks for 3D cephalograms using geometric principles in a computer algorithm. Grayson et al.⁴ reported the accuracy of biplanar stereo-metry using 2 cephalometric radiographs taken using 2 X-ray tubes positioned at a 90° angle to each other. Kusnoto et al.⁹ demonstrated the clinical application of a 3D CephTM (Department of Orthodontics, University of Illinois, Chicago, IL, USA) program that measured 3D distances by reconstructing lateral, frontal, and submentoververtex cepha-

This work was supported by a National Research Foundation of Korea (NRF) grant funded by the Korean government (Ministry of Science and ICT) (No. 2020R1F1A1070617 and NRF-2017R1D1A1B03032132).

Received April 13, 2021; Revised June 23, 2021; Accepted June 23, 2021

Published online Aug 11, 2021

*Correspondence to : Prof. Kyungmin Clara Lee

Department of Orthodontics, School of Dentistry, Chonnam National University, 33 Yongbong-ro, Buk-gu, Gwangju 61186, Korea
Tel) 82-62-530-5864, E-mail) ortholk@jnu.ac.kr

lometric radiographs.

Although 3D images can be generated from only lateral and frontal cephalograms using the biplanar radiography method instead of CBCT, this method has not been used routinely in clinical practice. In order to generate an accurate 3D cephalogram, the lateral and frontal cephalograms are obtained at exactly a 90° angle, and the patient's head posture is maintained during X-ray taking. This method requires 2 X-ray beams positioned at a 90° angle. In routine practice, clinicians obtain lateral and frontal cephalograms by using a single X-ray beam and a rotational radiographic cassette. This practice necessarily changes the patient's head posture, thus producing images of 2 different head postures. To avoid this disadvantage, a head posture aligner can be used for taking lateral and frontal cephalograms using a single X-ray beam and biplanar radiography.¹⁰ During X-ray taking, horizontal rotation of the patient's head is prevented by the ear rod in the cephalostat, while the vertical rotation of the patient's head is prevented by using the head posture aligner. With the use of a head posture aligner, conventional lateral and frontal cephalograms can be taken with the identical posture of the patient's head, which can contribute to the generation of accurate 3D cephalograms.

Previous studies evaluated the clinical validity of the 3D images generated from lateral and frontal cephalograms taken by biplanar radiography with a head posture aligner by comparing these images with 3D images generated from the lateral and frontal cephalograms taken with CBCT.¹¹⁻¹³

The purpose of this study was to evaluate the accuracy of virtual 3D cephalograms generated using conventional lateral and frontal cephalograms taken using the principle of biplanar radiography with the use of a head posture aligner by comparing those cephalograms with CBCT images.

Materials and Methods

Thirty orthodontic patients who had frontal and lateral cephalograms obtained with the use of a head posture aligner and CBCT scans were enrolled in this study. The present study was approved by Chonnam National University Dental Hospital Institutional Review Board (CNUDH-2018-001) in compliance with the Helsinki Declaration, and written informed consent was obtained from all patients.

Frontal and lateral cephalograms were taken with a head posture aligner and 2 kinds of fiducial markers. The head posture aligner was used to obtain the lateral and frontal cephalograms at the same head posture, so that the 2 cephalograms were taken in accordance with the biplanar radiography principle. In order to distinguish the right and left side gonion on the lateral cephalograms, an (o)-shaped marker was attached to the right side of mandibular angle area whereas a (+)-shaped marker was placed on the left side. The markers were attached to the patient's gonion area prior to the acquisition of radiographs. The patients were instructed to look at the mirror with a natural head position, and then the head posture aligner was attached to the left zygomatic area. An OrthoCeph[®] OC100 device (Imaging Instrumentarium, Tuusula, Finland) was used to obtain lateral and frontal cephalograms. When taking frontal cephalograms, the patient was repositioned at a 90° angle, and the head posture was adjusted according to the head posture aligner, ensuring that the head posture remained the same for lateral and frontal cephalograms. The magnification of the images was 110%.

Each CBCT scan was obtained using a head posture aligner and reference ear plug (Fig. 1) with an Alphard Vega scanner (Asahi Roentgen Co., Kyoto, Japan). The reference ear plug was used in this study to construct a virtual reference axis for the orientation of the head images. The refer-




Fig. 1. A. A head posture aligner (left) is used to obtain an identical head posture. An (o)-shaped and a (+)-shaped marker (right) are used to distinguish the right and left side gonion on the lateral cephalograms. Before taking radiographs, the head posture aligner is attached to the left zygomatic area, and the markers are attached to the patient's gonion area prior to the acquisition of radiographs. B. The reference ear plugs contain a titanium marker and are inserted into each ear hole of the patient so that the 2 markers can be used to construct the reference axis on the volume image.

Table 1. Description of cephalometric landmarks used in this study

Landmarks (abbreviation)	Lateral	Frontal
Midsagittal		
Nasion (N)	V notch of frontal and nasal bone	—
Basion (Ba)	The midpoint on the anterior margin of the foramen magnum	—
Anterior nasal spine (ANS)	The tip of the anterior nasal spine	—
Posterior nasal spine (PNS)	The most posterior point of the hard palate	—
A point (A)	The deepest point between the ANS and incisal alveolus	—
B point (B)	The deepest point between the pogonion and the lower incisal alveolus	—
Pogonion (Pog)	The most anterior point on the symphysis	—
Menton (Me)	The most inferior point on the symphyseal area	—
Bilateral		
Orbitale (Or)	The most inferior point of the orbital contour	The most inferior point of the orbital contour
Condylion (Cd)	The most superior point of the condyle	The most superior point of the condyle
Jugal process (J)	—	Intersection of the jugal process with the maxillary tuberosity
M point (M)	—	Intersection of the contour of buccal surface of the maxillary first molar with the adjacent alveolar bone
Gonion (Go)	The most posterior and inferior point at the mandibular angle	The most lateral and inferior point at the mandibular angle
Upper first molar (U6)	The most concave point on occlusal outline of the maxillary first molar	The most concave point on occlusal outline of the maxillary first molar
Lower first molar (L6)	The most concave point on occlusal outline of the mandibular first molar	The most concave point on occlusal outline of the mandibular first molar
Upper incisor (U1)	Incisal tip of the upper central incisor	Midpoint of the incisal edge of the upper central incisor
Lower incisor (L1)	Incisal tip of the lower central incisor	Midpoint of the incisal edge of the lower central incisor

ence ear plugs contained a titanium marker and were inserted into each ear hole of the patient, so that the 2 markers could construct the reference axis on the volume image.

To generate accurate 3D cephalograms, the image level of the lateral and frontal cephalograms was adjusted in Photoshop (Adobe Systems, San Jose, CA, USA). In order to minimize errors in the landmark identification, the landmarks were identified in Photoshop by using the zoom-in function prior to incorporating them into the 3D Ceph™ program. Then, the lateral and frontal cephalograms were imported into the software used for 3D cephalograms (3D Ceph™), and 26 landmarks were identified on each lateral and frontal cephalogram. Definitions of the landmarks are shown in Table 1. After importing the lateral and frontal cephalograms into 3D Aligner™ (Department of Orthodontics, University of Illinois, Chicago, IL, USA), the distance between the subject and the film was programmed. Then,

3D cephalograms were created by connecting each landmark on the lateral frontal cephalograms using the Create 3D frame function of the program. If the projection line passing through each landmark did not meet each other, the location of the landmark was modified using vector intercept with a manual algorithm (Fig. 2).^{7,14}

To evaluate accuracies of 3D cephalograms obtained using head posture aligner and compare with those obtained using CBCT, 34 measurements for height (5), width (7), depth (7), and oblique distance (15) were obtained using the 3D log function in the 3D Aligner™ program.

After normality of the data distribution was assessed using the Shapiro-Wilk test, the accuracy of the 3D cephalograms obtained using the head posture aligner and those obtained using CBCT images was compared using the paired *t*-test, which was carried out at the 5% level of significance with SPSS version 23 (IBM Corp., Armonk, NY, USA)

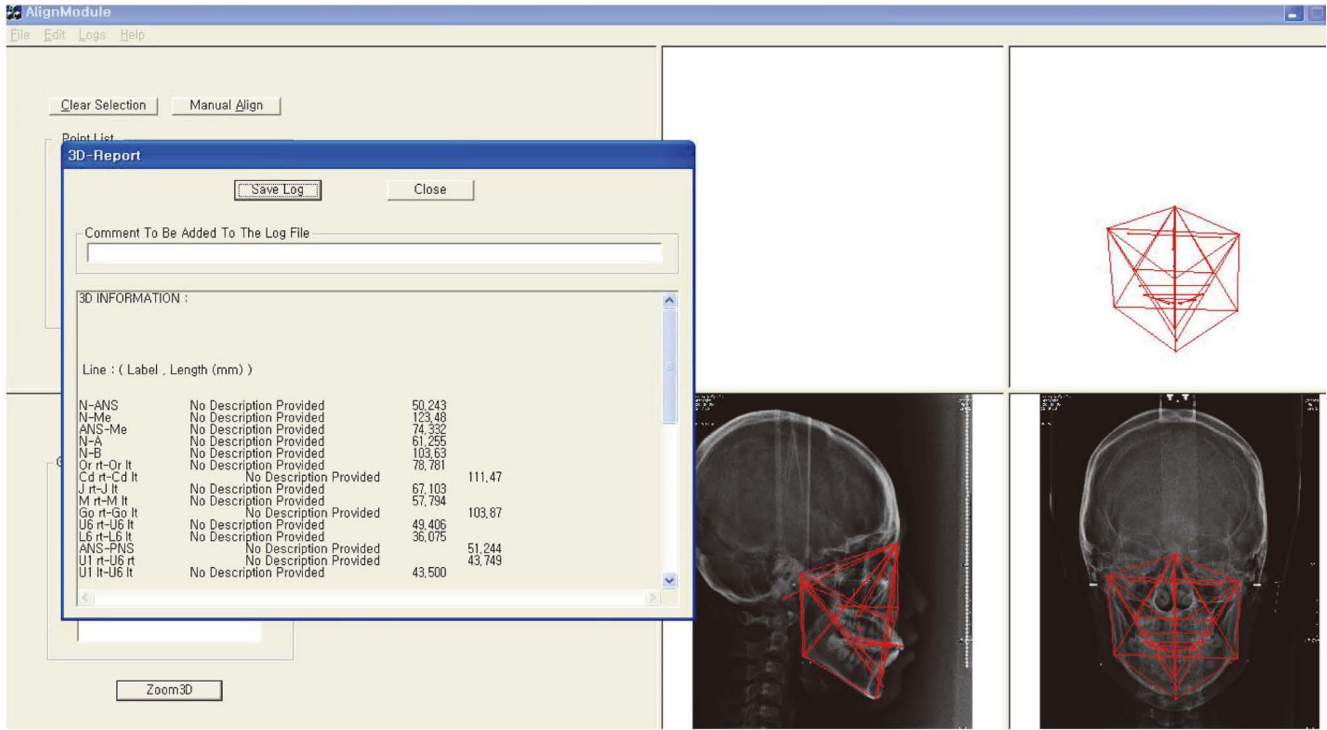


Fig. 2. A 3-dimensional (3D) cephalometric image generated from lateral and frontal cephalograms using the 3D Ceph™ program.

Table 2. Height measurements and comparison between virtual 3-dimensional (3D) cephalograms and cone-beam computed tomographic (CBCT) images (unit: mm)

	Virtual 3D cephalograms	CBCT	Difference
N-ANS	57.0 ± 3.7	56.9 ± 3.7	0.1
N-Me	128.5 ± 9.1	128.3 ± 9.1	0.1
ANS-Me	72.9 ± 7.3	72.8 ± 7.3	0.1
N-A	64.3 ± 4.3	64.3 ± 4.3	0.1
N-B	106.7 ± 7.6	106.7 ± 7.7	0.1

N: nasion, ANS: anterior nasal spine, Me: menton, A: A point, B: B point

and Bland-Altman plots¹⁵ (MedCalc Software, Ostend, Belgium).

Results

The mean values and standard deviations of each measurement from the 3D cephalograms obtained using the head posture aligner and CBCT images are shown in Tables 2-5. In the height measurements, the differences were within 0.1 mm, whereas the differences in the width measurements ranged from 0.7 to 1.3 mm. The paired *t*-test showed that the differences were not statistically significant ($P > 0.05$) (Tables 2-5).

Table 3. Width measurements and comparison between virtual 3-dimensional (3D) cephalograms and cone-beam computed tomographic (CBCT) images (unit: mm)

	Virtual 3D cephalograms	CBCT	Difference
Or _{rt} -Or _{lt}	69.8 ± 5.3	69.6 ± 5.1	1.0
Cd _{rt} -Cd _{lt}	115.1 ± 7.9	114.9 ± 7.7	1.3
J _{rt} -J _{lt}	69.6 ± 3.7	69.2 ± 3.3	1.0
M _{rt} -M _{lt}	53.8 ± 3.2	53.7 ± 3.2	1.0
Go _{rt} -Go _{lt}	105.6 ± 6.6	105.4 ± 6.7	1.2
U6 _{rt} -U6 _{lt}	47.5 ± 3.0	47.5 ± 3.0	0.7
L6 _{rt} -L6 _{lt}	43.2 ± 3.1	43.0 ± 2.9	0.8

Or_{rt}: right orbitale, Or_{lt}: left orbitale, Cd_{rt}: right condyilion, Cd_{lt}: left condyilion, J_{rt}: right jugal process, J_{lt}: left jugal process, M_{rt}: right M point, M_{lt}: left M point, Go_{rt}: right gonion, Go_{lt}: left gonion, U6_{rt}: right upper first molar, U6_{lt}: left upper first molar, L6_{rt}: right lower first molar, L6_{lt}: left lower first molar

The results of Bland-Altman plotting showed no systematic differences in 34 measurements between 3D cephalograms obtained using the head posture aligner and CBCT images. The differences were within the limits of agreement. In particular, in the height measurements, the magnitude of the differences was small, and the agreement width, which represents the distance between upper and lower limits of agreement, was narrower than those of the depth, width, and oblique measurements.

Table 4. Depth measurements and comparison between virtual 3-dimensional (3D) cephalograms and cone-beam computed tomographic (CBCT) images (unit: mm)

	Virtual 3D cephalograms	CBCT	Difference
ANS-PNS	51.7 ± 4.6	51.9 ± 4.5	0.9
U1 _{rt} -U6 _{rt}	39.7 ± 3.4	39.8 ± 3.3	0.8
U1 _{lt} -U6 _{lt}	40.4 ± 3.7	40.6 ± 3.7	0.4
L1 _{rt} -L6 _{rt}	35.7 ± 4.1	35.7 ± 3.8	0.8
L1 _{lt} -L6 _{lt}	35.7 ± 4.0	35.7 ± 4.1	0.8
Me-Go _{rt}	93.9 ± 6.0	93.9 ± 5.7	1.0
Me-Go _{lt}	93.1 ± 5.7	93.2 ± 5.7	0.8

ANS: anterior nasal spine, PNS: posterior nasal spine, U1: upper incisor, U6: upper first molar, L1: lower first molar, L6: lower first molar, rt: right, lt: left, Me: menton, Go: gonion

Table 5. Oblique measurements and comparison between virtual 3-dimensional (3D) cephalograms and cone-beam computed tomographic (CBCT) images (unit: mm)

	Virtual 3D cephalogram	CBCT	Difference
N-Ba	105.4 ± 5.7	105.8 ± 5.5	1.2
N-Cd _{rt}	102.4 ± 6.6	102.7 ± 6.6	1.2
N-Cd _{lt}	107.3 ± 5.8	107.5 ± 5.7	0.7
N-J _{rt}	71.5 ± 4.8	71.7 ± 4.6	0.7
N-J _{lt}	76.3 ± 5.3	76.2 ± 5.2	0.7
N-Go _{rt}	131.2 ± 8.1	131.4 ± 8.0	1.0
N-Go _{lt}	135.7 ± 7.8	135.8 ± 7.7	0.9
Cd _{rt} -A	107.9 ± 5.6	108.2 ± 5.4	1.1
Cd _{lt} -A	105.7 ± 5.1	105.8 ± 5.0	0.6
Cd _{rt} -B	128.1 ± 7.5	128.3 ± 7.4	0.9
Cd _{lt} -B	122.0 ± 7.3	122.1 ± 7.4	0.6
Cd _{rt} -Go _{rt}	68.9 ± 7.0	68.9 ± 7.0	0.5
Cd _{lt} -Go _{lt}	62.3 ± 6.2	62.2 ± 6.2	0.5
Cd _{rt} -Pog	138.4 ± 8.7	138.6 ± 8.5	0.9
Cd _{lt} -Pog	131.4 ± 8.5	131.5 ± 8.5	0.7

N: nasion, Ba: basion, Cd_{rt}: right condyilion, Cd_{lt}: left condyilion, J_{rt}: right jugal process, J_{lt}: left jugal process, Go_{rt}: right gonion, Go_{lt}: left gonion, A: A point, B: B point, Pog: pogonion

Discussion

There are 2 methods for fabricating 3D cephalograms: a coplanar method based on convergent geometry¹⁶⁻¹⁹ and a biplanar method based on biplanar geometry.⁴⁻⁹ Both methods can generate 3D images using 2D lateral and frontal cephalometric radiographs and allow the evaluation of cephalometric changes after orthodontic treatment by qualitative and quantitative approaches. The coplanar method requires the patient to remain at a certain point and the radiation source to move; thus, a special radiographic

apparatus is required to obtain lateral or frontal cephalometric radiographs. However, the biplanar method requires the patient to move; therefore, a separate radiation apparatus is not necessary for obtaining each of the 2 types of images. However, in the biplanar method, the lateral and frontal cephalograms are obtained at exactly a 90° angle with biplanar geometry. In fact, when Broadbent²⁰ first developed a cephalometric radiography system, it was possible to obtain a complete biplanar radiograph by arranging the 2 X-ray beams at 90° to each other and simultaneously obtaining both the lateral and frontal cephalometric radiographs.

Park et al.¹⁴ reported that a new biplanar imaging system, which consisted of 2 arrays of the X-ray beam at a 90° angle, could simultaneously take frontal and lateral cephalograms. However, this biplanar imaging system requires a large space because it uses 2 X-ray machines. Thus, in the present study, a head posture aligner was used to take the lateral and frontal cephalograms using a single X-ray beam and biplanar radiography without changing the patient's head posture during the procedure.

In our study, comparisons of height, width, depth, and oblique measurements showed no statistically significant differences between the measurements obtained from 3D cephalograms and those from CBCT images. This indicates that accurate 3D cephalograms similar to those obtained from CBCT images can be generated from 2 radiographs by using a head posture aligner to ensure the same head posture during radiography.

In order to produce accurate 3D cephalograms in the biplanar radiography computer program, it is necessary to set the landmarks in the same area in both the lateral and frontal cephalograms. In the 3D cephalogram program used in this study, it is difficult to identify landmarks accurately. Thus, to minimize errors in landmark identification, the landmarks were identified in Photoshop by using the zoom-in function prior to incorporating them into the 3D CephTM program.

Although the paired *t*-test did not show any significant difference among all the measurements, the difference in the height measurements was smaller than that in other measurements. The difference in width measurements was in the range of 0.7-1.3 mm, whereas the difference in the height measurements was approximately 0.1 mm. A potential explanation for the accuracy of landmark identification and generation of 3D cephalograms might be that the landmarks used for the height measurements existed on the mid-sagittal structure, not on bilateral structures, and lateral and frontal cephalograms were used to generate the 3D cephalograms. In the 3D Aligner program, there is an adjustment

process for landmark identification to make the projection lines coincide with each other. This process allows the vertical position of each landmark to be properly aligned. If the 3D cephalograms were generated using lateral and submentoververtex radiographs, the difference between depth measurements would have been smaller. If the 3D cephalograms were generated using frontal and submentoververtex radiographs, the difference between width measurements would have been smaller. It is possible to obtain 3D cephalograms with the same accuracy as those obtained using the CBCT images if any 2 radiographs can be taken using a head posture aligner.

As described above, the 3D cephalograms generated using the biplanar radiography principle are 3D images of a mesh composed of landmarks. Although it is not an actual image, it is possible to use the landmarks currently used in clinical settings, and the distance between the landmarks could be calculated accurately by using the actual distance through a computer function. Another advantage of this technique is that it enables previously recorded cephalometric radiographs, if any, to be incorporated into a computer program at any time for an accurate estimation of changes in the craniofacial morphology by calculating the distance between the landmarks and comparing the present measurement values. However, if the previous cephalograms were not taken in the same head posture, the accuracy of the generated 3D cephalograms and the corresponding comparative analysis would be limited. Therefore, it is suggested that clinicians who do not have a CBCT scanner, but want to perform a 3D evaluation, could use a head posture aligner in conjunction with cephalometric radiography.

Virtual 3D cephalograms using the biplanar radiography principle might accurately measure height, width, depth, and oblique distance and are comparable to CBCT images. Furthermore, this method could enable 3D image information to be obtained without using CBCT. Therefore, the use of virtual 3D cephalograms can be recommended for clinicians who do not have a CBCT scanner, but would like to perform 3D evaluations.

Conflicts of Interest: None

References

1. Mozzo P, Procacci C, Tacconi A, Martini PT, Andreis IA. A new volumetric CT machine for dental imaging based on the cone-beam technique: preliminary results. *Eur Radiol* 1998; 8: 1558-64.
2. Arai Y, Tammisalo E, Iwai K, Hashimoto K, Shinoda K. Development of a compact computed tomographic apparatus for dental use. *Dentomaxillofac Radiol* 1999; 28: 245-8.
3. Sukovic P. Cone beam computed tomography in craniofacial imaging. *Orthod Craniofac Res* 2003; 6 Suppl 1: 31-6.
4. Grayson B, Cutting C, Bookstein FL, Kim H, McCarthy JG. The three-dimensional cephalogram: theory, technique, and clinical application. *Am J Orthod Dentofacial Orthop* 1988; 94: 327-37.
5. Trocme MC, Sather AH, An KN. A biplanar cephalometric stereoradiography technique. *Am J Orthod Dentofacial Orthop* 1990; 98: 168-75.
6. Bookstein FL, Grayson B, Cutting CB, Kim HC, McCarthy JG. Landmarks in three dimensions: reconstruction from cephalograms versus direct observation. *Am J Orthod Dentofacial Orthop* 1991; 100: 133-40.
7. Brown T, Abbott AH. Computer-assisted location of reference points in three dimensions for radiographic cephalometry. *Am J Orthod Dentofacial Orthop* 1989; 95: 490-8.
8. Cutting C, Bookstein FL, Grayson B, Fellingham L, McCarthy JG. Three-dimensional computer-assisted design of craniofacial surgical procedure: optimization and interaction with cephalometrics and CT-based models. *Plast Reconstr Surg* 1986; 77: 877-87.
9. Kusnoto B, Evans CA, BeGole EA, de Rijk W. Assessment of 3-dimensional computer-generated cephalometric measurements. *Am J Orthod Dentofacial Orthop* 1999; 116: 390-9.
10. Kim EH, Hwang HS. The validity of head posture aligner in posteroanterior cephalometry. *Korean J Orthod* 2000; 30: 543-52.
11. Kumar V, Ludlow JB, Mol A, Cevidanes L. Comparison of conventional and cone beam CT synthesized cephalograms. *Dentomaxillofac Radiol* 2007; 36: 263-9.
12. Sun MK, Uhm GS, Cho JH, Hwang HS. Use of head posture aligner to improve accuracy of frontal cephalograms generated from cone-beam CT scans. *Korean J Orthod* 2009; 39: 289-99.
13. Hwang HS, Lee KM, Uhm GS, Cho JH, McNamara JA Jr. Use of reference ear plug to improve accuracy of lateral cephalograms generated from cone-beam computed tomography scans. *Korean J Orthod* 2013; 43: 54-61.
14. Park HY, Lee JS, Cho JH, Hwang HS, Lee KM. Accuracy of three-dimensional cephalograms generated using a biplanar imaging system. *Korean J Orthod* 2018; 48: 292-303.
15. Bland JM, Altman DG. Statistical methods for assessing agreement between two methods of clinical measurement. *Lancet* 1986; 1: 307-10.
16. Baumrind S, Moffitt FH, Curry S. The geometry of three-dimensional measurement from paired coplanar X-ray images. *Am J Orthod* 1983; 84: 313-22.
17. Baumrind S, Moffitt FH, Curry S. Three-dimensional X-ray stereometry from paired coplanar images: a progress report. *Am J Orthod* 1983; 84: 292-312.
18. Selvik G, Alberius P, Fahlman M. Roentgen stereophotogrammetry for analysis of cranial growth. *Am J Orthod* 1986; 89: 315-25.
19. Selvik G. Roentgen stereophotogrammetric analysis. *Acta Radiol* 1990; 31: 113-26.
20. Broadbent BH. A new X-ray technique and its application to orthodontia. *Angle Orthod* 1931; 1: 45-66.