

## Case report

Bilateral corneal denting after surgery under general anesthesia: A case report<sup>☆</sup>Satsuki Obata, Akiko Miki<sup>\*</sup>, Hisanori Imai, Makoto Nakamura

Department of Surgery, Division of Ophthalmology, Kobe University Graduate School of Medicine, Kobe, Japan



## ARTICLE INFO

## Keywords:

General anesthesia  
Cornea denting  
Complication  
Cardiovascular surgery

## ABSTRACT

**Purpose:** To report a case of temporary bilateral corneal denting in a patient who underwent cardiovascular surgery under general anesthesia.

**Observations:** A 71-year-old male with no history of ophthalmological disease experienced bilateral corneal denting immediately after undergoing surgery for aneurysm of the thoracic aorta under general anesthesia. Anesthesia was induced with propofol and maintained with rocuronium bromide and remifentanyl hydrochloride. The initial examination revealed significant denting on the surface of both the corneas and ocular hypotension. Visual evaluation could not be performed due to the patient's low level of consciousness resulting from delayed emergence from anesthesia. After applying tropicamide and phenylephrine ophthalmic solution for fundus examination, the ocular morphology improved. Ocular pressure was normal on the day after surgery, and creasing on the surface of the corneas had disappeared.

**Conclusions:** and **Importance:** We experienced a patient with bilateral corneal denting following a cardiovascular surgery under general anesthesia. The dents could be attributed to augmentation of ocular hypotension using several types of anesthesia at relatively high doses.

## 1. Introduction

Ocular complications after general anesthesia are uncommon.<sup>1</sup> Ocular surface disease such as dry eye is a most common finding.<sup>1</sup> It is also reported that patients who underwent coronary artery bypass graft surgery could develop retinal infarction or retinal emboli.<sup>2</sup>

On the other hand, corneal denting is a quite rare complication in connection with general anesthesia and has been reported only once by Hasegawa et al.<sup>3</sup> so far.

Here, we report a similar case of temporary bilateral corneal denting after surgery for aneurysm of the thoracic aorta under general anesthesia.

## 2. Case report

A 71-year-old male (height 156.0 cm, weight 40.0 kg) underwent ascending aorta and aortic arch replacement surgery for aneurysm of the thoracic aorta under general anesthesia. He remained under anesthesia for 10 h 20 min. Anesthesia was induced with propofol maintained with rocuronium bromide and remifentanyl hydrochloride. In addition, artificial cardiopulmonary bypass was performed during

the surgery; however, no diuretic drugs were used. The patient was consulted to the department of ophthalmology because ocular denting was observed after surgery. His medical history was left cerebral infarction, stenosis of the right internal carotid artery, and no history of ophthalmological disease. At initial examination, we observed denting and creasing on the surface of the corneas of both eyes. The anterior chambers were thin but maintained, and no fundal abnormalities were detected on non-dilated observation. The patient was not completely conscious during the initial examination and postoperative course; therefore, it was challenging to perform a visual acuity evaluation. In addition, ocular hypotension rendered the evaluation of ocular pressure challenging (Fig. 1).

After applying tropicamide and phenylephrine ophthalmic solution for fundus examination, we observed gradual improvement in the ocular morphology. Two hours after applying the ophthalmic solution, the corneal denting markedly improved and reduced to only slight creasing on the surfaces of the corneas. We did not find corneal edema in either eyes. The fundus examination did not indicate abnormal findings such as swelling of the optic disc or hemorrhage (Fig. 2).

On the day after surgery, the creasing on the surface of the corneas had disappeared and ocular pressure was normal (15 mmHg on the

<sup>☆</sup> This case was presented at the 70<sup>th</sup> Annual Congress of Japan Clinical Ophthalmology.

<sup>\*</sup> Corresponding author. Department of Surgery, Division of Ophthalmology, Kobe University Graduate School of Medicine, 7-5-2 Kusunoki-cho, Chuo-ku, Kobe 650-0017, Japan.  
E-mail address: [acacyey@med.kobe-u.ac.jp](mailto:acacyey@med.kobe-u.ac.jp) (A. Miki).

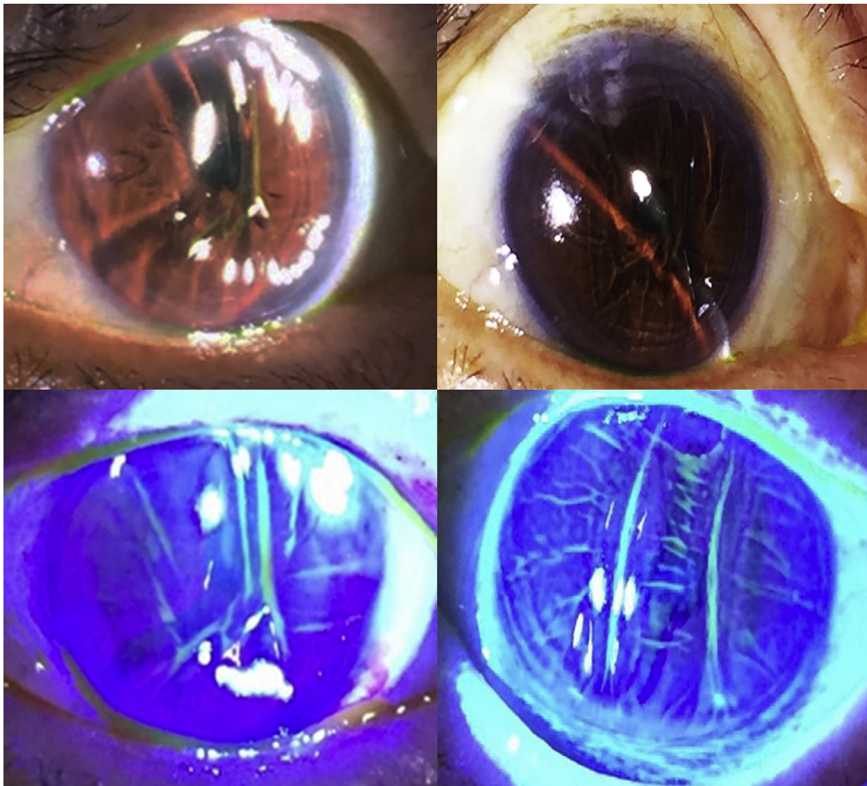


Fig. 1. Anterior chamber findings at initial examination. Significant corneal denting and creasing observed in both eyes.

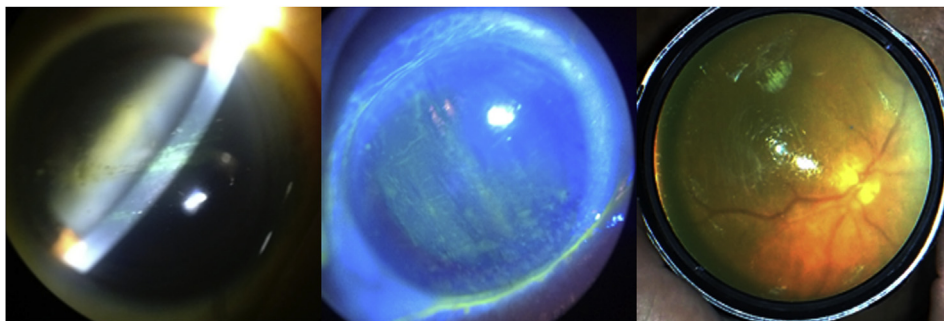


Fig. 2. Anterior chamber and fundus findings 2 h after the application of tropicamide and phenylephrine ophthalmic solution. Significant improvement in corneal denting, and normal fundus findings confirmed.

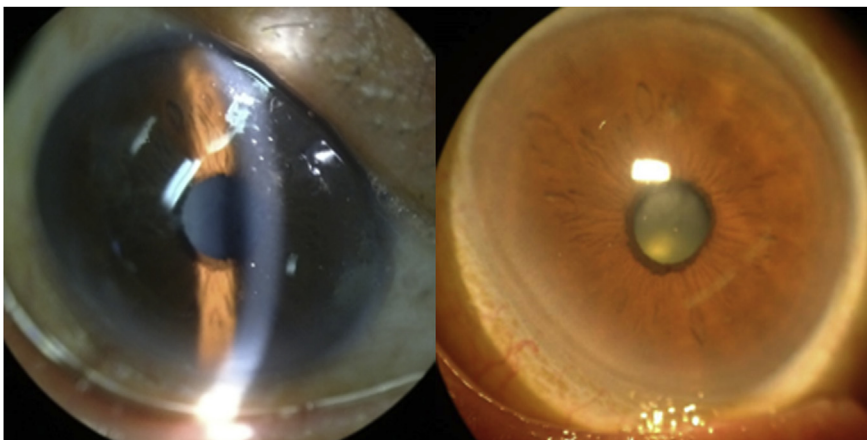


Fig. 3. Anterior chamber findings on the day following surgery. Creasing on the corneal surfaces has disappeared.

right and 14 mmHg on the left) (Fig. 3). We did not find apparent corneal endothelial cell damage in either eyes. In addition, the findings of the fundus examination were normal. Because our patient experienced delayed recovery from anesthesia, the assessment of visual function was impossible. Subsequently, he experienced septic shock and died 18 days after the surgery.

### 3. Discussion

Our patient experienced bilateral corneal denting after cardiovascular surgery under general anesthesia. A previous report<sup>3</sup> has discussed a case wherein the patient underwent blood vessel prosthesis implantation surgery under general anesthesia for acute aortic dissection and developed bilateral corneal denting immediately after the surgery. Similarities between that report and our report include the patient's advanced age, low body weight (Body mass index (BMI) < 18.5), and onset after long-term cardiovascular surgery.

The previous report<sup>3</sup> attributed the corneal denting to the following three factors: the effect of decreased ocular pressure because of general anesthesia (barbiturates), the possibility of excessive dose of mannitol for the body type during surgery, and the possibility of corneal denting because of the maintenance of corneal curvature radius by intraocular lens. However, the differences between the previous report and our report are the types of anesthetic agents used, high dose of diuretics, and history of cataract surgery in the previous study. Therefore, other factors may have been involved in the denting in the present case.

In the present case, multiple anesthetics, such as propofol, remifentanyl, and sevoflurane, which have the effect of decreasing ocular pressure, were utilized and may have augmented the ocular hypotension. All these anesthetic agents reportedly cause ocular hypotension.<sup>4,5</sup> In addition, the following mechanism of ocular hypotension caused by anesthesia has been reported<sup>6</sup>: aqueous outflow, which is regulated by intraocular pressure regulation center in the diencephalon, is promoted, and hypotonia of the extraocular muscles promotes decreased ocular tension and aqueous outflow. In addition, our patient experienced sympathetic nerve inhibition because of propofol, which, along with simultaneous decreases in the aqueous humor production, may have caused temporary excessive aqueous outflow.

Excessive doses of general anesthesia could also have been a cause of the corneal denting. In addition, our patient experienced delayed recovery from anesthesia, which may be attributed to the prolonged effect of excessive doses of anesthesia and muscle relaxants.<sup>5,7</sup> We also observed a likelihood of relatively excessive doses because of the patient's advanced age, low BMI, liver and renal functional disorders, and low cardiac function.<sup>8,9</sup> Because our case involved a patient with a low body weight who underwent cardiovascular surgery at a relatively advanced age, it is possible that relatively excessive doses of anesthesia were administered.

Another explanation for corneal denting might be the unbalance of pressure between anterior chamber and atonic pressure. The similar corneal denting infrequently takes place during cataract surgery when infusion does not catch up with aspiration, leading to a negative pressure in the anterior chamber compared with the atonic pressure. Such a negative pressure in the anterior chamber must have given rise for some reason in this patient during or after the cardiovascular surgery. General anesthetics may have negatively affected the partial pressure in the anterior chamber by passive diffusion into the aqueous humor.

The corneal morphology improved after applying tropicamide and phenylephrine ophthalmic solution. It may be because that the dilating

drops containing phenylephrine increase the resistance of aqueous outflow via the relaxation of ciliary muscle. Or there was also an inverse pressure gradient between the anterior and posterior chamber, and thus pupillary dilation may have released the reverse pupillary block. If so, an injection of physiological saline may be another option to treat this condition. It is also suggested that ocular morphology naturally became to its original state with time.

### 4. Conclusions

We report a case of bilateral corneal denting after surgery under general anesthesia. This case suggests that using multiple and relatively excessive doses of anesthetics increases the risk of corneal denting because of the augmentation of intraocular hypotension.

#### Patient consent

The patient's legal guardian consented to publication of the case in orally.

#### Funding

No funding or grant support.

#### Conflicts of interest

The authors declare that there is no conflict of interests regarding the publication of this paper.

#### Authorship

All authors attest that they meet the current ICMJE criteria for Authorship.

#### Acknowledgements

None.

#### References

- [1]. Kara-Junior N, Espindola RF, Valverde Filho J, Rosa CP, Ottoboni A, Silva ED. *Ocular Risk Management in Patients Undergoing General Anesthesia: An Analysis of 39,431 Surgeries Clinics (Sao Paulo)*. vol. 70. 2015; 2015:541–543 8.
- [2]. Shaw PJ, Bates D, Cartledge NE, et al. Neuro-ophthalmological complications of coronary artery bypass graft surgery. *Acta Neurol Scand*. 1987;76(1):1–7.
- [3]. Hasegawa T, Matsui Y, Morita M. Dented corneas related to cardiovascular surgery under general anesthesia. *Graefes Arch Clin Exp Ophthalmol*. 2012;50(3):465–466.
- [4]. Sator-Katzenschlager S, Deusch E, Dolezal S. Sevoflurane and propofol decrease intraocular pressure equally during non-ophthalmic surgery and recovery. *Br J Anaesth*. 2002;89(5):764–766.
- [5]. Hanna SF, Ahmad F, Pappas AL, et al. The effect of propofol/remifentanyl rapid-induction technique without muscle relaxants on intraocular pressure. *J Clin Anesth*. 2010;22(6):437–442.
- [6]. Schäfer R, Klett J, Auffarth G, et al. Intraocular pressure more reduced during anesthesia with propofol than with sevoflurane: both combined with remifentanyl. *Acta Anaesthesiol Scand*. 2002;46(6):703–706.
- [7]. Ullhas SM, Joshi Suchita Annasaheb, Shaikh Mudassar Mohd. Delayed recovery from anesthesia: a postgraduate educational review. *Anesth Essays*. 2016;10(2):164–172.
- [8]. Bowie MW, Slattum PW. Pharmacodynamics in older adults: a review. *Am J Geriatr Pharmacother*. 2007;5(3):263–303.
- [9]. Tsai HJ, Chen CC, Chang KY. Patients and surgery-related factors that affect time to recovery of consciousness in adult patients undergoing elective cardiac surgery. *J Chin Med Assoc*. 2011;74(8):345–349.