



# Ramsay Hunt Syndrome Presenting as Acute Unilateral Combined Peripheral and Central Vestibulopathies

Jae-Myung Kim<sup>a</sup>  
Kyung Wook Kang<sup>a</sup>  
Hyong-Ho Cho<sup>b</sup>  
Man-Seok Park<sup>a</sup>  
Seung-Han Lee<sup>a</sup>

<sup>a</sup>Department of Neurology,  
Chonnam National University Hospital,  
Chonnam National University  
Medical School, Gwangju, Korea

<sup>b</sup>Department of Otolaryngology-Head  
and Neck Surgery,  
Chonnam National University Hospital,  
Chonnam National University  
Medical School,  
Gwangju, Korea

Dear Editor,

A previously healthy 68-year-old female presented with spontaneous spinning vertigo with a 10-day history. She had been treated with intravenous acyclovir for 10 days before the onset of vertigo under a diagnosis of Ramsay Hunt syndrome (RHS). She denied otologic symptoms including hearing loss. The initial neurologic examinations revealed right-sided peripheral facial paralysis and spontaneous left-beating nystagmus (Fig. 1A). However, the direction of nystagmus shifted to the right side while looking toward the right, which suggested gaze-evoked nystagmus (GEN) (Fig. 1A). Skew deviation was absent, but prominent right-sided veering tendency without limb ataxia was noted. Bedside head impulse tests (HITs) revealed abnormal catch-up saccades (CS) in the right.

Bithermal caloric testing demonstrated right-canal paresis. However, video HITs showed decreases in the vestibulo-ocular reflex (VOR) gains in all six semicircular canals, with right-sided predominance (Fig. 1B and C). Cervical and ocular vestibular-evoked myogenic potentials were not observed when stimulating the right ear. Pure-tone audiometry was normal. GEN, bilateral abnormalities in video HITs, and severe prolonged vertigo with prominent imbalance were suggestive of a central vestibulopathy. Gadolinium-enhanced brain magnetic resonance imaging (MRI) revealed enhanced lesions in the brainstem (Fig. 1D-G). Therefore, a presumptive diagnosis of RHS with brainstem involvement was made based on the clinical and neuroradiologic findings. The addition of intravenous administration of dexamethasone and acyclovir for 7 days improved all of the symptoms except the facial paralysis.

Patients with RHS often suffer from severe vertigo and/or otologic symptoms since the vestibulocochlear nerve is the most frequently involved cranial nerve.<sup>1,2</sup> Accordingly, patients with RHS and vertigo typically present with acute peripheral vestibulopathy. However, RHS can be complicated by rare but serious central vestibular disorders involving the brainstem and/or cerebellum.<sup>3,4</sup> Identifying central signs was essential for the correct diagnosis in our patient because she required additional treatment after discerning the central lesion.<sup>1</sup>

Our patient demonstrated clinical and laboratory features of combined peripheral and central vestibulopathies. A previous study of the etiologies and diagnoses of 55 patients with combined peripheral and central vestibulopathies identified only 1 case of RHS.<sup>4</sup> That patient exhibited GEN as a central sign and other presentations consistent with unilateral peripheral vestibulopathy, but brain MRI was normal, in contrast to our case. There have been few studies of the neuro-otologic and vestibular evaluations in RHS with brainstem involvement.<sup>1</sup>

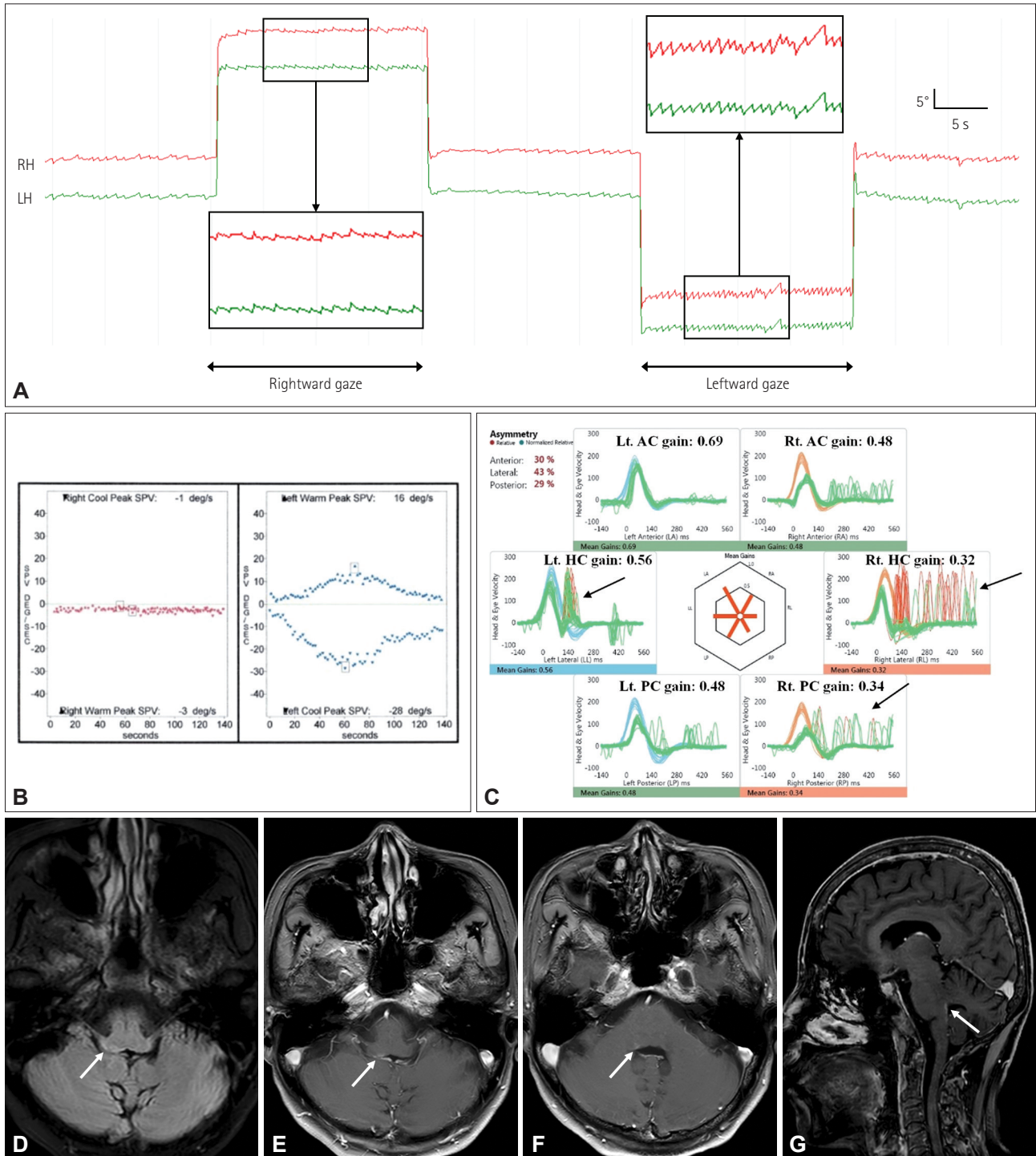
Dissociation in the VOR between different stimulation frequencies could be a significant feature of combined vestibulopathy.<sup>4</sup> Our patient showed ipsilesional (unilateral) canal paresis in the caloric test (low-frequency VOR), but bilaterally decreased VOR gains with abnormal CS in the video HITs (high-frequency VOR). In cases involving central vestibular structures including the vestibular nucleus, nucleus prepositus hypoglossi (NPH), or flocculus, a disruption in neural interconnection between the structures may result in a reduction in VOR gains

© This is an Open Access article distributed under the terms of the Creative Commons Attribution Non-Commercial License (<https://creativecommons.org/licenses/by-nc/4.0>) which permits unrestricted non-commercial use, distribution, and reproduction in any medium, provided the original work is properly cited.

**Received** May 31, 2021  
**Revised** July 19, 2021  
**Accepted** July 19, 2021

## Correspondence

Seung-Han Lee, MD, PhD  
Department of Neurology,  
Chonnam National University Hospital,  
42 Jebong-ro, Dong-gu,  
Gwangju 61469, Korea  
**Tel** +82-62-220-6274  
**Fax** +82-62-228-3461  
**E-mail** nrshlee@chonnam.ac.kr



**Fig. 1.** Neuro-otologic evaluations and neuroimaging of the patient. A: Video-oculography reveals spontaneous left-beating nystagmus, which is augmented during leftward gaze (mean SPV=2.5 °/s, 16 °/s during leftward gaze). However, the direction of nystagmus shifts to the right side when the patient looks toward the right, which is consistent with gaze-evoked nystagmus. B: The bithermal caloric test indicates canal paresis in the right ear (90% weakness calculated using Jongkees' formula). C: The video head impulse test shows reductions in the VOR gain for all six semicircular canals (predominantly right-sided impairment) with catch-up saccades in the right horizontal, right posterior, and left horizontal canals (black arrows). D-G: Fluid-attenuated inversion recovery (D) and gadolinium-enhanced (E-G) brain magnetic resonance imaging demonstrates high signal intensities with enhancement in the right dorsal pons and medulla along the caudal floor of the fourth ventricle (white arrows). Reduced VOR gains were defined as <0.8 and <0.7 for the horizontal and vertical canals, respectively. AC, anterior canal; HC, horizontal canal; LH, horizontal position of the left eye; Lt., left; PC, posterior canal; RH, horizontal position of the right eye; Rt., right; SPV, slow-phase velocity; VOR, vestibulo-ocular reflex.

without obvious overt saccades during contralesional head impulses. This finding may be useful for distinguishing from bilateral vestibulopathy.<sup>5</sup> In addition to ipsilesional CS in bedside HITs, video HITs displayed bilateral CS in our patient. It is noteworthy that the CS of the contralesional horizontal canal were mostly covert saccades, which were barely noticeable without the quantitative HITs. Thus, clinicians should pay close attention to CS while performing and interpreting bedside HITs without using a quantitative HIT device.<sup>4</sup>

The anatomical distribution of RHS with brainstem involvement usually ranges from the dorsolateral medulla to the caudal pons, including the ipsilateral solitary nucleus, spinal trigeminal nucleus and tract, and vestibular nucleus.<sup>3</sup> The pathomechanism of central nervous system (CNS) involvement of the varicella zoster virus (VZV) in RHS is still unclear. The retrograde transsynaptic spread of VZV through the geniculate ganglion has been hypothesized as a mechanism, based on cerebral spinal fluid (CSF) pleocytosis and positivity in polymerase chain reaction assays for CSF VZV.<sup>2,3</sup>

Several critical structures that control eye movement are located along the dorsal medulla, including the vestibular nuclei, NPH, and inferior cerebellar peduncle.<sup>6</sup> Lesions involving the vestibular nucleus may manifest with GEN, which is more prominent during contralesional gaze, bilaterally impaired HITs, and features suggestive of unilateral peripheral vestibulopathy.<sup>6</sup> The present neuro-otologic evaluations appeared to indicate the vestibular nucleus as the main culprit structure in our patient.

A previous study found various time intervals (12–27 days) between the onset of facial paralysis and the detection of brainstem involvement on brain MRI.<sup>3</sup> Moreover, it has been reported that patients experience worsening or progressive neurologic deficits several weeks after the onset of facial paralysis.<sup>3</sup> Our patient developed spinning vertigo approximately 10 days after a diagnosis of RHS. The temporal evolution of the symptoms and signs and the considerable time interval between the onset of facial paralysis and central vestibulopathy were probably indicative of viral spread into the CNS after reactivation.

RHS can present as combined peripheral and central vestibulopathies by virtue of brainstem involvement. Meticulous neuro-otologic evaluations for detecting hidden central vestibular signs are warranted to ensure proper diagnosis and better outcomes in patients with RHS.

### Ethics Statement

This study was performed in accordance with the recommendations of the Institutional Review Board of the Chonnam National University Hospital (Gwangju, South Korea) (IRB no. CNUH-EXP-2021-369). The patient provided written informed consent in accordance with the Declaration of Helsinki.

### Availability of Data and Material

Data sharing not applicable to this article as no datasets were generated or analyzed during the study.

### ORCID iDs

Jae-Myung Kim	<a href="https://orcid.org/0000-0003-0483-4179">https://orcid.org/0000-0003-0483-4179</a>
Kyung Wook Kang	<a href="https://orcid.org/0000-0001-9362-8670">https://orcid.org/0000-0001-9362-8670</a>
Hyong-Ho Cho	<a href="https://orcid.org/0000-0002-1331-4039">https://orcid.org/0000-0002-1331-4039</a>
Man-Seok Park	<a href="https://orcid.org/0000-0002-0637-5394">https://orcid.org/0000-0002-0637-5394</a>
Seung-Han Lee	<a href="https://orcid.org/0000-0002-4410-646X">https://orcid.org/0000-0002-4410-646X</a>

### Author Contributions

Conceptualization: Jae-Myung Kim, Hyong-Ho Cho, Seung-Han Lee. Data curation: Kyung Wook Kang, Hyong-Ho Cho. Formal analysis: Kyung Wook Kang, Man-Seok Park, Seung-Han Lee. Investigation: Seung-Han Lee. Project administration: Seung-Han Lee. Supervision: Seung-Han Lee. Writing—original draft: Jae-Myung Kim. Writing—review & editing: Kyung Wook Kang, Hyong-Ho Cho, Man-Seok Park, Seung-Han Lee.

### Conflicts of Interest

The authors have no potential conflicts of interest to disclose.

### Funding Statement

This study was supported by a grant (BCRI20050) from Chonnam National University Hospital Biomedical Research Institute.

## REFERENCES

- Kim JH, Chung PW, Oh S, Hong SB, Chung CS, Jung CW, et al. Ramsay Hunt syndrome complicated by a brainstem lesion. *J Clin Virol* 2007;39:322-325.
- Corral C, Quereda C, Muriel A, Martínez-Ulloa PL, González-Gómez FJ, Corral Í. Clinical spectrum and prognosis of neurological complications of reactivated varicella-zoster infection: the role of immunosuppression. *J Neurovirol* 2020;26:696-703.
- Inagaki A, Toyoda T, Mutou M, Murakami S. Ramsay Hunt syndrome associated with solitary nucleus, spinal trigeminal nucleus and tract, and vestibular nucleus involvement on sequential magnetic resonance imaging. *J Neurovirol* 2018;24:776-779.
- Choi SY, Kim HJ, Kim JS. Chasing dizzy chimera: diagnosis of combined peripheral and central vestibulopathy. *J Neurol Sci* 2016;371:69-78.
- Choi JY, Kim HJ, Kim JS. Recent advances in head impulse test findings in central vestibular disorders. *Neurology* 2018;90:602-612.
- Kim HJ, Lee SH, Park JH, Choi JY, Kim JS. Isolated vestibular nuclear infarction: report of two cases and review of the literature. *J Neurol* 2014;261:121-129.