



Maxillo-mandibular Defect Reconstruction with Bilateral Free Fibula Flaps with Dental Implant Placement and Immediate Loading: A Case Report of the Three-team Approach

David Nazarian, MD, PhD¹ Aleksei Dikarev, MD, PhD¹ Mikhail Mokhirev, MD, PhD¹
 Georgy Zakharov, MD¹ Alexander Fedosov, MD¹ Maksim Potapov, MD¹
 Mikhail Chernenkiy, BSE² Yuriy Vasilev, MD, PhD³ Grigoriy Kyalov, MD²
 Saniyat Chausheva, MD, PhD⁴ Arbak Khachatryan, MD¹ Artur Tevosyan, MD⁵
 Gevorg Arakelyan, MD⁵

¹Maxillofacial and Reconstructive Surgery Department, FSBI NMRCO FMBA, Moscow, Russia

²Maxillofacial and Reconstructive Surgery Department, NK Clinic, Moscow, Russia

³Radiology Department, Research and Practical Clinical Center of Diagnostics and Telemedicine Technologies, Moscow, Russia

⁴Plastic Surgery Department, FSBI NMRCO FMBA, Moscow, Russia

⁵Department of clinical medicine, International School "Medicine of the Future", Sechenov University

Address for correspondence Arakelyan Gevorg, MD, International school "Medicine of the Future," Sechenov University, 2 Bol'shaya Pirogovskaya Street, Moscow 119435, Russia (e-mail: dr.gevorgarakelyan@gmail.com).

Arch Plast Surg 2022;49:652–655.

Abstract

Patients with advanced malignant tumors, including both jaws, is a challenging task for a head and neck surgeon. Current treatment landscape demonstrates good functional, anatomical, and aesthetic results in patients who could previously receive only palliative care. The extensive tissue defects resulting from oncological resections in the head and neck region require immediate reconstruction due to the exposure of vital structures and their contact with the external environment. A patient was operated using a three-team multidisciplinary approach involving simultaneous work of three specialized teams of maxillofacial and reconstructive microsurgeons, as well as an implantologist and a prosthodontist. This approach allowed simultaneous tumor resection with subsequent reconstruction of the intraoperative defect involving bilateral harvesting of two revascularized free fibular osteomusculocutaneous flaps with dental implantation and simultaneous rehabilitation of dentition with crowns.

Keywords

- ▶ jaw defect
- ▶ fibula flap
- ▶ bilateral harvesting
- ▶ case report
- ▶ three-team approach

Introduction

Around 41 to 45% of submandibular salivary gland tumors are malignant, the most common of which are mucoepidermoid

carcinoma, adenoid cystic carcinoma, and adenocarcinoma.¹ Radical surgical excision followed by adjuvant radiotherapy is the treatment of choice for well-differentiated salivary gland tumors with higher T stage.²

received

December 16, 2021

accepted after revision

February 17, 2022

DOI <https://doi.org/10.1055/s-0042-1756350>.

ISSN 2234-6163.

© 2022. The Korean Society of Plastic and Reconstructive Surgeons. All rights reserved.

This is an open access article published by Thieme under the terms of the Creative Commons Attribution-NonDerivative-NonCommercial-License, permitting copying and reproduction so long as the original work is given appropriate credit. Contents may not be used for commercial purposes, or adapted, remixed, transformed or built upon. (<https://creativecommons.org/licenses/by-nc-nd/4.0/>)

Thieme Medical Publishers, Inc., 333 Seventh Avenue, 18th Floor, New York, NY 10001, USA

The operation involves an extensive en bloc resection followed by a modified radical lymph node dissection. Such resection leaves an extensive defect in soft and hard tissues, which should be reconstructed with free revascularized flaps to restore the structural and functional integrity of this anatomical region. Reconstruction of critical-size jaw defects with a free revascularized bone autograft (in particular, a fibular flap) is currently the gold standard in head and neck surgery.³

Here, we report a case of patient with malignant myoepithelioma, who underwent a radical en bloc resection of both jaws with immediate reconstruction using two fibular bone flaps. During reconstruction dental implant placement and immediate loading on prefabricated flaps were made. In this case we applied a three-team approach for parallel performance of the steps of operation.

Case

In 2014, a 37-year-old female patient was diagnosed with pleomorphic adenoma of right submandibular gland. The extirpation of salivary gland was performed.

In 2015, the patient had a recurrence of tumor. A second surgical procedure was performed to remove the tumor, after which the patient was put under follow-up.

On January, 2018, the patient discovered the presence of a tumor in the right carotid triangle and in the right submandibular region. The patient went to the local oncological hospital in March. A preliminary diagnosis was established: recurrence of pleomorphic adenoma of the right submandibular salivary gland. On April 05, 2018, a biopsy was performed from a tumor of the right submandibular salivary gland. The patient was diagnosed with cancer of the submandibular salivary gland with spread to the right half of the parapharyngeal space and destruction of the upper and lower jaws with regional metastases to right cervical lymph nodes, T4acN1M0, stage IVa. The tumor measured 76 × 46 × 63 mm. On the multidisciplinary consilium, the decision was made to perform four courses of polychemotherapy - doxorubicin 100 mg (60 mg/m²) + cisplatin 60 mg (40 mg/m²). During chemotherapy, the patient showed no response with an increase in tumor size (78 × 49 × 70 mm). Later, a course of radiation therapy (cumulative dose - 38 Gy) was performed with concurrent chemotherapy with paclitaxel (100 mg daily for 3 weeks), but no significant response was observed. In November, 2018, the patient visited our surgical center complaining on a tumor in the right submandibular and retromandibular regions, on the lateral surface of the neck and in the oral cavity, third-degree trismus, pain, tissue disintegration, and periodic recurrent bleeding (► **Figs. 1A** and **2A**)

The clinical examination included photo anthropometry, contrast-enhanced CT of the maxillofacial region, contrast-enhanced maxillofacial MRI, PET/CT, and histological examination (► **Fig. 3A**). The following diagnosis was made: malignant myoepithelioma of the right submandibular salivary gland with invasion and destruction of the maxilla and mandible on the right and with regional metastases to right

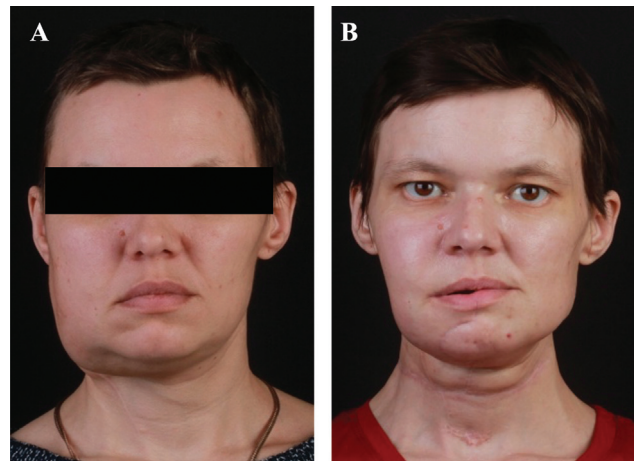

Fig. 1 Anthropophotometry. (A) Tumor in the lower and upper jaws on the right, in the submandibular region, on the lateral surface of the neck, a scar is visible from the previous surgical resection; (B) Anthropophotometry 6 months after the treatment.

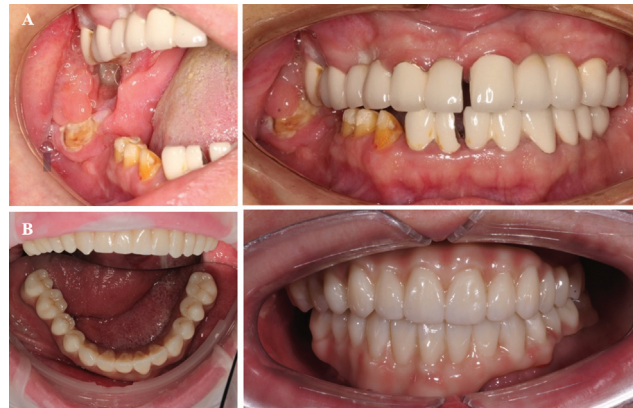

Fig. 2 (A) The tumor spread in the oral cavity. (B) 1 year postoperatively.

cervical lymph nodes, T4acN1M0, stage IVa, grade group II. Tumor size was 52 × 53 × 82 mm.

The following surgery was considered for the patient: right-sided oropharyngeal en bloc resection of the maxilla and mandible, bilateral-modified extended lymph node dissection with simultaneous reconstruction with two free revascularized fibular osteomusculocutaneous autotransplants and dental implantation with immediate loading.

The surgical procedure was performed under endotracheal anesthesia. The patient underwent the lower tracheostomy (The Björk technique). The first team of surgeons made a collar-shaped incision along the cervical fold, passing into the submental region and the lower lip. Modified radical bilateral cervical type III lymphadenectomy was performed from this approach. The external carotid artery, the facial arteries and veins, and the external jugular vein were prepared. A vertical mandibulotomy between 3.1 and 4.1 teeth was performed, and a fragment of the right half of the lower jaw was isolated. According to the preoperative planning model, an osteotomy was performed at the level of right condylar process. The next step was the resection of the

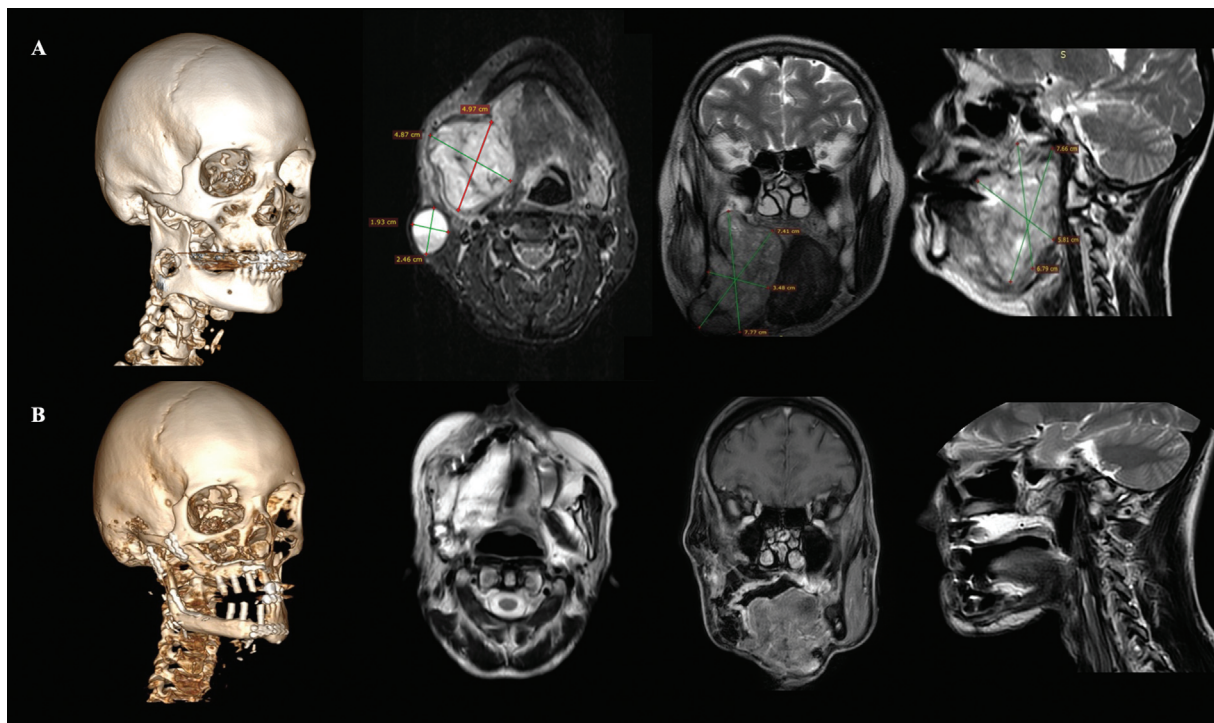


Fig. 3 CT and MRI reconstruction. (A) The tumor of the right submandibular region, half of the floor of oral cavity, peripharyngeal space, with destruction of the lower and upper jaw on the right. (B) CT and MRI imaging 6 months postoperatively. CT, computed tomography; MRI, magnetic resonance imaging.

tumor of parapharyngeal space and the right upper jaw. Oropharyngeal en bloc resection was performed. Adequacy of the surgical resection is confirmed by frozen section of margins.

Simultaneously, two teams of surgeons harvested free fibular osteocutaneous flaps and their subsequent modeling according to the intraoperative template with dental implantation and placement of temporary crowns. According to preliminary marking, skin islets were also isolated (10 × 5 cm on the right and 5.5 × 5 cm on the left leg). Modeling, implantation, and placement of the prosthodontic construction were performed without division of the vascular pedicle. The final osteosynthesis of the bones of the «neomaxilla» and «neomandible» was performed under the control of occlusal stability of implant-supported bridges.

To provide vascular supply of maxilla, the anastomoses were applied between the right external carotid and peroneal arteries, the right external jugular vein and peroneal veins. For the mandible vascularization, the anastomoses were made between the left facial and peroneal arteries and the left external jugular and peroneal veins. The lateral surface of the pharynx and the retromolar area were reconstructed using the skin islets of both flaps.

The entire surgical procedure lasted 18 hours. During the procedure, the patient lost 1,500 mL of blood, and the urine output was 1300 mL. Over the period of the manipulation, 640 mL of donor blood was transfused to the patient.

A week later, the endoscopic revision of wounds was made. The wound healed without signs of inflammation or swelling of the vestibule and vocal cords.

Six-month follow-up included CT and MRI of the maxillofacial region, CT of the chest, PET CT, ultrasound scanning of the soft tissues of the neck, abdominal, and pelvic organs (►Figs. 1B, 2B, and 3B).

On December 3rd, 2020, the patient complained of deformations of middle and low thirds of face. The defect is repaired with inguinal fold autodermal and palatal mucous grafts. Dental implantation (Renova 3.75 × 11.5 mm. Torque 50 N cm) of 21, 23 teeth was performed.

After surgical reconstruction, the chewing ability of the patient was changed significantly. This is primarily due to the limitation of the function of masticatory muscles, as well as restriction of tongue movements. The patient eats food predominantly with liquid consistency. The patient is able to open her mouth up to 40 mm. The patient has no difficulty with breathing and swallows freely. Bilateral harvesting of fibula flaps slightly affected the movement of patient. The patient undergoes diagnostic CT/MRI every 6 months. Three

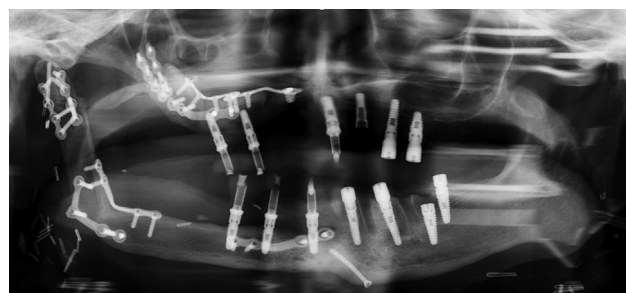


Fig. 4 Panoramic X-ray 3 years postoperatively.

years after surgery the patient has no recurrence of the tumor (→ Fig. 4).

Discussion

Jaw reconstruction using two fibular autografts with simultaneous implantation in patients with a defect in both jaws allows avoiding additional, delayed surgical procedures that prolong treatment to more than a year.⁴ Besides, one-stage implantation with temporary prosthetics allows the patient to avoid psychological stress of feeling inferior due to the absence of dentition. The temporary prosthetics ensures the patient's adaptation to new occlusion and contributes to the fastest possible speech recovery.

After adequate rehabilitation, the patient was able to walk steadily and maintain balance. The use of two fibula flaps in patients with extensive jaw defects is justified, since it does not increase morbidity.⁵

Reconstructive operations of a similar complexity require the participation of various specialists in maxillofacial surgery, reconstructive microsurgery, dentistry, and prosthodontist. For the first time, the simultaneous work of several surgical teams was demonstrated during an esophageal resection and reconstruction operation.⁶ Freiberg and Bartlett pioneered this approach in head and neck reconstruction.⁷ Today, the simultaneous work of several surgical teams is the standard for extensive surgical interventions.⁸

Reconstructive operations in the head and neck region could be quite lengthy.⁹ An increase in surgery time positively correlates with the incidence of postoperative complications.¹⁰ In particular, the probability of reoperations increases three times after surgical interventions lasting more than 10 hours.¹¹

The multidisciplinary team approach has undeniable benefits for both patient and medical staff. It allows reducing the time spent by the patient on operating table and, accordingly, decreasing the risk of anesthesia.^{12,13} Also, reducing the duration of the operation through simultaneous work of several surgical teams results in lower likelihood of flap loss.⁹ It should be added that this method significantly reduces the load on each surgeon and improves the efficiency of the entire surgical team (→ Fig. 4). This case report demonstrates that the simultaneous work of three surgical teams together with an implantologist and a prosthodontist is an effective approach to the reconstruction of extensive head and neck defects. This method expands the indications and scope of surgical interventions, in particular, through the use of computer planning, auxiliary surgical template printing, harvesting several revascularized flaps, and a well-coordinated multiteam approach. Apart from prolonging the life of patients who were previously doomed to palliative care, this surgery organization method ensures efficient and safe functional and anatomical rehabilitation and socialization of patients.

Authors' Contributions

Conceptualization: D.N., A.D., M.M., G.Z., M.C., G.K. Data curation: M.P., S.C., G.A., A.T. Formal analysis: A.K. Meth-

odology: M.M., G.K. Project administration: D.N., A.D., Y.V. Visualization: Y.V., M.C. Writing - original draft: G.A., A.T. Writing - review and editing: D.N., A.K. All authors read and approved the final manuscript.

Ethical Approval

The study was performed in accordance with the principles of the Declaration of Helsinki. Written informed consent was obtained.

Patient Consent

The patient provided written informed consent for the publication and the use of his images.

Funding

None.

Conflict of Interest

None declared.

References

- Guzzo M, Locati LD, Prott FJ, Gatta G, McGurk M, Licitra L. Major and minor salivary gland tumors. *Crit Rev Oncol Hematol* 2010;74(02):134–148
- Licitra L, Karamouzis MV. 2017 ESMO Essentials for Clinicians Head and Neck Cancers. ESMO Press 2017. Chapter 10
- Su T, Fernandes R. Microvascular reconstruction of the mandible: an argument for the fibula osteocutaneous free flap. *Rev Española Cirugía Oral Maxilofac* 2014;36(01):1–8
- Patel A, Harrison P, Cheng A, Bray B, Bell RB. Fibular reconstruction of the maxilla and mandible with immediate implant-supported prosthetic rehabilitation: jaw in a day. *Oral Maxillofac Surg Clin North Am* 2019;31(03):369–386
- Ferrari S, Perlangeli G, Mammi P, et al. Bilateral harvesting of a fibula free flap: assessment of morbidity. *J Craniofac Surg* 2018;29(08):2131–2134
- Nanson EM. Synchronous combined abdomino-thoraco-cervical (oesophagectomy). *Aust N Z J Surg* 1975;45(04):340–348
- Freiberg A, Bartlett GS. Two-team approach to surgery for head and neck cancer. *Can J Surg* 1980;23(01):35–38
- Torabi SJ, Chouairi F, Dinis J, Alperovich M. Head and neck reconstructive surgery: characterization of the one-team and two-team approaches. *J Oral Maxillofac Surg* 2020;78(02):295–304
- Crawley MB, Sweeny L, Ravipati P, et al. Factors associated with free flap failures in head and neck reconstruction. *Otolaryngol Head Neck Surg* 2019;161(04):598–604
- Cheng H, Clymer JW, Po-Han Chen B, et al. Prolonged operative duration is associated with complications: a systematic review and meta-analysis. *J Surg Res* 2018;229:134–144
- Wan M, Zhang JX, Ding Y, et al. High-risk plastic surgery: an analysis of 108,303 cases from the American College of Surgeons National Surgical Quality Improvement Program (ACS NSQIP). *Plast Surg (Oakv)* 2020;28(01):57–66
- Bauermeister AJ, Zuriarrain A, Newman M, Earle SA, Medina MA III. Impact of continuous two-team approach in autologous breast reconstruction. *J Reconstr Microsurg* 2017;33(04):298–304
- Marsh D, Patel NG, Rozen WM, Chowdhry M, Sharma H, Ramakrishnan VV. Three routine free flaps per day in a single operating theatre: principles of a process mapping approach to improving surgical efficiency. *Gland Surg* 2016;5(02):107–114