



# Diagnosis and Treatment of Anterior-Canal Benign Paroxysmal Positional Vertigo: A Systematic Review

Evangelos Anagnostou

Ioanna Kouzi

Konstantinos Spengos

Department of Neurology,  
Eginition Hospital, University of Athens,  
Athens, Greece

**Background and Purpose** In contrast to the posterior- and horizontal-canal variants, data on the frequency and therapeutic management of anterior-canal benign paroxysmal positional vertigo (AC-BPPV) are sparse. To synthesize the existing body of evidence into a systematic review regarding the incidence and treatment of AC-BPPV.

**Methods** Systematic search of medical databases employing predefined criteria, using the term “anterior canal benign paroxysmal positional vertigo.”

**Results** The electronic search retrieved 178 unique citations, 31 of which were considered eligible for further analysis. Analysis of the collected data revealed an estimated occurrence of AC-BPPV among benign paroxysmal positional vertigo patients of 3% (range 1–17.1%). No controlled therapeutic trials could be identified, and so the analysis was focused on uncontrolled case series. Treatment was categorized into three groups: Epley maneuver, Yacovino maneuver, and specific, nonstandard maneuvers described in individual articles. All three categories demonstrated success rates of over 75%, and the overall sample-size-weighted mean was 85.6%.

**Conclusions** The present analysis demonstrated that AC-BPPV comprises about 3% of all BPPV cases. It can be treated safely using the Epley, Yacovino, and other maneuvers with rates of symptom resolution lying in the range of that reported for the other, more frequent canal variants. Multicenter controlled trials are needed in order to develop evidence-based guidelines for the treatment of AC-BPPV.

**Key Words** benign paroxysmal positional vertigo, anterior semicircular canal, repositioning, Epley, yacovino.

## INTRODUCTION

Benign paroxysmal positional vertigo (BPPV) is the most common cause of vertigo, and represents 1% of all patient visits to neurologists and ear, nose, and throat specialists.<sup>1,2</sup> The most frequent form of BPPV is posterior canalolithiasis (PC-BPPV), which has a lifetime prevalence of 2.4%.<sup>2</sup> The effects of various treatment maneuvers have been investigated extensively in prospective studies with adequate patient samples, and have been the subject of detailed systematic reviews and meta-analyses.<sup>3-5</sup> Posterior-canal BPPV reportedly accounts for 80–90% of cases, while lateral-canal BPPV (LC-BPPV), including both canalolithiasis and cupulolithiasis, occurs in 10–20% of patients.<sup>6</sup> However, more recent investigations suggest that the frequency of posterior-canal BPPV has been overestimated, while the prevalence of the horizontal-canal variant has been underestimated, suggesting occurrence frequencies of 60–90% and 10–30%, respectively.<sup>7,8</sup> While only a few studies have assessed the prevalence, diagnosis, and treatment of LC-BPPV, this condition has been the subject of a systematic review.<sup>9</sup>

© This is an Open Access article distributed under the terms of the Creative Commons Attribution Non-Commercial License (<http://creativecommons.org/licenses/by-nc/3.0>) which permits unrestricted non-commercial use, distribution, and reproduction in any medium, provided the original work is properly cited.

**Received** November 17, 2014

**Revised** February 15, 2015

**Accepted** February 16, 2015

### Correspondence

Evangelos Anagnostou, MD  
Department of Neurology,  
Eginition Hospital,  
University of Athens,  
Vas. Sophias Avenue 74,  
Athens 11528, Greece  
**Tel** +302107289291  
**Fax** +302107242020  
**E-mail** granavan@yahoo.com

Anterior-canal BPPV (AC-BPPV) is considered the rarest form of semicircular canalolithiasis, with a postulated frequency of 1–2%.<sup>6</sup> Its low incidence contrasts with the clinical importance of its most prominent characteristic, positional down-beating nystagmus, which also occurs as central positional nystagmus associated with various brainstem and cerebellar lesions, and may indicate a sinister pathology.<sup>10–12</sup> The down-beating nystagmus in AC-BPPV is often accompanied by a less pronounced torsional component, which is thought to indicate the affected side. When moving the patient from a sitting to a lying position with the head straight and bent backwards as far as possible, a clockwise torsional nystagmic component would suggest right-side AC-BPPV. However, the torsional component is often difficult to recognize by visual inspection alone. Ideally, sophisticated three-dimensional scleral-coil or video-oculographic recordings are necessary to identify the precise direction of the nystagmic fast phases.<sup>13</sup>

In contrast to the posterior- and horizontal-canal variants, data on the frequency, diagnostic techniques, and therapeutic maneuvers for AC-BPPV are sparse, and many studies have investigated only a few patients. The present study conducted a systematic review of studies describing the incidence, applied diagnostic procedures, and the treatment options of this rare form of canalolithiasis.

## METHODS

The Medline (PubMed) and EMBASE databases were searched for articles using the term “anterior canal benign paroxysmal positional vertigo,” without restriction of publication date or patient age. Reference lists from retrieved articles were also searched manually for relevant publications on AC-BPPV that were not included in the lists created through PubMed and EMBASE. Research abstracts from meeting proceedings or unpublished studies were not included. When necessary, corresponding authors were contacted by e-mail in order to complete the published data. The search was last updated in July 2014.

The title and abstract of all of the articles yielded by the search were screened by two independent reviewers (E.A. and I.K.) and selected using predetermined criteria. These criteria excluded papers that were single case reports, were not in English, lacked original patient data, or were duplicated data published in other included papers. Due to the rarity of the syndrome, studies with small numbers of subjects were not excluded. Furthermore, preconditions regarding the kind of maneuver used for diagnosis or treatment were not established. At the abstract level, concordance was mandated for reason of exclusion; any disagreement regarding the acceptability of a particular study was resolved by discus-

sion. Full-text screening was applied to all abstracts considered eligible or possibly eligible by at least one reviewer.

Information was extracted at the subject level as provided in the included articles, and sample-size-weighted means were calculated where appropriate. Data were analyzed using SPSS version 15.0 (SPSS Inc., Chicago, IL, USA).

## RESULTS

The database searches yielded 178 unique citations and hand search added 4 articles. The oldest English-language article found was published in 1996 by Herdman and Tusa,<sup>14</sup> and the most recent was published in 2014 by Califano et al.<sup>15</sup> Full-text review resulted in the exclusion of 147 articles; 35 articles were thus considered eligible (Fig. 1). The percentage agreement among the two reviewers regarding article inclusion was high (97.8%), yielding an interrater agreement kappa value of 0.93. Two papers were unretrievable despite multiple attempts from various sources. More detailed reading of the articles revealed that three studies did not provide either absolute or relative (anterior canal/entire BPPV sample) numbers of patients with AC-BPPV,<sup>16–18</sup> while in another article anterior canalolithiasis was described only in cases with simultaneous multiple canal involvement.<sup>19</sup> These 4 articles were not considered for further analysis, leaving 31 articles in the final data set (Table 1).

### Studies

There were no randomized controlled studies among the retrieved articles. The data were analyzed prospectively in 12 studies, and retrospectively in 14; the direction of the analysis (i.e., prospective vs. retrospective) was not clear in 5 arti-

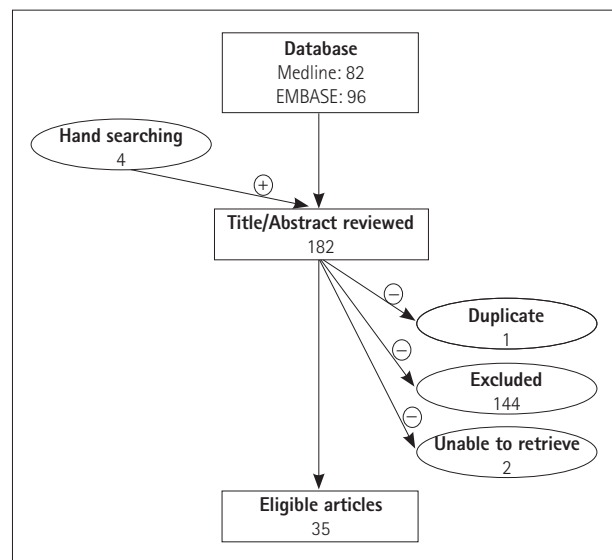


Fig. 1. Article search and selection algorithm.

Table 1. Articles selected for inclusion in chronological order

Study	Year of publication	Pro-(p) or retrospective (r)	Design*	No. of AC-BPPV patients	Percentage of AC-BPPV <sup>†</sup>	Therapeutic maneuver	Success rate (%)	Evidence <sup>‡</sup>
Herdman and Tusa <sup>14</sup>	1996	r	ne	2	na	nc	50	5
Honrubia et al. <sup>20</sup>	1999	p	ne	4	1.4	Epley	50	5
Mosca and Morano <sup>21</sup>	2001	nc	ne	1	1	Other	100	5
Bertholon et al. <sup>10</sup>	2002	nc	ne	12	nc	nc	nc	5
Korres et al. <sup>22</sup>	2002	r	ne	2	1.6	Epley	50	5
Rahko <sup>23</sup>	2002	nc	ne	57	nc	Other	92.3	5
Crevits <sup>24</sup>	2004	p	e	2	na	Other	100	5
Lopez-Escamez et al. <sup>25</sup>	2005	p	ne	12	17.1	Epley	75	5
Prokopakis et al. <sup>26</sup>	2005	p	ne	12	2	Epley	nc	5
Kim et al. <sup>27</sup>	2005	p	e	30	na	Other	96.7	4
Cakir et al. <sup>28</sup>	2006	r	ne	2	1.2	na	na	5
Lopez-Escamez et al. <sup>29</sup>	2006	p	e	14	na	Epley	71.4	5
Moon et al. <sup>30</sup>	2006	r	ne	38	2.2	Epley	76.2	5
Lorin <sup>31</sup>	2007	r	e	16	na	Other	100	5
Celebisoy et al. <sup>32</sup>	2008	p	ne	2	1.4	Epley	100	5
Yacovino et al. <sup>33</sup>	2009	r	e	13	2.3	Yacovino	100	5
Ogawa et al. <sup>34</sup>	2009	r	e	4	na	nc	nc	5
Chung et al. <sup>35</sup>	2009	r	ne	17	2.9	na	na	5
Korres et al. <sup>36</sup>	2010	r	e	5	na	Other	60	5
Gananç et al. <sup>37</sup>	2010	r	ne	4	3.3	nc	nc	5
Dlugaiczky et al. <sup>38</sup>	2011	r	ne	3	4.8	na	na	5
De Stefano et al. <sup>39</sup>	2011	r	ne	10	2.4	na	na	5
Casani et al. <sup>40</sup>	2011	r	e	18	na	Other	94.4	5
Pérez et al. <sup>41</sup>	2012	p	ne	4	5.8	Epley	75	5
Soto-Varela et al. <sup>42</sup>	2013	p	ne	32	5.2	Epley	79.4	5
Prokopakis et al. <sup>43</sup>	2013	p	ne	20	2.1	Epley	nc	5
Park et al. <sup>44</sup>	2013	r	ne	41	6.8	Epley	87.8	5
Imbaud-Genieys <sup>45</sup>	2013	nc	e	20	1.4	Epley	95	5
Cambi et al. <sup>46</sup>	2013	nc	e	50	14.5	na	na	5
Marques et al. <sup>47</sup>	2014	p	ne	3	5.3	Yacovino	100	5
Califano et al. <sup>15</sup>	2014	p	e	11	1.2	Yacovino	36.4	5

\*AC: Focused exclusively on patients with AC-BPPV, G: describing AC-BPPV within a greater cohort of posterior, lateral and anterior canal BPPV, <sup>†</sup>Fraction of AC-BPPV to the entire BPPV sample (if applicable), <sup>‡</sup>Level of Evidence according to the Oxford Centre for Evidence-Based Medicine 2011 Levels of Evidence.  
e: exclusively, Epley: reverse Epley repositioning maneuver, na: not applicable, nc: not clear, ne: non-exclusively, other: therapeutic maneuver described by the authors of a specific study and used only in this study, Yacovino: "deep head hanging maneuver" of Yacovino et al.<sup>33</sup>

cles. In 21 articles AC-BPPV cases were reported among other (posterior- and lateral-canal) BPPV patients, while 10 studies focused exclusively on an AC-BPPV cohort.

### Epidemiological data

Twenty-one studies presented AC-BPPV cases as part of a larger cohort of BPPV patients, thereby allowing estimation of the relative frequency of anterior canalolithiasis. The frequencies ranged from 1%<sup>21</sup> to 17.1%.<sup>25</sup> The sample-size-weighted mean estimated from a pooled sample of 9,953 BPPV patients was 3%. Despite the great variation in AC-BPPV frequency across studies, the largest prospective<sup>43</sup> and largest retrospective<sup>30</sup> studies yielded similar results (2.2% and 2.1%, respectively). In all studies the diagnosis of AC-BPPV was based on the occurrence of downbeat-torsional nystagmus triggered by the Dix-Hallpike maneuver or straight head hanging.

### Treatment

Information regarding the therapeutic maneuvers for AC-BPPV was provided in 20 articles. These data were inhomogeneous, since the prior identification of the affected side, the applied repositioning maneuver, the number of maneuver repetitions, and the method of evaluating therapeutic success varied significantly between the studies. For data synthesis it appeared meaningful to categorize treatment maneuvers into three groups: Epley (application of the Epley or reverse Epley maneuver), Yacovino (application of the maneuver described by Yacovino et al.<sup>33</sup>), and “other” (in which the investigators described their own, nonstandard therapeutic maneuvers). To the best of our knowledge, the nonstandard maneuvers used in the studies assigned to “other” group have not been described in any previous or subsequent articles. Further categorization regarding the affected side, maneuver repetitions, and method of success evaluation was not possible due to the smallness of the sample.

Overall, the available data on 312 patients (pooled from all 20 studies) yielded a sample-size-weighted mean success rate of 85.6%. The Epley or reverse Epley maneuver was applied in ten studies, the Yacovino maneuver in three studies, and the remaining seven articles described other, nonstandard maneuvers. The mean success rate was high in all three categories: 75.9% for Epley, 78.8% for Yacovino, and 92% for other. Inhomogeneities in study design did not allow formal statistical comparisons between the three groups.

Of particular interest were studies that were 1) prospective and 2) focused exclusively on an AC-BPPV sample; four studies fulfilled these criteria.<sup>15,24,27,29</sup> Crevits<sup>24</sup> used a prolonged forced position procedure that required a 24-h hospital stay during which the patient was in the supine position with the head bent forward and supported by a pulley sys-

tem. The author reported a 100% recovery rate in his small sample ( $n=2$ ). Kim et al.<sup>27</sup> described a repositioning procedure that requires prior knowledge of the affected side and bears similarities to both the reverse Epley and the Yacovino maneuvers.<sup>33</sup> Their procedure cured 29 out of 30 patients (96.7%). Lopez-Escamez et al.<sup>29</sup> employed a modified Epley maneuver that was effective in 10 out of 14 subjects (71.4%). Finally, Califano et al.<sup>15</sup> reported more modest results (4 of 11, 36.4%) obtained using the Yacovino maneuver.

Of practical interest was a comparison of maneuvers requiring prior knowledge of the affected side versus side-independent maneuvers. The first category includes mainly the Epley maneuver (i.e., either the classical Epley procedure or the reverse Epley maneuver, which starts from the non-affected side). Nonetheless, it was difficult to identify the exact canalith repositioning technique from the reviewed papers, since most authors neglected to state whether they used the ipsilesional or the reverse Epley maneuver.

Four articles were identified that explicitly presented results following the Epley maneuver starting from the ipsilesional side,<sup>25,29,32,45</sup> and two articles were retrieved that reported on canalith repositioning procedures starting from the contralateral side (the reverse Epley maneuver).<sup>27,44</sup> The sample-size-weighted mean success rates of these two procedures were 83.3% and 91.5%, respectively. On the other hand, pooled data from nonlateralizing maneuvers (e.g., Yacovino<sup>15,33,47</sup> and Crevits, or Crevits variants<sup>24,40</sup>) yielded a sample-size-weighted mean clearance rate of 82.9%. Hence, maneuvers that do not require identification of the affected labyrinth demonstrate sufficiently high success rates.

## DISCUSSION

The incidence of AC-BPPV was examined in this review. Furthermore, data regarding the therapeutic maneuvers used to resolve the issue were obtained, and their efficacy was assessed. Interest in this particular form of BPPV is relatively recent, since no relevant studies have been reported prior to 1996. Most of the included articles reported on small case series, and 12 out of 31 studies examined patients in a prospective manner. All studies reported up to 2004 examined small series or single cases of AC-BPPV among larger samples of BPPV patients. Crevits<sup>24</sup> was the first to publish exclusively on AC-BPPV, although only in two patients. Kim et al.<sup>27</sup> presented the first data on a larger cohort ( $n=30$ ) in a prospective study in which exclusively AC-BPPV patients were recruited. At the time of writing (July 2014), no other AC-BPPV-focused, prospective studies on a comparable number of patients have been published. Hence, the quality of the Kim et al.<sup>27</sup> study ranks as the best among the 31 articles included

in this systematic review; however, that study is still of insufficient quality since it did not employ a control group or a sham maneuver.

Overall, the occurrence of AC-BPPV among BPPV populations after data synthesis was 3%. Six articles cite AC-BPPV frequencies of >5%,<sup>25,41,42,44,46,47</sup> with two studies presenting extreme values of 14.5% and 17.1%.<sup>25,46</sup> However, the largest prospective<sup>43</sup> and retrospective<sup>30</sup> studies, analyzing 965 and 1692 BPPV subjects, respectively, estimated the AC-BPPV frequency to be near 2% (i.e., much closer to the frequency calculated for the present pooled analysis). The frequencies of PC-BPPV were 88%<sup>43</sup> and 61%<sup>30</sup> in these two studies, whereas horizontal-canal involvement occurred in 10% and 32% of the samples, respectively. Moon et al.<sup>30</sup> also observed a frequency of 5% for mixed canal involvement.

The treatment of PC- and LC-BPPV has been investigated extensively in prospective randomized controlled trials. Studies of posterior canalolithiasis have demonstrated symptom resolution in 75.9–95% of cases,<sup>48–55</sup> with the exception of the study of Blakley, who found no difference in outcome between patients treated with the canalith repositioning maneuver and controls.<sup>56</sup> The success rates of the Epley and Semont maneuvers are similar, with no study thus far showing a significant difference between the two. Similarly, sham-controlled studies on horizontal canalolithiasis have demonstrated symptom resolution in 61–83.8% of cases with the Gufoni maneuver.<sup>57–59</sup> Notably, Kim et al.<sup>58</sup> compared the Gufoni maneuver to the barbeque maneuver in a sample with the geotropic variant of LC-BPPV, and demonstrated similar efficacies. The lack of controlled trials for AC-BPPV does not allow for direct comparisons with the success rates of posterior- or horizontal-canal maneuvers. Nonetheless, descriptive analysis revealed an overall success rate of 85.6% for AC-BPPV, which is in the same range as for the posterior- and horizontal-canal variants. Most case series applied the Epley (or reverse Epley) maneuver, some authors used self-invented maneuvers, and others applied the Yacovino maneuver. Despite inhomogeneities in study design, all three procedures yielded success rates of >75%. Grouping treatment maneuvers into techniques requiring prior knowledge of the affected side and those that do not yielded analogously high clearance rates.

The available data on AC-BPPV were evaluated herein, including the proportions of patients reporting symptomatic relief as a result of therapy. The present data indicate that AC-BPPV is an uncommon variant of BPPV and can be treated safely and effectively. In the absence of robust evidence-based information on the incidence and treatment options of AC-BPPV, the present synthesis of the existing body of information may facilitate the development of multicenter, con-

trolled therapeutic trials.

### Conflicts of Interest

The authors have no financial conflicts of interest.

### REFERENCES

- Mizukoshi K, Watanabe Y, Shojaku H, Okubo J, Watanabe I. Epidemiological studies on benign paroxysmal positional vertigo in Japan. *Acta Otolaryngol Suppl* 1988;447:67-72.
- von Brevern M, Radtke A, Lezius F, Feldmann M, Ziese T, Lempert T, et al. Epidemiology of benign paroxysmal positional vertigo: a population based study. *J Neurol Neurosurg Psychiatry* 2007;78:710-715.
- Helminski JO, Zee DS, Janssen I, Hain TC. Effectiveness of particle repositioning maneuvers in the treatment of benign paroxysmal positional vertigo: a systematic review. *Phys Ther* 2010;90:663-678.
- Hunt WT, Zimmermann EF, Hilton MP. Modifications of the Epley (canalith repositioning) manoeuvre for posterior canal benign paroxysmal positional vertigo (BPPV). *Cochrane Database Syst Rev* 2012; 4:CD008675.
- van Duijn JG, Isfordink LM, Nij Bijvank JA, Stapper CW, van Vuren AJ, Wegner I, et al. Rapid systematic review of the epley maneuver for treating posterior canal benign paroxysmal positional vertigo. *Otolaryngol Head Neck Surg* 2014;150:925-932.
- von Brevern M. Benign paroxysmal positional vertigo. *Semin Neurol* 2013;33:204-211.
- Fife TD, Iverson DJ, Lempert T, Furman JM, Baloh RW, Tusa RJ, et al. Practice parameter: therapies for benign paroxysmal positional vertigo (an evidence-based review): report of the Quality Standards Subcommittee of the American Academy of Neurology. *Neurology* 2008;70:2067-2074.
- Kim JS, Zee DS. Clinical practice. Benign paroxysmal positional vertigo. *N Engl J Med* 2014;370:1138-1147.
- van den Broek EM, van der Zaag-Loonen HJ, Bruinjes TD. Systematic review: efficacy of gufoni maneuver for treatment of lateral canal benign paroxysmal positional vertigo with geotropic nystagmus. *Otolaryngol Head Neck Surg* 2014;150:933-938.
- Bertholon P, Bronstein AM, Davies RA, Rudge P, Thilo KV. Positional down beating nystagmus in 50 patients: cerebellar disorders and possible anterior semicircular canalolithiasis. *J Neurol Neurosurg Psychiatry* 2002;72:366-372.
- Anagnostou E, Mandellos D, Limbitaki G, Papadimitriou A, Anastasopoulos D. Positional nystagmus and vertigo due to a solitary brachium conjunctivum plaque. *J Neurol Neurosurg Psychiatry* 2006;77: 790-792.
- Anagnostou E, Varaki K, Anastasopoulos D. A minute demyelinating lesion causing acute positional vertigo. *J Neurol Sci* 2008;266:187-189.
- Aw ST, Todd MJ, Aw GE, McGarvie LA, Halmagyi GM. Benign positional nystagmus: a study of its three-dimensional spatio-temporal characteristics. *Neurology* 2005;64:1897-1905.
- Herdman SJ, Tusa RJ. Complications of the canalith repositioning procedure. *Arch Otolaryngol Head Neck Surg* 1996;122:281-286.
- Califano L, Salafia F, Mazzone S, Melillo MG, Califano M. Anterior canal BPPV and apogeotropic posterior canal BPPV: two rare forms of vertical canalolithiasis. *Acta Otorhinolaryngol Ital* 2014;34:189-197.
- Tomaz A, Ganança MM, Ganança CF, Ganança FF, Caovilla HH, Harker L. Benign paroxysmal positional vertigo: concomitant involvement of different semicircular canals. *Ann Otol Rhinol Laryngol* 2009; 118:113-117.
- Kerrigan MA, Costigan MF, Blatt KJ, Mathiason MA, Domroese ME. Prevalence of benign paroxysmal positional vertigo in the young adult population. *PM R* 2013;5:778-785.
- Perez-Fernandez N, Martinez-Lopez M, Manrique-Huarte R. Vestibu-

- lo-ocular reflex in patients with superior semicircular canal benign paroxysmal positional vertigo (BPPV). *Acta Otolaryngol* 2014;134:485-490.
19. Balatsouras DG. Benign paroxysmal positional vertigo with multiple canal involvement. *Am J Otolaryngol* 2012;33:250-258.
  20. Honrubia V, Baloh RW, Harris MR, Jacobson KM. Paroxysmal positional vertigo syndrome. *Am J Otol* 1999;20:465-470.
  21. Mosca F, Morano M. Benign paroxysmal positional vertigo, incidence and treatment. *Ann Otolaryngol Chir Cervicofac* 2001;118:95-101.
  22. Korres S, Balatsouras DG, Kaberos A, Economou C, Kandiloros D, Ferekidis E. Occurrence of semicircular canal involvement in benign paroxysmal positional vertigo. *Otol Neurotol* 2002;23:926-932.
  23. Rahko T. The test and treatment methods of benign paroxysmal positional vertigo and an addition to the management of vertigo due to the superior vestibular canal (BPPV-SC). *Clin Otolaryngol Allied Sci* 2002;27:392-395.
  24. Crevits L. Treatment of anterior canal benign paroxysmal positional vertigo by a prolonged forced position procedure. *J Neurol Neurosurg Psychiatry* 2004;75:779-781.
  25. Lopez-Escamez JA, Molina MI, Gamiz M, Fernandez-Perez AJ, Gomez M, Palma MJ, et al. Multiple positional nystagmus suggests multiple canal involvement in benign paroxysmal vertigo. *Acta Otolaryngol* 2005;125:954-961.
  26. Prokopakis EP, Chimona T, Tsagournisakis M, Christodoulou P, Hirsch BE, Lachanas VA, et al. Benign paroxysmal positional vertigo: 10-year experience in treating 592 patients with canalith repositioning procedure. *Laryngoscope* 2005;115:1667-1671.
  27. Kim YK, Shin JE, Chung JW. The effect of canalith repositioning for anterior semicircular canal canalithiasis. *ORL J Otorhinolaryngol Relat Spec* 2005;67:56-60.
  28. Cakir BO, Ercan I, Cakir ZA, Civelek S, Sayin I, Turgut S. What is the true incidence of horizontal semicircular canal benign paroxysmal positional vertigo? *Otolaryngol Head Neck Surg* 2006;134:451-454.
  29. Lopez-Escamez JA, Molina MI, Gamiz MJ. Anterior semicircular canal benign paroxysmal positional vertigo and positional downbeating nystagmus. *Am J Otolaryngol* 2006;27:173-178.
  30. Moon SY, Kim JS, Kim BK, Kim JI, Lee H, Son SI, et al. Clinical characteristics of benign paroxysmal positional vertigo in Korea: a multicenter study. *J Korean Med Sci* 2006;21:539-543.
  31. Lorin P. Treatment of anterior semi-circular canalithiasis by a sedimentation procedure in a vertical rotatory chair. *Ann Otolaryngol Chir Cervicofac* 2007;124:184-188.
  32. Celebisoy N, Polat F, Akyurekli O. Clinical features of benign paroxysmal positional vertigo in Western Turkey. *Eur Neurol* 2008;59:315-319.
  33. Yacovino DA, Hain TC, Gualtieri F. New therapeutic maneuver for anterior canal benign paroxysmal positional vertigo. *J Neurol* 2009;256:1851-1855.
  34. Ogawa Y, Suzuki M, Otsuka K, Shimizu S, Inagaki T, Hayashi M, et al. Positional and positioning down-beating nystagmus without central nervous system findings. *Auris Nasus Larynx* 2009;36:698-701.
  35. Chung KW, Park KN, Ko MH, Jeon HK, Choi JY, Cho YS, et al. Incidence of horizontal canal benign paroxysmal positional vertigo as a function of the duration of symptoms. *Otol Neurotol* 2009;30:202-205.
  36. Korres S, Riga M, Sandris V, Danielides V, Sismanis A. Canalithiasis of the anterior semicircular canal (ASC): treatment options based on the possible underlying pathogenetic mechanisms. *Int J Audiol* 2010;49:606-612.
  37. Ganança FF, Gazzola JM, Ganança CF, Caovilla HH, Ganança MM, Cruz OL. Elderly falls associated with benign paroxysmal positional vertigo. *Braz J Otorhinolaryngol* 2010;76:113-120.
  38. Długaiczek J, Siebert S, Hecker DJ, Brase C, Schick B. Involvement of the anterior semicircular canal in posttraumatic benign paroxysmal positioning vertigo. *Otol Neurotol* 2011;32:1285-1290.
  39. De Stefano A, Kulamarva G, Citraro L, Neri G, Croce A. Spontaneous nystagmus in benign paroxysmal positional vertigo. *Am J Otolaryngol* 2011;32:185-189.
  40. Casani AP, Cerchiai N, Dallan I, Sellari-Franceschini S. Anterior canal lithiasis: diagnosis and treatment. *Otolaryngol Head Neck Surg* 2011;144:412-418.
  41. Pérez P, Franco V, Cuesta P, Aldama P, Alvarez MJ, Méndez JC. Recurrence of benign paroxysmal positional vertigo. *Otol Neurotol* 2012;33:437-443.
  42. Soto-Varela A, Santos-Perez S, Rossi-Izquierdo M, Sanchez-Sellero I. Are the three canals equally susceptible to benign paroxysmal positional vertigo? *Audiol Neurootol* 2013;18:327-334.
  43. Prokopakis E, Vlastos IM, Tsagournisakis M, Christodoulou P, Kawachi H, Velegrakis G. Canalith repositioning procedures among 965 patients with benign paroxysmal positional vertigo. *Audiol Neurootol* 2013;18:83-88.
  44. Park S, Kim BG, Kim SH, Chu H, Song MY, Kim M. Canal conversion between anterior and posterior semicircular canal in benign paroxysmal positional vertigo. *Otol Neurotol* 2013;34:1725-1728.
  45. Imbaud-Genieys S. Anterior semicircular canal benign paroxysmal positional vertigo: a series of 20 patients. *Eur Ann Otorhinolaryngol Head Neck Dis* 2013;130:303-307.
  46. Cambi J, Astore S, Mandalà M, Trabalzini F, Nuti D. Natural course of positional down-beating nystagmus of peripheral origin. *J Neurol* 2013;260:1489-1496.
  47. Marques PS, Castillo R, Santos M, Perez-Fernandez N. Repositioning nystagmus: prognostic usefulness? *Acta Otolaryngol* 2014;134:491-496.
  48. Lynn S, Pool A, Rose D, Brey R, Suman V. Randomized trial of the canalith repositioning procedure. *Otolaryngol Head Neck Surg* 1995;113:712-720.
  49. Asawavichianginda S, Isipradit P, Snidvongs K, Supiyaphun P. Canalith repositioning for benign paroxysmal positional vertigo: a randomized, controlled trial. *Ear Nose Throat J* 2000;79:732-734, 736-737.
  50. Simhadri S, Panda N, Raghunathan M. Efficacy of particle repositioning maneuver in BPPV: a prospective study. *Am J Otolaryngol* 2003;24:355-360.
  51. Yimtae K, Srirompotong S, Srirompotong S, Sae-Seaw P. A randomized trial of the canalith repositioning procedure. *Laryngoscope* 2003;113:828-832.
  52. Chang AK, Schoeman G, Hill M. A randomized clinical trial to assess the efficacy of the Epley maneuver in the treatment of acute benign positional vertigo. *Acad Emerg Med* 2004;11:918-924.
  53. von Brevern M, Seelig T, Radtke A, Tiel-Wilck K, Neuhauser H, Lempert T. Short-term efficacy of Epley's manoeuvre: a double-blind randomised trial. *J Neurol Neurosurg Psychiatry* 2006;77:980-982.
  54. Chen Y, Zhuang J, Zhang L, Li Y, Jin Z, Zhao Z, et al. Short-term efficacy of Semont maneuver for benign paroxysmal positional vertigo: a double-blind randomized trial. *Otol Neurotol* 2012;33:1127-1130.
  55. Mandalà M, Santoro GP, Asprella Libonati G, Casani AP, Faralli M, Giannoni B, et al. Double-blind randomized trial on short-term efficacy of the Semont maneuver for the treatment of posterior canal benign paroxysmal positional vertigo. *J Neurol* 2012;259:882-885.
  56. Blakley BW. A randomized, controlled assessment of the canalith repositioning maneuver. *Otolaryngol Head Neck Surg* 1994;110:391-396.
  57. Kim JS, Oh SY, Lee SH, Kang JH, Kim DU, Jeong SH, et al. Randomized clinical trial for apogeotropic horizontal canal benign paroxysmal positional vertigo. *Neurology* 2012;78:159-166.
  58. Kim JS, Oh SY, Lee SH, Kang JH, Kim DU, Jeong SH, et al. Randomized clinical trial for geotropic horizontal canal benign paroxysmal positional vertigo. *Neurology* 2012;79:700-707.
  59. Mandalà M, Pepponi E, Santoro GP, Cambi J, Casani A, Faralli M, et al. Double-blind randomized trial on the efficacy of the Gufoni maneuver for treatment of lateral canal BPPV. *Laryngoscope* 2013;123:1782-1786.