

Contents lists available at [ScienceDirect](https://www.sciencedirect.com)

# Urology Case Reports

journal homepage: [www.elsevier.com/locate/eucr](https://www.elsevier.com/locate/eucr)

## Traumatic right testicular amputation with left testicular repositioning: A case report of a farmer from Nepal

Awaj Kafle<sup>a,\*</sup>, Sudhir Kumar Singh<sup>a</sup>, Rikesh Jung Karkee<sup>a</sup>, Samir Chaudhary<sup>a</sup>, Ankur Poudel<sup>b</sup>, Hardik Kumar Sethi<sup>c</sup>

<sup>a</sup> Division of Urology, B. P. Koirala Institute of Health Sciences, Dharan, Nepal

<sup>b</sup> Department of General Surgery, B. P. Koirala Institute of Health Sciences, Dharan, Nepal

<sup>c</sup> Department of Anaesthesiology and Critical Care, B. P. Koirala Institute of Health Sciences, Dharan, Nepal

### ARTICLE INFO

#### Keywords:

Testicular amputation  
Genital self-mutilation  
Testicular repositioning  
Genital trauma  
Testicular injury  
Penetrating injury

### ABSTRACT

Male external genitalia injury with testicular loss is relatively uncommon in civilian practice. Testicular amputation is usually found with military trauma and self-mutilation. However, they do occur while operating machines for domestic purposes. The standard protocols for the management of traumatic testicular amputation are lacking. The management is focused on resuscitation of the patient and restoration of testicular function with acceptable cosmesis. Here, we present a case of a 45-year-old man with traumatic right testicular amputation while he was using a thresher for rice cutting.

### 1. Introduction

Urological injuries account for 10% of all trauma cases, however, injury to male external genitalia, due to its secluded position, is relatively uncommon.<sup>1</sup> Scrotal and/or testicular injury account for only 1% of such cases.<sup>2</sup> Testicular loss is rare in civilian practice and is usually found after animal bites, military trauma, and self-mutilation.<sup>3</sup> Genital self-mutilation, a relatively rare phenomenon, has almost exclusively been described with psychotic disorders and substance abuse.<sup>4</sup> Here, we present a case of traumatic right testicular amputation with total loss of scrotal skin in a 45-year-old man while he was using a thresher for rice cutting.

### 2. Case presentation

A 45-year-old married male was brought to the emergency department of our hospital with an alleged history of trauma to the scrotum. He was using a thresher for cutting rice when accidentally his clothes got entangled in the machine. He sustained injury to the scrotal and inguinal region. He got treatment from a local hospital and was referred to our center 8 hours post-injury. On arrival to the emergency department, he was in shock with blood pressure recorded as 80/60 mm Hg and a pulse rate of 120 beats/min. He was resuscitated with intravenous fluids and

blood transfusion as his hemoglobin level was just 8 gm/dl.

On examination, his right testis was already amputated with localized hematoma in the right inguinal region. His left testis was hanging outside with total loss of scrotal skin (Fig. 1). After resuscitation, he was taken up for immediate exploration. Intra-operatively, there was localized hematoma in the right spermatic cord region with retraction of cord structures. His cord structures were followed retroperitoneally by extending the inguinal incision upwards where they were identified and doubly ligated (Fig. 2). Around 250 ml of blood clot was evacuated. After hemostasis was secured, copious irrigation with normal saline and hydrogen peroxide was done to minimize the contamination. As there was a total loss of scrotal skin, the left testis was repositioned in the medial aspect of the left thigh by creating a pouch (Fig. 3). Scrotal skin was closed using rotation flap from the thigh.

The patient received two more pints of blood transfusion post-operatively and was managed with broad-spectrum antibiotics and daily dressing. On ultrasonography, his left testis was viable and his serum testosterone level was within the normal limit (6.5 ngm/ml). The patient was discharged on the 10th postoperative day with a healthy incision wound.

\* Corresponding author. F-22-1-1, Ghopa Camp, BPKIHS, Dharan, Nepal.

E-mail addresses: [awaj.kafle.ak@gmail.com](mailto:awaj.kafle.ak@gmail.com) (A. Kafle), [drsinghsudhir@gmail.com](mailto:drsinghsudhir@gmail.com) (S. Kumar Singh), [dr.rikeshjung@gmail.com](mailto:dr.rikeshjung@gmail.com) (R. Jung Karkee), [nevergains@yahoo.com](mailto:nevergains@yahoo.com) (S. Chaudhary), [ankurpoudel86.86@gmail.com](mailto:ankurpoudel86.86@gmail.com) (A. Poudel), [hardiksethi90@yahoo.in](mailto:hardiksethi90@yahoo.in) (H. Kumar Sethi).

<https://doi.org/10.1016/j.eucr.2022.101993>

Received 16 December 2021; Received in revised form 24 December 2021; Accepted 6 January 2022

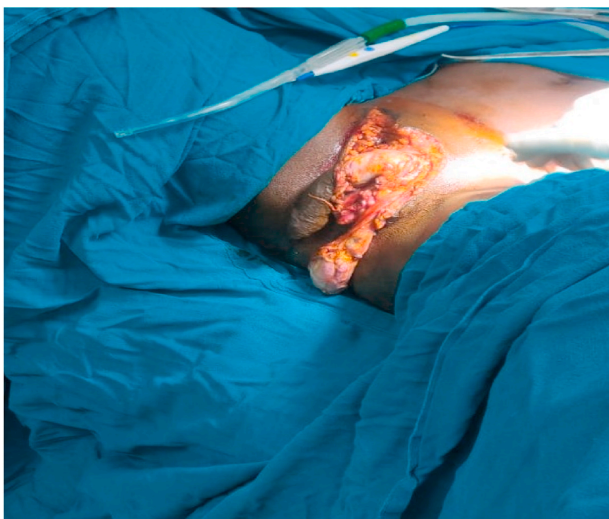
Available online 7 January 2022

2214-4420/© 2022 The Authors.

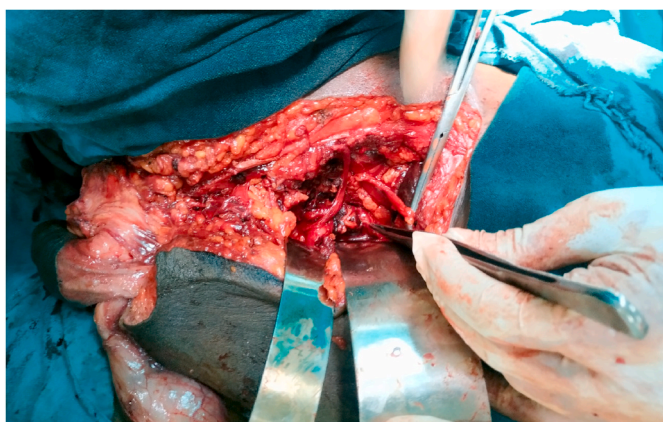Published by Elsevier Inc.

This is an open access article under the CC BY-NC-ND license

(<http://creativecommons.org/licenses/by-nc-nd/4.0/>).



**Fig. 1.** Pre-operative picture of the patient lying on operating table. Left testis is seen dangling outside due to total loss of scrotal skin.



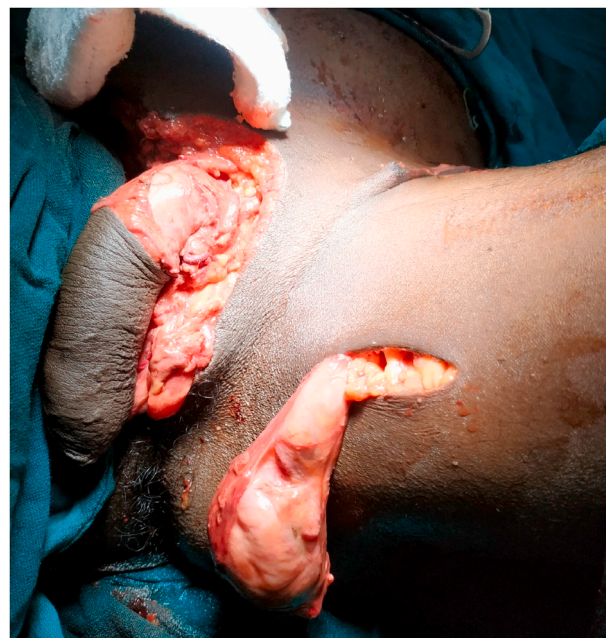
**Fig. 2.** Right testicular vessels were followed in retroperitoneum where they were identified and doubly ligated.

### 3. Discussion

Traumatic testicular amputation in civilian practice is uncommon.<sup>1</sup> The testis is protected by its mobility and relatively secluded position. Testicular injuries do occur in military trauma and are also self-inflicted by patients with psychotic disorders mostly under substance abuse.<sup>3,4</sup> Most of the cases of testicular amputation reported in the literature are of genital self-mutilation. Ramdas et al. reported a similar case of accidental injury to the perineum with bilateral testicular amputation.<sup>5</sup>

In our case, the patient was a novice to the cutting machine, got his clothes entangled, and landed up in shock following right testicular self-amputation. The management of traumatic testicular injury is typically twofold: resuscitation and preservation of function whenever possible with acceptable cosmesis. Few standardized protocols exist due to the lower incidence of male external genitalia injuries. The primary goal is to save the patient's life as the testicular vessels bleed heavily and retract easily. Testicular preservation should be attempted whenever possible as this will have a positive impact on the future well-being of the patient especially when the injury is bilateral. A microsurgical approach to testicular re-anastomosis is possible when patients land up as early as 6 hours and expertise is available.

In our case, we first resuscitated the patient and was taken up for immediate exploration once stabilized. His hemostasis was secured by ligating right spermatic vessels which was the prime aim of the surgery.



**Fig. 3.** Left testis about to be repositioned in the pouch created in the medial aspect of left thigh.

For this purpose, the spermatic vessels were traced retroperitoneally almost till their origin. His left testis was repositioned safely in the left medial thigh for future spermatogenesis and testosterone production. The scrotal defect was approximated using a simple rotation flap from the medial thigh.

Young adults without proper training when employed to operate these machines usually land up in disaster, as in our case the person was a novice and did not know how to operate the machine. So, we recommend proper training of individuals beforehand to prevent such mishaps.

### 4. Conclusion

Testicular amputations do occur in civilian practice, albeit rare. Due to the paucity of literature, standard guidelines are not available. However, a practicing urologist must be aware and be prepared for such injuries with care ranging from orchidectomy to testicular reimplantation.

### Consent

Written informed consent for publication of their clinical details and/or clinical images was obtained from the patient.

### Declaration of competing interest

None declared.

### Acknowledgement

None.

### References

1. Bjurlin MA, Kim DY, Zhao LC, et al. Clinical characteristics and surgical outcomes of penetrating external genital injuries. *J Trauma Acute care surg.* 2013 Mar 1;74(3):839–844.
2. Randhawa H, Blankstein U, Davies T. Scrotal trauma: a case report and review of the literature. *Can Urol Ass J.* 2019 Jun;13(6 Suppl4):S67.

3. Jones GH, Kirkman-Brown J, Sharma DM, Bowley D. Traumatic andropause after combat injury. *Case Rep.* 2015 Aug 28, 2015:bcr2014207924.
4. Charan SH, Reddy CP. Genital self mutilation in alcohol withdrawal state complicated with delirium. *Indian J Psychol Med.* 2011 Jul;33(2):188–190.
5. Ramdas S, Thomas A, Kumar SA. Temporary ectopic testicular replantation, refabrication and orthotopic transfer. *J Plast Reconstr Aesthetic Surg.* 2007 Jul 1;60(7):700–703.