

ORAL PRESENTATION

Open Access

# CMR real-time, free-breathing, phase contrast flow quantification: a novel approach to assess ventricular coupling in constrictive pericarditis

Paaladinesh Thavendirathan\*, David Verhaert, Michael Walls, Sanjay Rajagopalan, Chung Yiu-Cho, Orlando Simonetti, Subha V Raman

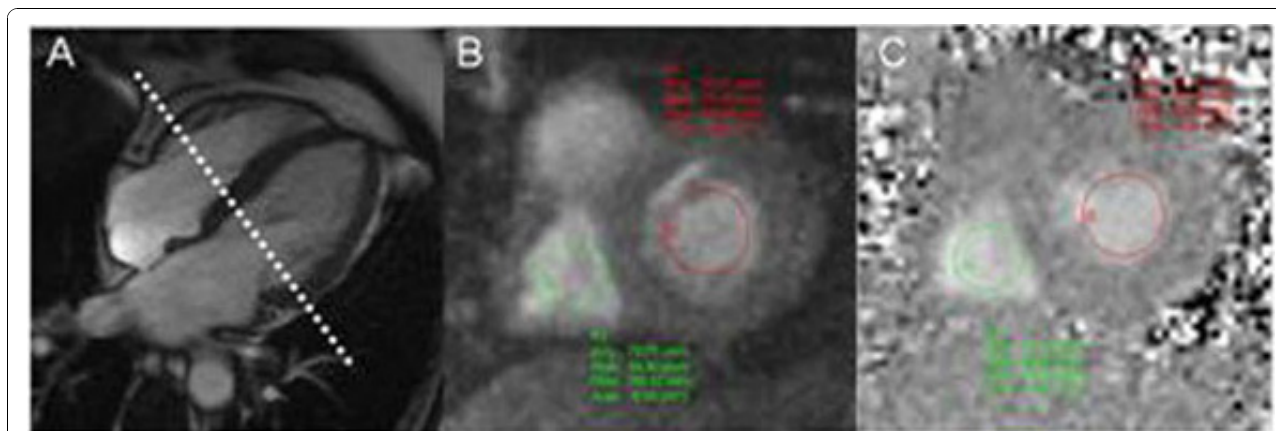
From 2011 SCMR/Euro CMR Joint Scientific Sessions  
Nice, France. 3-6 February 2011

## Background/objective

Constrictive pericarditis (CP) is an important cause of heart failure; however, with accurate diagnosis and directed treatment it is potentially curable. Cardiac magnetic resonance imaging (CMR) has played a diagnostic role, primarily by allowing assessment of pericardial morphology but with limited depiction of physiological changes. We sought to examine the feasibility of a novel CMR approach that enables real-time phase contrast (RT-PC) assessment of discordant respirophasic changes in trans-mitral and tricuspid flow velocity - the signature findings in CP - due to enhanced ventricular interdependence.

## Method

Patients referred to the CMR lab pre-pericardectomy or for assessment of suspected CP were included. Following routine CMR examination for CP, transmitral (MV) and tricuspid valve (TV) flow velocities were simultaneously obtained by through-plane RT-PC imaging during unrestricted respiration using a slice position to include both valves (Figure 1) with the following parameters: TR/TE=13.7ms/2.5ms, water excitation pulse with flip angle=25°, 10mm slice thickness, 160x120 matrix, EPI factor=15, TSENSE rate=2, slice thickness=10mm, and VENC=150cm/s. Shared velocity encoding was used to achieve an effective temporal



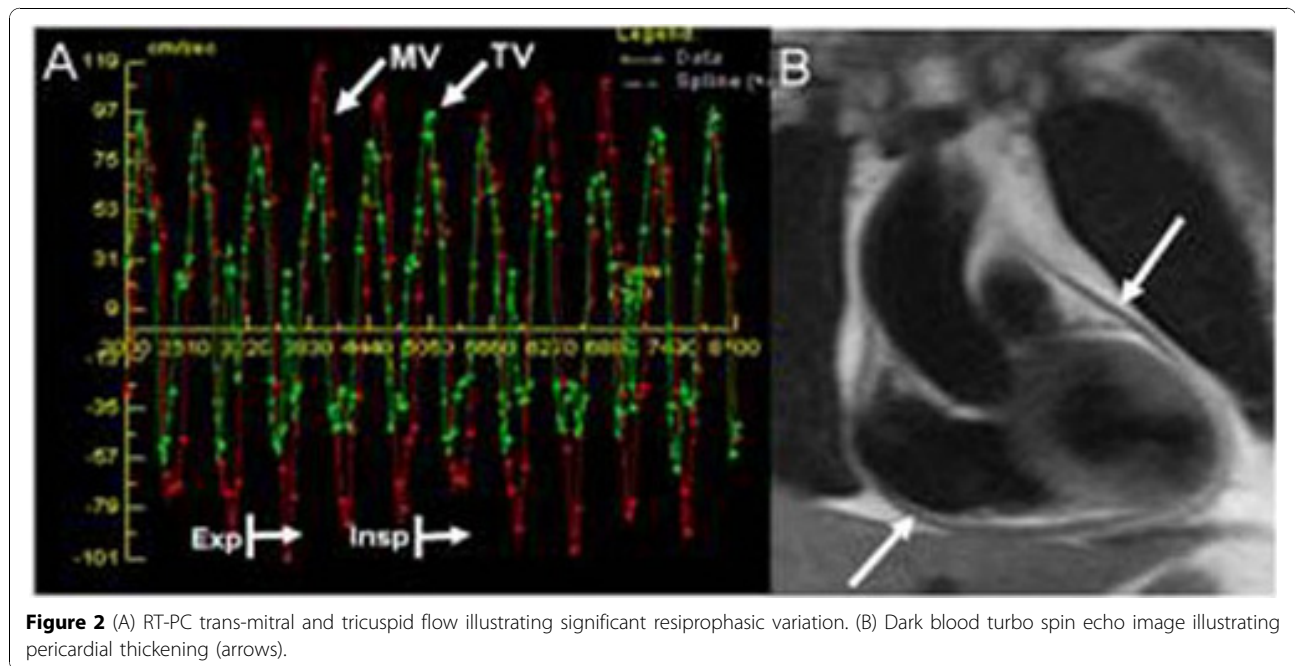
**Figure 1** (A) Horizontal long axis cine image used for selection of RT-PC imaging plane. (B) Magnitude and (C) phase images obtained with RT-PC acquisition. Regions of interest for mitral inflow (red) and tricuspid inflow (green) are illustrated in both the magnitude and phase images.

resolution of 55ms and typically, 200-400 phases were obtained. The diagnosis of CP was confirmed using a combination of clinical history, diagnostic imaging, invasive hemodynamic measurements, intra-operative findings, and histopathology. Regions of interest at the mid-portion of the MV and TV were chosen on the PC images (Figure 1). Peak velocity data from average of 4 neighboring pixels for both valves were displayed simultaneously (Figure 2). The percentage change in velocity were calculated for MV as  $(MV \text{ expiratory E velocity} -$

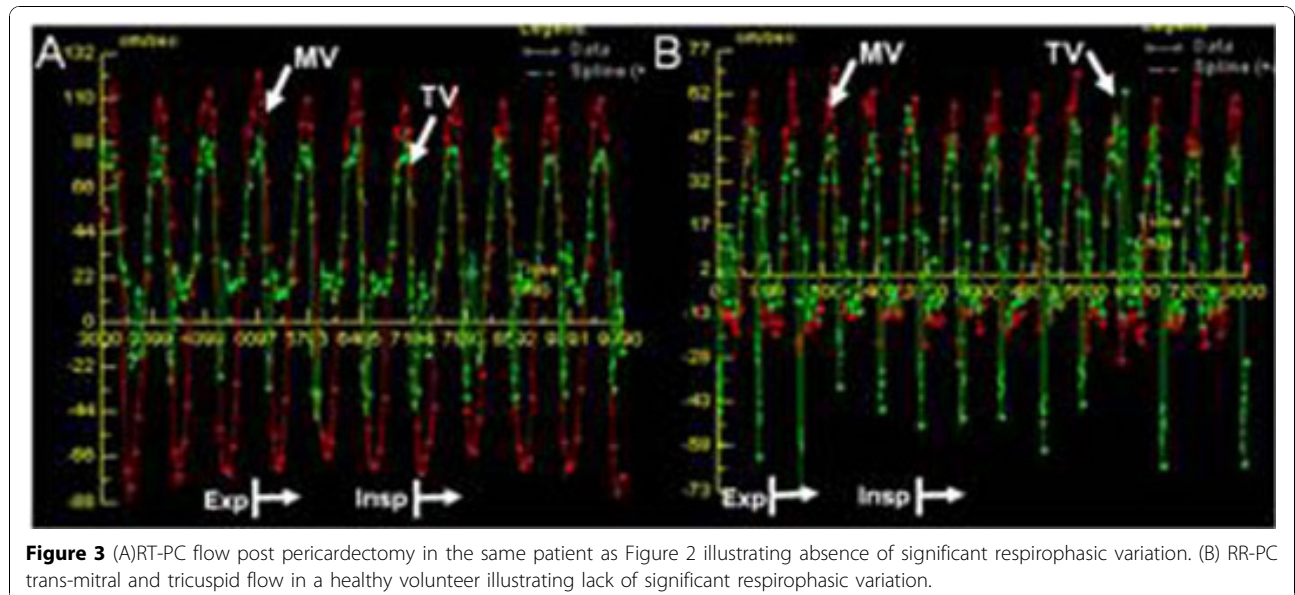
inspiratory E velocity)/(inspiratory E velocity) and for TV as  $(TV \text{ inspiratory E velocity} - \text{expiratory E velocity})/(\text{expiratory E velocity})$ .

### Results

9 patients (7 men, age  $56 \pm 17$  years) and 9 healthy volunteers (6 men, age  $31 \pm 10$ ) were included. All patients had increased pericardial thickness ( $6.3 \pm 1.5$ mm), a respirophasic shift of the interventricular septum, and inferior vena cava enlargement. Discordant



**Figure 2** (A) RT-PC trans-mitral and tricuspid flow illustrating significant respirophasic variation. (B) Dark blood turbo spin echo image illustrating pericardial thickening (arrows).



**Figure 3** (A) RT-PC flow post pericardectomy in the same patient as Figure 2 illustrating absence of significant respirophasic variation. (B) RR-PC trans-mitral and tricuspid flow in a healthy volunteer illustrating lack of significant respirophasic variation.

respirophasic flow velocities across the mitral and tricuspid valves were recorded in all CP patients (Figure 2), with mean trans-mitral and tricuspid flow velocity variation measuring  $46\pm 21\%$  and  $60\pm 16\%$  respectively, compared to  $17\pm 5\%$  ( $p=0.003$ ) and  $30\pm 13\%$  in controls ( $p<0.001$ ) (Figure 3).

### Conclusions

Reciprocal respirophasic changes in mitral and tricuspid inflow velocity in CP can be simultaneously displayed by RT-PC imaging. This provides essential hemodynamic information, which in conjunction with other morphological and functional changes is a useful addition to the diagnostic armamentarium of CMR for the diagnosis of CP.

Published: 2 February 2011

doi:10.1186/1532-429X-13-S1-O33

**Cite this article as:** Thavendiranathan *et al.*: CMR real-time, free-breathing, phase contrast flow quantification: a novel approach to assess ventricular coupling in constrictive pericarditis. *Journal of Cardiovascular Magnetic Resonance* 2011 **13**(Suppl 1):O33.

**Submit your next manuscript to BioMed Central  
and take full advantage of:**

- Convenient online submission
- Thorough peer review
- No space constraints or color figure charges
- Immediate publication on acceptance
- Inclusion in PubMed, CAS, Scopus and Google Scholar
- Research which is freely available for redistribution

Submit your manuscript at  
[www.biomedcentral.com/submit](http://www.biomedcentral.com/submit)

